17th WIMC

WARSAW INTERNATIONAL MEDICAL CONGRESS

ABSTRACT BOOK

MAY 6–8, 2022

WARSAW, POLAND

17th Warsaw Medical Congress

6th - 8th May 2022
Warsaw, Poland

Congress Internet Service
Website: www.wimc.wum.edu.pl
Facebook: Warsaw International Medical Congress
Instagram: _WIMC
wimc@wum.edu.pl

Contact
The Students' Scientific Association
at Medical University of Warsaw
1a Oczki St., 02-007 Warsaw, Poland
www.stn.wum.edu.pl
stn@wum.edu.pl

The Students' Scientific Association is not responsible for the content of abstracts contained in the book

Contents

1. Honorary Patronage
2. Institutional Patronage
3. Patronages
4. Partnership
5. Sponsors
6. Organisers
7. Abstracts
    - Basic & Preclinical Science
    - Cardiology & Cardiac Surgery
    - Dermatology
    - Endocrinology & Diabetes
    - Infectious Diseases
    - Internal Medicine
    - Laryngology, Audiology & Phoniatrics
    - Lifestyle Medicine & Public Health
    - Nephrology & Transplantology
    - Neurology & Neurosurgery
    - Obstetrics, Gynecology & Perinatology
    - Oncology & Hematology
    - Orthopedics & Traumatology
    - Psychiatry & Clinical Psychology
    - Surgery
    - PhD Basic & Preclinical Science
    - PhD Clinical & Health Science
    - Gynecological Case Report
    - Internal Case Report
    - Pediatrics Case Report
    - Surgical Case Report

Honorary Patronage

MEDICAL UNIVERSITY OF WARSAW

His Magnificence Rector of Medical University of Warsaw
Professor Zbigniew Gaciong, MD, PhD

MEDICAL UNIVERSITY OF WARSAW

Deputy Rector for Student Affairs and Education
Professor Marek Kuch, MD, PhD

MEDICAL UNIVERSITY OF WARSAW

Deputy Rector for Clinical Affairs and Investments
Professor Wojciech Lisik, MD, PhD

MEDICAL UNIVERSITY OF WARSAW

Deputy Rector for Human Resources
Professor Agnieszka Cudnoch - Jędrzejewska, MD, PhD

MEDICAL UNIVERSITY OF WARSAW

Deputy Rector for Science and Technology Transfer
Professor Piotr Pruszczyk, MD, PhD

MEDICAL UNIVERSITY OF WARSAW

Deputy Rector for Internationalisation, Promotion and Development
Professor Paweł Włodarski, MD, PhD

Dean of the Faculty of Medicine
Professor Rafał Krenke, MD, PhD

Dean of the Faculty of Medical Sciences
Professor Dariusz Białoszewski, MD, PhD

Dean of the Faculty of Health Science
Professor Mariusz Gujski, MD, PhD

Rector of Medical University of Lodz
Professor Radzisław Kordek, MD, PhD

Rector of Jagiellonian University Medical College
Professor Tomasz Grodzicki, MD, PhD

Rector of Medical University of Silesia
Professor Tomasz Szczepański, MD, PhD

Krajowa Reprezentacja Doktorantów

The Mayor of Warsaw
Rafał Trzaskowski

Naczelna Rada Lekarska

Institutional Patronages

Patronages

The Students' Scientific Association at Medical University of Lodz

The Students' Scientific Association at Medical University of Poznan

Partnership

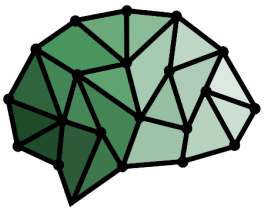

JUVENES PRO MEDICINA

Sponsors

Organisers

The Students' Scientific Association at Medical University of Warsaw

Head of the Organizing Committee: Jan Borkowski

President of the 17th Warsaw International Medical Congress: Anna Krawczyk

Scientific Programme: Magdalena Radziszewska, Jadwiga Jarosińska, Bartek Korzeb, Agnieszka Ozdarska, Agata Gaweł, Magdalena Justyniarska

Workshops: Julia Iwoła, Mikołaj Marszałek

Social Media: Mikołaj Marszałek, Michał Kurp

Gala Dinner: Marcin Łapiński, Jadwiga Jarosińska, Mikołaj Marszałek

Social Programme: Agnieszka Ozdarska, Marcin Łapiński

Corporate Partnerships, fundraising: Julia Iwoła, Anna Ziobro

International Relations and Patronages: Karolina Garbas, Anna-Maria Janik, Agata Gaweł

Session Coordinators

- Ewa Krzyżanowska
- Paweł Tyrna
- Hanna Feder
- Paulina Przybysz
- Emilia Piotrkowicz
- Klaudia Łuczak
- Monika Polkowska
- Monika Ryglewicz
- Robert Kołaczyński
- Carolyn Szwed
- Liwia Rogalewicz
- Karolina Piwko
- Natalia Krajewska
- Aleksandra Żuk
- Iwona Chaberska
- Maria Deczkowska
- Emilia Włoszek
- Weronika Zając
- Jędrzej Machtyl
- Zuzanna Kamińska
- Aleksandra Hyży
- Olga Adamska
- Aleksandra Śliwka
- Weronika Caban
- Anna Burban
- Dorota Słupik
- Anna Terlecka
- Bożena Pezała
- Szymon Lipiec
- Patryk Pindlowski
- Jakub Komorowski - Roszkiewicz
- Aleksandra Kawałko
- Magda Skudzińska
- Michał Zygarowicz
- Andrea Marianna Wirth

Basic & Preclinical Science

Date: 7th May 2022, 12:30 PM

Coordinators:
Ewa Krzyżanowska
Paweł Tyrna

Patronage:

Polskie Towarzystwo Immunologii Doświadczalnej i Klinicznej

Biuletyn Wydziału Farmaceutycznego Warszawskiego Uniwersytetu Medycznego

[1198] Targeting the tumor microenvironment using an anti-PD-L1 chimeric antigen receptor-redirected T cells – an in-vitro study.

Authors: Kuba Retecki
Affiliation: Department for Immunology MUW, Immunology Students' Science Association
Trustee of the paper: Małgorzata Bajor PhD, Mossakowski Medical Research Institute Polish Academy of Sciences

Corresponding author: Kuba Retecki (kuba.retecki@gmail.com)

Introduction
The microenvironment of solid tumors exerts an immunosuppressive impact on tumor-infiltrating lymphocytes and impairs their cytotoxic function against neoplastic cells. This phenomenon can be delineated by different mechanisms, of which the interaction embracing immune checkpoints plays a significant role. The tumor microenvironment (TME) is represented by tumor associated macrophages (TAMs), which are known to express PD-L1 molecule. We and others have previously shown that PD-L1-CAR T cells can effectively kill PD-L1 expressing cells. Therefore, we used PD-L1-CAR T to challenge the in vitro model of TAMs.

Aim of the study
The objective of this study was to assess the expression of PD-L1 on different macrophage populations which resembled macrophages in the TME and to evaluate the cytotoxic activity of PD-L1-CAR T cells against these cells.

Materials and methods
PD-L1-CAR construct consisting of atezolizumab-based scFv, IgG1 hinge, CD28 transmembrane region, CD28, and CD3ζ signaling domains, was introduced into CD3+ T cells isolated from peripheral blood mononuclear cells (PBMC) by lentiviral transduction to obtain PD-L1-CAR T. CD14+ cells were isolated from PBMC by negative immunoselection and stimulated with 100 ng/ml macrophage colony-stimulating factor (M-CSF) for 7 days to differentiate macrophages. Then, cells were stimulated with either 20 ng/ml IFNγ and 100 ng/ml LPS to obtain M1-like phenotype, or 20 ng/ml IL-4 and 20 ng/ml IL-10 to obtain M2-like phenotype. After four days of differentiation, cells were detached, washed, and used for further analysis. The surface marker expression on differentiated macrophages as well as PD-L1 expression was determined by flow cytometry. To assess the cytotoxicity of PD-L1-CAR-T against different populations of macrophages, an impedance-based Real-Time Cell Analysis (RTCA) was conducted.

Results
The purity and phenotype of differentiated populations of macrophages were confirmed. All macrophage groups were PD-L1 positive, however, cells differ in PD-L1 mean fluorescence intensity (MFI) between particular populations. The highest PD-L1 expression was detected in M2-like (IL-4+IL-10), intermediate in M1-like (IFNγ+LPS) and the lowest was observed in M0 group. All groups were effectively killed by PD-L1-CAR T in comparison to control T cells.

Conclusions
PD-L1 CAR T can effectively kill various populations of macrophages including those that present an immunosuppressive phenotype.

[1269] Comparison of digital project with crown substructures manufactured with three techniques: Direct Metal Laser Sintering, Milled Wax Technique and 3D Printed Resin Technique.

Authors: Kamila Wróbel-Bednarz, Aleksandra Sochańska, Agnieszka Ochał, Marcin Śmiechowicz
Affiliation: Medical University of Warsaw, Department of Prosthodontics
Trustee of the paper: Kamila Wróbel-Bednarz

Corresponding author: Marcin Śmiechowicz (msmiechowicz98@gmail.com)

Introduction
Marginal fit is one of the crucial factors influencing the positive outcome of long-term fixed prosthetic treatment. Digital technologies based on the CAD / CAM system, provides clinicians with new methods to design and manufacture crown substructures with marginal gap thickness value within 10 μm – 50 μm.

Aim of the study
To examine the accuracy of marginal adaptation of CoCr fixed prosthesis made with three methods: Direct Metal Laser Sintering (DMLS), Milled Wax Technique and 3D Printed Resin Technique.

Materials and methods
The abutment tooth model preparation was performed to obtain a chamfer margin. The surface of the abutment was scanned with an intraoral Trios III (3shape) scanner and uploaded to the EXOCAD program. Research material involved thirty metal CoCr crowns fabricated with three various methods:
I) 3D Printed Resin Technique (10 samples)
II) Direct Metal Laser Sintering (DMLS) from CoCr alloy powder (10 samples)
III) Milled Wax Technique (10 samples)
The abutment tooth and inner surfaces of crowns' frameworks were scanned with laboratory CAD star NEO scanner and uploaded to the GOM Inspect 2018 program. The Local Best Fit command was used to compare them and make heat maps after randomly marking fifty reference points on the marginal space of each crown. Extracted data were used to analyse the marginal fit between the original model and each sample in all three groups. Numerical data were subjected to statistical analysis with the STATISTICA program.

Results
The heat maps and data analysis demonstrated that the range of deviations between points differs between each group. In Group I, the highest discrepancy was observed, and the range of deviations oscillated between - 0.17 and + 0.15 mm. The lowest discrepancy range was obtained in Group II (-0.1 – 0.05 mm). However, in the Group III only positive deviations were observed with the range from 0 to + 0.17 mm.

Conclusions
In all three experimental groups the range of deviations is relatively small, which confirms that their usage can significantly improve the production process of fixed prostheses. The marginal fit of Direct Metal Laser Sintering patterns is more precise than the other two production techniques. The Milled Wax method, because of its smaller discrepancy range, is slightly more accurate than the 3D Printed Resin Technique.

[1284] Preliminary studies on identification of proteome differences between bronchoalveolar stem cells and alveolar type 2 cells

Authors: Susanne Leszczak, Kamila Bujko, Christian Leszczak, and Andrzej Ciechanowicz
Affiliation: Laboratory of Regenerative Medicine, Center for Preclinical Research, Medical University of Warsaw, Warsaw, Poland
Trustee of the paper: Andrzej Ciechanowicz

Corresponding author: Susanne Leszczak (leszczak.susanne@gmail.com)

Introduction
The bronchoalveolar duct junction (BADJ) is the termination point of the mouse airways, an area which has been found to house bronchioalveolar stem cells (BASC), a potentially crucial component of the lung regeneration process. However, whether BASC cells are a distinctive stem cell population in vivo continues to be an extensively debated topic, with the lack of a specific marker gene for BASCs being a contributing factor to the uncertainty of their action. Methods, not based on cell surface marker differences, should be explored to distinguish BASC cells from AT2.

Aim of the study
The aim of this project is to identify marker proteins characteristic for a BASC population isolated from the lungs of mice.

Materials and methods
The study was conducted on 24 healthy wild type (C57BL/6Clzd) mice. From isolated lungs we FACS sorted populations of BASCs and AT2 cells. Those cells were lyzed, digested and analyzed with the use of nano-UHPLC coupled to ESI-Q-TOF MS (Compact, Bruker). Mass spectra were analyzed with the use of DataAnalysis program and identified with the MASCOT server and SwissProt database. Identified proteins were annotated to signaling pathways and biological processes with the use of Uniprot.org.

Results
During proteomic analysis, we identified 6276 proteins, among which 1590 were characteristic and observed only among bronchoalveolar stem cells, 3081 were observed only in alveolar type 2 cells, and 1605 in both cell populations. Among proteins characteristic for BASCs, 45 proteins are involved in the cell population proliferation process and among the protein's characteristic for AT2 cells, 107 proteins were found to be involved in cell population proliferation. Moreover, 13 proteins among the protein's characteristic for BASC were annotated to stem cell differentiation and in the group of proteins identified only in AT2 cells, 26 were observed in this biological process.

Conclusions
We have identified 1590 potential marker proteins characteristic for bronchoalveolar stem cells, and 3081 potential marker proteins characteristic for alveolar type 2 cells.

[1307] Acetylsalicylic acid presents anticancer properties against melanoma by inhibiting PFKFB3 kinase

Authors: Natalia Sauer
Affiliation: Faculty of Pharmacy, Wroclaw Medical University, Wrocław, Poland
Trustee of the paper: Katarzyna Karłowicz-Bodalska

Corresponding author: Natalia Sauer (natalia.sauer99@gmail.com)

Introduction
Among cancers, melanoma is one of the most aggressive, due to its ability to spread to other organs more rapidly if it is not treated at an early stage. One of the melanomas types is amelanotic melanoma (AM), in which the malignant cells have little to no pigment. Cancer cells are highly proliferative, in which altered metabolism is pivotal for tumor growth, primarily by providing energy, reducing equivalents and building blocks. Most cancer cells show increased glycolysis, which is used as a metabolic pathway to generate ATP as a major energy source. PFKFB3 kinase is widely overexpressed in cancer and may represent an attractive target for therapeutic strategies.

Aim of the study
We aimed to investigate the role of acetylsalicylic acid, as an inhibitor of PFKFB3, on human amelanotic melanoma cells (C32).

Materials and methods
C32 cells were treated with different concentrations of acetylsalicylic acid. Treatment effects were assessed by measuring mitochondrial activity using the MTT assay. Caspase-3 Activity Assay was used to examine apoptotic activity. The studies were validated on 3D cell culture models. Acetylsalicylic acid and 3PO (selective inhibitor) were docked to PFKFB3 structure obtained from Protein Data Bank and MMGBSA values were calculated accordingly. Molecular docking studies were performed in Maestro (Schrödinger).

Results
Acetylsalicylic acid binds to the same inhibitory region of PFKFB3 as the selective inhibitor of the kinase 3PO. The drug inhibits the kinase, hence the C32 cells undergo necrosis. Our studies show that acetylsalicylic acid induce a cytotoxic effect and promotes necrosis cell death of C32 cells. The necrotic effects is also observed in 3D cell culture models as well.

Conclusions
The study demonstrated pronecrotic and antiproliferative effect on human amelanotic melanoma. Our findings suggest that acetylsalicylic acid presents anticancer properties by binding at the inhibitory site of PFKFB3. In the treatment of amelanotic melanoma, targeting PFKFB3 may be a promising therapeutic strategy.

[1320] Thiamine hydrochloride hydrates: mechanisms of dehydration

Authors: Ewa Napiórkowska, Katarzyna Milcarz, Łukasz Szeleszczuk
Affiliation: Department of Physical Chemistry, Faculty of Pharmacy, Medical University of Warsaw
Trustee of the paper: dr hab. n. farm. Łukasz Szeleszczuk

Corresponding author: Ewa Napiórkowsa (napiorkowskaewa07@gmail.com)

Introduction
Thiamine is water-soluble vitamin B1. Thiamine hydrochloride can occur in two forms of hydrates, monohydrate and hemihydrate, which differ by stability and water loss behaviour. Hydration and dehydration of solid API can alter physicochemical properties of the final product like stability, solubility thus bioavailability and effectiveness of pharmacotherapy. Furthermore, water is used in many manufacturing processes e.g., granulation and humidity can reduce storage time. Considering fact that most of drugs available on market are in solid forms and that form is the most convenient and preferred by patients, it is important to research hydrates behaviour during dehydration process.

Aim of the study
The aim of the study was to evaluate if it is possible to predict physicochemical properties of hydrates and differences in behaviour of dehydration using molecular modeling methods.

Materials and methods
Crystal structures of thiamine hydrochloride monohydrate and hemihydrate from the Cambridge Crystallographic Data Centre were used as initial for the periodic density functional theory (DFT) calculations. The study consists of geometry optimizations of crystal structures, gradual dehydration for both forms, geometry optimizations of modified structures with various water content to compare differences in energy and lattice parameters between the structures. NMR spectra have been simulated to compare with experimental data and explain the mechanism of dehydration. The next step was to conduct the ab initio molecular dynamic simulations under NPT conditions to include temperature impact on the dehydration process.

Results
Obtained computational results are in good agreement with an experimental data. They show that thiamine hydrochloride monohydrate and hemihydrate have significantly different mechanism of dehydration and characterise various vulnerability to water loss.

Conclusions
As it is presented in the example of thiamine hydrochloride hydrates, DFT periodic calculations are powerful in research of dehydration behaviour. Hydrates formulation can be one of the methods of creating new solid forms of drugs. Hence, investigating hydration/dehydration mechanism and stability of hydrates using molecular modeling could be an essential step in drug development.

[1334] Keratin Scaffolds Containing Casomorphin Stimulate Macrophage Infiltration and Accelerate Full-Thickness Cutaneous Wound Healing in Diabetic Mice

Authors: Rybka Mateusz 1, Laskowska Anna K 2, Kłodzińska Ewa 3, Sulejczak Dorota 4, Schwartz Robert A. 5, Czuwara Joanna 6, Konop Marek 1,6,7
Affiliation: (1), (2), (6) Medical University of Warsaw, Warsaw, Poland; (4), (7) Polish Academy of Sciences, Warsaw, Poland; (3) Institute of Sport-National Research Institute, Warsaw, Poland; (5) Rutgers New Jersey Medical School, Newark, USA
Trustee of the paper: Konop Marek, PhD

Corresponding author: Mateusz Rybka (maqmaq48@gmail.com)

Introduction
Impaired wound healing is a major medical problem, especially in diabetics patients. Many scientific groups look for new therapies, regeneration methods, which are based on the use of natural-derived biomaterials that accelerate wound healing. In this context keratin biomaterials are a promising candidate due to their biocompatibility, biodegradability, and bioactivity. In this study, casomorphin, an opioid peptide, was incorporated into fur keratin-derived powder (FKDP) and was tested as a wound dressing.

Aim of the study
Evaluation of the effect of keratin scaffolds containing casomorphin as a new therapeutic option in a diabetic full-thickness skin wound model in mice.

Materials and methods
Fur keratin-derived powder (FKDP) was prepared from mice fur and was coated with 0.1% solution of casomorphin (Caso). In vitro studies were made in a monolayer of NIH/3T3 cells. In vivo studies were made on twenty 12-15-week-old male C57BL6/J mice. In vitro experiment showed that this dressing is biocompatible, non-toxic and supports cell growth. In vivo study was made on mice with iatrogenically induced diabetes (streptozotocin at dose 80 mg/kg). Two full-thickness skin wounds were made on the mice's back, one was covered with FKDP + 0,1% Caso and the second one served as control and remained undressed. On days 5, 8 and 15 post-injury wounds were photographed. Histological and immunohistological stainings were performed to evaluate the changes during the healing process in both wounds.

Results
Wounds covered with keratin-casomorphin dressing demonstrated significantly ($p < 0.05$) faster process of skin wound healing to its final stage. They underwent faster reepithelization, ending up with a thicker epidermis than control wounds, as confirmed by histopathological and immunohistochemical examinations. This dressing stimulated macrophages infiltration, which favors tissue remodeling and regeneration, unlike in the control wounds in which neutrophils predominated. Dressed wounds presented a significantly decreased number of microhemorrhages as compared with control wounds. Applied dressing favored reconstruction of more regular skin structure and assured better cosmetic outcomes in terms of scar formation and appearance.

Conclusions
Keratin scaffolds containing casomorphin promote macrophages infiltration over neutrophils, which favors tissue remodeling and regeneration. Our results have shown that insoluble keratin wound dressing containing casomorphin supports skin regeneration and accelerates wound healing in diabetic mice.

[1335] "Stone heart" phenomenon as a collateral finding in the study of ischemia-reperfusion injury in the rat heart

Authors: Adrian Barzyc, dr n. med. Małgorzata Wojciechowska, Karol Momot, Wojciech Łysik, prof. dr hab. n. med. Agnieszka Cudnoch-Jędrzejewska, prof. dr hab. n. med. Marek Kuch
Affiliation: Katedra i Zakład Fizjologii Doświadczalnej i Klinicznej WUM
Trustee of the paper: prof. dr hab. n. med. Marek Kuch

Corresponding author: Adrian Barzyc (adrianbarzyc@gmail.com)

Introduction
In the treatment of acute coronary syndrome with ST segment elevation a coronary angioplasty procedure is used. However, the sudden restoration of blood flow to the ischemic area causes reperfusion injury, which may account for up to 50% of the final infarct size and increases the risk of arrhythmias.

Aim of the study
The aim of the study is to investigate whether the coronary administration of diphenyliodonium and L-arginine in an acidic buffer reduces the likelihood of life-threatening arrhythmias and has a positive effect on the size of post-infarction scar in rats, and thus reduces reperfusion injury.

Materials and methods
Sixty-seven 12-week-old male Sprague-Dawley rats were operated on under general anesthesia with ketamine and xylazine. First, the heparin was administered into the inferior vena cava, then the heart was excised. Each heart was connected to the Langendorff system. After a 15-minute period of monitoring systolic and diastolic pressure in the left ventricle accompanied by observation of possible arrhythmias, the flow in the Langendorff system was stopped. This method resulted in a 30 minutes long complete global myocardial ischemia. The buffer flow was then turned on again for 60 minutes. In the first group the Krebs-Henseleit buffer was used during reperfusion without any modifications, which served as a control group. The composition of the buffer used during reperfusion was modified by adding diphenyliodonium in groups 2,5,6,8, L-arginine in groups 3,5,7,8, and an acidic buffer in groups 4,6,7,8. At the end the size of the post-infarction scar was assessed in each heart.

Results
In the experiments conducted so far, an increase in pressure in the left ventricle were observed between 20 and 30 minutes of ischemia and during reperfusion in all studied groups. Moreover, in the heart muscle during reperfusion occurred the "stone heart" phenomenon. In the following minutes of reperfusion, a gradual normalization of pressure in the left ventricle and a subsiding of myocardial contracture were observed. There was no extensive myocardial necrosis. Further planimetric analysis and comparison of the incidence of life-threatening cardiac arrhythmias will be performed after completion of the study.

Conclusions
The obtained results go beyond the main goals of the study, which has not been fully conducted yet. The observations correspond to the reperfusion contracture described in the literature. It is postulated that it may be related to intracellular Ca2+ overload or malfunction of the mitochondria.

[1370] Immunological profile of relapsing-remitting MS (RRMS) patients at an early phase of the disease

Authors: Maja Machcińska, Magdalena Kierasińska, Martyna Michniowska, Marta Maruszewska-Cheruiyot, Ludmiła Szewczak, Rafał Rola, Anna Karlińska, Michael Stear, Katarzyna Donskow-Łysoniewska
Affiliation: Laboratory of Parasitology, General Karol Kaczkowski Military Institute of Hygiene and Epidemiology, 01-163 Warsaw, Poland
Trustee of the paper: Magdalena Kierasińska

Corresponding author: Magdalena Kierasińska (glaczynska.magdalena@gmail.com)

Introduction
Multiple sclerosis (MS) is an idiopathic chronic autoimmune and neurodegenerative disease that is one of the most common causes of very severe disability. The pathogenesis of the disease is not fully understood. The development of MS is caused by an imbalance between the regulatory response and the inflammatory response, with an increase in the level of pro-inflammatory IL-6 and the lack of sensitivity of autoreactive T cells to regulatory T cells (Treg).

Aim of the study
The purpose of our aim was to determine the immune profile of T cells and the level of cytokines in relapsing-remitting MS (RRMS) patients at an early phase of the disease. With particular emphasis on the levels of CD4+ and CD8+ Treg cells.

Materials and methods
PBMC and serum were isolated from peripheral blood from healthy donors and patients with relapsing-remitting multiple sclerosis (RRMS) without earlier treatment.
T regulatory cells from peripheral blood were analyzed using flow cytometry (14-color panel). The phenotype of Treg cells were analyzed based on surface markers including CD3, CD4, CD8, CD25, CD62L, CTLA-4, PD-1, GITR, CD122, CD28 and intracellular transcription factor: FoxP3 and Helios. The cytokine (TGFβ-1, IL-10, IL-6sR) levels in serum of RRMS patients and healthy donors were detected using the ELISA test.

Results
In RRMS patients compared to healthy donors were observed more CD8+CD25+FoxP3+ cells but fewer CD8+CD122+ cells and CD4+CD25+ cells. T cells analysis for immunosuppressive markers such as CD25, CTLA-4, PD-1, GITR and transcription factors FoxP3 and Helios show: - CD4+CD25+ and CD8+CD122+ T cells expressed more FoxP3 but less Helios in RRMS patients compared to healthy controls. - CD8+ T cells and CD4+ T cells in RRMS patients had reduced expression of the suppressive marker PD-1 but no changes for marker CTLA-4. The low expression of PD-1 on CD4+ and CD8+ T cells in RRMS patients correlated with the increased concentration of TGFβ -1 in serum. Additionally, this study examined the associations with disease, EDSS, gender and age.

Conclusions
These findings provide new insights into the composition of CD4+ and CD8+ T cells in RRMS patients and may contribute to the development of new ways of treatment for MS. This work was supported by grants from the TEAM TECH/2017-4/22 project carried out within the TEAM TECH programme of the Foundation for Polish Science, co-financed by the European Union under the European Regional Development Fund.

[1467] Hypomagnesemia is highly prevalent in transfused red blood cells

Authors: Katarzyna Pietrucha, Gabriela Górska, Justyna Malinowska, Milena Małecka-Giełdowska
Affiliation: Medical University of Warsaw
Trustee of the paper: Central Laboratory, Central Teaching Hospital of University Clinical Center of Medical University of Warsaw

Corresponding author: Katarzyna Pietrucha (katarzyna_pietrucha@wp.pl)

Introduction
Transfusion of red blood cells (RBCs) is a procedure conducted in many clinical settings, from severe anemia to hemorrhage shock. Although safe, it is associated with the risk of complications such as hypothermia, metabolic and electrolyte disturbances, among which is dysmagnesemia. Electrolyte disturbances can result from the patient's pre-existing disorders, or the blood donors, but also from loss of minerals related to the method of blood product processing. The high quality of the blood products used for the transfusion is of great clinical importance because of the fact that in patients with severe conditions disturbances of magnesium concentration already occur at the time of hospital admission and stay. Because magnesium is an intracellular cation, its concentration in RBCs provides a better reflection of body magnesium status than its serum concentration. However, it is not known, how often blood products have abnormal levels of magnesium.

Aim of the study
The aim of this study was to assess how often blood products have abnormal intracellular magnesium concentrations.

Materials and methods
We tested 108 RBCs samples, that were used for transfusion. Samples were frozen, diluted in a ratio of 1: 2, and lysed. Magnesium concentration was measured by the colorimetric method with Cobas 702 analyzer.

Results
The median RBCs magnesium concentration was 1.12 (0.34-3.18) mmol/l, which is below the reference values of 1.65–2.65 mmol/L. Hypomagnesemia was found in 79 (73%) samples with median concentration of 0.96 (0.34-1.62) mmol/l, normomagnesemia in 28 (26%) with mean concentration of 1.93±0.17 mmol/l, and hypermagnesemia in 1 (0.9%) with concentration of 3.18 mmol/l.

Conclusions
RBCs median magnesium concentration indicates a common magnesium deficiency in packed red blood cells intended for transfusion, which may affect mineral homeostasis in blood recipients.

[1473] Application of microspectroscopy in analysis of the cornea with keratoconus

Authors: 1. Paweł Oszczędłowski [1], 2. Przemysław Raczkiewicz [1], 3. Piotr Więsyk [1], 4. Katarzyna Nowakowska [1], 5. MD Abdelrahman Nassasra [2] Affiliation (University / Department)
Affiliation: (1) Medical University of Lublin, Students' Scientific Association at the Chair and Department of General and Pediatric Ophthalmology, (2) Medical University of Lublin, Chair and Department of General and Pediatric Ophthalmology
Trustee of the paper: Post-doctoral degree, PhD, MD Tomasz Chorągiewicz [2]

Corresponding author: Paweł Oszczędłowski (pawelosz99@gmail.com)

Introduction
Keratoconus is a non-inflammatory disease that results in thinning of the cornea. Its unclear origins are widely researched and discussed. Infrared spectroscopy is a procedure in which material is tested for its absorption of different wavelengths of light. FTIR is a variant of the technique, in which using interference between waves and interpreting it with linear operator named Fourier transform is applied to obtain more accurate results in a shorter time. The technique can be used to analyse biochemical changes in the material.

Aim of the study
To find specific marker spectral ranges of electromagnetic wave that can be applied in identifying biochemical changes in cornea with keratoconus.

Materials and methods
Corneal sections from multiple radical keratectomies were collected, formalin-fixed and paraffin embedded and then cut into 9 μm thick slides. Corneal tissue not affected by the disease process served as a control group. Slides were analysed with microspectrometer FTIR Vertex 70 with focal plane array detector. The spectra were recorded in the range from 4000 cm-1 to 850 cm-1, with 4 cm-1 resolution, 64 sample scans and 64 background scans.

Results
The performed spectral analyses allowed for the identification of the 4 frequency ranges characterizing the spectral differences between the cornea in the course of keratoconus and the normal cornea.

Conclusions
Biochemical profile of the cornea changes in the course of keratoconus. Therefore, identified spectral ranges of electromagnetic wave can be possibly used to research the origins of that disease. The further research should aim at discovering the mechanisms of alteration and investigate the usability of FTIR in keratoconus diagnostics.

[1494] Mechanistic study of novel gold(III) complex in in vitro colon cancer model: a potential alternative for cisplatin?

Authors: Szymon Lipiec, Izabela Agnieszczak, Przemysław Szymański, Agata Gurba, Łukasz Szeleszczuk, Przemysław Taciak, Jakub Fichna, Izabela Młynarczuk-Biały
Affiliation: Histology and Embryology Students' Science Association at the Department of Histology and Embryology, Faculty of Medicine, Medical University of Warsaw, Chałubińskiego 5, 02-004 Warsaw, Poland
Trustee of the paper: Izabela Młynarczuk-Biały

Corresponding author: Szymon Lipiec (szymonlipiec55@gmail.com)

Introduction
Cisplatin was the first metal-based agent to enter into clinical use for cancer treatment. However, the application of this platinum(II) drug is limited by heavy side effects. Thus, there is a need to develop a less toxic alternative to cisplatin. Gold(III) compounds, which are isoelectronic with platinum(II), may be good candidates. Several studies have shown that gold(III) agents have great antiproliferative properties, but none of these complexes got into clinical use in cancer treatment. Therefore, our team has developed innovative gold(III) complex (TGS 121) with the formula [Au(CN)4]2 (ClO2)Na.

Aim of the study
Within this study, our team aimed to examine the anti-cancer potential and safety profile of TGS 121. We also try to define the most probable molecular targets for our novel gold(III) complex.

Materials and methods
The cytotoxicity of TGS 121 was assessed on human colon cancer cells (Colo-205), parental nonmalignant fibroblasts (NIH3t3), and their variant with Ha-Ras mutation (Ras-3T3), also on isolated peripheral blood mononuclear cells (PBMC). The SI value was calculated as the ratio of IC50 values of TGS 121 for NIH3t3 and Ras-3t3 cells. The cell cycle phases distribution was analyzed and cell morphology was assessed. Moreover, in vitro wound-healing assay was performed.

Results
Antiproliferative properties were observed against colon cancer cells and Ha-Ras-transfected fibroblasts. The IC50 values for NIH3t3 were significantly lower than in Ras-3t3. Selectivity indexes (for NIH3t3/Ras-3t3 cells) were 4 and 21.9 respectively for 24h and 48h of incubation. The viability of PBMC was not decreased in concentrations lethal to malignant cells. Arrest at the G2/M phase was observed in Colo-205 and Ras3t3 cells. The migration of cells treated with TGS 121 was limited.

Conclusions
TGS 121 turned out to be selective for malignant cells in comparison to normal cells. Significantly lower viability of Ras-3t3 cells compared to normal NIH3t3 cells proclaim that the Ras-Raf-MEK-ERK pathway is a probable molecular target of the investigated agent. Based on our results we propose that this compound may be a good candidate for further assessment of its safety and utility as a potential antitumor drug, especially in colon cancer.

Cardiology & Cardiac Surgery

Date: 6th May 2022, 11:30 AM

Coordinator:
Natalia Krajewska

Patronage:

Konsultant Krajowy w dziedzinie Angiologii

prof. dr. hab. Aleksander Sieroń

Klub 30
Polskiego Towarzystwa Kardiologicznego

Prezes dr. hab. n. med. Agnieszka Kapłoń - Cieślicka

[1150] Risk of undiagnosed diabetes in patients undergoing coronary artery angiography: A cross-sectional study

Authors: Mohammadamin Sadeghdoust, Tolou Hasandokht, Arsalan Salari, Sofia Jafarpoor, Farnaz Aligolighasemabadi

Affiliation: Health Policy Research Centre, Institute of Health, Shiraz University of Medical Sciences, Shiraz, Iran
Trustee of the paper: Arsalan Salari

Corresponding author: Mohammadamin Sadeghdoust (m.sadeghdoust@gmail.com)

Introduction
Previous studies revealed high prevalence of undiagnosed diabetes in general population. Also, a higher frequency of coronary artery diseases (CAD) is reported in patients with undiagnosed diabetes compared to non-diabetic patients.

Aim of the study
The purpose of this study is to stratify the risk for diabetes in patients undergoing coronary artery angiography.

Materials and methods
This was a cross-sectional study conducted in a tertiary university-based hospital from June 2020 to November 2021. Candidate patients for coronary artery angiography, who were not diagnosed with diabetes at the time of angiography and also were not under treatment with any diabetes medications, were included in this research. American Diabetes Association Risk Score (ADA) were calculated for each patient by using variables such as age, sex, weight, height, family history of diabetes, gestational diabetes, and physical activity. Then, ADA risk was classified as high (score> 5), moderate (score=4) and low (score<4).

Results
Three-hundred patients (male=59.3%) with mean age of 59.44 ± 15.7 years were included in this study. Only 24.3% of subjects were in low-risk category, while 32% and 43.7% were at moderate and high-risk categories, respectively. In addition, the frequency of patients with at least two coronary artery involvement was significantly higher high-risk group (43.1%) compared to either moderate (34.4%) and low risk groups (22.5%) (p=0.02).

Conclusions
This study revealed that almost half of the patients with AMI are at high risk of undiagnosed diabetes. So, the risk of diabetes as a cardiometabolic risk factor must be assessed carefully in AMI patients in order to control the associated risk factors and achieve a better disease outcome.

[1154] Assessment of incidence of fragmented QRS in electrocardiography in patients with systemic sclerosis and systemic lupus erythematosus

Authors: Ewa Tomicka, Jan Wójcik, Szymon Staneta, Tomasz Cader, Olaf Wasilewski, Monika Lisicka, Piotr Pruszczyk, Michał Ciurzyński, Piotr Bienias
Affiliation: Students` Scientific Association ZATOR by Department of Internal Medicine and Cardiology, Medical University of Warsaw, Poland; Department of Internal Medicine and Cardiology, Medical University of Warsaw, Poland
Trustee of the paper: Piotr Bienias

Corresponding author: Ewa Tomicka (ewa.tomicka@vp.pl)

Introduction
Various cardiovascular complications including arrhythmias and sudden death can occur in connective tissue diseases. Cardiac involvement is most common in patients with systemic sclerosis (SSc) and systemic lupus erythematosus (SLE).

Aim of the study
To assess the presence of a new electrocardiographic parameter i.e. fragmented QRS (fQRS), which may indicate a scar or diffuse damage of the heart muscle or conduction system disturbances. We also aimed to test whether fQRS could be considered a potential marker of asymptomatic heart involvement in SSc and SLE, while previous data indicate that fQRS may be present in approximately 5% of healthy subjects.

Material and methods
We examined 74 consecutive patients with SSc and 77 with SLE. Accurate patients` ECG assessment was performed manually under expert supervision. Among other evaluations, we examined fQRS incidence according to worldwide accepted Das` criteria. Disease severity in SSc and SLE was estimated by Rodnan and SLICCC/ACR-DI scores, respectively.

Results
Compared to patients with SSc, those with SLE were slightly younger (53±14 vs 46±14 yrs), women constituted 88.3% and 90.5% of studied groups (p=0.80). The duration of disease in SSc and SLE patient was similar (9.45±10.4 vs 10,2±8.7, p=0.59). Median of Rodnan and SLICCC/ACR-DI scores were 5 and 4 points, respectively.
Mean value of left ventricle ejection fraction in both studied groups was similar (65,5 vs 65,1%, p=0.51), whereas mean tricuspid regurgitation pressure gradient was higher in SSc (26.4 vs 21.5 mmHg, p=0.00006). Hypertension incidence was lower in SSc patients (24.3%) compared to SLE (48.1%), p=0.004. Compared to SSc, patients with SLE also presented prolonged corrected QT interval (432 vs 424 ms, p=0.03).
It is worth noting that in our studied groups fQRS occurred very often and were observed in 34 (45.9%) SSc and 29 (37.7%) SLE patients, p=0.33. Notched S waves were significantly more frequent in SSc than in SLE (in 27,5% vs 10.7%, p=0.01), while other fQRS (i.e. additional R or notched R wave) occurred with a similar frequency.

Conclusions
Although the most common cardiac complications in SSc and SLE are different, the incidence of fQRS in both diseases is similar. We observed a very high incidence of fQRS in SSc and SLE, which is much more common than in healthy subjects. It is possible that fQRS may be considered an additional marker of heart involvement in these rare diseases.

[1181] Early stratification of the severity of coronary artery disease in patients with chest pain

Authors: Patrycja Pabis, Radosław Szydłowski, Marta Siwek, Elżbieta Rynkiewicz
Affiliation: Medical University of Silesia in Katowice/ Department of Cardiology
Trustee: dr hab. n. med. Beata Morawiec, prof SUM; dr hab. n. med. Damian Kawecki, prof SUM

Corresponding author: Patrycja Pabis (patrycjapabis.lek@gmail.com)

Introduction

The knowledge on presence, extent and severity of coronary artery disease (CAD) in patients presenting with chest pain might improve early management of this large and heterogenic group of patients.

Aim of the study

The aim of this study was to evaluate early predictors of the severity of CAD and the prognosis in patients with chest pain in the emergency department.

Material and methods

Consecutive patients with chest pain presenting to the emergency department and at least one coronary artery stenosis on coronary angiogram were enrolled in this prospective study and stratified into groups depending on the severity of CAD into: one- (1VD), two- (2VD) or multivessel disease (3VD). Baseline clinical characteristics, medical history, electrocardiographic findings and final diagnosis were compared between groups. Patients were followed-up for one year for the incidence of major adverse cardiac events (MACE: death, non-fatal myocardial infarction and acute revascularization).

Results

From the total of 485 patients with chest pain, 458 patients had coronary angiogram and 376 were diagnosed with CAD, after exclusion of 39 patients with the history of CABG, 116 (34% had 1VD, 114 (34%) had 2VD and 107 (32%) had 3VD.

Relatively to increasing severity of CAD, patients were older ($p<0.001$), had lower baseline GFR ($p=0.002$), more often were male ($p=0.004$), with the history of peripheral artery disease (PAD) ($p=0.007$) and diabetes ($p=0.037$) but there were less active smokers ($p=0.009$). Baseline ejection fraction (EF) was the lowest and EDD was the largest in 3VD group ($p<0.001$ and $p=0.002$, respectively). Baseline hs-TnT concentration increased significantly with increasing severity of CAD ($p=0.004$). Ischemic pattern in baseline ECG was the most frequent in 3VD ($p=0.029$), but only ST-segment depression was significantly different between groups ($p=0.006$). There were significant but weak correlations between these variables and the severity of CAD (correlation r range -0.177;0.207).There was no difference in the incidence of MACE at follow-up in regard to the severity of CAD and the severity of CAD was not a risk factor for MACCE in Cox analysis (HR 1.27 95%CI 0.85-1.90, $p=0.25$).

Conclusions

Complex baseline screening of ECG, echocardiography and single blood draw together with screening for specific risk factors from medical history may help to identify patients at higher probability of diffuse CAD. Nevertheless, the severity of CAD was not a risk factor at one year.

[1193] Mortality risk after transcatheter aortic valve implantation in severe aortic stenotic patients with frailty syndrome based on Katz scale.

Authors: Monika Ryglewicz1, Patryk Pindlowski1, Katarzyna Byczkowska2, Agnieszka Pawlak2,3
Affiliation: 1. 4th year medical student, Medical University of Warsaw 2. Cardiology Department Central Clinical Hospital of the Ministry of Interior and Administration, Woloska 137 Warsaw, Poland 3. Mossakowski Medical Research Institute, Polish Academy of Sciences
Trustee of the paper: Profesor Agnieszka Pawlak

Corresponding author: Monika Ryglewicz (mryglewicz@op.pl)

Introduction
Frailty syndrome is a common comorbidity in elderly people with symptomatic severe aortic stenosis. We think it is essential to evaluate stratification risk in transcatheter aortic valve implantation (TAVI) by defining frailty as a prognostic clinical factor.

Aim of the study
Recent studies have shown higher morbidity and mortality in patients undergoing TAVI due to frailty syndrome. The aim of present study was to evaluate prognostic value in patients with frailty undergoing TAVI procedure by using STS risk score.

Material and methods
This is a one-center registry study including 105 patients with severe aortic stenosis (AS) and treated with TAVI at the Department of Invasive Cardiology, Central Clinical Hospital of the Ministry of Interior. In study group all patients were confirmed with frailty syndrome and 48% of them with advanced stage based on frailty Katz's score.

Results
1 year follow-up observation showed difference between survival and Katz's frailty score performed before TAVI. Patients with moderate to severe frailty syndrome with Katz score <4 had 3,28 higher risk of cardiovascular death per year compared to the group of independent patients with score > 5 of Katz's scale. After 1 year follow-up mortality of patients with Katz score <4 was 30 % and those with score >5 was accordingly 3%.

Conclusions
The Katz frailty score is important prognostic risk factor in patients with moderate and severe frailty syndrome. It correlates also with much more higher cardiovascular death risk in patients undergoing TAVI .

[1225] Very early risk modeling in patients with chest pain based on the pattern of admission ECG

Authors: Radosław Szydłowski, Patrycja Pabis, Marta Siwek, Elżbieta Rynkiewicz, Maciej Kocjan, Piotr Muzyk
Affiliation: Śląski Uniwersytet Medyczny w Katowicach
Trustee of the paper: Beata Morawiec, Damian Kawecki

Corresponding author: Radosław Szydłowski (radwielki@gmail.com)

Introduction
Electrocardiographic study is one of the first available examinations in patients with chest pain and suspected acute myocardial infarction. High proportion of this group presents with no ischemic changes on ECG, which may be misleading and delay appropriate management.

Aim of the study
The aim of this study was to assess diagnostic accuracy of very early risk modeling based on the pattern of admission ECG.

Material and methods
This prospective registry included adult patients with chest pain and suspected for AMI. Patients were divided into groups with and without ischemic ECG changes. ECG criteria of ST-segment elevation/depression and negative T waves from the 4th universal definition of AMI were applied to define ischemia on admission ECG. Major adverse cardiac event were death, non-fatal myocardial infarction and acute revascularization at one year.

Results
From the total of 483 patients, after exclusion of STEMI (93 patients), 390 patients were available for analysis. 231 patients had ischemic changes on ECG (59%). AMI was diagnosed in 259 patients (65%), among them NSTEMI in 238 (92%), AMI type 2 in 21 patients (8%). Patients with ischemia on admission ECG were older, had higher admission high-sensitivity troponin T, lower GFR, and lower EF, higher incidence of MACCE, death and AMI at one year with no difference at 3 months. Ischemia on admission ECG was a single risk factor of MACCE at one year and remained significant in multivariate model together with admission hs-TnT and EF. Single admission hs-TnT concentration was not a risk factor of adverse events, nor was the final diagnosis of AMI. There was a correlation between admission ischemia on ECG and hs-TnT concentration with 194/304 (64%) positive admission hs-TnT cases in ischemic ECG group. As early as at admission, the combination of ischemic ECG and positive hs-TnT identified the group of patients at the highest risk of MACCE at one year. The combination of ischemic ECG with the final diagnosis of AMI increased the predictive value of AMI alone.

Conclusions
Ischemia on admission ECG in patients presenting chest pain and suspected for AMI is a strong pre-hospital risk factor of adverse events at one year. Additional early stratification with single hs-TnT draw at admission identifies the group of the highest risk of adverse events better than postponed risk stratification based on final diagnosis of AMI. Ischemic changes on admission ECG increase one year risk of MACCE in AMI patients.

[1270] Assessment of virtual reality in morphometric analysis of tetralogy of Fallot

Authors: Antoni Ludew, Maksym Helman, Nikola Topuzov
Affiliation: Medical University of Warsaw, Department of Descriptive and Clinical Anatomy
Trustee of the paper: Adam Koleśnik MD

Corresponding author: Antoni Ludew (s083677@student.wum.edu.pl)

Introduction

Tetralogy of Fallot (ToF) is a lesion produced by a combination of two features - antero-cephalad malposition of the outlet septum and hypertrophy of the right ventricle outflow tract (RVOT) trabeculations, resulting in changes in right ventricle proportions and geometry, yet studies regarding the morphometry rely mostly on fixed specimens or CT scans. More complex studies have been analysed using 3D reconstructions, 3D-printing and more recently virtual reality.

Aim of the study

The aim of our study was to assess the value of direct virtual reality volume rendering in morphological measurements in patients with ToF.

Material and methods

The study involved 10 CT scans of paediatric patients with ToF performed prior to the treatment which were rendered directly in virtual reality using VMersive software. The patients' age at the time of the CT scan ranged from 0 to 294 days (median = 34). The measurements involved: outlet septum (OS) width, length of the right ventricle, diameters of RVOT, pulmonary trunk (PT), the aorta at the level of outlet septum and in sinotubular junction (STJ) and the length of the PT. Subsequently following proportions were calculated: RVOT diameter to the whole infundibulum (defined as a sum of RVOT diameter, OS width and aorta diameter at the level of OS), RVOT length to the total length of the RV and PT to RVOT length.

Results

All measurements were possible to be performed in VR reconstructions, the mean time of analysis being 36 min. The mean OS width was 3.9 mm, mean RVOT diameter was 6.69 mm, RVOT length was 12.33 mm, right ventricle length was 43.18 mm and mean subaortic diameter was 12.76 mm. In our study RVOT diameter comprised 0.28 of the infundibulum, RVOT length comprised 0.26 of the total RV length and mean PT to RVOT length proportion was 1.42.

Conclusions

Volume rendering of DICOM files in virtual reality can be used for morphological assessment of ToF and possibly other congenital heart defects. The authors consider the method of virtual rendering to be more intuitive and easier to learn. The method also allows for analysis of three-dimensional anatomy without time consuming 3D-modeling and 3D-printing.

[1446] A 6-year analysis of the etiology of infective endocarditis in the single center

Authors: Dorota Słupik, Aleksandra Reda, Anna Burban, Mateusz Ziomek, Miłosz Starczyński
Affiliation: Medical University of Warsaw
Trustee of the paper: Agnieszka Kołodzińska

Corresponding author: Dorota Słupik (slupikdorota@gmail.com)

Introduction
Infective endocarditis (IE) is still a disease associated with high mortality and often serious complications. The most common microorganism found in patients with IE is Staphylococcus aureus. Together with viridans group streptococci and enterococci, it is responsible for up to 90% of IE cases.

Aim of the study
The aim of this study was to analyse the etiology and the correlation between etiology and the type of valve involved or cardiac device implanted in patients with infective endocarditis.

Material and methods
95 patients diagnosed with infective endocarditis between 2015 and 2021 were included to this single-centre study. The diagnosis of IE was based on modified Duke criteria.

Results
IE with negative blood cultures was the most common diagnosis, found in 20 out of 95 patients, representing 21%. The most common etiology causing IE was Staphylococcus aureus MSSA- 15 out of 95 patients (15.8%). The third most common cause was mixed etiologies, which were found in 13 out of 95 patients (13.7%).
IE with valve involvement was diagnosed in 63 patients. The most frequently involved valve was the aortic valve (34.7%), where a staphylococcal etiology was found in 33.3% of cases, of which 45.4% were MSSA and 36.4% Staphylococcus epidermidis. Staphylococcal etiology was also predominant on the mitral valve and in patients with cardiovascular implantable electronic devices IE. 21/95 required valve replacement, and 24/37 whole hardware removal. Mortality rate was 26/95 (27,4%) with predomination of Staphylococcus aureus MSSA.

Conclusions
Staphylococcus aureus is the predominant microorganism in both IE found on heart valves and CIED IE, and is associated with patient's death/mortality.

[1447] Mobile App and Digital System for Patients After Myocardial Infarction (afterAMI): early results from a prospective, open-label, randomized trial

Authors: Bartosz Krzowski, Michał Peller, Maria Boszko, Paulina Hoffman, Natalia Żurawska, Kamila Skoczylas, Gabriela Osak, Łukasz Kołtowski, Marcin Grabowski, Grzegorz Opolski, Paweł Balsam
Affiliation: 1st Chair and Department of Cardiology, Medical University of Warsaw, Warsaw, Poland
Trustee of the paper: Bartosz Krzowski

Corresponding author: Maria Boszko (mariaboszko@gmail.com)

Introduction
Treatment of acute myocardial infarction has been significantly improved. However, managing patients' cardiovascular risk factors in the early months after discharge requires further improvements. Establishing optimal control in this stage of recovery is crucial for patient's long-term prognosis. Telemedical solutions are a field of extensive research. 'afterAMI' is a mobile application dedicated to patients after myocardial infarction. It offers an educational mode, visit calendar, vital signs diary, medication reminders and other features. Evidence on the feasibility of telemedical solutions in patients with coronary artery disease is limited.

Aim of the study
To perform a comprehensive evaluation of a newly developed mobile application in the clinical setting.

Material and methods

This was a prospective, open-label, randomized, single-center study. 100 patients with myocardial infarction were enrolled. On admission, the patients were randomized into two groups: one with a digital support system (afterAMI) (n=50), the other with a standard model of care (n=50). We assessed the impact of mobile app assist on LDL-cholesterol levels during the rehabilitation process, 1-month after discharge.

Results
The majority of the studied population in both groups were man (68% vs 61%, p=0.67). Mean age of the population was 60.11 ± 10.84 years old. There were no differences between groups in the mean cholesterol level during hospitalization (116.24 ± 67.58 mg/dl vs 110.35 ± 55.2 mg/dl, p=0.65). Patients in the intervention group had significantly lower LDL level on the first follow-up visit (50 ± 24.59 mg/dl vs 73.45 ± 28.91 mg/dl, p=0.001). Additionally, significantly more patients in the digital support group met treatment goals established in the European guidelines, compared to the group with standard model of care (58% vs 22%, p=0.005). However, there was no significant difference in the cholesterol level change between the groups, during the period between hospitalization and control visit (65.00 ± 45.51 mg/dl vs 39.17 ± 65.05 mg/dl, p=0.099).

Conclusions
Mobile-app-based digital system of care contributed to a reduction in mean LDL-cholesterol concentrations. Moreover, patients in the study group were more likely to meet recommended target goals. This study exemplifies the clinical utility of novel, telemedical solution in everyday clinical practice. Innovative cardiac rehabilitation process enhancements can improve patients' cardiovascular risk factors' control.

[1480] Leukocyte extracellular vesicles as the first biomarkers to predict outcomes in patients undergoing percutaneous aortic valve replacement

Authors: Olaf Domaszk, Katarzyna Pieniak, Szymon Jędrzejczyk, Magdalena Chudzik, Aleksandra Gąsecka, Marcin Grabowski, Zenon Huczek, Janusz Kochman
Affiliation: 1st Chair and Department of Cardiology, Medical University of Warsaw
Trustee of the paper: Aleksandra Gąsecka

Corresponding author: Olaf Domaszk (olafdomaszk@gmail.com

Introduction
Transcatheter aortic valve implantation (TAVI) is a novel treatment for aortic stenosis (AS), associated with better outcomes than surgical aortic valve replacement in high-risk patients. However, up to 29% of patients annually experience major adverse cardiac and cerebrovascular events (MACCE) after TAVI. MACCE are mostly caused by atherothrombosis, i.e. formation of platelet aggregates (thrombi) on ruptured atherosclerotic plaques. Because platelets release extracellular vesicles (EVs) during thrombus formation, we hypothesized that EVs are a biomarker to predict MACCE after TAVI.

Aim of the study
The aim of the study was to determine the predictive value of extracellular vesicles concentration for MACCE after TAVI.

Material and methods
This was a multicentre, prospective clinical study. Venous blood was collected 1 day before TAVI and at hospital discharge (n=57, mean age 79.9+6.4 years, 49% male). Flow cytometry (Apogee A60-Micro) was used to determine concentrations of plasma EVs labelled with markers for endothelial cells (CD146), leukocytes (CD45), platelets and megakaryocytes (CD61) and activated platelets (CD62p). Analysis of flow cytometry data files was fully automated. Rosetta Calibration (Exometry) and Flow-SR were used for diameter and refractive index determination. Wilcoxon signed rank test was used to compare EV concentrations before and after TAVI. The predictive value of EVs for MACCE and the cut-offs were calculated using a receiver operating characteristic curve. Logistic regression model incorporating EV concentrations and clinical characteristics was used to determine the best model for MACCE prediction.

Results
Concentrations of EVs from activated platelets increased, whereas from leukocytes decreased after TAVI, compared to the measurement before (p=0.06, p=0.04, respectively). Among 55 patients discharged from the hospital, 14 patients experienced MACCE (25%) during the median 15 months of observation. Increased baseline concentration of leukocyte EVs and male gender were the only independent predictors of MACCE in multivariable analysis (OR 4.01, 95% CI 0.77 - 23.77, p=0.04 for leukocyte EVs; OR 6.84, 95% CI 1.41 - 33.17, p=0.03 for male gender).

Conclusions
We identified increased concentrations of leukocyte EVs as new candidate biomarkers to predict MACCE after TAVI. Leukocyte EVs could be used to augment risk stratification in this patient cohort. The next step is to validate the clinical applicability of EVs to predict post-TAVI MACCE in a large-scale clinical trial.

[1499] Prostacyclin analogues decrease platelet aggregation but have no effect on thrombin generation, fibrin clot structure, and fibrinolysis in pulmonary arterial hypertension

Authors: Miłosz Starczyński 1, Aleksander Siniarski 2, Aleksandra Gąsecka 1, Marcin Kurzyna, Krzysztof J.Filipiak, Jadwiga Nessler 2, Grzegorz Gajos 2
Affiliation:1 1st Chair and Department of Cardiology, Medical University of Warsaw, Warsaw, Poland; 2 Department of Coronary Artery Disease and Heart Failure, Institute of Cardiology, Jagiellonian University Medical College, John Paul II Hospital, Kraków, Poland
Trustee of the paper: Aleksandra Gąsecka

Corresponding author: Miłosz Starczyński (szepelska@gmail.com

Introduction
Prostacyclin (PGI2) analogues are the cornerstone of pulmonary arterial hypertension (PAH) treatment. PGI2 analogues inhibit platelet reactivity, but their impact on coagulation and fibrinolysis parameters has not been elucidated.

Aim of the study
We aimed to compare platelet reactivity between the group of patients receiving PGI2 analogues and the group of patients not treated with PGI2 analogues. Secondly, we aimed to compare coagulation and fibrinolysis parameters between the two groups of patients.

Material and methods
We compared platelet reactivity, coagulation and fibrinolysis parameters in patients with PAH treated with PGI2 analogues (epoprostenol, treprostonil, iloprost) (n = 20) and those not receiving PGI2 analogues (n = 20). Patients were eligible for enrollment if they: (I) were diagnosed with PAH according to the guidelines of the European Society of Cardiology and European Respiratory Society, (II) were treated with PGI2 analogues on top of other drugs (endothelin receptor antagonists (ERA), phosphodiesterase 5 inhibitors (PDE-5i) and/or calcium channel blockers (CCB); PGI2 (+) group) or were only treated with ERA, PDE-5i and/or CCB (PGI2 (-) group) for at least 1 month, and (III) provided written informed consent. Platelet reactivity was evaluated by multielectrode aggregometry using the following platelet activation agonists: arachidonic acid (AA), adenosine diphosphate (ADP), and thrombin receptor activating peptide-6 (TRAP). Coagulation and fibrinolysis parameters included plasma fibrin clot permeability, clot lysis time, and thrombin generation.

Results
Platelet reactivity was lower in patients treated with PGI2 analogues, compared to the control group, as evaluated with AA, ADP, TRAP tests ($p= 0.009$, $p = 0.02$, $p = 0.007$, respectively). In the subgroup analysis, both treprostinil and epoprostenol decreased platelet reactivity to the similar extent. There were no differences regarding thrombin generation, clot permeation and lysis parameters in patients receiving and not receiving PGI2 analogues ($p \geq 0.60$ for all). In the subgroup analysis, there were no differences regarding coagulation and fibrinolysis parameters between treprostinil, epoprostenol, and no PGI2 analogues.

Conclusions
We showed that patients with PAH treated with PGI2 analogues have reduced platelet reactivity, but similar thrombin generation, fibrin clot permeation, and lysis parameters, compared to patients not

receiving PGI2 analogues. Epoprostenol and treprostinil seem to reduce platelet reactivity to a similar extent.

Dermatology

Date: 7th May 2022, 12:30 PM

Coordinator:
Carolyn Szwed

[1141] Autoimmune bullous skin disorders - retrospective cohort study

Authors: Adrianna Pyrek, Laura Eliszewska, Natalia Rutecka, dr hab. n. med. Agnieszka Owczarczyk-Saczonek, prof. dr hab. n. med. Waldemar Placek
Affiliation: Department and Clinic of Dermatology, Sexually Transmitted Diseases and Clinical Immunology, University of Warmia and Mazury in Olsztyn
Trustee of the paper: prof. dr hab. n. med. Waldemar Placek, dr hab. n. med. Agnieszka Owczarczyk-Saczonek

Corresponding author: Adrianna Pyrek (adrianna273@gmail.com)

Introduction
Autoimmune bullous disorders is a group of chronic diseases. Bullous pemphigoid is the most common autoimmune bullous disease of all, affecting mainly elderly people in the 8th decade of life, without gender predilection. Pemphigus manifests usually between 45 and 65 years of age, with a female predilection reported in most epidemiological studies.

Aim of the study
Assessing the prevalence of bullous diseases with respect to their types in different age groups, coexistence with neoplasms and other diseases.

Materials and methods
Retrospective analysis of medical histories of patients hospitalized in the Department of Dermatology, Sexually Transmitted Diseases, and Clinical Immunology at the University of Warmia and Mazury in Olsztyn with a diagnosis of bullous diseases between 2015 and 2021.

Results
72 patients diagnosed with autoimmune bullous diseases were treated in the Department of Dermatology from 2015 to 2021. The mean age of patients was 76 years for pemphigoid diseases and 58 years for pemphigus. A causative agent such as drugs or consumption of bulbous plants was suspected in 10 patients (13.9%). Coexisting neoplasms were present in 12 patients (16.7%). In the case of one patient, the first symptoms of pemphigoid (L12.0) appeared along with the diagnosis of liver cancer. With the end of the oncological treatment, the treatment of pemphigoid was discontinued, because there was a resolution of the skin lesions. In the remaining cases, no similar correlation was observed between the treatment of cancer and the severity of autoimmune symptoms of bullous diseases. The subjects also had comorbidities, the most common of which was hypertension (23 patients).).

Conclusions
The study confirmed most of the epidemiological data: bullous pemphigoid mainly affects the elderly, in the 8th decade of life, while pemphigus usually manifests itself before the age of 65. Symptoms can be provoked by external factors such as drugs, pathogens, UV light, diet, and stress. They can also coexist with other autoimmune and cardiovascular diseases.

[1395] Comparison of surgical approach in Rhinophyma

Authors: Joanna Górak, Tymoteusz Kulbikowski, Ewa Maria Sokolewicz
Affiliation: Medical university of Gdańsk/ Student Scientific Circle of Practical and Experimental Dermatology by the Clinic of Dermatology, Venerology and Allergology
Trustee of the paper: Dr Monika Sikorska

Corresponding author: Joanna Górak (asia.gorak3@gmail.com)

Introduction

Rhinophyma is a disfiguring nasal deformity. It is characterized by telangiectasias, sebaceous hyperplasia, and erythematous hypertrophied skin of the nose. It occurs due to a proliferation of sebaceous glands and underlying connective tissue.
Acne rosacea is considered a precursor condition to later development of rhinophyma. Rhinophyma is most commonly found in white men over the age of 50 with a male to female ratio of 5 to 1 up to 30 to 1. Risk factors include advanced age, male gender, blood vessel disorders, androgenic influences and digestive tract disorders. The respiratory as well as psychological consequences of the disorder make it essential to treat. Various treatment methods include CO2 laser, electroresection, surgical procedures as well as intensive pulse light and lasertherapy. However, CO2 laser is still considered gold standard.

Aim of the study

Determination of various clinical outcomes

Materials and methods

In a cross-sectional study we analyzed patients admitted in the course of the year 2021 to the dermatology ward of Medical University of Gdańsk for treatment or follow up of rhinophyma. The research group consisted of five male patients in the mean age of 66 years.
Patient interview, past medical history, treatment and its outcomes were studied.

Results

Out of five patients, three were treated with electroresection and two with lasers. While one patient was treated solely with CO2 laser, the therapy of the second based on both, CO2 and Nd-YAG laser. The effectiveness of electroresection yields promising effects and is proof that this method can be considered an equally good, if not better treatment method of rhinophyma, comparing to CO2 laser.

Conclusions

1. The results of electroresection of rhinophyma are as good as those of CO2 laser
2. Positive treatment results are crucial, since patients suffer from both respiratory and psychological consequences of rhinophyma
3. Rhinophyma is a chronic and recurring dermatological disorder, hence regular and complex dermatological treatment is crucial in this set of patients

[1430] ATTITUDE AND KNOWLEDGE ABOUT ORAL ISOTRETINOIN AMONG ACNE VULGARIS PATIENTS

Authors: Anete Erta
Affiliation: Rīga Stradiņš University, Department of Dermatology and Venereology
Trustee of the paper: Aleksejs Zavorins, MD (Rīga Stradiņš University, Department of Dermatology and Venereology)

Corresponding author: Anete Erta (anete.erta@gmail.com)

Introduction
Acne vulgaris is one of the most common dermatological conditions, requiring long-term management, and has substantial negative impact on patients' quality of life. Oral isotretinoin is an effective method counteracting all pathogenic factors in acne. Use of isotretinoin is relatively long-term and associated with multiple adverse effects which may reduce the compliance.

Aim of the study
The objective of this study was to compare and evaluate knowledge, personal experience and attitude towards oral isotretinoin among acne patients.

Materials and methods
A cross-sectional study was performed in dermatology out-patient clinic among 46 acne patients. Patients were compared in two groups: patients receiving oral isotretinoin (isotretinoin group, N=27) and patients not receiving it (non-isotretinoin group, N=19). An anonymous survey was distributed among patients. Statistical analysis was performed using Chi-square test. P value < 0.05 was considered statistically significant.

Results
61% of patients were female and 39% male, mean age 23 years. 81% of the patients in isotretinoin group believe that isotretinoin is the most effective acne treatment method compared to 42 % in non-isotretinoin group, p=0.006. 81% of patients in isotretinoin group evaluate their experience with isotretinoin as successful while majority of patients in non-isotretinoin group (53%) evaluate their acne treatment as unsuccessful, p=0.00007. Regarding adverse-effects isotretinoin group demonstrated most concerns towards skin dryness and liver damage (44%), while non-isotretinoin group towards eye (47%) and liver damage (42%). Isotretinoin group demonstrated better level of knowledge answering 66% correctly and 34% incorrectly or with "I don't know" to the questions regarding isotretinoin treatment basic principles compared to non-isotretinoin group with 56% correct answers, p=0.004. In both groups main source of information regarding isotretinoin was reported to be the treating physician (85% in isotretinoin group, 74% in non-isotretinoin group).

Conclusions
Patients treated with isotretinoin reported more successful experience with acne treatment and demonstrated better level of knowledge regarding isotretinoin treatment compared to acne patients not receiving it. In both groups majority of patients didn't demonstrate high-degree of concerns regarding adverse effects associated with isotretinoin. With good patient counselling and education isotretinoin is safe and most effective acne treatment option in case of severe acne.

[1492] Toxic epidermal necrolysis - a retrospective study of cases of years 2011-2020 in Department of Dermatology, Medical University of Warsaw

Authors: Jędrzej Niessner, Wiktoria Rutkowska
Affiliation: Medical University of Warsaw/Department of Dermatology
Trustee of the paper: dr hab. Joanna Czuwara

Corresponding author: Jędrzej Niessner (jedrzej.niessner@gmail.com)

Introduction
Toxic epidermal necrolysis (TEN) is a rare, severe mucocutaneous reaction with a high mortality rate. The pathogenesis is still unclear, however various drugs are reported to induce epithelial reactions. Involvement of the ocular and genital epithelium is associated with serious complications if the condition is not treated properly. There is any specified recommended treatment, but various systemic therapies are used including immunoglobulin G and cyclosporin A administration.

Aim of the study
We would like to evaluate the clinical manifestation and treatment of TEN in the Department of Dermatology, Medical University of Warsaw.

Materials and methods
Case histories of 15 patients diagnosed with TEN in the past 10 years were collected and the major symptoms, causing factor, coexisting diseases and treatment were assessed.

Results
Analyzed group included 11 women and 4 men (mean - 51.5y.o. from 19 to 85y.o.). Four of them (26,6%) reacted to an antibiotic, three of patients (20%) after pain reliever medication, three (20%) after lamotrigine, one (6,6%) after allopurinol and in four (26,6%) patients the reason for TEN is unclear. Lesions started occurring usually after 2 weeks from taking triggering medication (from 2 days to 3 weeks). Nine patients (60%) required to be hospitalized in the Intensive Care Unit.

Conclusions
With our study, we are required to point out that TEN can occur in many disciplinaries and often requires treatment in high-specialized centres. Accurate and fast diagnosis can increase patients' chances to recover and minimize sequelae.

[1226] Necrobiotic xanthogranuloma – symptom or disease?

Authors: Piotr Nawrot, Paulina Głowacka, Joanna Czuwara
Affiliation: Department of Dermatology, Medical University in Warsaw
Trustee of the paper: Dr hab. n. med. Joanna Czuwara

Corresponding author: Piotr Nawrot (piotrnawrot@onet.com.pl)

Background

Necrobiotic xanthogranuloma (NXG) is an indolent non–Langerhans cell histiocytosis strongly associated with a monoclonal gammopathy. It is characterized by slowly progressive granulomas within the subcutaneous and dermal layers with focal areas of collagen degeneration. NXG presents clinically as yellowish to red-orange or violaceous plaques, nodules, or papules that may ulcerate. Preferable location of NXG is around the eyes and with disease progression it can lead to disfigurement. This disease may involve extracutaneous sites such as heart or respiratory tract with documented cases of pulmonary and myocardial giant cell granulomas. There is no definitive first-line therapy for NXG due to its rarity and uncertain etiology.

Case Report

We present a 65-yo patient with an IgG isotype of the monoclonal gammopathy with coalescent infiltrated papules, plaques and nodules localized at her periorbital area expanding to the ears and her chest. The biopsy was taken for NXG confirmation and revealed extensive palisading histiocytic xanthogranulomas with bizarre giant multinucleated cells devouring collagenous stroma leading to necrobiosis with cholesterol clefts formation in the middle dermis. The patient started to be treated with intravenous immunoglobulins (IVIG) with good tolerance and response. Regression of disfiguring skin lesions with noticeable post-inflammatory discolorations was achieved.

Conclusions

The pathogenesis of NXG is unclear. NXG may represents a granulomatous response to cutaneous deposition of Ig complexed with lipids, may result from monocytic cell lineage activation by accelerated complement reaction or impaired macrophage lipid homeostasis. Majority of patients have an associated monoclonal gammopathy, and the most common is IgG monoclonality as in our case. Management of patients with necrobiotic xanthogranuloma is a therapeutic challenge due to lack of consensus guidelines and limited data on therapeutic options. There are encouraging results with intravenous immunoglobulin in cases with monoclonality, autologous stem cell transplantation in underling hematologic disorder, oral lenalidomide, alkylating agents such as chlorambucil or melphalan in combination with prednisolone or pulsed dexamethasone. Consequently, treatment proves difficulties due to undetermined or complexed NXG cause, patients tolerability and low therapeutic efficacy with no recommended first-line therapy in this rare disease.

[1462] The promising outcomes of wedge lip resection - a case series.

Authors: Julia Sternicka, Michał Kacprzak, Ewa Maria Sokolewicz
Affiliation: Department of Dermatology, Venereology and Allergology, University Hospital Center, Medical University of Gdańsk
Trustee of the paper: Dr Andriy Petranyuk

Corresponding author: Julia Sternicka (julia.sternicka@gumed.edu.pl)

Background

Lips provide multiple functions, ranging from swallowing, and speech to social interactions such as expressing emotions. They encircle oral orifice and contain vermilion, mucosal membrane and cutaneous surfaces. Anatomically, the lips are made up of orbicularis oris m., incisivus superior m. and incisivus inferior m.

Pathological changes that occur on the lips include cutaneous horn, keratoacanthoma, lichen planus, nodular fibrous hyperplasia, squamous cell papilloma, mucocele, squamous cell carcinoma (SCC), actinic keratosis, which is considered an intraepitelial form of the SCC, basal cell carcinoma (BCC) as well as melanoma. While BCC develops more commonly on the upper lip, SCC is a pathology associated mainly with the lower lip. Currently, lip lesions can be treated in a variety of ways, including pharmacological, radiotherapeutic and surgical methods. Surgical management includes vermilionectomy and mucosal advancement, wedge excision and primary closure, wedge excision and Abbe-Estlander reconstruction, wedge excision and cheek flap reconstruction, excision and naso-labial flap reconstruction.

Case Report

We present a case series of three patients, who underwent a wedge resection of the lip at the Dermatology, Venereology and Allergology Clinic of the University Hospital Center of Medical University of Gdansk..

Conclusions

Wedge resection of the lip, carried out on patients of the Dermatology, Venereology and Allergology Clinic of the University Hospital Center of Medical University of Gdańsk, provided highly satisfactory clinical outcomes, taking into account the blood supply, innervation and post-excisional cosmetic effect of the lip reconstruction.

[1493] Toxic epidermal necrolysis related to ketoprofen

Authors: Jędrzej Niessner
Affiliation: Medical University of Warsaw/Department of Dermatology
Trustee of the paper: dr hab. Joanna Czuwara, lek.Magdalena Jasińska

Corresponding author: Jędrzej Niessner (jedrzej.niessner@gmail.com)

Background
Toxic epidermal necrolysis (TEN) is a rare, severe mucocutaneous reaction with a mortality rate of 30%, characterized by erythema, necrosis and bullous detachment of the epidermis and mucosal membranes. Various drugs are reported to induce epithelial reactions, including antibiotics, nonsteroidal anti-inflammatory drugs. The involvement of mucosae, ocular and genital epithelium is associated with serious complications. There is no specified recommended treatment, but various systemic therapies are used, including immunoglobulin G and cyclosporin A. The role of systemic steroids is controversial.

Case Report
On admission, a 19-year-old female patient presented symptoms of extensive oedemic-erythematous skin lesions all over the body (BSA 13,5%), involving several atypical targetoid lesions. Within three days before admission, oral mucosa involvement with blistering of the lips and erosions was observed. Detailed history suggested the intake of ketoprofen due to menstrual cramps two weeks before. Based on the clinical picture, TEN was diagnosed. TEN-dedicated SCORTEN score, developed to predict the prognosis on the day of admission, was obtained as 1/7 with a predicted mortality of 3.2%. For the next 2 days after admission, a progression of skin lesions up to 98% BSA was observed, including extensive epidermal exfoliation, blisters and erosions involving up to 55% BSA. Due to the deteriorating condition, the patient was transferred to ICU. Treatment consisted of fluid infusions, oral and intramuscular steroids, cyclosporine, IVIG, antibiotics, plasmapheresis, pain medication, anticoagulants, oxygen therapy, topical treatment including disinfectants and daily dressings. After 16 days in ICU, the patient was transferred back to the Dermatology Unit and discharged after 22 days of hospitalisation. The patient was regularly consulted by an ophthalmologist. Cornea and conjunctivae erosions were managed with extensive lubrication of the eyes, antibiotics, and management of synechiae between the eyelids and conjunctiva.

Conclusions
TEN is a life-threatening skin and mucous membranes disorder with an incidence estimated between 0.4 and 1.2 cases per million each year. The aetiopathogenesis remains unknown, however specific HLA types and drug hypersensitivity are reported to be correlated. More than 50% of patients surviving TEN suffer from long-term sequelae. NSAIDs are widely considered to carry the risk of inducing TEN. Among them, however, ketoprofen is reported rarely.

Endocrinology & Diabetes

Date: 7th May 2022, 12:30 PM

Coordinators:
Michał Zygarowicz
Andrea Marianna Wirth

Patronage:

Konsultant Krajowy w dziedzinie Diabetologii

Prof. dr hab. Krzysztof Strojek

Konsultant Krajowy w dziedzinie Endokrynologii i diabetologii dziecięcej

Prof. dr hab. Mieczysław Walczak

[1386] IS INSULIN RESISTANCE A RISK FACTOR OF ATHEROSCLEROSIS?

Authors: Małgorzata Landowska, Emilia Babula, Aleksandra Kargul, Karolina Garbas, Natalia Pacocha

Affiliation: Medical University of Warsaw/ Department of Endocrinology and Diabetology of the Central Clinical Hospital of the Ministry of Interior and Administration in Warsaw
Trustee of the paper: Bernadetta Kałuża MD PhD; Prof. Edward Franek MD PhD, Head of the Department of Endocrinology and Diabetology of the Central Clinical Hospital of the Ministry of Interior and Administration in Warsaw

Corresponding author: Małgorzata Landowska (malgorzata.landowska97@wp.pl)

Introduction
Rising evidence seem to support the view that insulin resistance may be one of the factors involved in the atherogenesis.

Aim of the study
The present paper aims to investigate whether insulin resistance can be considered as one of the atherosclerotic risk factors.

Materials and methods
In order to conduct our study we analysed the medical history of patients hospitalised between 2014 and 2017 in the Central Clinical Hospital of the Ministry of Interior and Administration in Warsaw. 79 subjects (N=79) agreed to participate in the prospective part of the research. The following procedures were performed during the course of our study: obtaining the blood samples, measuring the ankle brachial index (ABI), measuring the waist circumference and assessing the carotid intima media complex thickness (IMT). The study cohort was then divided into two groups according to value of the homeostasis model assessment of insulin resistance (HOMA-IR) index: group 1 (n=59) with the index value lower than 2,5 and group 2 (n=20) with the index value more or equal to 2,5.

Results
Regardless of the phase of the study, the values of Castelli's risk index I (CRI-I), Castelli's risk index II (CRI-II) and atherogenic coefficient (AC) were significantly higher in patients from the group 2 (2014-2017: CRI-I: 3,11±1,05 vs. 4,25±1,5, p=0,0009; CRI-II: 1,7±0,8 vs. 2,52±1,03 p=0,002; AC: 2,11±1,05 vs. 3,25±1,5, p=0,001)(2021: CRI-I: 3,2±1,02 vs. 3,99±1,75, p=0,04, CRI-II: 1,75±0,76 vs. 2,23±0,9, p=0,03, AC: 2,17±1,02 vs. 2,99±1,74, p=0,04). Fasting insulin concentration was significantly higher in the second group, while cholesterol HDL concentration was higher in the first group. In the multivariate logistic regression we showed that body mass index (BMI) can be regarded as an independent risk factor of increased carotid IMT, while HOMA-IR can be considered as an independent risk factor of ABI<0,9. Using the multivariate Cox regression analysis we were able to prove that over our observation period HOMA-IR was significantly associated with carotid IMT>1mm and ABI<0,9.

Conclusions
Elevated BMI can be considered as an independent risk factor of subclinical atherosclerosis defined by carotid IMT higher than 1mm. HOMA-IR is positively associated with low value of ABI and can be accounted as an independent risk factor of peripheral atherosclerosis.

[1387] IS FRAX CALCULATOR SUITABLE FOR DIABETIC PATIENTS?

Authors: Małgorzata Landowska, Emilia Babula, Aleksandra Żuk, Kinga Woźniak, Izabela Agnieszczak
Affiliation: Medical University of Warsaw
Trustee of the paper: Bernadetta Kałuża MD PhD, Prof. Edward Franek MD PhD

Corresponding author: Małgorzata Landowska (malgorzata.landowska97@wp.pl)

Introduction
FRAX® is a computer - based algorithm which evaluates patient's 10-year probability of a fracture, mainly a hip or a major osteoporotic ones and takes into the following variables: body mass index, bone mineral density, history of a fracture, usage of oral glucocorticoids. Up to this date the utility of FRAX® has not been evaluated in the polish patients suffering from diabetes mellitus type 2.

Aim of the study
The aim of this study is to assess the suitability of FRAX® in patients with diabetes mellitus type 2.

Materials and methods
In order to conduct the study we recruited 35 patients (N=35), who during the hospitalisation in 2010-2011, in the Central Clinical Hospital of the Ministry and Administration in Warsaw were diagnosed with diabetes mellitus type 2. Study participants underwent clinical and biochemical assessment. The bone mineral density of the lumbar spine and femoral neck was assessed using bone densitometry. The study cohort was later divided into two subsets: group 1: (n=23) patients with diabetes mellitus type 2 who during 10-year observation did not develop osteoporosis or experience any fracture and group 2: (n=12) subjects with diabetes mellitus type 2 who during 10-year follow-up period were diagnosed with osteoporosis and/or experienced a fracture.

Results
The analysed groups were significantly different in terms of major-osteoporotic FRAX® (group 1: 2,2±0,9; group 2: 3,9±1,5, p=0,00066) and hip fracture FRAX® (group 1:0,2±0,2; group 2: 0,6±0,4, p=0,01). ROC curves revealed that FRAX® can be considered as a valuable diagnostic tool in terms of fracture and osteoporosis prediction in patients with diabetes mellitus type 2.

Conclusions
Calculator FRAX® seem to be a suitable diagnostic tool for fracture and osteoporosis prediction in patients with diabetes mellitus type 2.

[1500] Analysis of the ultrasound image of thyroid nodules in different types of thyroid neoplasms

Authors: Magdalena Radziszewska, Aleksandra Idzik
Affiliation:Students' Scientific Society ThyroIdea of the Department of Oncological Endocrinology and Nuclear Medicine of Maria Sklodowska-Curie National Research Institute of Oncology in Warsaw
Trustee of the paper: Agnieszka Żyłka MD, PhD

Corresponding author: Magdalena Radziszewska (magda.17@o2.pl)

Introduction
Thyroid cancer is the most common endocrine malignancy. In ultrasound assessment(USG) of thyroid nodules the TIRADS scale(based on most significant features of malignancy) is commonly used. Thyroid cancers include Papillary Thyroid Cancer(PTC), Follicular Thyroid Cancer(FTC), Medullary and Anaplastic cancers. Nodules can also contain a benign tumor–a thyroid adenoma.

Aim of the study
The aim of the study was to evaluate the USG features of neoplastic thyroid nodules, analyze them with respect to their histopathological type and asses applicability of EU-TIRADS scale.

Materials and methods
Our study took into account 188 patients with suspected/confirmed thyroid malignancy. Each patient underwent thyroid USG, in which suspicious nodules were described, and then thyroidectomy. Histopathological results confirmed the type of tumor in each patient. Hence descriptions of neoplastic nodules(one of most distinctive nature per patient) of confirmed type were analyzed.

Results
In PTC, most of the 130 patients had hypoechoic(86.1%) and solid(93.1%) nodules that varied in shape.34% had microcalcifications.51.5% had peripheral vascularity pattern. Only in 7.7% suspicious pathological lymph nodes were seen.91.5% of nodules scored 5 in TIRADS.
In FTC, most nodules in 24 patients were hypoechoic(83.3%) and solid(79.2%) of mostly round(58.3%) shape.41.7% of nodules had a peripheral halo of decreased echogenicity and 16.7% had microcalcifications.54.1% had peripheral vascularity pattern and 29.2% presented capsular bulging. 79.2% of nodules scored 5 in TIRADS.
Medullary cancers(8 patients) were mostly hypoechoic and solid, with variety of shapes.50% of them had halo effect and microcalcifications.62.5% presented intranodular vascularity pattern. All nodules scored 5 in TIRADS scale.
95.5% of adenomas had oval shape and 63.6% presented a halo sign. Only 4% contained microcalcifications. TIRADS scores were heterogenous.

Conclusions
Most of neoplastic nodules were described as hypoechoic and solid. Many presented alarming features like peripheral halo or microcalcifications. Except for medullary cancer, other neoplasms had peripheral vascularity pattern, which can be wrongly interpreted as a calming sign during estimation of potential malignancy. The assessment of traits included in TIRADS scale is crucial to the diagnosis of thyroid neoplasms, as it allows to correctly predict the character of suspicious nodule.

[1153] Cervical lymphadenopathy as the initial diagnosis in patient with subacute thyroiditis

Authors: Agata Król
Affiliation: Department of Oncological Endocrinology and Nuclear Medicine, Maria Sklodowska-Curie National Research Institute of Oncology
Trustee of the paper: Agnieszka Żyłka MD, PhD

Corresponding author: Agata Król (agatakrol517@gmail.com)

Background
Subacute thyroiditis (SAT) is an inflammatory thyroid condition following a viral infection. Nowadays, there are increasingly more reports linking SAT to SARS-CoV-2. SAT has a distinctive triphasic clinical course: hyperthyroidism, hypothyroidism and a return to normal thyroid function. The most common symptoms are neck pain and cervical tenderness. During the first weeks, signs of thyrotoxicosis may occur. In some patients, no treatment is required – the disease is often self-limited.

Case Report
A 59-year-old man presented to primary care with anterior neck pain, tenderness and a palpable mass. He had had a history of upper respiratory infection with symptoms similar to COVID-19 a month ago, but he had not been tested then. Ultrasound revealed cervical lymphadenopathy. A neoplasm of unknown type, possibly lymphoma, was suspected.The patient was referred to the National Institute of Oncology in Warsaw, where a fine needle aspiration (FNA) of cervical lymph nodes was unsuccessfully attempted. No lesions were found in the sample; however, the thyroid gland looked abnormal. CT of the neck showed an asymmetry in the oropharynx with enlarged lateral wall thickness and hypodense infiltrations in both lobes of the thyroid. Thyroid ultrasound showed extended heterogeneous hypoechoic gland. FNA revealed an infiltration composed mostly of lymphocytes, described as Bethesda category III because of atypical image of likely neoplastic or reactive atypia. Blood test results suggested subclinical hyperthyroidism indicative of SAT. In the following weeks the patient developed hypothyroidism treated with levothyroxin. The patient continued to receive endocrinolocial care with a prognosis of complete recovery.

Conclusions
SAT ought to be considered in differential diagnosis in patients who present with unspecified cervical lesions and who have had recent history of an upper respiratory infection, including COVID-19. Ultrasound is the gold standard for diagnosing changes in thyroid gland

[1292] A 65-year old patient presenting with back pain as the only manifestation of otherwise asymptomatic metastatic Hurthle cell carcinoma.

Authors: Weronika Karwowska
Affiliation: Student's Scientific Society "ThyroIdea" of Department of Oncological Endocrinology and Nuclear Medicine, Maria Sklodowska-Curie National Research Institute of Oncology
Trustee of the paper: Agnieszka Żyłka MD, PhD

Corresponding author: Weronika Karwowska (wera.karwowska@gmail.com)

Background
Hurthle cell carcinoma is a relatively rare variant of thyroid cancer. It consists of more than 75% oncocytic tumor cells and is considered to be more aggressive than follicular thyroid cancer (FTC), from which it derives. The most common metastases are to the lungs, bones and the brain. There are no known exogenous risk factors for developing specifically this variant of FTC.

Case Report
In 2020, a 65-year old female patient presented with a back pain in the upper lumbar and sacral bone area that lasted for 6 months. A MRI revealed a pathologic fracture with a bulging of L1 vertebra into the vertebral canal which resulted in neuralgia. The lesions were suspected to be of neoplastic origin. The patient had undergone an additional MRI of thoracic vertebrae, which revealed a pathological lesion of Th2 and an enlargement of the thyroid. An ultrasonographic examination of the neck confirmed a suspicion of a thyroid tumor. A subsequent fine-needle aspiration biopsy of L1 vertebra was carried out that resulted in suspicion of FTC. The patient underwent thyroidectomy and lymphadenectomy of the surrounding area. The histopathological results confirmed a 45 mm Hurthle cell carcinoma (pT3Nb1) in the right thyroid lobe with multiple satellite tumors and vascular invasion, without capsular invasion. The tumor had spread to three lymphatic nodes ranging 5-20 mm in size. As the prior biopsy of L1 had revealed the lesion to be metastatic, the patient underwent intensity-modulated radiotherapy (IMRT) for Th12-L1 region and subsequently 131-I therapy following the thyroidectomy. The neck area and the upper mediastinum showed radioiodine uptake in scintigraphy. After a repeated 131-I therapy, the second scintigraphy did not reveal radioiodine uptake in the bones, leading to introducing sorafenib treatment. It was later replaced by lenvatinib as a result of continued disease progression observed in bone metastases. The secondary tumors were also being treated through IMRT in separate sessions. Currently, the patient is stable and reports good tolerance to lenvatinib.

Conclusions
Symptoms such as back pain might be indicative of bone metastases of an otherwise asymptomatic tumor of thyroid such as Hurthle cell carcinoma. The lesions can partially obstruct the spinal canal causing pain. The carcinoma is in all cases treated by radiotherapy. In case of its inefficiency, antineoplastic agents such as sorafenib or lenvatinib are introduced.

[1428] Treatment of melanoma with immune checkpoint inhibitors as a rare cause of hypophysitis, adrenal insufficiency and hypothyroidism – a case report

Authors: Paulina Filipowicz
Affiliation: Medical University of Warsaw, Department of Oncological Endocrinology and Nuclear Medicine, Maria Sklodowska-Curie National Research Institute of Oncology, Warsaw
Trustee of the paper: Agnieszka Żyłka MD, PhD

Corresponding author: Paulina Filipowicz (paulinafilipowicz7@gmail.com)

Background
The development of immune checkpoint inhibitors, including pembrolizumab – a humanized, anti-programmed death receptor 1 (anti-PD-1) monoclonal antibody - was a breakthrough in melanoma treatment. Despite the high efficacy, associated adverse events may cause therapy discontinuation.

Case Report
A 47-year-old man presented to the Maria Sklodowska-Curie National Research Institute of Oncology in Warsaw with evolving and bleeding pigmentary lesion on the left arm. Pathological examination revealed nodular melanoma of size 35x30 mm with Breslow infiltration thickness of 5.5 mm and ulceration (pT4b). The patient underwent sentinel node biopsy, wide radical excision of the scar and a CT scan. Owing to the final diagnosis of high-risk, stage IIC disease, the patient was enrolled in the randomized clinical trial with pembrolizumab and received 7 courses administered every 3 weeks. The therapy was discontinued due to adverse events. After the last course, the patient was admitted to the hospital with nonspecific symptoms – nausea and vertigo, vomiting after meals, jaundice, nystagmus, deterioration of visual acuity, brachybasic gait and tremor. Imaging studies ruled out the presence of metastases to the central nervous system, although showed an unspecified focal lesion in the hypophysis without organ enlargement. In addition, hyponatremia, low cortisol, and ACTH levels led to the diagnosis of hypophysitis and, consequently, secondary adrenal insufficiency. Moreover, the asymptomatic hyperthyroidism was detected after the first course. However, the consecutive laboratory tests demonstrated the development of hypothyroidism. The persisting endocrinopathies require hydrocortisone and levothyroxine substitution with personalized doses. In January 2022, the patient was hospitalized due to impaired consciousness during COVID-19. Concomitant infection and diarrhea led to hyponatremia (123 mmol/L) – a premise of adrenal crisis.

Conclusions
Despite the development of drugs with a better safety profile, treatment with immune checkpoint inhibitors constitutes a rare cause of endocrinopathies. The presented case demonstrates the diagnostic and therapeutic challenges in immune-related adverse events (irAEs). Cooperation of the interdisciplinary team is necessary to prevent the disease progression and potentially life-threatening complications of therapy. However, the presence of endocrine irAEs may be associated with better outcomes in patients with melanoma.

[1442] Treatment-resistant paraganglioma of the retroperitoneal space

Authors: Weronika Kowalczyk
Affiliation: Medical University of Warsaw/ Department of Oncological Endocrinology and Nuclear Medicine, Maria Sklodowska-Curie National Research Insititute of Ocology
Trustee of the paper: Agnieszka Żyłka MD, PhD

Corresponding author: Weronika Kowalczyk (wk.weronikakowalczyk@gmail.com)

Background
Paraganglioma is a rare neuroendocrine tumor with the ability to secrete neuropeptides and catecholamines. The most common clinical presentation is hypertension and sympathetic nervous system overactivity. We reported a case of paraganglioma originating from retroperitoneum, which is resistant to standard treatment.

Case Report
A 73-year-old male patient was admitted due to the detection of a tumor in the retroperitoneal space on ultrasound (US) examination on 04.2019. He complained of long-term constipation and suprapubic back pain without weight loss. His past medical history is significant for well-controlled hypertension, type 2 diabetes mellitus, paroxysmal atrial fibrillation and hyperlipidemia. His medication, social, and family history were otherwise unremarkable. Physical examination revealed a soft abdomen without palpable masses. Computed tomography (CT) of the abdomen revealed an 8x6x8cm solid heterogeneous tumor in the retroperitoneal space invading the aortocaval space. The tumor adhered closely to the vessels, local nodes were not enlarged. High scores of methoxy derivatives of catecholamines were found in plasma (normetanephrine - 7099pg/ml; the norm is to 200pg/ml) and urine. Histopathological examination confirmed a paraganglioma. Radiological studies have shown that the tumor is inoperable. Genetic testing revealed no relevant mutation. Whole-body scintigraphy and SPECT at 24, 48 and 72 hours reveal areas of high I-131MIBG-uptake in the tumor. On 11.2019 the patient was started on I-131MIBG treatment, after pharmacological preparation with doxazosin. He received 4 doses every 5 months. The follow-up US and scintigraphy after each treatment revealed that the tumor size remained unchanged, no metastases were found. In 05.2021 intensity-modulated radiation therapy (IMRT) was introduced for 6 weeks with a total dose of 4860cGy/T. A PET scan performed after this treatment showed no change in tumor mass. The patient is currently under observation and waiting for a follow-up CT scan. Oncologists plan to introduce chemotherapy in case of unsuccessful treatment.

Conclusions
Although this patient was symptomatic with scintigraphy I-MIBG-uptake, the tumor was resistant to treatment. This prompts the search for new therapeutic pathways and multidisciplinary approaches between an experienced endocrinologist, radiologist, genetics, pathologist, oncologist.

[1454] A case study of 78-year old patient with lung adenocarcinoma metastasizing to thyroid gland

Authors: Paulina Kalman
Affiliation: Student's Scientific Society „ThyroIdea" of Department of Oncological Endocrinology and Nuclear Medicine, Maria Sklodowska-Curie National Research Institute of Oncology
Trustee of the paper: Agnieszka Żyłka MD, PhD

Corresponding author: Paulina Kalman (paulina.kalman@wp.pl)

Background
Thyroid cancer is not a common disease, it occurs in about 4% of malignancies in women and 0. 5% in men. Primary tumours are the most common. Metastasis to the thyroid gland are unusual with a reported frequency of up to 2.1% among all thyroid malignancies.

Case Report
The case of a 78-year-old patient who had a nodular lesion in her right lung, revealed in a control radiography study in 2010. The computed tomography (CT) study showed a mass in the ½ upper segment of the right lung without enlarged regional lymph nodes and two nodules in the left adrenal gland, confirmed in dynamic CT test as metastases. On the basis of a histopathological examination an adenocarcinoma of the lung was diagnosed. The patient received three cycles of chemotherapy with Cisplatin 110 mg + Vepesid 500 mg which was discontinued due to pancytopenia and lack of regression. An upper right-sided bilobectomy was conducted and three months later left-sided adrenalectomy with splenectomy, removal of the tail of the pancreas. The primary diagnosis of lung adenocarcinoma ypT2aN1M1L1V1R0 was confirmed. In 2013, a focal change in the head of the pancreas was detected during follow-up. Positron emission tomography (PET-CT) showed increased fluorodeoxyglucose metabolism (FDG) in the area of the pancreas head. The patient was approved for Whipple surgery. Examination of the postoperative material revealed the lesion to be a metastasis of lung adenocarcinoma. During a follow-up examination in September 2021 the patient reported a change in the anterior neck area. An ultrasound was performed which showed an enlargement of both thyroid lobes and hypoechogenic solid lesions with the largest diameter of 22x25x31mm in the left lobe and 26x18x32mm in the right lobe. A fine-needle aspiration biopsy (FNAB) showed metastasis of lung cancer in the left thyroid lobe. The patient was classified for left-sided thyroidectomy. Histopathological examination of the postoperative material confirmed the metastases of lung adenocarcinoma Napsin A[+], TTF-1[+], CK19[+], Thyroid globulin (TGB) [+]. The resection margin showed the tumor tissue and the patient was qualified for further diagnosis and a total thyroidectomy.

Conclusions
This case reminds us that metastatic changes in the thyroid gland may occur several years after the initial diagnosis. In a patient with a known history of malignancies, the finding of a new thyroid mass should be promptly evaluated with a thyroid FNAB to search for metastatic disease.

[1471] A case study of primary hyperaldosteronism caused by adrenal adenoma- from diagnosis to treatment

Authors: Paweł Szajewski
Affiliation: Student's Scientific Society „ThyroIdea" of Department of Oncological Endocrinology and Nuclear Medicine, Maria Sklodowska-Curie National Research Institute of Oncology
Trustee of the paper: Agnieszka Żyłka MD, PhD

Corresponding author: Paweł Szajewski (pawelszajewski0@gmail.com)

Background
Primary hyperaldosteronism (PA) may cause high blood pressure in up to 10% patients. This disease requires different diagnostic and therapeutic measures than primary hypertension. Most patients do not present any characteristic symptoms. One of the causes of PA may be an aldosterone-producing adrenal cortex adenoma.

Case Report
The case presents a 47-year-old patient with a history of pain on the left side of the lumbar spine area. For this reason, an ultrasound examination of the abdominal cavity was carried out, during which a focal change in the lower pole of the left kidney was observed. In contrast computed tomography, a focal change of the left adrenal gland with a diameter of 9 mm with a density of 28 Hounsfield unit (HU) was revealed. It delayed in the arterial phase up to 140HU, portal vein 94HU, with a relative leaching rate of 52%, absolute –74% –with radiological characteristics of a pheochromocytoma. The patient had a history of regularly administered elevated blood pressure levels (up to 180/100mmHg). He also suffered from hypertension, type 2 diabetes, dyslipidaemia, obesity, iliosacral and lumbar spine osteoarthritis. The results of the hormone studies showed a normal circadian rate of cortisol release at 1mg dexamethasone with a cortisol level of 1. 18ug/dL. The results of plasma concentrations of the methoxycatecholamines in the normal range (normetanephrine 38. 69pg/ml, methanephrine 12. 92pg/ml, methoxytyramine undetectable). Laboratory results revealed aldosterone 227pg/ml, renin 7. 1pg/ml, aldosterone/renin ratio (ARR) 31. 97 and 2 hours after verticalization: aldosterone 643pg/ml and renin 18. 5pg/ml, ARR 34. 76. Due to a suspicion of PA, a saline infusion test was performed. Before salt infusion a following results were obtained: aldosterone level 255pg/ml, renin level 1. 2pg/ml, ARR 212. 5 and after infusion: aldosterone level 149pg/ml, renin level 1. 0pg/ml, ARR 149. Norcholesterol scintigraphy was planned to confirm the lateralization of the tracer uptake in the adrenal lesion, which showed that the lesion in the left adrenal gland is consistent with a mineralocorticoid secreting adenoma. A left-sided adrenalectomy was performed.

Conclusions
Initially, it was suspected that the patient's hypertension was due to his concomitant obesity and unhealthy lifestyle. However, this case underlines the importance of a multidirectional diagnostic process, which can lead to a correct diagnosis in patients with multiple non-specific symptoms.

[1501] Uncovering the true nature of an adrenal incidentaloma – a case report

Authors: Magdalena Radziszewska
Affiliation: Students' Scientific Society ThyroIdea of the Department of Oncological Endocrinology and Nuclear Medicine of Maria Sklodowska-Curie National Research Institute of Oncology in Warsaw
Trustee of the paper: Agnieszka Żyłka MD, PhD

Corresponding author: Magdalena Radziszewska (magda.17@o2.pl)

Background
Incidental adrenal masses fairly are common. Adrenocortical carcinoma(ACC) is an aggressive, but rare tumor originating in the adrenal cortex. In computed tomography(CT) image it often has a density above 10HU, which is used to distinguish it from benign adenoma. Schwannoma is a usually benign and slow-growing nerve sheath tumor.

Case Report
A 46-year old woman was reported to the Department of Oncological Endocrinology and Nuclear Medicine in July 2021 due to the accidentally found focal change(solid, 41x37mm) in the right adrenal gland in the ultrasound examination conducted elsewhere. The patient negated stomach pains, abnormal stools or palpitations and said she gained 5kg in weight recently. Despite absence of worrisome symptoms, further diagnostics were planned. Serum hormone levels were within normal limits. Chest x-ray was normal. Abdominal and pelvical CT scan confirmed focal change in the right adrenal gland(43x42mm). It was described as heterogeneous with hypodense areas. Mean density of the lesion was 26HU and after contrast administration - after 60s 56HU and after 15 minutes 71HU.This image was not typical for a benign adrenocortical adenoma, hence there was a suspicion of a malignant process. Other elements in this CT scan were unremarkable and there was no signs of possible metastases. Due to difficulties of establishing the possible nature of the focal change and risk of it being malignant, it was decided that right adrenalectomy would be the best course of action. The surgery took place in September 2021 and it went without complication. Month later, in October 2021, the histopathological results of removed right adrenal gland came. It was suspected that they could reveal a highly malignant adrenocortical carcinoma, however, to everyone's surprise, they revealed a benign tumor – schwannoma. Due to that, the patient required no additional treatment and, as of now, feels well and remains under observation in the Department's outpatient clinic.

Conclusions
It is important to carry out a proper diagnostics in patients with adrenal incidentalomas, because while most of them could be benign adenomas, some of them could be a very dangerous carcinomas requiring urgent and radical treatment. However, while searching for a diagnosis, it is also important to remember about the possibility of the change being of completely different type.

Infectious Diseases

Date: 7th May 2022, 8:30 AM

Coordinator:
Magda Skudzińska

Patronage:

Kolegium Medycyny Laboratoryjnej

[1137] Attitude Toward Receiving COVID-19 Booster Dose in the Middle East and North Africa (MENA) Region: a Cross-sectional study

Authors: Mohamed Abouzid1,2, Alhassan Ali Ahmed2,3, Elżbieta Kaczmarek3
Affiliation: 1- Department of Physical Pharmacy and Pharmacokinetics, Poznan University of Medical Sciences; 2- Doctoral School, Poznan University of Medical Sciences; 3-Department of Bioinformatics and Computational Biology, Poznan University of Medical Sciences
Trustee of the paper: Prof. dr hab. Elżbieta Kaczmarek

Corresponding author: Alhassan Ahmed (alhassan.pha@gmail.com)

Introduction
COVID-19 vaccines are crucial to control the pandemic and avoid COVID-19 severe infections. The rapid evolution of COVID-19 variants such as B.1.1.529 is alarming, especially with the gradual decrease of serum antibody levels in vaccinated individuals. The Middle Eastern countries showed a lower tendency to accept the initial doses of vaccines.

Aim of the study
We investigated if the vaccination attitude in the Middle East has changed toward the booster dose to achieve public herd immunity.

Materials and methods
We conducted an online survey in 5 countries (Egypt, Iraq, Palestine, Saudi Arabia, and Sudan) in November and December 2021. The questionnaire included self-reported information about the vaccine type, side effects, fear level, and several demographic factors. Kruskal–Wallis ANOVA was used to associate the fear level with the type of COVID-19 vaccine. Logistic regression was performed to confirm the results and reported as odds ratios (ORs) and 95% confidence interval.

Results
The final analysis included 3041 fully vaccinated participants. Overall, 60.2% of the respondents reported willingness to receive the COVID-19 booster dose, while 20.4% were hesitant. Safety uncertainties and opinions that booster dose is not necessary were the primary reasons for refusing the booster dose. The willingness to receive the booster dose was in a triangular relationship between the side effects of first and second doses and the fear ($p < 0.0001$). Females, individuals with normal body mass index, history of COVID-19 infection, and influenza unvaccinated individuals were significantly associated with declining the booster dose. Significant higher fear levels were observed in females, rural citizens, chronic and immunosuppressed patients.

Conclusions
Our results suggest that vaccine hesitancy and fear in several highlighted groups remain challenges for healthcare providers, requiring public health intervention and prioritizing the need for targeted awareness campaigns, and facilitating the spread of evidence-based scientific communication.
Acknowledgments: Mr. Mohamed Abouzid and Mr. Alhassan Ali Ahmed are participants of STER Internationalization of Doctoral Schools Programme from NAWA Polish National Agency for Academic Exchange No. PPI/STE/2020/1/00014/DEC

[1169] Do COVID-19 predisposes to prolonged presence of anti-nuclear antibodies (ANA) in the blood of convalescents?

Authors: Michalina Lulek, Agata Skwarek, Paweł Kozłowski, Marcin Śmiarowski, Olga Ciepiela
Affiliation: Students Scientific Group of Laboratory Medicine, Medical University of Warsaw
Trustee of the paper: Olga Ciepiela

Corresponding author: Michalina Lulek (michalina.lulek@onet.pl)

Introduction
Autoimmunity may be triggered by numerous viral infections. COVID-19, a disease caused by SARS-CoV-2, is suggested to be one of them. Several studies have shown that patients with active and severe COVID-19 develop autoimmune reactions, including presence of anti-nuclear antibodies (ANA). However, no studies were performed to analyze how long these antibodies persist and if they may be associated with post-COVID syndrome.

Aim of the study
The aim of this study was to assess the presence of ANA in serum of healthy adult blood donors who recovered from COVID-19.

Material and methods
To the study 163 healthy blood donors were included. They were volunteer blood donors registered at Regional Blood Donation Center in Warsaw, aged 18-65, with no chronic or acute diseases neither under any medical treatment. Among them 90 confirmed previous SARS-CoV-2 positivity, and 73 denied previous SARS-CoV-2 infection. Basing on anti-nucleocapsid anti-SARS-CoV-2 IgG antibodies tests (Roche Diagnostics, Switzerland), 22 of 73 non-infected subjects were classified as convalescents. In all included subjects presence of ANA antibodies in serum using indirect immunofluorescence method (Werfen, Spain) was analyzed, where positive result was considered at 1:80 titer and higher.

Results
ANA antibodies were found in 9.82% of convalescents (11/112), among whom 6 didn't know that they were previously infected with SARS-CoV-2, and in 25.49% (13/51) of previously non-infected individuals. Among convalescents 9 of 11 presented weak speckled pattern of fluorescence, and 2 of 11 – nucleolar. In non-infected 10 of 13 had speckled pattern, 1 - peripheral, 1 presented pattern of proliferating cell nuclear antigen (PCNA) and 1 anti-centriole pattern. Statistical analysis using Fisher exact test showed that ANA were more often found in non-infected subjects, comparing to convalescents ($p=0.0155$). Moreover, at titer cut-off value at 1:160 none of convalescents had positive result, whereas 6 of 51 non infected had positive result, $p=0.0008$.

Conclusions
Based on our results it can be stated that recovering from COVID-19 does not spawn liability to persistent presence of ANA autoantibodies.

[1211] Levels of CD3 +, CD4 +, CD8 + cells and Overall Prognosis of ARDS in COVID-19 Patients - Preliminary Results

Authors: Sanarya Al Kharsan and Ishani Khanna
Affiliation: Department VII of the Provincial Infectious Hospital, Medical University of Warsaw, Poland
Trustee of the paper: lek. Michał Makowiecki and Dr n.med. Agnieszka Bednarska

Corresponding author: Sanarya Al Kharsan (sanarya.mk@gmail.com)

Introduction

Mortality of COVID-19 is estimated at 0.68% and depends on many factors. Acute Respiratory Distress Syndrome (ARDS) is a life-threatening condition, and when encountered in COVID-19, it leads to unfavorable outcomes. ARDS develops in 42% of patients presenting with COVID-19 pneumonia, and 61–81% of those requiring intensive care. Laboratory diagnostics show a significant reduction in the number of CD4+ and CD8+ cells in patients with COVID and ARDS.

Aim of the study

Our aim was to determine the relationship between the number of CD3 +, CD4 +, CD8 + cells and the overall prognosis within the course of COVID-19 in patients who are at risk of developing ARDS.

Material and methods

An observational study was carried out in 16 patients diagnosed with ARDS in COVID-19. Routine diagnostics were performed in all patients. In addition, cytometric tests of peripheral blood were also performed. These tests were performed in all patients included in the study on the second, fourth and sixth day of hospitalization. Within this abstract, we report preliminary results of our investigation. A simple linear regression test was performed to see if there were any initial correlations between the levels of CD3+, CD4+, CD8+ cells and the overall prognosis. $P < 0.05$ was used as a threshold for statistical significance.

Results

Sixteen COVID-19 patients with ARDS were included. 4/16 (25%) died, 6/16 (37.5%) partially recovered while 6/16 (37.5%) fully recovered. The mean age was 61.5. The average percentage of lung infiltrations was 53.9. The most common comorbidities were hypertension and diabetes. The simple regression linear test found a statistically significant correlation between levels of CD3+, CD4+, CD8+ cells on day 4 and day 6 and the overall prognosis in our patients ($p<0.05$). Higher numbers of CD3+, CD4+, and CD8+ cells were associated with good prognosis and lower death rates in included patients.

Conclusions

Our study showed a correlation between the numbers of CD3+, CD4+, CD8+ cells and the prognosis of severe COVID-19. Higher numbers of these parameters were found in COVID-19 patients who subsequently recovered from the disease.

[1326] Comparison of transient elastography (Fibroscan) and liver biopsy results in patients with chronic hepatitis B infection.

Authors: Martyna Zwierzchowska, Jan Pawłasek, Mikołaj Pater
Affiliation: Students' Scientific Society of the Department of Infectious and Tropical Diseases and Hepatology of Medical University of Warsaw
Trustee of the paper: Tomasz Mikuła MD, PhD

Corresponding author: Martyna Zwierzchowska (martyna.zwierzchowska@gmail.com)

Introduction
The detection and quantification of hepatic inflammation and fibrosis is a key element of diagnostic evaluation and prognostication for patients with hepatitis of various etiology. Liver biopsy is an invasive and the most sensitive diagnostic method of assessing parenchymal disease and remains the reference standard. The use of non-invasive methods such as transient elastography (FibroScan) is becoming more prominent. Fibroscan provides an indirect measure of fibrosis via assessment of liver stiffness (LS).

Aim of the study
This study aimed to investigate the concordance between biopsy based histological grading and staging and LS measurement by FibroScan.

Material and methods
We performed statistical analysis comparing Fibroscan and liver biopsy findings in patients with chronic HBV observed between 2015 and 2021.The biopsy grading and staging results were based on the Ishak score. We analyzed serum biochemical parameters, AST, ALT, GGTP, ALP, AFP, total bilirubin and INR. The FibroScan results were interpreted to give the Metavir fibrosis (F0-F4), median LS (kPa), CAP (dB/m). We assessed correlations between the studied parameters. Statistical significance was interpreted as $p<0.05$.

Results
The patients (n=42) had undergone both Fibroscan and liver biopsy evaluation within a one-year interval (31 men, 11 women, median age 35 years, with no co-infections). Median LS was positively correlated with serum ALT, AST, GGTP, bilirubin ($r>0.506$ for all), $p=0.012$, 0.012, 0.006 and 0.010, respectively. There was no correlation with AFP or INR $r=0.377$, $r=0.293$, $p=0.092$, $p=0.165$, respectively. CAP scores were not positively correlated with ALT ($r=0.057$, $p=0.797$), AST ($r=-0.033$, $p=0.881$), INR ($r=0.163$, $p=0.457$), AFP ($r=-0.135$, $p=0.571$), GGTP ($r=0.417$, $p=0.053$), ALP ($r=0.253$, $p=0.268$), bilirubin ($r=0.289$, $p=0.277$). CAP scores were positively correlated with grading rho=0.445; $p=0.038$, but not with staging (rho=0.371, $p=0.089$). Metavir scores were positively correlated with staging ($r=0.471$, $p=0.002$) and grading ($r=0.468$, $p=0.002$).

Conclusions
FibroScan LS results can be correlated with serum ALT, AST, GGTP, bilirubin in patients with chronic HBV. CAP scores can be used to assess liver inflammation. Metavir scores were positively correlated with grading and staging biopsy results.

[1333] Variability of selected biochemical markers in hepatitis A – an 8-week observation study

Authors: Krzysztof Bratek, Julia Hanke
Affiliation: Students' Scientific Society of the Department of Infectious and Tropical Diseases and Hepatology, Medical University of Warsaw
Trustee of the paper: Tomasz Mikuła MD, PhD, Department of Infectious and Tropical Diseases and Hepatology, Medical University of Warsaw, Elżbieta Sienkiewicz PhD, Faculty of Mathematics and Information Science, Warsaw University of Technology

Corresponding author: Krzysztof Bratek (krzyszbr@wp.pl)

Introduction
Hepatitis caused by the hepatitis A (HAV) virus is one of the most common faecal-oral transmitted disease. Its clinical manifestation can vary greatly from asymptomatic to life-threatening liver failure. Elevated serum activity of alanine aminotransferase (ALT), alkaline phosphatase (ALP), aspartate aminotransferase (AST), gamma-glutamylotransferase (GGTP), serum bilirubin (BIL) concentration with the presence of anty-HAV antibody are the main markers confirming the HAV infection.

Aim of the study
This study estimates ALT, ALP and BIL serum levels changes during 60 days observation.

Material and methods
We analyzed the results of n = 92 patients infected with HAV admitted to our department from January 2017 to December 2021.
We analyzed ALT, ALP, and BIL results on admission acting as point zero and used test results within a range of the subsequent 60 days to estimate value function.
We used Functional Data Analysis (FDA) to model the levels of ALT, ALP, and BIL as functions of time, with the only assumption being the smoothness of the underlying process. The mean level was established point-wise and confidence intervals calculated assuming normality of measurements.

Results
ALT mean value on day zero was 2196.8 IU/l (confidence intervals: 1606.9 – 3003.3) and dropped to 110.3 IU/l (confidence intervals: 50.0 – 243.2) on day 60. (ALT reference range: 10 – 40 IU/l)
Bilirubin mean value on day zero was 102.5 μmol/l (confidence intervals: 80.5 – 130.5), and dropped to 18.4 μmol/l (confidence intervals: 11.2 – 30.4) on day 60. (BIL reference range: 5.1 – 17.1 μmol/l)
ALP mean value on day zero was 186.7 IU/l (confidence intervals: 158.4 – 200.1) , dropping to 72,7 IU/l (confidence intervals: 56.4 – 93.7) on day 60. (ALP reference range: 30 – 120 IU/l)
The mean value of each parameter declined rapidly until the 40th day when the decrease slowed. Out of the all parameters, only ALP means value reached the normal range within the 60 days, hitting 119.8 IU/l on day 18.

Conclusions
Elevated serum ALT activity and serum bilirubin concentration can be detected 8 weeks after first symptoms of HAV infection
Serum ALP activity normalizes faster than ALT and bilirubin concentration in 8-week observation.

[1418] Thrombosis-related circulating miR-16-5p is associated with disease severity in patients hospitalised for COVID-19

Authors: Mikołaj Marszałek, Zofia Wicik, Sérgio N. Simões, David C. Martins-Jr, Jenny Simon, Disha Keshwani, Anna Nowak, Joanna Jarosz-Popek, Marta Wolska, Dariusz Soldacki, Marek Postula, Ceren Eyileten,
Affiliation: Department of Experimental and Clinical Pharmacology, Medical University of Warsaw, Center for Preclinical Research and Technology CEPT, 02-091 Warsaw, Poland
Trustee of the paper: Ceren Eyileten

Corresponding author: Mikołaj Marszałek (mszalek.m@gmail.com)

Introduction
SARS-CoV-2 tropism for the ACE2 receptor, along with the multifaceted inflammatory reaction, is likely to drive the generalized hypercoagulable state and thrombosis seen in patients with COVID-19 infection

Aim of the study
We aimed to select miRNAs based on a bioinformatic analysis and to validate their expression in patients with COVID-19 to analyze the diagnostic and predictive utility of thrombosis-related miRNAs (miR-16-5p, miR-27a-3p, Let-7b-5p and miR-155-5p)

Material and methods
Using the original bioinformatic workflow and network medicine approaches we reanalyzed four coronavirus-related expression datasets and performed co-expression analysis focused on thrombosis and ACE2 related genes. We first identified microRNAs (miRNAs) which play a role in ACE2-related thrombosis in coronavirus infection. Furtherly, we validated the expressions of those miRNAs in 79 hospitalized COVID-19 patients and 32 healthy volunteers with PCR. We searched for miRNAs patterns during the acute phase of COVID-19, as well as for the prognostic potential of these miRNAs as biomarkers.

Results
We identified EGFR, HSP90AA1, APP, TP53, PTEN, UBC, FN1, ELAVL1 and CALM1 as regulatory genes which could play a pivotal role in COVID-19 related thrombosis. We also found miR-16-5p, miR-27a-3p, Let-7b-5p and miR-155-5p as regulators in the coagulation and thrombosis process. We observed in separate cohort of COVID-19 patients and healthy controls that: (a) expression of miR-16-5p, miR-27a-3p and miR-155-5p increased during the observation, compared to the baseline measurement; (b) a low baseline miR-16-5p expression presents predictive utility in assessment of the hospital length of stay or death in follow-up as a composite endpoint (AUC:0.810, 95% CI, 0.71-0.91, $p<0.0001$); (c) low baseline expression of miR-16-5p and diabetes mellitus are independent predictors of increased length of stay or death according to a multivariate analysis (OR: 9.417; 95% CI, 2.647-33.506; $p=0.0005$ and OR: 6.257; 95% CI, 1.049-37.316; $p=0.044$, respectively).

Conclusions
This study allowed us to better characterize changes in gene expression and signaling pathways related to COVID-19 thrombosis. We identified, characterized and validated miRNAs which could serve as novel thrombosis-related biomarkers of COVID-19, and could also be possibly used for early stratification of patients and prediction of individual severity development.

[1487] Factors influencing the severity of COVID-19 infection in patients hospitalized the Central Teaching Clinical Hospital in Warsaw during the fourth wave of the pandemic

Authors: Zuzanna Danielecka, Damian Maruszak MD, Jakub Strzelczyk MD, Klaudia Knapik MD
Affiliation: Department of Internal Medicine, Hypertension and Vascular Diseases, Medical University of Warsaw
Trustee of the paper: Piotr Abramczyk, MD, PhD; Jerzy Tyszkiewicz MD, PhD

Corresponding author: Zuzanna Danielecka (z.danielecka@gmail.com

Introduction
The COVID-19 infection has various course: from asymptomatic to severe requiring mechanical ventilation, with high mortality. There are several reports correlating selected laboratory parameters and the severity of COVID-19 illness.

Aim of the study
The aim of this study was to evaluate the relationship between initial laboratory parameters and the severity of COVID-19 defined by the type of oxygen therapy in patients during the fourth wave of the pandemic in the COVID Department of the Central Teaching Clinical Hospital in Warsaw, Poland.

Material and methods
The study group consisted of 86 patients consecutively admitted to the COVID Department due to primary diagnosis of SARS-CoV-2 infection. The patients with other reasons of admission, despite the later diagnosis of COVID-19, were not included. Selected laboratory parameters measured at admission were analyzed. Patients were grouped according to severity of COVID-19 measured by the highest oxygen therapy needed during hospitalization (FiO2): group A (0.21-0.39) - 34 patients; group B (0.40-1.0) - 21 patients; group C (HFNO) - 31 patients.

Results
The statistical significance of the relationship was found between initially increased NT-proBNP and Troponin I levels and highest oxygen therapy needed during hospitalization of groups A and C of patients. Concentrations of NT-proBNP (M ± SD: group A= 1162.5±1561.2; group B= 4232.2±6997.0; group C= 4732.3±6817.0) and Troponin I (M ± SD: group A = 0.128±0.367; group B= 0.138±0.306; group C= 0.191±0.352) were significantly higher ($p<0.05$) in group C compared to group A. Patients in group B had significantly higher initial levels of LDH (M ± SD: group A= 348.5±114.2; group B= 568.0±153.6; group C= 364.9±116.0) compared to groups A ($p<0.05$) and C ($p<0.05$). Initial level of C-reactive protein and D-dimer, number of leucocytes and percentage of neutrophils did not predict highest oxygen therapy needed.

Conclusions
On the basis of our study, we can conclude that the levels of certain laboratory parameters as Troponin I, NT-proBNP which as predictors are probably associated with right ventricular overload and/or left ventricular ischemia. That indicates a significant burden not only on the respiratory system but also on the cardiovascular system in the course of COVID-19.

[1497] Serum procalcitonin levels and other blood test markers in patients diagnosed with malaria

Authors: Magdalena Radziszewska, Róża Pszonak, Zofia Gajek
Affiliation: Students' Scientific Society of the Department of Infectious and Tropical Diseases and Hepatology of Medical University of Warsaw
Trustee of the paper: Dagny Krankowska, MD; Tomasz Mikuła MD, PhD

Corresponding author: Róża Pszonak (roza.ps@interia.pl)

Introduction
Due to the availability of affordable traveling, tropical diseases, such as malaria, are diagnosed more often in countries such as Poland. Procalcitonin (PCT) is a peptide, the level of which rises in a response to a pro-inflammatory stimulus, especially of bacterial and fungal origin. Measurement of PCT can be used as a marker of severe sepsis and generally grades well with its degree. Levels above 10 ng/ml are considered to be a marker of high risk of sepsis and septic shock.

Aim of the study
The aim of the study was to analyze serum levels of PCT, complete blood count (CBC) and other biochemical blood tests in patients with malaria admitted to our department.

Material and methods
We analyzed data of 16 patients diagnosed with malaria (9 men, 7 women) in years 2016-2021. The results of laboratory tests on the day of the admission including PCT, c-reactive protein (CRP), CBC, d-dimers, alanine aminotransferase (AlAT), asparagine transaminase (AspAT) and international normalized ratio (INR) were considered.

Results
The mean patients' age was 36,7 years and they were returning from either Sub-Saharian countries (13 patients) or Asian countries (3 patients). Most of them were diagnosed with Plasmodium falciparum (75,0%), P. vivax was found in 2 patients (12,5%, both returning from India) and in 2 patients the species of Plasmodium spp. Was not determined. Mean parasitemia was 3,58% (ranging from 0,1% to 18%). 56,2% of patients didn't use any kind of anti-malarial prophylaxis.
Analyzed mean PCT level in the studied group was 9,56 ng/ml (ranging from 0,05 to 36,85 ng/ml), with elevated values present in 62,5% of the patients.
Mean level of CRP was 105,9 mg% (normal up to 10,0mg%) and it was increased in 87,5% of the patients. Mean platelets count was 133,1 G/L (normal 150-450 G/L) and ranging from 17 to 327 G/L. D-dimers were significantly elevated with mean value of 7266,0 ng/ml (normal: below 500 ng/ml) and with the highest value of 28756,0 ng/ml. The INR were normal in all patients. Serum levels of AlAT and AspAT were elevated in more than a half of the studied patients (62,5%).

Conclusions
All patients with elevated PCT, CRP, AlAT, AspAT, D-dimer levels coming from tropical regions should be considered as potentially infected with malaria. However none of these findings could alone be considered as specific for Plasmodium spp. infection. Moreover, it is important to emphasize that in order to prevent the contraction of the disease all people going to malaria endemic areas should use effective anti-malarial prophylaxis.

Internal Medicine

Date: 7th May 2022, 8:30 AM

Coordinators:
Patryk Pindlowski
Jakub Komorowski - Roszkiewicz

Patronage:

Polskie Towarzystwo Nadciśnienia Tętniczego

Konsultant krajowy w dziedzinie chorób płuc
Prof. dr hab. n. med. Halina Batura - Gabryel

Polskie Towarzystwo Gastroenterologii

Konsultant Krajowy w dziedzinie gastroenterologii
Prof. dr hab. n. med. Jarosław Reguła

[1149] Spirometry findings in Patients with Allergic Rhinitis and Diagnosis of Silent Asthma

Authors: Mohammadamin Sadeghdoust, Farnaz Aligolighasemabadi, Mohammadmedhi araqi, Hora seyedeashrafi
Affiliation: Health Policy Research Centre, Institute of Health, Shiraz University of Medical Sciences, Shiraz, Iran.
Trustee of the paper: Mohammadamin Sadeghdoust

Corresponding author: Mohammadamin Sadeghdoust (m.sadeghdoust@gmail.com)

Introduction
Allergic rhinitis is a chronic inflammatory disease of nasal mucosa induced by type I hypersensitivity response upon exposure to common inhaled allergens in sensitized individuals and affects up to 40% of worldwide population with an increasing prevalence over the past 20 years. Allergic rhinitis causing symptoms like rhinorrhea, sneezing, nasal itching and congestion.

Aim of the study
Due to the high prevalence of Allergic rhinitis and asymptomatic cases of asthma, we performed this research to study spirometric parameters in allergic rhinitis patients without pulmonary symptoms.

Materials and methods
This cross-sectional study included all patients with allergic rhinitis who referred to Gangavian hospital, a tertiary hospital in Dezful city (Iran), from August to December 2021. Patients with asthma, chronic cough, active respiratory infection, and smoker subjects and also those who recently used corticosteroids or anti- histamine were excluded from the study. Spirometry with and without bronchodilators was performed for all patients and FEV1, FVC, FEF25-75, were recorded. The spirometry test was considered positive if: (a) the difference in FEV1 before and after spirometryis more than 12; (b) The difference between FEF25-75 and FEV1 more than 20; (c) The difference in FEF25-75 before and after the spirometry test more than 20. Data were analyzed by SPSS software version 22 and P value ≤ 0.05 was considered significant.

Results
After initial recruitment of 459 patients with allergic rhinitis and careful consideration of the exclusion criteria, a total of 120 patients were included in this study. Fifty-five (45.8%) were female and 65 (54.1%) were male and the mean age was 32±12.32. According to spirometry study, FEV1 before-after in 24 of patients (20%) were more than 12, the difference between FEF25-75 and FEV1 in 33 of patients (28%) were more than 20, and FEF25-75 before-after in 30 patients (25%) were more than 20. There was no statistically significant relationship between spiromery parameters age, gender, or duration of disease ($p>0.05$ for all).

Conclusions
According to the results, in patients with allergic rhinitis, spirometry can be helpful in early diagnosis of the asthma. It especially important in patients with new asthma treatment methods such as immunotherapy.

[1165] Causes of chronic cough among adults managed in the cough clinic

Authors: Paweł Kukiełka, Katarzyna Moliszewska
Affiliation: Students' Research Group 'Alveolus', Medical University of Warsaw, Poland / Department of Internal Medicine, Pulmonary Diseases and Allergy, Medical University of Warsaw, Poland
Trustee of the paper: Marta Dąbrowska, MD, PhD

Corresponding author: Paweł Kukiełka (p.kukielka7@gmail.com)

Introduction
Chronic cough (CC) is a common complaint significantly reducing patients' quality of life. There is a wide spectrum of diseases which can cause CC among adults.

Aim of the study
The aim of our study was to analyze the causes of CC in adults diagnosed in a cough clinic.

Materials and methods
We retrospectively analyzed data from adults managed in the cough clinic of Department of Internal Medicine, Pulmonary Diseases and Allergy between 2016-2021.

Results
Research included data from 281 patients (201 F, 80 M) with median age 56.5 years (IQR 43-67), median CC duration 48 months (IQR 24-120) and median CC intensity measured by 100 mm VAS 62/100 (IQR 44-77).
In 3 (1%) patients no reason of CC was identified and idiopathic CC was diagnosed. In 65 (23.1%) patients only 1 cough reason was found, in others 2 or more cough coexisting causes were diagnosed.
The most common CC reason was upper airway cough syndrome (175 pts; 61.4%), followed by gastroesophageal reflux disease (150 pts; 53.0%) and asthma (131 pts; 46%).
Among other reasons of CC obstructive sleep apnea (25 pts, 8.9%), non-asthmatic eosinophilic bronchitis (12 pts, 4.3%), interstitial lung diseases (9 pts, 3.2%) and bronchiectasis (7 pts, 2.5%) were the most frequently diagnosed.

Conclusions
Idiopathic CC was rare among adults managed in our cough clinic. In the majority of patients with CC ≥ 2 coexisting causes of cough were identified. The less common causes of cough should be considered in diagnosing adults with CC.

[1183] Differences between men and women in the management of adults with chronic cough.

Authors: Aleksandra Marchwińska, Katarzyna Mazurek
Affiliation: Department of Internal Medicine, Pulmonary Diseases and Allergy, Medical University of Warsaw
Trustee of the paper: Marta Dąbrowska MD PhD

Corresponding author: Aleksandra Marchwińska (a.marchwinska@outlook.com)

Introduction
Chronic cough (CC) is a common medical condition that affects women more frequently. It is caused by many different diseases.

Aim of the study
The study aims to compare the spectrum of diseases causing CC and the response to therapy between men and women.

Materials and methods
The retrospective analysis of data in patients diagnosed due to chronic cough in the Department of Internal Medicine, Pulmonary Diseases and Allergy between 2017 and 2021 was performed. The study included 231 patients. The data on the efficacy of treatment were available in 149 cases. The response to treatment was assessed based on the reduction in the intensity of cough measured by 100 mm visual analogue scale (VAS) or improvement in the quality of life (QoL) measured by the Leicester Cough Questionnaire (LCQ). Good response was defined as a decrease of cough intensity by at least 30 mm or an increase in LCQ by at least 1,5 points.

Results
164 women (70.9%) and 67 men (29.1%) were included in the study. The mean age of the patients was 57 years (44.8-67.3), while the mean duration of cough was 48 months (24-120). The median severity of cough on the VAS scale was 61 (41-78), and the median QoL measured by LCQ score was 11.26 (8.6-13.84). There were no differences between males and females in terms of demographics or baseline cough severity. Upper airway cough syndrome (UACS) and obstructive sleep apnea (OSA) were diagnosed more frequently in men than women (UACS 75% vs 53%, p =0.0025 and OSA 21%vs 6%, p=0.0008). There was a significant reduction in the intensity of cough in both groups (in women reduction of median VAS from 55 to 40 mm, $p<0.0001$ and in men from 69 to 39 mm, p=0.0096, respectively). Similarly, in both groups, the improvement in the QoL after treatment was documented (in women increase in median LCQ from 11.5 to 13.9, $p<0.0001$, while in men from 10.6 to 14.6, p=0.0004). The effectiveness of CC treatment measured by the VAS scale was greater in men (median VAS reduction was 32 in men vs 17.5 in women, p=0.006).

Conclusions
The study points at some relevant differences between women and men both in the spectrum of CC causes and effectiveness of CC therapy.

[1196] Does the diagnosis of gastroesophageal reflux (GER) make the treatment of chronic cough (CC) less effective?

Authors: Katarzyna Moliszewska, Paweł Kukiełka
Affiliation: Students' Research Group 'Alveolus', Medical University of Warsaw, Poland Department of Internal Medicine, Pulmonary Diseases and Allergy, Medical University of Warsaw, Poland
Trustee of the paper: Marta Dąbrowska, MD, PhD

Corresponding author: Katarzyna Moliszewska (k.moliszewska@gmail.com)

Introduction
Gastroesophageal reflux (GER) is a common condition often coexisting with chronic cough (CC). Efficacy of treatment of GER related CC in adults is known to be limited.

Aim of the study
The aim of this study was to analyze the effectiveness of therapy in patients with GER and CC.

Materials and methods
We retrospectively analyzed data from adults managed in the cough clinic of Department of Internal Medicine, Pulmonary Diseases and Allergy between 2017-2021. Patients diagnosed with GER were treated with modification of diet and proton pump inhibitors for 4-6 weeks. The response to therapy was measured based on patients related outcomes: cough severity measured by 100mm Visual Analogue Scale (VAS) and cough related quality of life (QoL) measured by Leicester Cough Questionnaire (LCQ). Effective treatment was defined as a ≥30 mm reduction in VAS or ≥ 1.5 pts improvement in LCQ.

Results
Research included data from 231 adults with CC (164 F, 67 M), with median age 57 years (IQR45-67), median cough duration 48 months (IQR 24-120), median CC severity measured by VAS 61mm (IQR 41-78) and median QoL measured by LCQ 11.3 pts (IQR 9.2-13.8).
GER was diagnosed in 150 patients (64.9%). Patients with GER related CC had higher BMI (median BMI 27.4 vs 25.3, p=0.014) and longer lasting cough (median duration 60 vs 48 months, p=0.011). There were no differences in cough severity or QoL between GER and non-GER patients.
Evaluation of response to therapy was possible in 149 adults. Both GER and non-GER patients presented a significant reduction of cough severity and improvement in QoL after anti-reflux treatment. However, we did not find differences in the effectiveness of treatment between patients with GER related CC and other patients with CC.

Conclusions
Although diagnosis of GER affects the course of CC, it does not impact on less effective treatment of CC.

[1219] The impact of COVID pandemic on perception of cough in adults with chronic cough.

Authors: Monika Rudzińska, Łukasz Banaszek
Affiliation: Department of Internal Medicine, Pulmonary Diseases and Allergy, Medical University of Warsaw, Poland
Trustee of the paper: Marta Dąbrowska, MD, PhD

Corresponding author: Monika Rudzińska (mrudzinska19@gmail.com)

Introduction
Chronic cough (CC) significantly impairs patients' quality of life. During COVID pandemic cough has been considered as a cardinal symptom of SARS-CoV-2 infection.

Aim of the study
The aim of this study was to assess the impact of COVID pandemic on perception of cough in patients with CC.

Materials and methods
A survey, which included 13 closed questions, was conducted among 50 adults with CC who were treated in a cough clinic at the Department of Internal Medicine, Pulmonary Diseases and Allergy between November 2021 and February 2022.

Results
Forty six patients (27 women, 19 men) replied to the questionnaire. Median age of patient was 57 (46-68,7), median duration of cough - 6 years (3-10). Twenty three patients (50%) had SARS-CoV-2 infection confirmed by antigen or RT-PCR test, but increase of cough intensity was noted only in 52.5% of them (12/23). We did not find differences in perception of cough between the patients with CC, who had SARS-CoV-2 infection and those, who did not.

Conclusions
During COVID pandemic majority of adults with CC were exposed to unfavourable social reactions what might negatively affect their quality of life. However, only few of them noted deterioration of cough or needed escalation of antitussive therapy.

[1303] COVID-19 and necessity for beta-blockers treatment after recovery

Authors: Tomasz Jędrasek
Affiliation: Department and Clinic of Internal and Occupational Diseases and Hypertension
Trustee of the paper: MD PhD Jakub Gawryś

Corresponding author: Tomasz Jędrasek (tomyjedrasek@gmail.com)

Introduction
Manifestation of a Sars-CoV-2 infection is observed not only in the respiratory system but also in other organs, with frequent cardiovascular symptoms. Recent data indicates that arterial hypertension and cardiovascular diseases (CVD) are the most prevalent comorbidities in patients infected with Sars-CoV-2. Many patients who have recovered from COVID-19 still experience symptoms and suffer from cardiovascular complications.

Aim of the study
The aim of the study is to examine if patients with CVD need additional treatment with beta-blockers or changes in previous dosage after recovery from a Sars-CoV-2 infection.

Materials and methods
We conducted a retrospective study of 70 patients (age above 18); 33 women and 37 men with CVD, hospitalized due to COVID-19 from October 2020 to february 2022 in a temporary ward of Department and Clinic of Internal and Occupational Diseases and Hypertension and in Temporary Hospital in Wrocław. The aim of the study was to assess a profile of COVID-19 patients with CVD and to compare whether and how the dose of beta-blockers changed before and after Sars-CoV-2 infection. Collected data included patient gender, age, medical history, medication taken before and after COVID-19, course of COVID-19, measurements of respiration rate, pulse rate, and blood pressure during Sars-CoV-2 infection. When making a statistical analysis we used Wilcoxon signed-rank test (for related qualitative variables).

Results
Selected study group of 70 patients was divided into two groups: the first (n = 50) without increase or initiation of beta-blocker therapy, the second (n = 20) with administration or increase of the dose. The Wilcoxon pair sequence test showed a significant difference between groups (before and after infection) with p = 0,000196. In the second group 6 patients were treated with beta-blockers before COVID-19 and a dose increase was recommended after they had recovered, 14 patients who had not taken beta-blockers before the infection were prescribed beta-blockers after recovery.

Conclusions
The results of our study suggest that after recovery from a Sars-CoV-2 infection, patients need an additional treatment with beta blockers or increase in the previous beta-blocker dosage due to post-COVID-19 complications.

[1351] Does cigarette smoking prevent from severe allergic reactions to Hymenoptera venom?

Authors: Weronika Chodak, Ewa Malaka, Julia Turek
Affiliation: University of Opole, Department of Internal Medicine with Division of Allergology, Institute of Medical Sciences
Trustee of the paper: Lukasz Moos MD, Prof. Zenon Brzoza MD, Ph.D

Corresponding author: Weronika Chodak (weronikachodak4@gmail.com)

Introduction
Hymenoptera venom allergy is an allergic reaction to a sting from insects such as a honeybee, vespid and ant. Allergy symptoms range from mild, involving only the skin, through moderate to severe, including anaphylactic shock.
Allergy and asymptomatic sensitization to hymenoptera venom (both IgE and non-IgE dependent) in adults are common in Poland.
In this region most of the patients with Hymenoptera venom allergy (around two thirds) react to wasp stings, while one third to bee stings. Nonetheless, up to 59% of patients have double-positive results in IgE tests.
Factors that increase the risk of sensitisation to Hymenoptera venom include age; gender; use of medications; cardiovascular diseases; increased serum tryptase levels.
Nicotine is one of the most used and common stimulants. In 2018 smokers in Poland accounted for 26%. Both passive and active smoking may lead to the development of various diseases such as cardiovascular diseases, chronic obstructive pulmonary disease.
There are studies suggesting possible protective effects of cigarette smoking on autoimmune and allergic diseases (e.g. chronic spontaneous urticaria, autoimmune hypothyroidism).

Aim of the study
The aim of our study was to assess the prevalence of cigarette smoking among patients diagnosed with Hymenoptera venom allergy

Materials and methods
Data from the study were obtained by statistical analysis of 64 patients admitted to the University Hospital in Opole in the years 2018-2021 diagnosed with Hymenoptera venom allergy (grade III and IV according to RING and Messer). The group was divided according to the severity of Hymenoptera venom allergy and cigarette smoking, distinguishing also patients allergic to wasp and bee venom. The chi-square test method was used in the calculations.

Results
Among the studied group, there were 2 smokers allergic to bee venom and 10 non-smokers, and 12 smokers allergic to wasp venom and 40 non-smokers.
In our analysis, the prevalence of cigarette smoking among patients allergic to Hymenoptera venom with diagnosed severe allergic reaction is 21.9%.

Conclusions
The prevalence of cigarette smoking among patients allergic to Hymenoptera venom with diagnosed severe allergic reaction is lower than in the general population of Poland.
No statistically significant differences were found in the incidence of individual degrees of severity of anaphylaxis and in the percentage of wasp or bee sensitization between smokers and nonsmokers

[1382] Exercise-induced retinal microcirculation changes in healthy subjects analyzed with adaptive optics rtx1 TM.

Authors: Maria Żmijewska, Maciej Janiszewski, Jakub Janiszewski, Zbigniew M. Wawrzyniak, Anna Zaleska-Żmijewska
Affiliation: Ophthalmology Department at the Medical University of Warsaw
Trustee of the paper: dr hab n. med. Anna Zaleska-Żmijewska Ophthalmology Department

Corresponding author: Marta Żmijewska (zmijewska01@gmail.com)

Introduction
The effects of an aerobic physical exercise on the retinal microvascular regulation in healthy volunteers.

Aim of the study
To investigate the effects of intensive aerobic physical exercise on the retinal microvascular regulation in healthy volunteers.

Materials and methods
The study was performed in the Ophthalmology Department at the Medical University of Warsaw. We included healthy volunteers (11 men and 14 women) aged 20,6± 0,9. Heart rate (HR), systolic and diastolic blood pressure (SBP, DBP) were recorded before and immediately after a stationary cycling exercise. Oxygen saturation at rest was collected. Physical exertion consisted of continuously riding on a training ergometer, with the same protocol for all participants. All participants reached 80% of the maximum theoretical heart rate. The superior temporal retinal artery measurements were captured using adaptive optics (AO) camera system rtx1TM (Imagine Eyes, Orsay, France). We compared measures of vessel diameter (VD), lumen diameter (LD), two walls (Wall 1, 2) and wall to lumen ratio (WLR), and cross-sectional wall analysis (WCSA) before and after the physical effort.
The study was conducted following the tenets of the Helsinki Declaration with the patient's informed consent.

Results
All patients had an oxygen saturation that exceeded 98% before activity. After exercise, SBP, DBP and HR changed significantly, from 130,2±13,2 to 160,0±16,1 mm Hg, 81,2± 6,3 to 77,1±8,2 mm Hg and 80,8± 16,1 to 175,0±6,2 bpm, respectively ($p < 0.002$). The mean BMI was 23,1± 4,3. The mean time of the circling episode to achieve the 80% of the maximal HR was 10,1±2,9 minutes.
There were no differences between right and left eye parameters in axial length and mean vessel diameters at rest. Before the exercise the mean LD was 96±6,8, VD 118,5±8,3, WLR 0,234±0,02, WCSA 3802,77±577,61. The mean LD and Wall 1 didn't change significantly after exercises but slightly decreased. The VD, Wall 2, WLR and WCSA decreased significantly after exercises ($p<0.05$). The dependence between BMI and WLR and WCSA in the linear correlation was also found.

Conclusions
Our results suggest that the response of the retinal microcirculation to the intensive short term aerobic physical effort results in an increase in blood pressure and heart rate and narrowing of small retinal arterioles.

Laryngology, Audiology & Phoniatrics

Date: 7th May 2022, 8:30 AM

Coordinator:
Aleksandra Kawałko

Patronage:

Konsultant Krajowy w dziedzinie Otolaryngologii Dziecięcej
Prof. dr hab. n. med. Wiesław Konopka

Wojewódzki Konsultant w dziedzinie Otolaryngologii
dr hab. n. med. Karolina Dżaman

magazyn OTORYNO-LARYNGOLOGICZNY

Union of the European Phoniatricians

TOFAP

[1368] Quantitative assessment of olfactory and gustatory function during an active SARS-CoV-2 infection and convalescence period

Authors: Paulina Szot, Zuzanna Steć, Zofia Burska, Eliza Brożek-Mądry, Marcin Straburzyński, Antoni Krzeski
Affiliation: Department of Otolaryngology, Faculty of Medicine and Dentistry, Medical University of Warsaw
Trustee of the paper: Eliza Brożek-Mądry

Corresponding author: Paulina Szot (paulinaszotszkolny@gmail.com)

Introduction
SARS-CoV-2 is the virus that causes coronavirus disease 2019 (COVID-19). The main symptoms of infection are fever, cough and breathing difficulty. Reported symptoms often include loss of smell and taste, which are predictive of COVID-19.

Aim of the study
Quantitative analysis of magnitude of olfactory and gustatory dysfunction during an active SARS-CoV-2 infection and convalescence period.

Material and methods
Eight patients were recruited to take part in this study between March and December 2021. Recruitment criteria included: SARS-CoV-2 infection confirmed by a positive RT-PCR or antigen (Abott) test, 1-8 day of infection on the day of the inclusion in the study, loss of smell and taste on the day of the inclusion in the study, age between 18 to 60 years. Patients were asked to complete the University of Pennsylvania Smell Identification Test (UPSIT) and taste strip test during the first 8 days of infection, then 7 days after the first test, 5 weeks (35 days ±3) since the beginning of infection, 8 weeks (56 days±3) since the beginning of infection. UPSIT is a validated, self-administered, multiple-choice, odorant test which has a high reliability in assessment of olfactory function. It consists of 40 microencapsulated "scratch and sniff" odorants. Taste strip test is used for assessment of gustatory function. Home-made filter papers were saturated with tastants (sodium chloride, saccharose, quinine and citric acid) in increasing concentrations. The patient places each strip in the middle of the anterior third of their tongue and identifies the perceived taste.

Results
Eight patients (aged 25 - 56 years, average 41y) exhibited olfactory dysfunction at baseline - 2 exhibited total anosmia (25%), 3 exhibited severe microsmia (37.5%), 1 person presented with moderate anosmia (12.5%), 2 exhibited mild microsmia (25%). During 8 week follow up, 1 person exhibited total anosmia (12.5%), 2 presented with moderate anosmia (25%), 3 exhibited mild microsmia (37.5%), 2 exhibited normosmia (25%). Five patients exhibited hypogeusia at baseline (62.5%), 3 presented with normal gustatory function. During 8 week follow up, 2 patients exhibited hypogeusia (25%), whereas 6 exhibited normal gustatory function (75%).

Conclusions
Quantitative olfactory and gustatory assessment shows that smell and taste function is heavily impaired during an active SARS-CoV-2 infection. Most patients experienced an enhancement in gustatory function during convalescence period, whereas olfactory dysfunction persisted up to 8 weeks.

[1404] Persistent perforations in pediatric patients

Authors: Arkadiusz Moskwa
Affiliation: Otorhinolaryngology Department - Pediatric Hospital of the Medical University of Warsaw
Trustee of the paper: dr hab. n. med. Lidia Zawadzka-Głos

Corresponding author: Arkadiusz Moskwa (m.arek@onet.eu)

Introduction
Insertion of the tympanostomy tube (TT) into the ear can provide proper ventilation of the middle ear in pediatric patients in the severe middle ear diseases. Nevertheless perforations of the tympanic membrane after the surgery and TT extrusion or during chronic otitis media with cholesteatoma can occur and can even be persistent. Thus myringoplasty is performed to avoid deteriorating the sense of hearing or gaining entry the water into the ear while swimming.

Aim of the study
The aim of this study was to assess the rate of the tympanic membrane perforation occurrence after severe conditions.

Material and methods
The data was gathered from 70 patients (140 tympanic membranes) who were referred to our Department to perform myringoplasty due to the tympanic membrane persistent perforation. The data was analysed from years 2019-2022. The diagnoses such as condition after the tympanostomy and chronic otitis media with cholesteatoma were considered because the perforations are the most often after these conditions.

Results
The mean age of all these patients, when they had their first operation, totalled approx. 11 y.o. In 58 (41%) tympanic membranes of these patients the persistent perforations were found. The TTs were inserted into 67 (48%) tympanic membranes. The cholesteatoma was found in 54 (39%) middle ears.

Conclusions
It might be considered that the occurence of the perforation after severe conditions in pediatric patients is coincidence. Nevertheless due to literature there is significant difference in this rate comparing to other hospitals. The difference can exist because of the high reference level of the Pediatric Hospital of MUW. Further prospective research is needed to give better understanding of this phenomenon.

[1503] Revision parotidectomy - analysis of indications for the procedure and treatment results based on 10 years follow-up.

Authors: Ewa Kucharska, Anna Rzepakowska, Zuzanna Krupa, Anna Zając, Natalia Winiarska, Ewa Osuch-Wójcikiewicz
Affiliation: Department of Otorhinolaryngology, Head and Neck Surgery, Medical University of Warsaw
Trustee of the paper: Ewa Kucharska, Anna Rzepakowska

Corresponding author: Natalia Winiarska (natalia.winiarska@hotmail.com)

Introduction
Parotid surgery is a challenge for surgeons due to the risks associated with paralysis of the facial nerve and, consequently, asymmetry and dysfunction of the patient's facial muscles. The risk of damaging the facial nerve is even greater with parotid reoperation. Unfortunately, some pathologies of the salivary glands tend to recur and require another surgery. They include benign neoplasms, especially pleomorphic adenoma, and various types of malignant neoplasms of the salivary glands.

Aim of the study
The aim of this retrospective cohort study is a review of indications and outcomes of revision parotidectomy in adults hospitalized in the Department of Otorhinolaryngology, Head and Neck Surgery, Medical University of Warsaw for 10 years (2010-2020).

Material and methods
The retrospective analysis was based on the 66 medical records (form hospitalization and ambulatory treatment) collected over a period of 10 years (2010-2020).

Results
Among 66 patients, the main cause of salivary gland reoperations was pleomorphic adenoma 62,12% n =41. The distribution of cases by sex showed a more frequent occurrence of changes in women (57.57%, n = 38). The mean age of the first operation was 44.4 years for women and 47.625 for men. Number of recurrences ranged from one (39,39% n=28) to eight (1,52%, n=1).
The lesions were most often located in the parotid gland and were single-focal.
Most of the facial nerve function was completely normal before the first surgery.
Malignant neoplasms were the second group of indications for reparotidectomy.

Conclusions
The most common cause of salivary gland reoperation was recurrence of pleomorphic adenoma. The reoperations of this region are associated with complications, including facial nerve paralysis, that strongly affect the patients' lives. This group of patients should be treated in specialized centers.

[1168] PARTIAL TONGUE PARALYSIS AFTER STYLOIDECTOMY IN EAGLE'S SYNDROME

Authors: Maliborski P, Usowska K, Szeląg Adam, Dr. Chodkowski K
Affiliation: Student Scientific Research at Oral and Maxillofacial Surgery Clinic at Military Institute of Medicine in Warsaw
Trustee of the paper: Dr. Karol Chodkowski

Corresponding author: Piotr Maliborski (p_maliborski@icloud.com)

Background

Eagle's syndrome is a rare set of symptoms resulting from styloid process hypertrophy or calcification of the stylomandibular or stylohyoid ligament.
There are 2 basic types of Eagle's syndrome.
The classic form is a complication after tonsillectomy, manifested by pain when swallowing and the sensation of having a foreign object in the throat.
The second type is styloid-carotid artery syndrome caused by the stimulation of nerves situated in the carotid artery wall by a misshapen and extended styloid process. In this case, the most common complaints are the following: migraine headaches, blurred vision, neurological disorders and craniofacial pain.
Eagle's syndrome is difficult to recognize due to the lack of characteristic clinical spectrum. Diagnosis is based on an interview with a patient and physical examination; however, it is crucial to perform computed tomography in order to accurately identify hypertrophy of the styloid process.
Surgical treatment is the treatment of choice; however, it is possible to achieve good therapeutic results by preventive treatment – eliminating the symptoms without the removal of pathology.
Properly performed therapy leads to the abolishment of ailments and significantly reduces the risk of the occurrence of complications.

Case report

The clinical case describes a 32-year-old woman who was consulted at the Clinic of Otolaryngology at Military Institute of Medicine in Warsaw due to chronic and severe pain in the right submandibular part and a sore throat. CT showed a considerable hypertrophy of the right styloid process (7 cm), indicating Eagle's syndrome.
The patient was referred to Maxillofacial Surgery Outpatient Clinic for styloidectomy.
After the procedure, the patient had a follow-up appointment. Limited mobility and sensation in the right part of the tongue were recorded; however, the conditions caused by hypertrophy
of the styloid process turned out to have disappeared. In a month, limited mobility and sensation in the right part of the tongue resolved spontaneously.

Conclusions

Surgical treatment of Eagle's syndrome is associated with a risk of cranial nerve palsies (V, VII, IX and X), which can lead to tongue impairment and swallowing disorders. These symptoms, however, are mainly reversible and do not affect patient's health in the long term.

[1317] Cerebral abscesses as a rare and severe complication of a paediatric acute rhinosinusitis.

Authors: Jakub Jędrychowski
Affiliation: Department of Paediatric Otolaryngology, Medical University of Warsaw
Trustee of the paper: MD Maria Wolniewicz

Corresponding author: Jakub Jędrychowski (jakubjedrychowski@gmail.com)

Background
Acute rhinosinusitis is one of the most common diagnoses in children. In the post-antibiotic era most bacterial cases are self-limiting. However, we still observe severe complications, which are classified as local, intraorbital (e.g. orbital cellulitis, orbital abscess) and intracranial (e.g. cerebral abscesses, meningitis). They require intensive specialist treatment, sometimes including surgical intervention, as they may be life-threatening, like a case described below.

Case report
15-year-old male patient presented to his GP with headache and mucous rhinorrhoea since month, which became purulent 10 days before examination. He received amoxicillin and intranasal steroids with temporal improvement. Seven days later, due to the persisting strong headache and a sudden paresis of the left lower extremity, he was admitted to the Paediatric Otolaryngology Department. Laboratory blood tests showed slightly enhanced inflammation markers, high D-dimers level, prolonged INR and low factor VII level. His PCR test for COVID-19 was positive. CT scan of the head with contrast on admission showed massive inflammatory changes in the right maxillary and both frontal sinuses, together with cerebral abscesses in the right frontal lobe and thrombosis of the right transverse and the right sigmoid sinuses. He was diagnosed with complicated rhinosinusitis. Pharmacological treatment consisted of a wide range antibiotic therapy (vancomycin, metronidazole, ceftriaxone), enoxaparin, dexamethasone and factor VII substitution. The patient was qualified for endoscopic sinus surgery, Beck's puncture and neurosurgical procedure with abscesses' drainage. The microbiological results showed growth of Streptococcus intermedius cultures and the treatment was modified to meropenem (according to the antibiogram), finally changed to crystal penicillin due to an allergic reaction. Follow-up investigations confirmed abscesses' regression and clinical improvement was observed.

Conclusions
Despite the ubiquity of rhinosinusitis in children's population severe complications are rare. However, they occur and require specialist intensive treatment. The awareness of possible risks of an inaccurate or delayed treatment and the pace of its progression leading to the development of its complications is essential, as it may even be life-threatening. Early diagnosis, proper treatment and regular follow-up prevent in most cases from the development of severe intracranial complications.

[1332] An ectopic salivary gland as a potential diagnosis of a tonsillar arch lesion in a pediatric patient: a case study.

Authors: Maria Rutowicz, Paula Piórkowska
Affiliation: Medical University of Warsaw, Students' Research Group of Pediatric Otorhinolaryngology "OTORHINO" in the Department of Otorhinolaryngology at the Pediatric Clinical Hospital of MUW
Trustee of the paper: Maria Wolniewicz, MD

Corresponding author: Maria Rutowicz (ma.rutowicz@gmail.com)

Background
Ectopic salivary glands are a rare condition, in which salivary gland tissue is located outside its anatomical sites. Typically, they are found along sternocleidomastoideus muscle but other locations of the head and neck region are also reported, such as pituitary gland, ear, cervical lymph nodes. Like normotopic salivary glands, they can be affected by their classic pathologies, like inflammation or carcinogenesis.

Case report
A 7-year-old boy presented to the Department of Pediatric Otorhinolaryngology with the exacerbation of symptoms that appeared 2 weeks prior. These symptoms included hoarseness, subtle dysphonia, hypersalivation, dysphagia and globus sensation. He denied pain or dyspnea. In the ORL examination a red globular pedunculated lesion with the diameter of 1cm was found in the right posterior tonsillar arch. The patient's mother declared that some lesion in the same location had already been detected within the past several years. Since then, the pathology was under observation during laryngological follow-up visits after atretic external ear canal treatment. A CT scan of the head was performed but, because of some technical problems, it's result was inconclusive. The decision of surgical excision was made. The histopathological examination showed an ectopic salivary gland that was totally excised.

Conclusions
In the area of the palatine tonsils and arches we may encounter various pathological masses. The differential diagnosis should include anomalies like hypertrophic tonsil, peritonsillar abscess or Hodgkin or non-Hodgkin lymphoma. Since the heterotopic salivary gland tissue is one of the least prevalent among possible interpretations, they can raise a major diagnostic challenge to the clinicians. As our case shows, the histopathological examination is crucial in final determination of the nature of the lesions.

[1342] Neuroflow as an audiological diagnostic method for patients with CAPD and similar disorders.

Authors: Julia Dwornik
Affiliation: Student Scientific Audiological and Phoniatric Club, Department of Otolaryngology, Pediatric Hospital of Medical University of Warsaw, Poland
Trustee of the paper: dr n. med. Andrzej Senderski, dr hab. n. med. Lidia Zawadzka-Głos

Corresponding author: Julia Dwornik (juliaromeo@vp.pl)

Background
CAPD (Central Auditory Processing Disorders) are a group of disturbances in which the brain has difficulties with analyzing the sounds despite no damage to the peripheral hearing organ. Their symptoms include trouble with telling the characteristic differences among similar sounds, understanding what is said, coping with suppression of background noise and recognizing where a sound is coming from. CAPD is closely related to pedagogical and speech therapy difficulties.

Case report
The clinical case under consideration is a male patient who is on the autism spectrum and was diagnosed with disorders of higher auditory functions accompanied by auditory hypersensitivity. A therapeutic program using Neuroflow auditory training was planned based on Neuroflow diagnostic tests and observation of the patient's behaviour during those tests. Therapy has been undertaken.

Conclusions
As a result of the Neuroflow therapy auditory functions have improved significantly. It is recommended to continue Neuroflow auditory training to strenghten the achieved progress. Our novel Neuroflow therapy proved extremely useful in a case of a patient in autism spectrum and resulted in many improvement in his everyday life. It is easy to use, doesn't require specialized equipment and can be carried out from everywhere.

[1379] Endoscopic removal of an intranasal ectopic tooth in an adult: a case report

Authors: Radvilė Raubaitė
Affiliation: Vilnius University, Faculty of Medicine, Institute of Odontology
Trustee of the paper: MD Donata Šukytė-Raubė, MD Dalius Matkevičius

Corresponding author: Radvilė Raubaitė (radvileraubaite@gmail.com)

Background
An aberrant tooth can be found in sites outside of the oral cavity and can be a supernumerary, deciduous, or a permanent tooth. The presence of supernumerary or ectopic teeth is not an uncommon fact, which occurs in 1% of the general population. The ones that have been reported include the mandibular condyle, coronoid process, orbit, palate, nasal cavity, and maxillary antrum. Intranasal tooth represents a small portion of all reported cases of the ectopic tooth and is a rare phenomenon. The cause of intranasal eruption of teeth is unclear: trauma, infection, and abnormal development probably play a significant role. The identification of such teeth can be important since they have the potential to cause considerable morbidity.

Case report
A 45-year-old Caucasian male presented with chronic complaints of the right-sided nasal obstruction, rhinorrhea, snoring and bad smell in January 2021 in the department of Otorhinolaryngology. The patient could not tell when dyspnea started, reported that both rhinorrhea and bad smell get more intensive in winter. The patient has been using a variety of nasal sprays with no relief of symptoms. A facial trauma in childhood (5 years old) was recorded in his medical history. Upon fiberoptic examination of the nose, a hard foreign body with a tooth-like bony structure on the floor of the right nasal cavity was found. The patient underwent an endoscopic intranasal removal of the ectopic tooth without complications. No postoperative epistaxis appeared. During the follow-up visits (1 month, 6 months, 1-year post-op) the patient reported complete resolution of the preoperative symptoms.

Conclusions
The intranasal ectopic tooth is a rare finding although potentially harmful when left untreated. It may cause significant morbidity such as epistaxis, paranasal sinusitis, nasal septal deviation, nasal septal abscess, and nasal-oral fistula. When an intranasal ectopic tooth is surgically removed, the patient's quality of life improves. Extraction of the intranasal tooth under endoscopic guidance has the advantages of good illumination, clear visualisation and precise dissection.

[1429] Chronic otitis media with cholesteatoma.

Authors: Karolina Markusiewicz, Agata Marszałek, Adam Mróz, Aleksandra Szczepanik
Affiliation: Medical University of Warsaw
Trustee of the paper: dr n. med. Eliza Brożek - Mądry

Corresponding author: Karolina Markusiewicz (12karolina21@gmail.com)

Background
Chronic otitis media with cholesteatoma is a serious type of chronic otitis media. It may present with various complications, ranging from mild to severe. Especially threatening for the patient are intracranial complications, including brain abscess. It is a rare condition, requiring specialized surgical intervention and a multi- specialized approach.

Case report
A 64-year-old patient was admitted to the hospital with a diagnosis of otitis media. Before admission he lost his conscience in the bathroom, had an epileptic attack and there was no contact with him. Computer Tomography (CT) revealed a state after a left craniotomy with a possible perforation to the middle fossa of the cranium. A growth in left temporal lobe was detected, which had a loss of densivity and so an abscess was suspected. Magnetic Resonance Imaging (MRI) showed intracerebral abscess within the temporal lobe and the puss coming from it. After the diagnosis of exacerbation of chronic otitis media with cholesteatoma with intracranial complication the patient was qualified for a surgery and was given antibiotics i.v. After operation, on a CT scan, a loss of pneumatization was observable as well as clues for puss. After that, the patient was in a changing general condition, and he developed a peripheral paralysis of cranial nerve VII. Since then a gradual regression of the disease was observed.

Conclusions
Chronic otitis media with cholesteatoma is an exceptionally serious entity and may result in various complications, both temporal and intracranial. As for temporal, it may involve a peripheral paralysis of cranial nerve VII and inflammation of the surrounding tissues. Intracranial otherwise, may include brain abscess. This life-threatening condition may require a precipitous surgery and extended antibiotic therapy.

Lifestyle Medicine & Public Health

Date: 7th May 2022, 8:30 AM

Coordinators:
Aleksandra Żuk
Elena Sztemberg

Patronage:

Patronat Polskiego Towarzystwa Medycyny Stylu Życia

POLSKIE TOWARZYSTWO medycyny stylu życia

Konsultant Krajowy w dziedzinie Zdrowia Publicznego

dr hab. n. med. Jarosław Pinkas

Polskie Towarzystwo Nauk Żywieniowych

PTNŻ

[1143] Availability of Cardiodiabetological Drugs in Poland during the First Year of COVID-19 Pandemic: Retrospective Study

Authors: Bartosz Nowak
Affiliation: Department of the Treatment of Obesity and Metabolic Disorders, and of Clinical Dietetics, Poznan University of Medical Sciences, Poznan, Poland
Trustee of the paper: Mikołaj Kamiński, MD

Corresponding author: Bartosz Nowak (poz.bartosznowak@gmail.com)

Introduction
Cardiovascular diseases are the leading reason for preterm morbidity in Poland. Good control of chronic disease relies on regular usage of prescribed drugs. There was a fear that COVID-19 pandemics could result in a shortage of supplies of some drugs.

Aim of the study
We aimed to analyze if the COVID-19 pandemic resulted in the availability drop of different cardiodiabetological medicaments. Special attention was put to combined therapies and to investigate the general availability of these drugs.

Materials and methods
Data were obtained from the Polish startup company GdziePoLek regarding the availability of 121 cardiodiabetolocigal drugs divided into 23 separate categories in Polish pharmacies. The period of the analysis was limited from 1 January 2019 to 31 December 2020. The threshold of a 20% decrease of median availability was set to found drugs with the most severe drop in availability during the COVID-19 pandemic. We also identified medicaments with a median availability of less than 50%.

Results
We identified two drugs with the most severe drop in availability level during COVID-19 pandemics: acenocoumarol (decrease by 52.0%) and nitrendipine (decrease by 98.3%). In 2019 and 2020, 27 of 121 drugs had a median availability lower than 50%. The limited availability concerned the most novel agents and polypills, mostly
non-insulin antidiabetic drugs.

Conclusions
The decrease in drug availability in Poland was not as severe as expected. Accessibility to some novel non-refunded medicaments is limited.

[1172] LGBT+ patients experiences and expectations towards healthcare in Poland

Authors: Weronika Caban, Marzena Dacewicz
Affiliation: Medical University of Warsaw
Trustee of the paper: dr. Antonina Doroszewska

Corresponding author: Weronika Caban (weronika.j.caban@gmail.com)

Introduction
Available data suggest, that symbol of acceptance for LGBT+ community would increase the sense of safety among this group of patients. Public opinion polls show that attitudes towards LGBT+ people are very diverse. Therefore, the issue of treating LGBT+ patients in healthcare facilities is particularly important.

Aim of the study
The aim of the study was to test the hypothesis of possible positive impact of the LGBT+ acceptance symbol in a medical facility. Another aim of the study was to learn about the experiences and expectations of this group of patients towards medical staff.

Materials and methods
A research survey was conducted online, the respondents were recruited by social media. 105 LGBT+ people completed the questionnaire. Participants were asked about their experiences with the Polish health care system and their expectations towards it.

Results
The hypothesis about the declared positive impact of the LGBT+ acceptance symbol in a medical facility was tested and confirmed. The article contains also quantitative and qualitative description of experiences with health care and expectations towards it. According to the results, the most frequently indicated expectations were: the use of an inclusive language and not assuming heteronormative orientation and/or cisgender identity (93% of respondents).

Conclusions
An LGBT+ acceptance symbol could positively impact this group of patients. Further experimental studies are needed to discover whether this effect would replicate in a real-life medical setting. Inclusive language and considering non-heteronormative/non-cisgender perspectives are expected by LGBT+ patients and therefore should be included in medical education.

[1268] The lactase gene variants and dairy intake amongst Polish population with obesity

Authors: Izabela Garstka, Dominika Kurpiewska, Gabriela Jastrzębska, Małgorzata Wrzosek
Affiliation: Department of Biochemistry and Pharmacogenomics, Faculty of Pharmacy, Medical University of Warsaw and Center for Preclinical Studies, Warszawa, Poland
Trustee of the paper: Małgorzata Wrzosek PhD

Corresponding author: Izabela Garstka (garstkaiza@gmail.com)

Introduction
The lactase enzyme is responsible for the digestion of milk sugar lactose and is encoded by the lactase (LCT) gene. The LCT variant -13910C>T has been shown to affect adulthood lactase activity and is associated with lactose intolerance in different ethnic groups. In addition, the LCT gene is emerging as a new candidate gene related with obesity and related disorders.

Aim of the study
The aim of the presented investigation was to determine the prevalence of LCT-13910C>T genotypes in Polish population and to describe the association of LCT genetic variants with dairy product consumptions and metabolic parameters.

Materials and methods
The study involved a population of 424 individuals with obesity. Measurements of anthropometric parameters, blood pressure, fasting blood glucose, insulin concentration, insulin resistance (HOMA-IR) were recorded. Genotyping for LCT-13910C>T was performed using Viia 7 system (Thermo Fischer Scientific,USA) and TaqMan Assays. The prevalence of LCT-13910C>T genotypes was compared by using $\chi 2$ analysis. Insulin was determined by enzyme-linked immunosorbent assay (ELISA), and the homeostasis model assessment for insulin resistance (HOMA-IR) was calculated using these values.

Results
The mean age was 43.8±11.2 years and the mean body mass index (BMI) 42.8±6.6 kg/m2. Prevalence of the LCT −13910 C>T genotypes were: CC 37.0% (n = 157), CT 45.6% (n = 189), and TT 18.4% (n = 78). This distribution was in Hardy–Weinberg equilibrium (P = 0.115). The CC genotype was associated with lower milk or dairy product consumption in the whole population. In addition insulin, glucose levels, and HOMA-IR were lower in C allele carriers. We did not detect a significant association between LCT −13910 C>T variant and fat mass, weight, BMI, and blood pressure in whole group.

Conclusions
The LCT-13910C>T gene variant is associated with lactose intolerance in Polish adults with obesity. Individuals with CC genotype often avoid dairy consumption and have better glucose metabolism.

[1298] Are rural residents able to recognize colorectal cancer symptoms?

Authors: Julia Pikul
Affiliation: Students' Scientific Organization of Cancer Cell Biology, Department of Cancer Prevention, Medical University of Warsaw, Warsaw, Poland
Trustee of the paper: dr hab. Anna Badowska-Kozakiewicz

Corresponding author: Julia Pikul (julia.pikul@onet.pl)

Introduction
Colorectal cancer (CRC) is one of the most predominant malignancies among adult population. Identification of premalignant lesions and detection of asymptomatic early-stage malignancies result in decreased incidence and mortality. In Poland CRC screening programmes encompass colonoscopy; nevertheless, people included in the risk group submit to testing unwillingly. The World Health Organization (WHO) estimated that 40% of cancers could be avoided by prevention and 40% could be cured assuming early detection.

Aim of the study
To evaluate the level of young adults' knowledge concerning CRC and to split to groups depending on residency.

Materials and methods
The knowledge was examined with the survey shared in social media between February and March 2021. Received data was completely anonymous and the participation was voluntary. The survey consisted of 21 questions (20 closed and 1 open). Statistical analysis was conducted with level of significance equal $p \leq 0.05$.

Results
Respondents (n=1546) were mostly female (81.4%), living in a city, with the population over 500 thousand (36.8%). The mean age of the participants was 23.1 (standard deviation (SD): 3.71, range: 18-35) years. We indicated that people from rural areas present a much lower level of knowledge and awareness concerning CRC in comparison to citizens, especially from large cities. One-way analysis of variance revealed that the place of residence differentiates knowledge about CRC ($F=6.91$, $p<0.001$). Post-hoc tests confirmed that village inhabitants scored fewer points in comparison to the inhabitants of a city ($p<0.001$) and a big city ($p=0.001$). Moreover, inhabitants of medium-size cities received fewer points than big city occupants ($p=0.011$). Analysis of particular questions proved that village inhabitants chose fewer risk factors and CRC symptoms than a city ($p=0.012$, $p=0.016$, respectively) and big-city occupants ($p<0.001$).

Conclusions
The knowledge gap in rural inhabitants group is significantly higher than in residents group, who come from larger places. Especially the lack of knowledge about CRC possible symptoms and risk factors in the rural group is frightening. Considering residence, disparities in access to information, screening, and prevention techniques should be reduced. Information about one of the most common cancers should be more available and spread. In the future, it may contribute to reducing the number of colorectal cancer morbidity and mortality.

[1339] How the COVID-19 vaccination affected the quality of sleep, exercise, nutrition, and mental health of Polish adult population? The survey.

Authors: Katarzyna Ulaszewska, Alicja Jodczyk
Affiliation: Students' Scientific Group of Lifestyle Medicine, 3rd Department of Internal Medicine and Cardiology, Medical University of Warsaw
Trustee of the paper: Daniel Śliż

Corresponding author: Katarzyna Ulaszewska (ulaszewska.k@gmail.com)

Introduction
The topic of vaccination against Covid-19 is still controversial among the public. Despite the passing of time, part of the population is still unvaccinated and/or unsure of the vaccination effects on quality of life and health.

Aim of the study
To assess the impact of vaccination against Covid-19 on the lifestyle of vaccinated polish population a survey was conducted. Survey focused on factors such as sleep, exercise, nutrition and mental health/comfort.

Materials and methods
The survey consisted of 29 questions about the lifestyle of respondents, education status, economical status, and several statements about vaccination itself. The survey was conducted between 13 January 2022 and 14 February 2022, through different social media channels. A total of 7018 adult Poles completed questionnaire: 5396 women, 1575 men, while 47 did not specify their gender; the mean age was of 48 years (varying from 18 to 68). Among the studied population 5742 persons (81,8%) were vaccinated against Covid-19 [VAC] and 1276 (18,2%) were not vaccinated [NotVAC].

Results
The most interesting result of the study was the self-assessment of the mental health/comfort before and after vaccination. The 28,4% (n = 1629) of VAC replied that their mental health improved after vaccination, of which as many as 11,2% indicated a maximum improvement of +5 (on a scale from -5 to +5). The 7,8% (n = 449) replied that mental health had deteriorated after vaccination. In the same study, participants were asked about the impact of the pandemic period on the mental health. Here 68,9% (n = 3957) of VAC assessed it negatively, however as much as 31%.5 (n = 1248) declared the improvement of their mental condition after vaccination. Among other effects of Covid-19 vaccination on sleep, exercise and nutrition, the responses indicated slightly negative impact: sleep (6,1% deterioration, 4,8% improvement), physical activity (7,5% deterioration, 6,3% improvement), nutrition (4,2% deterioration, 4,1% improvement).

Conclusions
The pandemic has caused a significant drop in quality of life including mental comfort, but the possibility of vaccination against Covid-19 improved this status to some extent.

[1341] Influence of visfatin's polymorphisms rs4730153 and nesfatin's rs1330 on body mass

Authors: Agata Macionga, Anna Gogola, Małgorzata Poręba, Grażyna Waśka
Affiliation: Student Research Group at the Department of Internal Medicine, Diabetology and Nephrology Medical University of Silesia in Katowice, Faculty of Medical Sciences in Zabrze
Trustee of the paper: dr hab. Mirosław Śnit, MD, Nikola Szweda-Gandor, MD, PhD

Corresponding author: Agata Macionga (agamacionga@gmail.com)

Introduction

Visfatin, being an adipocytokine, is a protein encoded by the PBEF gene, which is located on the long arm of chromosome 7 (7q22.2). Visfatin is produced by a variety of cells in our body, including adipocytes, hepatocytes, and immune system cells. Previous research findings indicate that visfatin may affect glucose and lipid metabolism and be involved in the development of overweight and obesity.

Aim of the study

The aim of the study was to assess the relationship between the polymorphisms of the visfatin's gene rs4730153 and rs1330 the prevalence of overweight and obesity as determined by the BMI scale.

Materials and methods

The study included 285 adult patients (153 women, 132 men) from Southern Poland who visited the primary care clinic. Patients' body weight was measured, BMI was calculated, and venous blood was collected for genetic testing. The Real-time PCR method was used to amplify the isolated DNA material of the subjects. The genotyping of visfatin's gene rs4730153 and rs1330 polymorphisms were performed with fluorescently labeled probes using the TaqMan Predesigned SNP Genotyping Assay.

Results

The study showed no statistically significant correlation between the single nucleotide polymorphisms rs4630153, rs1330 and BMI.

Conclusions

The gene polymorphisms of the rs4730153 and rs1330 probably do not significantly affect excess body weight. Further studies are necessary, in particular with regard to the remaining single nucleotide polymorphisms of the visfatin's gene. In addition, we suggest examining the effect of other adipocytokines that may be related to the pathogenesis of metabolic disorders.

[1359] The attitude to vaccination against COVID-19 in group of Polish non-vaccinated hospitalized patients with COVID-19

Authors: Jan Sobieraj, Szymon Barczak
Affiliation: Department of Internal Medicine, Hypertension and Vascular Diseases, Medical University of Warsaw, SKN Pressor
Trustee of the paper: Piotr Sobieraj

Corresponding author: Jan Sobieraj (sobieraj.janek@gmail.com)

Introduction
Vaccines against COVID-19 are widely available in Poland and reduce the risk of the disease, its severe course and death. However, relatively low vaccination rate against COVID-19 in Poland is observed. The reasons for COVID-19 non-vaccination remain unknown.

Aim of the study
Our study was aimed to evaluate attitude to vaccination against COVID-19 in non-vaccinated patients hospitalized for COVID-19.

Materials and methods
The study included consecutive COVID-19 unvaccinated patients hospitalized for COVID-19 who agreed to participate in the survey. Patients who, despite adequate oxygen therapy, had breathlessness that made it difficult to speak were excluded from the study. The disease was confirmed in all patients on the basis of the clinical diagnosis and the results of PCR and/or antigen tests. All participants were asked about the reason for non-vaccination, the impact of hospitalization on their attitude to vaccination and recommending COVID-19 vaccination after discharge from the hospital, assessment of the severity of COVID-19 by the patient, the source of information on vaccinations against COVID-19. The study was approved by local Bioethics Committee.

Results
Finally, 41 subjects (23 female) aged 62 ± 16.2 years were enrolled in the study. Only 7 subjects assessed their health condition as bad or very bad. As main source of information of COVID-19 most often subjects indicated doctors (24.4%), TV news (24.4%), friends and family (24.4%). In study group 2 subjects were hospitalized due to COVID-19 in past. As main reason of non-vaccination 24.4% subjects indicated that they believed to have a disease that is a contraindication to vaccination, 22% had fear of vaccination complications, 14.6% were convinced that they are healthy people not at risk from COVID-19, 7.3% questioned the effectiveness of the vaccination and 7.3% withdrew from vaccination due to peer pressure. Despite hospitalization, 36.6% of subject still were not convinced of vaccination. Most of vaccine opponents self-assessed course of the disease as mild (61.9%) vs. moderate or severe (38.1%), p=0.002. Only 48.7% subjects decided to recommend vaccination against COVID-19 after discharge while 4.9% subjects declared that they will receive vaccination against COVID-19.

Conclusions
Even hospitalization does not convince all unvaccinated against COVID-19 towards effective prevention of this disease. Its more severe course may convince the patient to vaccinate.

[1378] The impact of hypertension and diabetes on the dental extraction procedure: a survey of dentists' knowledge

Authors: Radvilė Raubaitė
Affiliation: Vilnius University, Faculty of Medicine, Institute of Odontology
Trustee of the paper: Dr. Rūta Rastenienė

Corresponding author: Radvile Raubaite (radvileraubaite@gmail.com)

Introduction
A significant number of cases involving patients with systemic diseases (SD) where dental extraction procedure (DEP) is needed are referred from primary dental care. With many treatments performed within oral surgery departments considered to be routine procedures, services to more critical patients may be delayed. The reluctance to perform DEP on patients with SD may be due to lack of confidence in knowledge on how to deal with some of the most common postoperative complications such as postoperative bleeding, delayed wound healing and hypoglycaemic shock.

Aim of the study
The aim of the study was to assess the knowledge of dentists of the influence hypertension and diabetes have on DEP, determine factors leading to one's better knowledge and assess the need for practical guidelines on the topic.

Materials and methods
A survey was presented to a voluntary response sample of Lithuanian dentists who were members of two of the most popular Facebook groups for Lithuanian dentists. All responses were collected electronically due to Covid-19 restrictions limiting access to dental clinics. Statistical data analysis was performed using IBM SPSS Statistics 23. The threshold for statistical significance was set at $p \leq 0.05$. Student's t, Shapiro – Wilk tests, Bonferroni adjustment, Kolmogorov-Smirnov criteria were used for data analysis.

Results
A total of 73 people participated in the study. Dentists, including dental specialists, answered less than half of the theoretical questions about hypertension and diabetes impact on DEP correctly (39,9 %). Oral surgeons scored significantly higher than the remaining dentists ($p = 0.04$). The knowledge of dentists with 0-5 years of experience was significantly better than those with 16-20 years of experience ($p = 0.001$). The knowledge of the respondents who graduated after 2005 was significantly better than those who graduated earlier ($p = 0.0198$). Dentists who attended conferences and/or training courses at least once a year scored higher than those who have not done it in a long time ($p = 0,014$). Most respondents (93,2%) indicated the need of practical guidelines on the topic.

Conclusions
The knowledge of dentists and dental specialists was similar, and the knowledge of oral surgeons was statistically significantly better. Participating in conferences and/or training courses related to minimal surgical interventions at least once a year contributed to one's better knowledge. There is a significant need for practical guidelines on this topic.

[1407] How did the level of women's knowledge about the effects of alcohol use during pregnancy change between three last generations?

Authors: Emilia Piotrkowicz
Affiliation: Medical University of Warsaw
Trustee of the paper: Ass. Prof. Iwona Szymusik, MD, PhD

Corresponding author: Emilia Piotrkowicz (em.piotrkowicz@gmail.com)

Introduction
Over the past several decades numerous studies on teratogenic effects of alcohol have been conducted. Since 1973, when Fetal Alcohol Syndrome (FAS) term was introduced, major impact has been put onto raising awareness about the negative effects of prenatal alcohol exposure.

Aim of the study
The study aimed to compare the level of knowledge about the risks of alcohol consumption during pregnancy between three last generations of women in order to assess the effectiveness of educating future mothers about FAS.

Materials and methods
A questionnaire survey was conducted among 471 women of reproductive age (15-49 years). Data were collected from 03/02/2022 to 03/03/2022. Questionnaire consisted of 27 closed-ended questions regarding demographics and knowledge about teratogenic effects of alcohol. The level of knowledge was determined based on average number of correct answers to 9 questions. The data were analyzed using Chi-squared and ANOVA Kruskal-Wallis tests.

Results
Out of all women participating in the study 164 (35%) belonged to Generation Z (15-25 years), 262 (55%) to Generation Y (26-41 years) and 45 (10%) to Generation X (42-49 years). 257 (55%) respondents were pregnant before. The average score for questions about the effects of alcohol use in pregnancy was the highest for Gen Y women (7,55 points) and the lowest for Gen X women (6,96 points). Women from Gen Z scored 7,27 points on average. ANOVA Kruskal-Wallis test was performed with p=0,07. 76% of Gen X, 81% of Gen Y and 67% of Gen Z women heard that having an occasional grass of wine during pregnancy is safe (p=0,01). 24% of Gen X, 10% of Gen Y and 16% of Gen Z women admitted to drinking alcohol during pregnancy (p=0,04). 5% of Gen X, 10% of Gen Y and 28% of Gen Z women declared being asked about alcohol consumption in pregnancy and informed about its teratogenic effects by their doctor (p=0,01). More than 12% of Gen X women declared being encouraged by a healthcare professional to drink alcohol occasionally when pregnant. In Gen Y and Gen Z no woman declared this fact (p=0,00).

Conclusions
The level of women's knowledge about the risks of alcohol consumption during pregnancy suggests that the methods of educating women about fetal alcohol spectrum disorders are less effective in recent years. Even though with each subsequent generation healthcare improves its role in fetal alcohol spectrum disorder prevention, still not enough women are being asked about alcohol use and educated about its teratogenic effects by healthcare professionals.

[1469] Attitudes towards COVID-19 vaccines among people aged 18-65 in Poland

Authors: Aleksandra Hyży
Affiliation: Pediatrics and Gastroenterology & Nutrition Department, Medical University of Warsaw
Trustee of the paper: prof. Aleksandra Banszkiewicz, MD, PhD

Corresponding author: Aleksandra Hyży (amhyzy@gmail.com)

Introduction
Vaccines are considered to be one of humanity greatest achievements in the area of disease prevention.

Aim of the study
The aim of the study was to assess the attitudes towards COVID-19 vaccines among people aged 18-65 in Poland.

Materials and methods
266 subjects took part in the study, 262 were qualified. The main inclusion criteria were the age between 18 and 65, proficiency in Polish language and ability to use electronic device on which the questionnaire was presented. Original on-line questionnaire was used for the study. The results were evolved with utilisation of MS Office and StatSoft Statistica 13.1.

Results
The study has shown that men, people with high monthly earnings as well as the vaccinated ones had significantly higher level of knowledge about COVID-19 vaccines ($p<0,04$, $p<0,0001$ and $p<0,0001$ respectively). Participants motivated their decision of taking the vaccine with wanting to protect themselves (78,7%) and their friends and families (77,8%) from the disease and its complications as well as wanting the pandemic to finish as soon as possible (73,1%). Unvaccinated subjects significantly more often lived in rural areas and small towns ($p=0,019$). Most common reasons for not taking a vaccine were waiting for one's place in the queue according to the National Vaccination Programme (42,9%), wanting to wait for studies showing better efficacy and safety of the vaccines (27,9%) and disbelief in vaccines' safety (26%). Scientific publications (51,5%), social media (40,5%) and television (36,6%) were the most common sources of information about COVID-19 vaccines. The older the subjects were, the less positive attitudes towards the pandemic and the vaccines were shown. Unmarried subjects (most often students) have shown more positive attitudes towards vaccines rather than the single, married and divorced ones or widows (p between 0 and 0,016). Subjects living in rural areas and small towns presented significantly less positive attitudes towards the pandemic and the vaccines. The higher the participants' monthly earnings were, the significantly more often they claimed that COVID-19 vaccines are safe and presented positive attitudes towards them (p between 0 and 0,033). Vaccinated subjects have shown more positive attitudes towards vaccines than the unvaccinated ones ($p=0,0$).

Conclusions
Particularly intensive education programmes about COVID-19 vaccines should be promoted among the elderly, people living in rural areas and small towns, as well as people with lower monthly earnings.

Nephrology & Transplantology

Date: 6th May 2022, 12:30 PM

Coordinators:
Anna Burban
Dorota Słupik

[1288] Montreal Cognitive Assessment (MoCA) for Cognitive Screening in Patients with IgA Nephropathy

Authors: Marija Halturina1, Anna Popova1,2,3

Affiliation: University of Latvia, Faculty of Medicine
Trustee of the paper: Dr.Anna Popova

Corresponding author: Marija Halturina (marija.halturina@gmail.com)

Introduction

IgA nephropathy (IgAN) is the most common form of glomerulonephritis worldwide and one of the causes of chronic kidney disease (CKD). It occurs at any age, the peak incidence is in the second and third decades of life. Patients with CKD are at an increased risk (compared with the general population) of both dementia and its prodrome, mild cognitive impairment, which are characterized by deficits in executive functions, memory and attention.

Aim of the study

The aim of the study was to investigate the association of cognitive decline with renal function and other possible risk factors in patients with IgAN.

Material and methods

This was a prospective study, that took place from January 2020 till January 2022. Patients with IgAN were included. Diabetes mellitus, oncology, acute inflammation processes were exclusion criteria. Demographic, anamnestic, clinical, laboratory data for renal function evaluation were collected. GFR was calculated using MDRD Equation. Patients were assessed with a MoCA. Results of MoCA have been compared with potential risk factors.

Results

Seventy six patients were included in the study. The mean age of the participants was 41.67 ± 10.62 years (IQR 35-47.75; range, 21-65), with predominance of male sex (64.5%), mainly with higher education (43.4%). Dialysis was performed in 7 patients, transplantation in 14 patients. The average duration of illness was 60 months ± 104.8 (IQR 36-120, range 1-456 months/38 years). Average GFR 53 ± 35.6 was 53 (IQR 27.25-93.5, range 3-131) ml/min/1,73m2, urea 9.1± 48.3(IQR 6.7-14.2, range 4-42.6). Patients did not have anemia, average hemoglobin 136± 15.3. MoCA ≤ 26 was observed in 43.4% of the patients. Most of the patients drank alcohol 1-3 times a month (40.8%). The MoCA correlated weakly with the patients age ($p=0.024$, $r=0.25$). Urea level correlated with abstraction task($p=0.017$, $r=0.21$). The worst results were seen in memory and visuospatial task. No other correlations were found between MoCA test results and mentioned analysed parameters.

Conclusions

According to the results of the study exists weak association of cognitive function with the age of patients. Also correlation between urea level and patient abstract intellection was found. No correlations have been found between GFR decline and renal replacement therapy with MoCA score. Education, alcohol consumption, or duration of illness did not significantly affect test scores.

[1295] Retrospective analysis of high risk corneal transplantations

Authors: Weronika Bartos, Mateusz Biszewski, Natalia Konarska, Karolina Urbańska, Piotr Więsyk
Affiliation: Medical University in Lublin
Trustee of the paper: MD PhD Tomasz Chorągiewicz

Corresponding author: Weronika Bartos (weronikabartos3@gmail.com)

Introduction

Corneal transplantation has been proven to be the most effective therapy for irreversible loss of corneal opacity. Standard planned keratoplasties have a high success rate. Sometimes keratoplasty has to be performed urgently. Leading causes of urgent keratoplasties are: infections unresponsive to conservative treatment, traumas or inability to examine the structures of the eyeball due to corneal opacity. Some keratoplasties are more susceptible to rejection due to conditions such as: active inflammation at the time of surgery, presence of ocular surface diseases, rejection of previous grafts or clinical history of eye surgeries, particularly glaucoma surgery. These are so-called high-risk corneal transplantations.

Aim of the study

Analysis of indications and success rate of treatment in high-risk corneal transplantations

Material and methods

Retrospective analysis of documentation of patients after urgent corneal transplantations performed between 2018-2022.

Results

We analyzed documentation of 86 patients - 46 women and 40 men after urgent corneal transplantations. Out of them we selected a group of 34 patients with the specific risk factors for rejection and/or graft failure. The average patients' age was 60,7 years. 49 corneal transplantations were performed – 38 penetrating keratoplasties, 4 penetrating keratoplasties with facoemulsification of the lens, 3 penetrating keratoplasties with vitrectomy, 3 mini-keratoplasties, and 1 penetrating keratoplasty with facoemulsification and posterior chamber intraocular lens implantation. Leading indications for the first keratoplasty were: infections (56%), prior graft's failures (15%), ocular traumas (12%) and aseptic corneal perforations (9%). 24 procedures (49%) ended up with a good outcome. Mean time of the observation was 17 months. Re-keratoplasty was performed in 12 patients, 3 of whom had the procedure done twice. The grafts' failures were observed mainly in patients with infection (47%), prior graft's disease (27%) and aseptic corneal perforation (13%). In case of failure the mean time of the graft's survival was 8 months. Mean visual acuity was 0,05 at the start and 0,097 at the end of observation. In 20 eyes (59%) an improvement of visual acuity was noted.

Conclusions

Graft's rejection was observed in 15 cases (31%) of high-risk keratoplasties. It proves the difficulties in managing the high-risk corneal transplantations. The literature claims similar outcomes with rejection episodes occurring in 30%–60% of grafts.

[1316] NR3C1 Glucocorticoid Receptor Gene Polymorphisms in IgA and Membranous Nephropathies

Authors: Michał Pac
Affiliation: Department of Immunology, Transplantology and Internal Diseases, Medical University of Warsaw, Warsaw, Poland
Trustee of the paper: Krzysztof Mucha

Corresponding author: Michał Pac (michalpac10@gmail.com)

Introduction
Glomerular diseases are responsible for approximately 20% of chronic kidney diseases. Glucocorticoid receptor gene (NR3C1) single nucleotide polymorphisms (SNPs) are implicated in interindividual differences in predisposition to autoimmunity and outcomes of immunosuppressive treatment.

Aim of the study
The aim of this study was to evaluate the frequency of three NR3C1 SNPs - rs6198, rs41423247 and rs17209237 - in IgA nephropathy (IgAN) and membranous nephropathy (MN) patients and to evaluate their association with the outcomes and effectiveness of immunosuppressive treatment.

Material and methods
The frequency of NR3C1 SNPs - rs6198, rs41423247 and rs17209237 was evaluated in 72 IgAN patients (34 females, 47%; mean age 33.96±12.03 years), 38 MN patients (14 females, 37%; mean age 42.89±14.37 years) and compared to 175 healthy controls (89 females, 51%; mean age 48.7±17.9 years). To obtain genotypes SNP array-based typing and real-time polymerase chain reactions were performed.
To assess the outcomes of the diseases and the effectiveness of treatment the reduction of proteinuria (g/24h) after 12 months and the estimated glomerular filtration rate (eGFR; mL/min/1.73 m2) change divided by the observation time (ΔeGFR/year) were measured. When a reduction of proteinuria <1 g/24 h occurred, patients were considered as good responders (GR), otherwise they were classified as bad responders (BR). The eGFR reduction of more than 1 mL/min/1.73 m2/year was considered as a poor outcome and eGFR change equal or lesser than this value was considered as a good outcome. The additional analysis was performed in subgroups receiving steroids.

Results
The frequency of rs41423247 GC genotype was significantly decreased in patients with MN ($p = 0.026$). The frequency of AA genotype of rs17209237 was significantly increased in the GR group comprised of MN and IgAN patients ($p = 0.013$) and in the IgAN GR group receiving steroids only ($p = 0.021$). Carriers of rs17209237 AG genotype had a lesser ΔeGFR/year compared to the major AA genotype ($p = 0.021$) in the group comprised of both IgAN and MN patients. The analysis restricted to patients on steroid treatment showed the significant association between rs17209237 AG genotype and a lesser ΔeGFR/year in MN ($p = 0.026$), as well as, in the group of both MN and IgAN ($p = 0.021$).

Conclusions
The results indicate that NR3C1 polymorphisms may influence treatment susceptibility and clinical outcome in IgAN and MN and should undergo further evaluation.

[1327] In search of the cause of skin lesions and membranoproliferative glomerulonephritis - case report

Authors: Monika Błądek, Justyna Bogdan, Benedykt Baljon
Affiliation: University of Rzeszow
Trustee of the paper: Małgorzata Rodzoń-Norwicz, MD; Agnieszka Gala-Błądzińska MD, PhD

Corresponding author: Monika Błądek (monikabladek01@gmail.com)

Background
A vasculitis is a group of diseases with a different etiopathogenesis and clinical picture depending on the type and size of the affected vessels. Inflammations with an immune system background include mixed spontaneous cryoglobulinemia. It affects the small vessels of the skin and kidneys. A typical feature of its course is the presence in the serum cryoglobulin-like monoclonal or polyclonal IgM antibodies, which form aggregates that accumulate in the vessels and activate the complement system. This disease often manifests itself on the skin in the form of palpable purpura, and also is accompanied by membranoproliferative glomerulonephritis.

Case report
A 59-year-old patient, chronically treated for arterial hypertension, was admitted to the hospital to determine the causes of the swelling visible on the lower legs and skin changes that evolved during her stay in previous hospital. These lesions initially appeared as red spots and then bloody spots on which scabs were formed. There were also ulcers in places. Gradually, the patients' renal parameters increased with progressive oliguria. The patient reported migrating joint pain, weakness, and fatigue. The diagnostics were extended to the histopathological biopsy of the left kidney, which resulted in a highly active image membranoproliferative glomerulonephritis. There were also imaging studies showing splenomegaly. Performed immunological tests for the presence of cryoglobulins in the serum gave a positive result. The clinical picture of the patient, along with the tests performed and the interview obtained, allowed for the diagnosis of mixed spontaneous cryoglobulinemia. The treatment implemented contributed to local improvement in skin lesions on the lower extremities, reduction of edema, weigh loss of 15 kilograms, as well as improvement of renal parameters along with the achievement of normal diuresis. The patient was discharged in good condition with indications for further outpatient treatment.

Conclusions
A correctly assembled interview allows for the start of differential diagnosis. The use of immunological tests in the described case allowed for the detection of cryoglobulins, determination of their type, and the final diagnosis. The availability of various types of tests, as well as extensive knowledge in the field of differentiating data from nosological units, made it possible to make an accurate diagnosis and immediately start treatment.

[1328] PATIENT WITH DOUBLE ORGAN TRANSPLANTATION: LUNG AND KIDNEY GRAFT

Authors: Michalina Strzedulla, Paulina Ziółkowska
Affiliation: Department of Cardiac, Vascular and Endovascular Surgery and Transplantology, Medical University of Silesia in Katowice, Silesian Centre for Heart Diseases, Zabrze, Poland
Trustee of the paper: M. Ochman Md Phd

Corresponding author: Paulina Ziółkowska (paula.ziolkowska268@gmail.com)

Background

Cystic Fibrosis (CF) is a progressive, multiorgan genetic disorder, leading to severe respiratory illnesses. It can be treated by means of the lung transplantation (LTx), which involves lifelong intake of immunosuppressive drugs. That pharmacotherapy has several adverse effects including progressive kidney impairment. In patients with aforementioned complication there is an increased probability of the occurrence of the end stage renal disease and consequently the necessity of kidney transplantation (KTx).

Case report

Case report describes 21-years old male patient, who became in 2018 double LTx recipient because of CF and three years later a kidney recipient in all probability due to the nephrotoxicity of calcineurin inhibitor – based immunosuppressive therapy. At the age of 15, when the patient presented chronic respiratory failure, he was qualified for LTx. After 2 years on national lung transplant waiting list, he underwent orthotopic double LTx. He was discharged in good health after monthlong hospitalisation with the normal kidney function – glomerular filtration rate and the level of serum creatinine were respectively >60ml/min./1,73^2 and 44µmol/l. At the time he was treated in 3-drug immunosuppression based on tacrolimus, mycophenolate mofetil and prednisolone. From October 2019 progressive impairment of kidney function was observed. At the age of 19 the patient presented the acute kidney failure and the dialysis therapy was implemented. In September 2020 the end stage renal disease was diagnosed and consequently the patient was qualified for KTx, which was finally performed in August 2021. He was discharged 3 weeks after KTx in good health. Nowadays, the patient is being treated with the same immunosuppressive therapy as mentioned earlier and he does not require supplemental oxygen therapy as well as the dialysis therapy.

Conclusions

Patients with the CF frequently require double LTx in order to live. However, in cases such as aforementioned patient, immunosuppression based on calcineurin inhibitor, required to maintain the transplanted organ, led to end stage renal disease. The end stage renal disease in patients with previous LTx significantly shortens life expectancy, therefore KTx is an important therapeutic option for patients in order to save their life.

[1436] Calciphylaxis – an underrecognized complication of advanced kidney failure

Authors: Wiktoria Grycuk
Affiliation: Department of Nephrology, Dialysis and Internal Medicine, Medical University of Warsaw
Trustee of the paper: Zuzanna Jakubowska, MD

Corresponding author: Wiktoria Grycuk (wiktoriagrycuk@gmail.com)

Background

Calciphylaxis is a rare, life-threatening disorder that occurs most frequently in patients with end-stage kidney disease treated with dialysis. The initial manifestation typically includes severely painful skin induration progressing rapidly to ischemic skin necrosis. Histologic features include calcification of small-sized vessels of the dermis and subcutaneous tissue. The disease carries a poor prognosis with a 1-year mortality rate of up to 80% with most deaths occurring due to sepsis. The data concerning optimal management are currently lacking.

Case report

An 86-year-old woman was admitted to the Nephrology Department for the evaluation of increasing bilateral lower extremity pain with signs of local inflammation. Her medical history included a long-term chronic kidney disease treated with hemodialysis. Skin examination revealed the palpable purpura accompanied by peripheral edema and red discoloration of the skin. The lesions were extremely tender on palpation with detectable induration. Laboratory findings were remarkable for elevated CRP, PTH, and phosphate levels. The imaging studies, including Doppler ultrasound and CT angiography excluded deep venous thrombosis and acute limb ischemia. The broad-spectrum antibiotic therapy was initially administered for presumed cellulitis but showed no efficacy. The evolution was marked by the appearance of necrotic ulcers with black eschars involving skin and adipose tissue. Based on the overall clinical assessment, the diagnosis of calciphylaxis was established, which was further confirmed by histopathology. Given the extent of necrotic lesions requiring bilateral limb amputation, the patient was disqualified from surgery. The subsequent treatment included daily wound care, opioid-based analgesia, pamidronate, nutritional support, and hemodialysis intensification. Over the next few weeks, the patient's general condition deteriorated and she died one month from the primary diagnosis.

Conclusions

Prompt diagnosis and initiation of treatment for calciphylaxis are essential to improve patients' quality of life and prevent complications. Calciphylaxis should be suspected in the setting of dialysis-dependent patients with painful skin lesions, especially in the presence of risk factors such as hyperphosphatemia, hypercalcemia and hyperparathyroidism. Although there is no approved treatment to date, the interdisciplinary approach, based on supportive management and elimination of predisposing conditions, is currently recommended.

[1459] Effective clinical decision-making at times of uncertainty in the diagnostic process: concomitant fragile X and Churg-Strauss syndromes.

Authors: Katarzyna Giemza
Affiliation: Student Scientific Society of the Department of Nephrology, Dialysis and Internal Diseases, Medical University of Warsaw
Trustee of the paper: lek. Małgorzata Twardowska – Kawalec, lek. Zuzanna Jakubowska

Corresponding author: Katarzyna Giemza (k.m.giemza@gmail.com)

Background
Fragile X syndrome (FraX) is a quite often occurred genetic disorder, characterized by impairment intellectual development and usually diagnosed at preschool age. Eosinophil granulomatosis with polyangiitis (EGPA, Churg-Strauss syndrome), on the other hand, is a very rare condition, with most typically manifesting with asthma, vasculitis, blood eosinophilia and sometimes renal involvement. It mostly occurs in adult patients. Diagnosing this disease often takes time and requires specific examination, however, in a patient with an intellectual deficit this process can be very challenging.

Case report
A 26-year-old man with FraX, moderate intellectual disability and legal incapacitation, was admitted to the Nephrology Department due to rapidly progressive glomerulonephritis (RPGN). For several years, the patient had been treated with inhaled steroids due to sinusitis with nasal polyps. At admission he was euvolemic, with low-grade fever, with no symptoms from the respiratory system. Laboratory tests showed increased renal and inflammatory parameters and decreased hemoglobin. Blood and urine cultures remained sterile. Antibiotic therapy was started without any success. Subsequent studies revealed presence of perinuclear antineutrophil cytoplasmic antibodies (p-ANCA), CT scan of thorax showed mediastinal lymphadenopathy and ground-glass opacity. After long preparation to help the patient and his family give informed consent, a renal biopsy and bronchoscopy were performed with the help of an anesthesiologist. Renal biopsy revealed pauci-immune necrotic glomerulonephritis with active lesions. Bronchoalveolar lavage (BAL) confirmed pulmonary eosinophilia.
In summary, the above diagnosis of Churg-Strauss syndrome was finally established, and immunosuppression treatment was started. This made it possible to stop the progression of the renal insufficiency and hopefully significantly lengthen the time to start renal replacement therapy.

Conclusions
Conducting diagnostics is sometimes challenging, especially in patients with intellectual deficits, when proper history-taking requires more time and effort. Moreover, it also requires also professional preparation of the patient and caregivers. However, the results can be satisfactory for both sides.

[1470] Delayed graft function after renal transplantation and related complications- a case report

Authors: Paweł Szajewski, Paulina Kalman
Affiliation: Student's Scientific Organisation of General and Transplant Surgery „Kindley", Department of General and Transplant Surgery, Medical University of Warsaw
Trustee of the paper: Maurycy Jonas MD, PhD

Corresponding author: Paweł Szajewski (pawelszajewski0@gmail.com)

Background
Delayed graft function (DGF) is defined as the need for dialysis during the first week after transplantation and is a manifestation of acute tubular necrosis (ATN). DGF occurs with about 20% transplants and can lead to faster rejection of the graft.

Case report
The case of a 64-year-old woman who had a kidney transplant for vesicoureteral reflux, with two renal arteries on a common patch. The patient developed a DGF. In the first week after the transplant, she had to undergo dialysis three times. Flow in the pole artery was invisible on Doppler ultrasound. The patient was receiving standard immunosuppressive therapy- tacrolimus, mycophenolate mofetil (MMF) and prednisone, but due to low therapeutic concentrations of tacrolimus, a conversion to cyclosporine (CsA) was made. The toxic effects of MMF have been studied and associated with persistent diarrhoea according to the aetiology of Clostridoides difficile and Cytomegalovirus (CMV). Conversion to everolimus was performed. Serum creatinine levels stabilized and decreased to <3mg/dl from initial values of 5. 8-7mg/dl. During therapy, the patient developed COVID19 infection with 30% pulmonary parenchymal involvement. The patient was discharged at home but was hospitalized after two weeks with creatinine 7. 1 mg/dl. A biopsy of the transplanted kidney showed acute vascular cellular rejection (Banff Classification IIB). Treatment with 250 mg methylprednisolone infusion resulted in a decrease in serum creatinine to 2. 7 mg/dl.

Conclusions
In summary, the DGF contributes directly to the function of graft and subsequent acute rejection. It should also be taken into account that immunosuppressive patients are particularly susceptible to various viral, bacterial and fungal infections and the function of the graft is also impaired by antimicrobial therapies.

[1481] Progression of chronic kidney disease in patient with bipolar disorder due to 30-year lithium treatment

Authors: Olaf Domaszk
Affiliation: Internal Medicine, Nephrology and Dialysis Clinic, Medical Military Institute Medical University of Warsaw
Trustee of the paper: Prof. Stanisław Niemczyk

Corresponding author: Olaf Domaszk (olafdomaszk@gmail.com)

Background
Lithium remains one of the most efficient mood stabilizers in bipolar disorder (BD) treatment. It is effective against both manic and depressive episodes as well as in the prevention of new episodes and significantly reduces suicide risk. However, it has numerous severe side effects such as tubulointerstitial nephritis leading to progressive chronic kidney disease (CKD). The risk of lithium-induced nephropathy substantially increases with age and the length of therapy duration.

Case report
In February 2020, a 56-year-old patient with CKD stage G4, secondary hyperparathyroidism, renal cysts, BD, goiter, and hyperlipidemia was admitted because of sustained proteinuria. However, a kidney biopsy was not done because consent was not obtained. The clinical picture- i.e. non-nephrotic proteinuria, normal kidney size, long course of the disease, and normal hemoglobin level was suggestive for interstitial nephritis. Moreover, performed OGTT revealed diabetes. Due to CKD gliquidone with dietary treatment was implemented. Importantly, the patient was lithium-treated for the previous 30-years.
After one month patient was admitted to the Department of Psychiatry due to a manic episode. Lithium was discontinued and after aripiprazole treatment initiation patient's symptoms subsided. Although BD treatment modification and both pharmacological and dietary treatment the CKD progressed. In June 2021, the patient was admitted to the hospital due to the symptoms of CKD exacerbation (lower limb edema and acute oliguria). Between the hospitalizations, GFR decreased from 22,2 to 14 ml/min. Laboratory tests also revealed hypertriglyceridemia (TG=518 mg/dl).
In December 2021, catheterization of the jugular vein was performed. With GFR=10 ml/min patient was initiated on hemodialysis. Routine ECG showed first-degree AV block and sinus bradycardia. However, no cardiovascular symptoms were reported.

Conclusions
Although lithium has proven effectiveness in BD, due to its adverse event profile, it should be prescribed after careful consideration. Importantly, it is mandatory to monitor its serum concentration to maintain it in the narrow therapeutic range (i.e. 0.6-0.8 mmol/L) as well as kidney and thyroid function. Increased lithium level is associated with numerous side effects including nephropathy, goiter, hypothyroidism, and AV blocks. Notwithstanding, currently there are no clear criteria for when to stop the therapy. Importantly, abrupt discontinuation may provoke manic relapse in patients with BD.

Neurology & Neurosurgery

Date: 6th May 2022, 11:30 AM

Coordinators:
Iwona Chaberska
Maria Deczkowska

Patronage:

Konsultant Krajowy w dziedzinie Neurologii Dziecięcej

Dr hab. n. med. Ewa Emich-Widera

Konsultant Krajowy w dziedzinie Neurologii

prof. dr hab. n. med. Agnieszka Słowik

Prezes: dr. hab. Marta Banach

[1147] Fingerprint of novel circulating microRNAs identify patients with stroke-embolic stroke of undetermined source

Authors: Disha Keshwani, Zofia Wicik, Joanna Jarosz-Popek, Anna Nowak, Marta Wolska, Dagmara Mirowska-Guzel, Anna Czlonkowska, Marek Postula, Ceren Eyileten, Izabela Domitrz
Affiliation: Department of Experimental and Clinical Pharmacology, Medical University of Warsaw, Center for Preclinical Research and Technology CEPT, Warsaw, Poland
Trustee of the paper: Ceren Eyile

Corresponding author: Disha Keshwani (dishkeswani@gmail.com)

Introduction
Stroke is the second-most common cause of death worldwide. Circulating levels of selected miRNAs open up new avenues for the identification of more effective and specific biomarkers to identify and risk-stratify stroke patients.

Aim of the study
The aim of the present study is to identify and select specific miRNAs to be used as disease biomarkers to improve both prognosis and prediction.

Materials and methods
48 patients with embolic stroke of undetermined source (ESUS) and 32 healthy individuals were involved in the study. We divided the ESUS patient groups based on patients who had a second stroke or TIA and those who did not have. Total RNA was extracted from plasma and quality was assessed with fluorometric electrophoresis. In total 48 microarray analysis was performed with the Affymetrix platform. Statistical analysis was performed in TAC software and R using Signal information obtained from the TAC output. We performed FDR correction, logistic regression, Mann-Whitney test, and t-test and calculated AUC using ROCp R package. Coexpression analysis to identify genes authentically expressed was performed using Spearman correlation (cutoff=0.9, Rpval=0.05). qRT-PCR was done for validation analysis.

Results
MiR-4786 (AUC=0.88; p=0.008), miR-1288 (AUC=0.93; p=0.002), miR-548ar-3p (AUC=0.85; p=0.009), miR-4676 (AUC= 0.93; p=0.005) were found to be the most differentially expressed miRNAs between the groups (patients with one stroke vs multiple strokes). Moreover, we validate these miRNAs between patients and healthy individuals. MiR-1288, miR-548ar were significantly lower in ESUS ($p<0.0001$, $p<0.0001$). MiR-4676 and miR-4786 were significantly higher in ESUS ($p<0.0001$, $p<0.0001$), compared to controls. Besides, our enrichment analysis showed IL-2 signaling pathway, lipid and lipoprotein metabolism, BDNF signaling pathway, MAPK signaling pathway, Intellectual Disability and Alzheimer's Disease are significantly related to ESUS- patients.

Conclusions
None of those miRNAs were ever studied in stroke patients before. Our results identified several novel circulating miRNAs that are down- or up-regulated in ESUS-stroke patients, as showing the predictive significance for the assessment of risk of the second stroke. Among those with the most relevant differential expression, several miRNAs were already identified to play a role in the pathophysiology of neurovascular diseases, paving the way to a new class of smart pathophysiology-based biomarkers in stroke.

[1238] Peripheral nervous system involvement among systemic sclerosis patients in Latvia

Authors: Daniils Žukovs (1), Evelīna Možeitoviča (1)
Affiliation: (1) Riga Stradiņš University, Riga, Latvia; (2) Pauls Stradiņš Clinical University Hospital, Riga, Latvia
Trustee of the paper: Kristīne Ivanova (1,2)

Corresponding author: Daniils Zukovs (daniel.zhukovs@gmail.com)

Introduction
Systemic sclerosis (SSc) is a chronic autoimmune disease with a wide spectrum of clinical manifestations, including involvement of the peripheral nervous system (PNS). Previously, PNS events were thought to be rare for SSc patients, however, current studies show a prevalence of neuropathy close to 30%. To our knowledge, no nationwide studies of peripheral nervous system disorders among patients with SSc had been carried out in Baltic countries previously.

Aim of the study
To determine a prevalence of mono-/polyneuropathy among SSc patients in Latvia.

Materials and methods
During a time frame of four and a half years, 109 patients with diagnosed systemic sclerosis were consulted in Latvian university hospitals. Of all participants approached, 67 enrolled in the study. SSc was accessed by ACR/EULAR criteria. Patients underwent a uniform evaluation of the peripheral nervous system: nerve conduction studies (NSC) were performed to access large fiber function; for those patients who had normal NSC results, quantitative sensory testing (QST) was used to assess small fiber function. Statistical analysis was performed using SPSS

Results
The mean age of the study group was 61.8±12.5 years with a prevalence of female sex (80.6%). The mean age for the onset of SSc was 46.3±16 years and the mean duration of disease was 15.5±10.2 years. There were 47.8% of subjects who had LFN (n=32/67) and 40.3% of subjects who had SFN (n=27/67). A total of 25 subjects had median neuropathy at the wrist (MNW). Median neuropathy at the wrist was found in 10 subjects with LFN and 14 subjects with SFN, while only one subject had MNW presented as isolated mononeuropathy. Common risk factors for neuropathy (e.g., cyclophosphamide treatment, diabetes mellitus) as a possible secondary cause were observed in 35.8% of subjects (n=24/67), but no significance was found (p=0.37).

Conclusions
The prevalence of peripheral polyneuropathies among SSc patients in Latvia is higher than the overall prevalence discovered in other studies. MNW is common in SSc, but its presence as an isolated mononeuropathy is rare.

[1259] The influence of DBS STN on quality of life in patients with Parkinson's disease

Authors: Barbara Buchalska, Agata Marszałek, Karolina Jaros
Affiliation: Neuromodulation Section, Students Scientific Group, Department of Neurology, Faculty of Health Science, Medical University of Warsaw
Trustee of the paper: Stanislaw Szlufik, MD, PhD

Corresponding author: Barbara Buchalska (buchalskabarbara@gmail.com)

Introduction
Parkinson's disease (PD) is one of the most commonly diagnosed movement disorder. Patients with PD experience many disturbing physical symptoms such as rest tremor, rigidity and slowness of movement. They also have emotional disorders like anxiety, depression or apathy.

Aim of the study
The study was conducted to assess the quality of life in patients with PD before and after bilateral STN DBS procedure.

Materials and methods
To conduct the study, PDQ-39, PDQ-8 and EQ-5D scales were used. The scales were obtained from 16 patients (5 women and 11 men, mean age 60.8±9.2years), with idiopathic PD, who underwent the DBS STN implantation procedure. All of the study patients were examined twice (before and after DBS STN surgery) during hospitalization in Department of Neurology.

Results
After the DBS STN implantation, the patients' mean PDQ-39 score decreased by 28% (from nearly 35 points to 25 points, p=0,2). The mean PDQ-8 score decreased non-significantly by 14% (from approximately 7 to 6 points, p=0,7) and the mean EQ-5D score decreased by 12% (from nearly 6 to 5 points, p=0,7).

Conclusions
The DBS STN implantation may improve the patients' scores, what tends to be determined mainly in PDQ-39 questionnaire, but not so clearly in PDQ-8 and EQ-5D scales, possibly due to its greater complexity.

[1260] The influence of DBS STN on emotional disorders in patients with Parkinson's disease

Authors: Barbara Buchalska, Agata Marszałek, Karolina Jaros
Affiliation: Neuromodulation Section, Students Scientific Group, Department of Neurology, Faculty of Health Science, Medical University of Warsaw
Trustee of the paper: Stanislaw Szlufik, MD, PhD

Corresponding author: Barbara Buchalska (buchalskabarbara@gmail.com)

Introduction
Parkinson's disease (PD) is one of the most common movement disorders. Patients with PD report many bothering physical symptoms like rest tremor, rigidity and bradykinesia. However concomitant emotional disorders including anxiety, depression or apathy, can be even more disturbing and markedly reduce the patients' quality of life.

Aim of the study
The study was conducted to evaluate the severity of emotional disorders in patients with PD before and after bilateral STN DBS procedure.

Materials and methods
To conduct the study, questionnaire TAS-20 was used. The questionnaires were obtained from 9 patients (1 woman and 8 men, mean age of 62.8years), with idiopathic PD, who underwent the DBS STN implantation procedure.

Results
After the DBS STN implantation the patients' mean TAS-20 score increased non-significantly by 2% (from nearly 63 to 64 points, t=0,5). In the Difficulty Describing Feelings subscale the mean score increased by 7% (from approximately 13 to 14 points, t=0,4). In the Difficulty Identifying Feeling subscale the mean score increased by 2% (from 17,9 to 18,2 points, t=0,9). In the Externally-Oriented Thinking subscale the mean score was the same before and after DBS implantation (32 points, t=1).

Conclusions
Although the treatment with DBS STN stimulation has many benefits it does not clearly reduce the severity of emotional disorders in patients with PD.

[1266] The impact of Deep Brain Stimulation of the Subthalamic Nucleus on BMI and carbohydrate metabolism in patients with Parkinson's Disease.

Authors: Agata Marszałek(1), Joanna Samborska-Ćwik(2)
Affiliation: (1) Neuromodulation Section, Students Scientific Group, Department of Neurology, Faculty of Health Science, Medical University of Warsaw; (2) Department of Neurology, Faculty of Health Science, Medical University of Warsaw
Trustee of the paper: Stanislaw Szlufik, MD, PhD

Corresponding author: Agata Marszałek (agata.marszalek000@gmail.com)

Introduction

Parkinson's Disease (PD) is a progressive neurodegenerative disorder that can be treated using pharmacotherapy or surgically. The most popular treatment in PD patients is pharmacotherapy, but recently Deep Brain Stimulation of the Subthalamic Nucleus therapy (DBS STN) has become an effective surgical treatment method in PD patients, which have complications of pharmacotherapy. DBS can alleviate symptoms such as tremor, stiffness and bradykinesia. The relationship between the type of therapy used and the BMI or the carbohydrate metabolism of PD patients is becoming the subject of the interest for researchers, as it is unclear.

Aim of the study

The aim of study was to investigate whether DBS STN therapy is associated with the risk of increasing BMI and change in the parameters of monitoring carbohydrate metabolism in patients with PD.

Materials and methods

Fifty-two patients (22 women, 30 men) with an average age of 56.9 years (±9.1) with PD were subjected to the study. Twenty-nine of them were qualified for DBS STN therapy (DBS group), and the 23 were treated only pharmacologically (BMT group). Patients were admitted for 3 visits during which they underwent the following measurements: body weight, OGGT, and glycosylated hemoglobin levels (HbA1c). The obtained results were interpreted using the Statistica 13.3 program.

Results

The study showed that the weight of patients enrolled in DBS STN at the second visit (which was first visit after surgery) increased significantly ($p = 0.016$). These changes are not so strongly manifested between the measurements from the 2nd and 3rd visits in DBS group ($p = 0.06$). The relationship between patient weight and subsequent visits was not observed in pharmacologically treated patients ($p<0.05$). Fasting blood glucose level at the third visit increased from the first visit in patients regardless of the type of treatment ($p = 0.048$).

Conclusions

DBS STN impacts on weight in PD patients. Therefore, patients should be informed about a risk of weight gain after DBS STN surgery, also taking into consideration the risk of increased fasting blood glucose (the increased risk of diabetes).

[1267] The influence of Subthalamic Nucleus Deep Brain Stimulation on sleep disorders and fatigue in patients with Parkinson's Disease.

Authors: Agata Marszałek, Barbara Buchalska, Karolina Jaros
Affiliation: Neuromodulation Section, Students Scientific Group, Department of Neurology, Faculty of Health Science, Medical University of Warsaw
Trustee of the paper: Stanislaw Szlufik, MD, PhD

Corresponding author: Agata Marszałek (agata.marszalek000@gmail.com)

Introduction
Parkinson's disease (PD) is a neurodegenerative disorder associated mainly with motor symptoms such as tremor, stiffness, or bradykinesia. However, the non-motor aspects of this disease are sometimes also very disabling – mainly smell loss, constipation, sleeping disorders and fatigue. Subthalamic nucleus deep brain stimulation (DBS STN) is a gold standard surgical procedure in PD patients with motor and non-motor complications of the pharmacological treatment. This therapy improves the patients' motor activity its impact on sleep disturbances and fatigue remains unclear.

Aim of the study
The aim of this study is to determine the impact of DBS STN on sleeping disorders and fatigue in PD patients undergoing the surgery.

Materials and methods
The study cohort consisted of 16 patients with idiopathic Parkinson's Disease (4 women, 12 men, mean age 60.8±9.2years) who were examined twice (before and after DBS STN procedure) using in-person surveys during the hospitalization in the Department of Neurology. The scales used were the Epworth Sleepiness Scale (ESS), Parkinson's Disease Sleep Scale 1 (PDSS-1) and the Fatigue Scale. The results were analyzed with Statistica 13.3 software.

Results
ESS results showed non-significant improvement in the quality of sleep in 56.25% of post-DBS PD patients (mean change 15.2%, p = 0.29, 0.875 pts). PDDS-1 scale also showed non-significant improvement in sleep quality in 60% of study patients with average by 5.44% (p=0.459). 50% of patients had non-significant reduction in mental fatigue by an average of 20.37% (9.69, p = 0.44), and physical fatigue by 17.27% (p = 0.39, 9.06 points).

Conclusions
Based on the conducted research, the DBS STN surgery may not have significant impact on sleep disturbances and fatigue in PD patients.

[1274] The use of a telephone application and a forearm band as markers of good therapy response in patients with Parkinson's disease

Authors: Julia Kaszucka, Natalia Kraciuk, Tomasz Gutowski
Affiliation: (1) Neuromodulation Section, Students Scientific Group, Department of Neurology, Faculty of Health Science, Medical University of Warsaw; (2) Institute of Computer and Information Systems, Faculty of Cybernetics, Military University of Technology
Trustee of the paper: Stanisław Szlufik, MD, PhD

Corresponding author: Natalia Kraciuk (n.kraciuk@gmail.com)

Introduction
Parkinson's disease (PD) is a neurodegenerative disease that affects an increasing number of the population. The main symptoms of the disease are motor disabilities, from which the main triad of motor symptoms are tremor, stiffness and bradykinesia. Since many therapeutic methods are currently under development, simple markers are being sought to assess the impact of pharmacological therapies on the reduction of movement disorders.

Aim of the study
The aim of the study is to evaluate the use of a telephone application and a forearm band as markers for assessing the severity of movement disorders in patients with Parkinson's disease.

Materials and methods
The study used the ClinicalTrialsAssistant telephone application prepared for the assessment of the severity of movement disorders (tremor, stiffness, bradykinesia) by the Institute of Information Systems of the Military University of Technology. The study included 10 patients with idiopathic Parkinson's disease (mean age 59.4 years, F=6, M=4), of which 6 patients performed all tests on the telephone and with the use of the forearm band. Patients were assessed in the ON and OFF phases (on drugs and 24 hours after their discontinuation). Patients were also assessed on the UPDRS III scale each time.

Results
The analysis of tests with the use of the phone and the forearm band showed statistically significant differences ($p < 0.05$) between the ON and OFF phase in terms of the parameters of accelerometry, magnetometry and gyroscope, in all directions (X, Y, Z). The most statistically significant parameters changing between phases of therapy (with drugs, without drugs) were the tremor amplitude, intensity and frequency. The severity of the parameters was correlated with the severity of the motor symptoms of Parkinson's disease (tremor, bradykinesia).

Conclusions
Our results confirm that the telephone application and the forearm band may be an easy-to-use marker of the severity of Parkinson's motor deficits, which in the future may translate into their use in the assessment of the impact of pharmacological therapies on the state of motor improvement in PD patients.

[1278] A mobile application as a marker to assess the effect of DBS on motor status in Parkinson's disease patients

Authors: Julia Kaszucka (1), Natalia Kraciuk (1), Tomasz Gutowski (2)
Affiliation: (1) Neuromodulation Section, Students Scientific Group, Department of Neurology, Faculty of Health Science, Medical University of Warsaw; (2) Institute of Computer and Information Systems, Faculty of Cybernetics, Military University of Technology
Trustee of the paper: Stanisław Szlufik, MD, PhD

Corresponding author: Julia Kaszucka (j.kaszucka@gmail.com)

Introduction
Subthalamic nucleus deep brain stimulation (DBS STN) is a highly effective treatment for Parkinson's disease (PD) tremor, wearing-off phenomenon, and medication-induced dyskinesias, that involves the implantation of electrodes into the targeted areas of the brain, and an impulse generator, that provides an electrical stimulus, which modulates the abnormal brain activity responsible for the motor symptoms. Nowadays, there is increasing use of biomarkers as an indicator in the parametric assessment of the effect of DBS STN on patients' motor improvement.

Aim of the study
The aim of the study was to determine the effectiveness of a phone application as a marker of the impact of DBS STN on the motor disabilities such as tremor, bradykinesia and rigidity in patients with Parkinson's disease.

Materials and methods
11 post-DBS STN PD patients (mean age 64.2 years, 9 males, 2 females) were examined using a specially designed phone application, that recorded patient's speed and precision while performing simple exercises within the mobile app, as well as a tracker forearm band, that measured patient's tremor, rigidity and bradykinesia. The procedure during each examination was conducted twice: in total ON phase (StimON-MedON) and in StimOFF-MedON phase. The patients' motor state was examined using UPDRS III scale.

Results
The analysis of the tests performed via the app and the tracker forearm band showed the statistically significant improvement in parameters of accelerometry, magnetometry and gyroscope (amplitude, intensity, frequency) in all directions (X, Y, Z) in StimON-MedON compared to StimOFFMedOn ($p < 0.05$). The motor improvement in the mobile app correlated with the severity of PD motor symptoms in UPDRS III scale (tremor, bradykinesia).

Conclusions
The mobile application has proven to be a simple and effective method of measuring the motor disability in Parkinson's disease patients. Therefore, it may be a helpful tool in assessment of DBS STN impact on the actual motor state of PD patients.

[1282] Postoperative cerebral venous sinus thrombosis following retrosigmoid approach – radiological and clinical analysis

Authors: Camlet K, Jankowski J, Przepiórka Ł, Kunert P, Wójtowicz K, Grabowska–Derlatka L, Marchel A
Affiliation: Department of Neurosurgery, Medical University of Warsaw, Warsaw, Poland
Trustee of the paper: Łukasz Przepiórka

Corresponding author: Katarzyna Camlet (camkasia@interia.pl)

Introduction
The retrosigmoid approach (RSA) is one of the most common neurosurgical approaches to the posterolateral skull base. Symptomatic postoperative cerebral venous sinus thrombosis (CVST) is a rare but known complication following RSA. However, the literature regarding CVST is still lacking.

Aim of the study
The aim of this study was to evaluate radiologic features of CVST (rCVST), whether occurrence of rCVST was related to the extent of bony opening and the frequency of clinical manifestation.

Materials and methods
We retrospectively evaluated 128 consecutive contrast enhanced computed tomography scans performed routinely after elective RSAs between postoperative days 3 and 7. In addition to rCVST, the extent of the bony opening relative to the venous sinuses was quantified by expressing the shortest distance of the craniotomy margin from the transverse sinus (TS) and sigmoid sinus (SS) in positive values, and the overlap of the bony opening with the sinus in negative values. Medical charts were evaluated for clinical diagnosis of CVST during the hospitalization.

Results
rCVST were found in 59 patients (46.1%), of which 38 (64.4%) in the TS, 37 (62.7%) in the SS, and 31 (52.5%) in the TS and SS junction. The mean ranges of sinus exposures in patients with and without rCVST were for SS: -3.13 and -1.90 mm (for the whole group: -2.47 mm); for TS: -7.20 and -5.04 mm (for the whole group: -6.04 mm). Exposure of SS or TS was found in 110 patients, of which 55 (50%) had rCVST. In 18 patients, neither SS nor TS was exposed, of which only 4 (22.2%) had rCVST ($p=0.04$). rCVST rates for exposed and unexposed SS were not significantly different (50.6% vs. 38.8%, $p=0.21$); similarly for TS (50.5% vs. 31.0%, $p=0.09$). Three patients (5%) had clinical manifestations of CVST, of which 1 involved superior sagittal sinus and 2 ipsilateral TS and SS.

Conclusions
rCVST are common sequelae of RSA, but occur less frequently when neither of sinuses (TS nor SS) is exposed at the time of bony opening. Approximately 5% of patients with rCVST present with clinical symptoms.

[1311] The impact of learning time on hippocampal volume of medical students and correlation with the results of the Medical Final Examination.

Authors: Jakub Marek; Olga Przybyla;
Affiliation: Second Department of Clinical Radiology, Medical University of Warsaw, Warsaw, Poland
Trustee of the paper: Edyta Maj

Corresponding author: Olga Przybyla (okprzybyla@gmail.com)

Introduction
The hippocampus is a part of the limbic system involved in the learning process. It is responsible for transferring information from short-term to long-term memory. Compared to a control group with similar cognitive abilities, some authors have observed an increase in the volume of the right and posterior hippocampus and the posterior and lateral parietal lobe in individuals going through a period of intensive studying.

Aim of the study
The aim of our study was to assess the effect of intensive studying on the plasticity of the hippocampal neurons and therefore on hippocampal volume changes and then how this correlate with the Medical Final Examination results.

Materials and methods
The analysis covered 44 final year medical students who underwent two volumetric 3DT1 magnetic resonance imaging with an interval of 20 weeks: 19 weeks before and one week after the Medical Final Examination. The FreeSurfer software was used to compare the volumes of whole hippocampus and their subfields from the two measurements. The other brain structures were also analyzed. The results were correlated with the outcome of the Medical Final Examination and with the time students spent studying.

Results
A statistically significant increase in the volume of the right hippocampus was observed in students with longer study time and better exam results. The right hippocampus subiculum area has increased. The volume of the left hippocampus remained unchanged.

Conclusions
Our research confirms the role of the hippocampus in the process of learning and remembering, especially the field called the subiculus. It also indicates that the plastic abilities of the hippocampus depend on the intensity of learning and translate into better skills.

[1330] STN DBS improves balance disorders in Parkinson's disease patients and impacts the disease progression.

Authors: Karolina Jaros1, Stanisław Szlufik2, Maria Kłoda2,3, Iwona Potrzebowska2,3, Andrzej Przybyszewski4, Tomasz Mandat5, Dariusz Koziorowski2
Affiliation: (1) Neuromodulation Section, Students' Scientific Group, Department of Neurology, Faculty of Health Science, Medical University of Warsaw; (2) Department of Neurology, Faculty of Health Science, Medical University of Warsaw; (3) Department of Rehabilitation, II Faculty of Medicine, Medical University of Warsaw; (4) Department of Informatics, Polish Japanese Academy of Information Technology; (5) Department of Neurosurgery, Maria Sklodowska Curie Memorial Oncology Center, Warsaw
Trustee of the paper: Stanislaw Szlufik, MD, PhD

Corresponding author: Karolina Jaros (karolinajaros99@gmail.com)

Introduction
Subthalamic nucleus deep brain stimulation (STN DBS) can influence on balance and gait disorders, but there are still some conflicting information.

Aim of the study
The aim of this study was to evaluate the impact of STN DBS on balance disorders in PD patients.

Materials and methods
DBS-group consisted of 28 PD patients who underwent bilateral STN DBS. Control group (BMT-group) consisted of 24 patients who did not undergo surgical intervention and were treated only with pharmacotherapy. UPDRS III scale and balance tests (UpAndGo Test, Tandem Walk Test) were measured during 3 visits: V1 (which was preop visit for DBS group), V2 and V3 in all DBS/pharmacotherapy phases. The mean periods between visits were 9±3months.

Results
There are statistically significant differences in all balance tests on each visit between Total-On and Total-off in both study groups ($p<0,05$). There are statistically significant differences in all balance tests in V2 and V3 visits between DBS-on/BMT-off and Total-off as well as BMT-on/DBS-off and Total-off, but values of the balance tests achieved in the DBS-on/BMT-off phase are significantly lower and tend to increase slower than those achieved in DBS-off/BMT-on.

Conclusions
STN DBS can improve balance disorders in PD patients more than pharmacological treatment. STN DBS may have an impact on PD progression.

[1488] Effects of unilateral and bilateral Subthalamic Nucleus Deep Brain Stimulation on pharmacotherapy modification in patients with Parkinson's disease

Authors: Zuzanna Danielecka, Kinga Dąbkowska
Affiliation: Neuromodulation Section, Students Scientific Group, Department of Neurology, Faculty of Health Sciences, Medical University of Warsaw; Head of the Department: Dariusz Koziorowski, MD, PhD
Trustee of the paper: Stanisław Szlufik, MD, PhD

Corresponding author: Zuzanna Danielecka (z.danielecka@gmail.com)

Introduction
Subthalamic Nucleus Deep Brain Stimulation (DBS STN) is a surgical treatment alternative for patients with Parkinson's disease (PD) when drug therapy causes complications (wearing off, dyskinesia). It impacts on motor state of PD patients and therefore enables the decrease of daily dosages of pharmacological treatment.

Aim of the study
The aim of this study was to evaluate the impact of unilateral and bilateral DBS STN on pharmacotherapy modification in patients with PD after DBS procedure.

Materials and methods
The study group consisted of 24 patients with Parkinson's disease (16 men and 8 women, mean age 54.2 years) after unilateral and bilateral implantation of DBS electrodes into the subthalamic nucleus. An analysis of the doses of pharmacotherapy (Levodopa Equivalent Daily Dose, LEDD) in patients who underwent unilateral and bilateral DBS STN implantation was performed – LEDD was calculated before the procedure, twice after the unilateral procedure and then two more times after the second DBS implantation.

Results
Patients already undergoing unilateral DBS STN have statistically significantly lower doses of pharmacotherapy (LEDD) compared to the visit before surgical treatment ($p<0.05$), with the second visit after unilateral DBS compared to the first visit after unilateral DBS not significantly different in drug doses ($p>0.05$). The implantation of second DBS STN system results in second statistically significant reduction of pharmacotherapy in patients with unilateral DBS ($p<0.05$).

Conclusions
Both unilateral and bilateral DBS STN procedures result in statistically significant reduction of the doses of drugs previously taken by patients, which has a great impact on reducing complications of previous pharmacological treatment in patients before DBS STN.

[1489] Gait and balance assessment after unilateral Gamma Knife thalamotomy for treatment of tremor

Authors: Anna Ziobro, Aleksandra Korn, Karol Sadowski
Affiliation: Medical University of Warsaw/Department of Neurology
Trustee of the paper: Monika Figura MD PhD

Corresponding author: Anna Ziobro (aannaziobro@gmail.com)

Introduction
Parkinson's Disease (PD) and essential tremor (ET) are among most common causes of tremor. Pharmacotherapy is the first line of treatment. It can sometimes be ineffective or have unacceptable side effects. In such cases, surgical treatment is an option. Deep Brain stimulation or thalamotomy are among commonly used methods.

Aim of the study
The aim of our study was to assess the impact of unilateral Gamma Knife thalamotomy on gait and balance of ET and PD patients.

Materials and methods
We included 20 consecutive patients with PD (n=10) or with ET (n=10) with pharmacoresistant tremor. The mean age was 63.5 (±9.5), 15 male and 5 female. They underwent assessments before (n=20); 12 months (n=20), and 24 months (n=15) after the thalamotomy. Timed "Up and go" test, tandem stance test, tandem pivot test, and walking tandem tests were performed. Stabilometry was performed using TecnoBody Prokin-M-line stabilometric platform with Prokin 3 software and gait was assessed on Zebris treadmill. Friedman's ANOVA and Wilcoxon's signed-rank test were used to compare the outcomes. Patients with PD were assessed in "ON" and "OFF" dopaminergic treatment state.

Results
Statistical analysis revealed no significant deterioration in gait and balance in performed tests in a 2-year follow-up.

Conclusions
We conclude that unilateral Gamma Knife thalamotomy does not affect on gait and balance of ET and PD patients.

[1491] What are neurological complications of infective endocarditis?

Authors: Anna Burban, Miłosz Starczyński, Dorota Słupik, Aleksandra Reda, Mateusz Ziomek
Affiliation: 1st Chair and Department of Cardiology, Medical University of Warsaw
Trustee of the paper: doc. Agnieszka Kołodzińska

Corresponding author: Anna Burban (ania.burban@gmail.com)

Introduction
Infectious endocarditis (IE) is a rare disease with high mortality percentage and numerous complications. Neurological complications are presented even at 15-30% patients with IE. Staphylococcus aureus is the most often observed etiologic factor of IE of those patients. The most often recognized neurological complication is an ischaemic stroke.

Aim of the study
To analyse the group of patients with infectious endocarditis and what are the neurological complications among them.

Materials and methods
We analysed retrospectively patients hospitalised at our cardiology unit between 2016-2021 and identified 96 patients with diagnosed infectious endocarditis.

Results
55 patients were female (57,3%) and the mean age of incidence was 68 years. The mean time of hospitalisation was 33 days. Out of 96 patients, 9 (9,38%) of them had neurological complications. 2 (22,2%) of them died. They were hospitalised with average of 51 days. 5 patients had symptoms which indicated a stroke. Conducted computed tomography revealed intracerebral hematoma in 4 of them, later evaluated as a probably raptured mycotic aneurysms. 1 patients as a result of brain damage in the course of endocarditis has repeatedly epileptic attacks. 3 of patients had neuroinfections: 2 had brain abscesses and one empyema of vertebral canal. Those demanded long antibiotic therapy and neurosurgery interventions. The etiology of IE was differentiated 3 patients had S. aureus, the other less typical bacteria for neurological complications: Enterococcus faecium, Klebsiella pneumoniae, Proteus Mirabilis, Staphylococcus epidermidis, Streptococcus anginosus. Vegetations were found in 4 patients on mitral valve, in 2 patients on aortic valve, in 2 patients connected with electrodes and one on tricuspid valve.

Conclusions
Neurological complications can lead to prolonged hospitalisations. In contrary to typical etiology and type of complications, in our group of patients S. aureus is an etiology factor at only 3 patients with IE. Furthermore, only one patient had an ischaemic stroke. As the S.aureus is associated with Ischaemic stroke, the other bacteria seem to cause other less typical neurological complications: neuroinfections and intracerebral hematomas. Analysed group is too small yet. Hence further studies are crucial to assess the risk factors for neurological complications.

Obstetrics, Gynecology & Perinatology

Date: 7th May 2022, 8:30 AM

Coordinators:
Aleksandra Śliwka
Weronika Caban

Patronage:

Konsultant Krajowy w dziedzinie Położnictwa i Ginekologii

Prof. dr hab. n. med. Krzysztof Czajkowski

Konsultant Krajowy w dziedzinie Perinatologii

Prof. dr hab. n. med. Mirosław Wielgoś

EUROPEAN ASSOCIATION OF PERINATAL MEDICINE

[1182] In vitro fertilization awareness among Polish population.

Authors: Aleksandra Marchwińska, Klaudia Łuczak
Affiliation: Students' Research Group at the 1st Department of Obstetrics and Gynecology, Medical University of Warsaw
Trustee of the paper: Ass. Prof. Iwona Szymusik MD PhD

Corresponding author: Aleksandra Marchwińska (a.marchwinska@outlook.com)

Introduction
World Health Organization describes infertility as a global health issue due to the scale of the problem. In vitro fertilization (IVF) is one of its treatment methods.

Aim of the study
The study aimed to analyze Poles' awareness and knowledge of IVF.

Materials and methods
The study group consisted of 2874 Polish respondents. Data were collected through a self-prepared online questionnaire including 42 questions. They included demographic data, knowledge about infertility, the process of the IVF procedure and legal regulations regarding IVF in Poland. 18 of these questions were chosen to assess the level of knowledge about IVF among respondents.

Results
2717 women (95%) and 157 men (5%) participated in the study. The most numerous groups of respondents included people aged 31-40 (37%), 18-25 (28%), and 26-30 (24%). The majority (96%) had secondary or higher education. Furthermore, 71% were professionally active and 22% indicated health care as their occupation. As many as 31% of respondents did not identify with any religion. Almost 53% had no children. Only 34% correctly indicated the scale of the infertility problem in Poland. The majority (59%) believes that this problem is more frequent. It has been shown that there is a relation between the perceived scale of infertility and fertility ($p < 0.001$). The average number of correct answers in the field of knowledge about IVF was 11.6 out of 18 possible, which was 65%. People aged 26-40 and respondents with higher education obtained better results than the others ($p < 0.001$). The level of knowledge about IVF was not influenced by fertility or religion. Only 33% of the respondents correctly indicated the average effectiveness of IVF. As many as 48% of people did not know about valid Polish law regarding infertility treatment and 34% had never heard of a partial refund of IVF costs from local government programs. The greatest discrepancy in the answers was obtained in the question concerning the opinion on the IVF procedure, regardless of the woman's age (50% are for, 50% are against). It has been shown that the percentage of the negative responses increased with the age of the respondent.

Conclusions
Knowledge about in vitro fertilization and legal regulations concerning infertility treatment in Poland is insufficient. Conducting more information campaigns that would increase the knowledge about infertility and the methods of its treatment appears important.

[1210] Women's awareness of the ophthalmological contraindications of natural childbirth - analysis

Authors: Jakub Chryn, Anna Skoczek-Wojciechowska, Natalia Zalewska
Affiliation: Medical University of Warsaw, First Department of Ophthalmology
Trustee of the paper: Joanna Ciszewska MD PhD

Corresponding author: Jakub Chryn (jakubchryn@gmail.com)

Introduction

It is still commonly belived that natural childbirth in patients with some eye diseases (myopy included) can worsen the ophthalmic conditions with irreversible decrease of visual acuity.
In Poland the most common ophthalmologic indication to terminate pregnancy by caesarean section is myopia (57%), whereas in most cases of the myopic patients natural labour does not have an impact on vision's quality. In 2014 Polish Ophthalmological Society released guidelines on ophthalmological indications for pregnancy termination by caesarean section.

Aim of the study

The study was conducted in order to assess and compare the awareness of the official ophthalmological contraindications of natural labour among Polish women.

Materials and methods

The original, structured, anonymous, online survey was performed. The survey, distributed in social media, included nineteen, both open and closed questions. The data were analyzed separately for each participant and in selected comparative groups, including women affected by visual impairments, women that had already given birth and women in general.

Results

In the study 624 women were involved, including 409 (65,5%) with myopia. Participants were asked if they agree with the statement that refractive error - mostly myopia is a contraindication of natural labour - 463 respondents (74,20%) agreed at some point or absolutely with this sentence. The most common contraindication (181 answers - 38,66%) shown by those respondents was some degree of myopia, supposedly worsening the visual acuity irreversibly. Only 13 respondents (2,08%) gave answers correct with the official indications. Myopic respondents were also asked if they were ever suggested that it is not recommended for them to give birth by natural labour - 130 (31,78%) answered positively. Only 18 respondents (4,93%), who have been pregnant, confirmed that a caesarean section was performed due to ophthalmological indications.

Conclusions

About one third of all respondents (31,57%) replied that any myopia or some degrees of myopia are indications to pregnancy termination by caesarean section. Due to still low awareness among Polish women about ophthalmological conditions predisposing to caesarean section, it is crucial for ophthalmologists and gynecologists to educate women about real medical contraindications of natural labour in those patients.

[1240] Knowledge of Polish women about the safety of medications taken during pregnancy

Authors: Gabriela Trojan
Affiliation: Kazimierz Pułaski University of Technology and Humanities in Radom
Trustee of the paper: Szymon Piątek, M.D. Ph.D

Corresponding author: Gabriela Trojan (pracanaukowa17@gmail.com)

Introduction
Increased self-awareness of women regarding the physiology and course of pregnancy lead to reducing the risk of perinatal complications. Raising awareness among people allows avoiding potentially harmful behaviors.

Aim of the study
Main goal of the study was to assess the knowledge of Polish women about the safety of medications taken during pregnancy and the most common beliefs related to taking medications, herbal preparations, and vaccinations by pregnant women. The secondary aim was to estimate the frequency of taking medications in pregnant women.

Materials and methods
An online questionnaire was prepared on the use of drugs, knowledge about their action and use, as well as beliefs about the use of drugs by pregnant women. 1,121 women took part in the study, both those who had pregnancy behind them and those who had never been pregnant. The survey was conducted from 1. January to 28. February 2022.

Results
81.6% of Polish women admitted that they had taken any medications during the pregnancy. 18,7% of women did not know if the drugs were safe to use at any stage of pregnancy. 17.3% of women did not know how to check drug safety during pregnancy. 18.7% do not have an opinion on this matter. 18.8% of the women believed that preventive vaccinations should not be taken during pregnancy. 31% of women do not have an opinion about immunization during pregnancy.

Conclusions
The level of knowledge is still not entirely satisfactory. Particular emphasis should be placed on promoting awareness among young women about the benefits of vaccination before and during pregnancy. A special role should be played by gynecologists, family doctors, and pharmacists, because they, along with the Internet, were indicated as the main source of knowledge about the harmfulness of various substances to the fetus.

[1241] Fertility-sparing treatment in uterine sarcoma

Authors: Szymon Piątek, Gabriela Trojan, Klaudia Rabek
Affiliation: Kazimierz Pułaski University of Technology and Humanities in Radom
Trustee of the paper: Szymon Piątek, M.D. Ph.D

Corresponding author: Gabriela Trojan (pracanaukowa17@gmail.com)

Introduction
Uterine sarcomas are rare gynecological malignancies that occur mostly in postmenopausal women. However, some cases are diagnosed in women before childbearing. Although uterine sarcomas are treated by hysterectomy some young patients may undergo fertility-sparing management.

Aim of the study
The objective of this study is an assessment of fertility-sparing treatment in premenopausal women with uterine sarcoma.

Materials and methods
An electronic database of patients treated between 2005 and 2021 at the Maria Sklodowska-Curie National Research Institute of Oncology, Department of Gynecologic Oncology was searched. Eligible criteria were: histopathology diagnosis of uterine sarcoma, FIGO stage I, age 18-40 and strong desire to preserve fertility. All patients underwent local tumor excision and uterine preservation.

Results
The analysis included 11 patients who fulfilled inclusion criteria. The mean age was 32,5 (17-35). Histopathological diagnosis include low-grade endometrial stromal sarcoma (n= 10), high-grade endometrial sarcoma (n=1). Median follow-up was 61 (11-158) months. 6 patients relapsed and they were treated by radical hysterectomy or chemotherapy. Patients, who relapsed were diagnosed with sarcoma stromale low grade, sarcoma stromale high grade, adenosarcoma low grade, leiomyosarcoma myxoides low grade, myofibroblastic sarcoma low grade.

Conclusions
Fertility-sparing treatment may be an option in the management of young women with uterine sarcoma.

[1243] Abnormal expression of proteins encoded by MMR genes in endometrial cancer patients in the Polish population.

Authors: Karolina Karoń, Natalia Szmigielska, Ewelina Bornio, Krzysztof Piątkowski
Affiliation: Uniwersytet Technologiczno - Humanistyczny im. Kazimierza Pułaskiego w Radomiu / Wydział Nauk Medycznych i Nauk o Zdrowiu
Trustee of the paper: dr n. med. Szymon Piątek

Corresponding author: Karolina Karoń (kkaron045@gmail.com)

Introduction
Evaluation of MMR protein expression is essential for the molecular classification of endometrial cancer. It entitles us to classify the patient into a specific risk group and modify the management accordingly. In addition, assessment of the expression of these repair proteins has a significant screening potential, which may be used to separate a group of patients with a potential Lynch syndrome and deepen the genetic diagnosis in them.

Aim of the study
The aim of the study is to evaluate the abnormal expression of MMR proteins in patients with endometrial cancer.

Materials and methods
This retrospective study involved patients with endometrial cancer treated at the Maria Sklodowska-Curie National Research Institute of Oncology in Warsaw between July 2020 to December 2021. The immunohistochemical expression of MMR proteins (MLH1, MSH2, MSH6, and PMS2) was assessed in patients with endometrioid endometrial cancer.

Results
75 eligible patients were included. Impaired expression in MMR proteins was found in 30 (40.00%) patients. The most common expression loss was MLH-1 protein that occurred in 24 patients (80.00%). Expression loss of PMS-2, MSH-6, the MSH-2 proteins were found in 24 patients (80.00%), 5 patients (16,67%) and 2 patients (6,67%), respectively.

Conclusions
MMR mutations may be more frequent in the Polish population (39.47%) than in the Chinese and British populations, respectively 23.70% and 26.40%. Moreover, the distribution of mutation frequency in individual proteins is different depending on the region - MSH-6 is the second least frequent mutation in the Polish population (16.67%) and the most frequent mutation in the Chinese population (68.29%) - therefore we may assume the differences between Asian and European citizens. Despite the concordance of the dominant mutation in Europe, we can see that in other countries there is not such a significant prevalence of MLH-1 mutations as in Poland (80.00%) - compared to the UK (62.87%) and Spain (72.13%). Further research on a larger study group is needed to determine if this is a statistically significant difference.

[1262] The most common side effects of oral hormonal contraception in adolescents and young adult women - Polish experience

Authors: Natalia Karpowicz, Katarzyna Mączka, Natalia Pacocha, Adrian Skoczylas
Affiliation: Department of Gynecological Endocrinology, Medical University of Warsaw, Warsaw, Poland, Student Scientific Group of Gynecological Endocrinology, Warsaw Medical University
Trustee of the paper: Monika Grymowicz PhD

Corresponding author: Natalia Karpowicz (nataliaakarpowicz@gmail.com)

Introduction
Simultanously with increasing oral hormonal contraception (OHC) utilization among women, there is a constant growth of disinformation and controvertions regarding to its safety and side effects. These factors may contribute to lower satisfaction, or even discontinuation of this method. According to WHO recommendations, physicians should offer evidence-based, comprehensive contraceptive counselling and recognize women fears, as well as the most disruptive side effects.

Aim of the study
Our aim was to assess concerns, most common and most undesirable side effects among Polish females divided into 3 age groups.

Materials and methods
A cross-sectional, questionnaire-based study was carried out from 29 April 2021 to 15 May 2021. The self-administered survey was distributed among about 8 Polish Facebook groups for women. The questionnaire included inquiries regarding OHC utilization patterns, side effects, health concerns and attitude of the responders. Anonymity and confidentiality were ensured. The statistical analysis of variables was conducted using Statistica software.

Results
The majority (58%) of 1699 responders, included in our analysis, were aged between 20 and 25 years. 67,1% of them were taking OHC at the time of the study and 21,9% took it in the past. Side effects, mentioned by 79% of all OHC users, were the main reason of discontinuation. A statistically significant factor in resigning from taking OHC was the occurrence of: decreased libido, weight gain, depressive mood and mood swings, ($p< 0.05$). These symptoms were also the most often reported side effects in general. About 14% of responders admitted to having concerns associated with safety and potential adverse effects of taking OHC. Most commonly reported were respectively: fear of weight gain (74%), hormonal disorders (66%) and loss of libido (54%). Moreover, age proved to be related to the occurrence of anxiety ($p<0.05$), showing tendency to decrease with years. Fears were also associated with the level of education ($p<0.05$). Most frequent concerns and least accepted side effects varied in different age groups.

Conclusions
Our research indicates the need to provide patients with accurate information about oral contraception, especially young women. Recognition of the most disruptive symptoms and concerns is essential for effective collaboration between health provider and a patient. We believe that it may have an impact on effectiveness, tolerance, lower risk of rejection and general satisfaction from using particular OHC.

[1281] The impact of pelvic venous disorders on quality of life of female patients.

Authors: Oliwia Madej, Natalia Kachnic
Affiliation: Department of Angiology, Jagiellonian University Medical College
Trustee of the paper: Paulina Kłapacz MD, PhD Candidate; Paweł Maga Associate Professor, MD, PhD

Corresponding author: Oliwia Madej (oliwka.madej@gmail.com)

Introduction
Pelvic venous disorders (PeVD) stem from pathologically dilated and enlarged blood vessels of abdomen and pelvis and are one of the major causes of chronic pelvic pain. The female patients frequently complain of dyspareunia and dysmenorrhea in conjunction with other symptoms. All of the above are well – known factors lowering patients' quality of life (QoL).

Aim of the study
The aim of our study was to assess QoL in the patients suffering from PeVD and evaluate the factors directly influencing QoL with emphasis on their distribution and frequency.

Materials and methods
The study involved 59 female patients from Department of Angiology diagnosed with PeVD admitted for endovascular treatment. They were asked to fill questionnaire based on disease-specific symptoms form designed by a working group in University of Manchester with questions acquired from gynecological QoL forms, e.g., Endometriosis Health Profile, Pelvic Pain Society assessment form, VEINES-Sym.

Results
As many as 81% of the respondents reported ailments such as pain and discomfort on the day of answering the questionnaire. Furthermore, 63% of the questioned women experience chronic pelvic pain for over 3 months. The reported pain occurs not only during menstruation (57,6%) but throughout the rest of the month as well in over half of the respondents (50,8%). It is quite often immersed with defecation (30,5%) and sexual intercourse (46%). The negative consequences of the pelvic pain included loss of appetite (50,8%) and sleep disturbances (73%). Almost two-thirds of the patients claimed not to be able to overcome the pain. As a consequence 40% of women attempted to alleviate the symptoms by taking the medication. NSAIDS were the first choice in 20 of the respondents, however, there were patients (n=3) who reached for stronger painkillers – opioids. There even happened to be cases of patients who reported taking antihemorrhagic agents in order to ease their symptoms.

Conclusions
The study revealed that persistent pain caused by PeVD often compels women to submit their everyday lives to it. Moreover, a significant number of them take medication in order to relieve their symptoms, mostly NSAIDs, chronically. Long – term repercussions for their overall health can be dire as those drugs are known for countless adverse effects. Therefore, prompt diagnosis and efficient treatment of not only symptoms, but also the underlying causes should be readily available as it could directly contribute to increasing the QoL of the patients with PeVD.

[1366] Menopausal symptoms most often experienced by women in Poland

Authors: Aleksandra Kargul, Aleksandra Olszewska
Affiliation: Medical University of Warsaw / Student Scientific Society of the Department of Gynecological Endocrinology
Trustee of the paper: dr n. med. Monika Grymowicz

Corresponding author: Aleksandra Kargul (aleksandra.k96@gmail.com)

Introduction
Menopause is a naturally occurring phenomenon in woman's life. However, this process can proceed in different ways depending on variable factors e.g. given populations or smoking habit. One of the main aspects of clinicians' focus of attention in this population group is managing menopausal symptoms.

Aim of the study
Data on the presence and severity of menopausal symptoms in the Polish population is not sufficiently studied. The aim of this study was to determine the most commonly occurring menopausal symptoms in the Polish population and to find possible correlations between the symptoms and socio-economic status, lifestyle, fertility, medications and the age of the first menstrual period.

Materials and methods
This cross-sectional observational study including 375 women (age 45–55 years) was conducted from June to September 2021. The data was mainly collected by means of a Google Form survey posted on various Internet groups. Statistical analysis was performed using t-test with the estimation of variance using the Brown-Forsythe test. P values <0.05 were considered significant.

Results
The mean age of the participants was: 50,65 years. 72,8% of the studied women declared sexual activity. More than a half of the interviewed women took in the past contraceptive pills (57,9%) or have ever smoked cigarettes (52,8%). Most of the women (77,1 %) gained weight after the age of 45. During the study 39% of the participants were still before menopause and reported having menstruation. The results have shown that the most frequent symptoms of perimenopausal period are hot flashes, palpitations, sleep disturbances, dizziness, headache, irritability, depression, general weakness, joint and muscle pain and tingling. These symptoms were much more severe in postmenopausal women compared to women who still menstruated ($p<0,05$). The survey showed that the symptoms related to genital tract were much more severe in women with chronic diseases ($p<0,05$) and women with offspring ($p<0,05$). The vaginal dryness and dyspareunia were also more severe in postmenopausal women ($p<0,05$). However, the influence of smoking and taking hormonal contraceptives on the intensity of menopausal symptoms was not demonstrated.

Conclusions
The most frequent menopausal symptoms in the studied population include hot flashes, palpitations, sleep disturbances, dizziness, headache, depression and thus will probably require the most attendance and holistic approach.

[1456] What do gynecologists, transplantologists and post-transplant women know about breastfeeding during immunosuppression? – a pilot study

Authors: Bartosz Korzeb, Daria Stelmach
Affiliation: 1st Department of Obstetrics and Gynecology, Medical University of Warsaw
Trustee of the paper: Prof. Bronisława Pietrzak,MD, PhD; Natalia Mazanowska, MD, PhD

Corresponding author: Bartosz Korzeb (bartoszkorzeb@gmail.com)

Introduction

Nowadays, the number of women treated with immunosuppressants is still growing, often they are young women, who need motherhood. Consequently, these women face the decision to breastfeed or not. Available studies recommend breastfeeding during immunosuppression, but the knowledge of patients and doctors about it might be insufficient.

Aim of the study

The study aimed at investigating the knowledge of gynecologists, transplantologists and women after transplantation about breastfeeding during immunosuppression and their source of information about it.

Materials and methods

We performed simultaneously two cross-sectional studies from February 1st 2022 till March 29th 2022. The first among 22 gynecologists (Group A) and 11 transplantologists (Group B) from the departments of Medical University of Warsaw. The second one among 38 female graft-recipients (24 after kidney and 14 after liver transplantation) of childbearing age (15-45 years) polled during their routine outpatient appointments, divided into two groups: 22 parous women (Group I) and 16 nulliparous women (Group II).

Results

The main immunosuppressive regimen (84,21%) was tacrolimus based. The majority of women (81,58%) were concerned about the possible harm to the babies through immunosuppressants in breastmilk. Average score for knowledge of the breastfeeding benefits was 51,05% (56,36% in Group I and 46,32% in Group II). Among parous women only 4 patients breastfed on immunosuppression. The decision on breastfeeding was influenced mainly by gynecologists' (75%) and transplantologists' (56,25%) counseling.

All the responding gynecologists and the majority of transplantologists (81,82%) know that breastfeeding is recommended and the benefits outweigh possible risks. As a potentially dangerous drug during breastfeeding 20 (90,91%) doctors in Group A and 9 (81,82%) in Group B correctly chose Mycophenolate Mofetil. Additionally 13 (59,09%) in Group A and 6 (54,55%) in Group B correctly chose Sirolimus. As a potentially safe immunosuppressant during breastfeeding in Group A: 21 (95,45%) doctors selected Prednisone, 18 (81,82%) Tacrolimus and Cyclosporine, and 17 (77,27%) Azathioprine. In Group B it was accordingly 10 (90,91%), 8 (72,73%), 7 (63,64%) and 3 (27,27%).

Conclusions

The women's knowledge about benefits from breastfeeding and possibility of it during immunosuppression is not satisfactory.

The doctors' knowledge seems to be at quite high level, with a slight advantage to gynecologists.

Oncology & Hematology

Date: 7th May 2022, 12:30 PM

Coordinator:
Anna Terlecka

Patronage:

Konsultant Krajowy w dziedzinie onkologii i hematologii dziecięcej

Prof. dr hab. n. med. Jan Styczyński

Konsultant Krajowy w dziedzinie Onkologii Klinicznej

Prof. dr hab. n. med. Maciej Krzakowski

Wielkopolskie Centrum Onkologii

Prof. dr hab. n. med. Andrzej Roszak

Polska Liga Walki z Rakiem

Honorary Patronage

[1171] Outcomes of TACE alone versus TACE combined with other treatment modalities in patients with hepatocellular carcinoma

Authors: Zofia Jankowska(1), Krzysztof Bartnik(2,3), Krzysztof Korzeniowski(3), Olgierd Rowiński(3), Grzegorz Rosiak(3), Tadeusz Wróblewski(4)
Affiliation: Medical University of Warsaw / 1 - Faculty of Medicine (4th year's student), 2 - Doctoral School, 3 - Second Department of Radiology, 4 - Department of General, Transplant and Liver Surgery
Trustee of the paper: Krzysztof Bartnik

Corresponding author: Zofia Maria Jankowska (zofiaajankowska@gmail.com)

Introduction
Transarterial chemoembolization (TACE) is first-line treatment modality for many patients with hepatocellular carcinoma (HCC) who are not surgical candidates. Multiple TACE sessions alone or combined with other treatment modalities are necessary for most patients according to the treatment stage migration strategy.

Aim of the study
In this study we aimed to compare the clinical effectiveness of TACE alone or in combination with various HCC specific therapies including: liver resection, orthotopic liver transplantation (OLTx), other locoregional therapies, sorafenib treatment and drug-eluting beads transarterial chemoembolization (DEB-TACE).

Materials and methods
In this retrospective study, we analyzed data of 267 consecutive patients (TACE monotherapy, n=169; TACE with other modalities, n=98) with HCC Barcelona Clinic Liver Cancer (BCLC) stage A/B who are not eligible for a treatment other than TACE at baseline. The outcome analyses were performed using Kaplan–Meier method with log rank test (Sidak correction) and the Cox proportional hazard model, while the overall survival (OS) was the primary study endpoint.

Results
OS of the entire cohort was 27 months (range 1-81). Median OS in TACE alone group (22 months) was significantly higher than in DEB-TACE group (16 months, p=0.049), but lower than in subjects that subsequently underwent OLTx (75% subjects censored, p=<0.001), resection (43 months, p=0.002) or other locoregional therapy (38 months, p=0.021). No significant association was noted between TACE combination with other locoregional therapy and survival in adjusted analysis (HR = 0.763 [95%CI: 0.48-1.21], p=0.25). There was significant association between initiation of sorafenib therapy and OS in TACE-monotherapy cohort (HR = 2.46 [95%CI: 1.37–4.41], p = 0.003).

Conclusions
The use of TACE as a bridging therapy for surgery provides the best treatment outcomes, underlining the importance of multidisciplinary patient management. Moreover, the combination of TACE with other locoregional therapies is not superior to TACE monotherapy in selected groups of patients and the therapy should be focused primarily on achieving local tumor control using treatment stage migration strategy. Unfavorable prognosis of patients who received sorafenib is probably due to inclusion criteria, which include disease progression.

[1390] Pancreatic Neoplasms: Comparison Between Younger And Elderly Patients

Authors: Sabina Kolawa, Apolonia Miążek
Affiliation: Department of General, Oncologic, Gastrointestinal Surgery and Transplantology; Jagiellonian University Medical College
Trustee of the paper: Jakub Kenig M.D. Pf.D. Prof. of Jagiellonian University

Corresponding author: Sabina Kolawa (sabina.kolawa@student.uj.edu.pl)

Introduction
Pancreatic cancer affects predominantly elderly patients. Almost two-thirds of patients are at least 65 years old and the average age of diagnosis is 70. Once the symptoms occur, only 20% of lesions are suitable for resection. Neoplasms of the pancreas include cancers, specifically adenocarcinoma and neuroendocrine neoplasms, as well as benign lesions, such as serous cystadenoma and precursors of adenocarcinoma: IPMN (Intraductal papillary mucinous neoplasm), MCN (Mucinous cystic neoplasm) and PanIN (Pancreatic intraepitelial neoplasia).

Aim of the study
The study aimed to compare the clinicopathological features of surgically resected pancreatic neoplasms between geriatric and younger patients.

Materials and methods
Histopathological records of patients hospitalised in the Department of General, Oncological, Gastroenterological and Transplant Surgery between 2019 and 2021 were reviewed. All patients with primary pancreatic neoplasms and complete data were analysed. A sample of 106 cases was divided into two age groups: ≥65 years old (n=59) and <65 yo (n=47). The geriatric group was later further divided into 3 subgroups with ages of 65-74 (n=45), 75-84 (n=13) and ≥85 (n=1), and analysed independently. Statistical analysis was thoroughly performed using Fisher exact and Mann-Whitney U tests as well as Spearman's rank correlation.

Results
The differences in cancer stage, grade and number of positive lymph nodes between the elderly and younger patients were not statistically significant. There was, however, a divergence in the distribution of histological types between the groups (p=0.006). IPMNs had a higher incidence in the elderly (15 versus 2 in the younger group), whereas PanINs were observed in the younger group only (n=5). The frequency of cancers was similar in both groups. Only the elderly showed a strong positive correlation (rho>0.5) between pathological grade and pT of neoplasms. No significant differences were found within the 3 geriatric subgroups regarding all of the above factors.

Conclusions
The findings of this study show that pancreatic neoplasms in patients qualified for surgery have similar stage, grade and count of positive lymph nodes regardless of chronological age. Therefore, the study suggests that age itself should not be considered a criterion of qualification for surgery. Further research involving postoperative course and survival is needed to draw reliable clinical conclusions.

[1394] Five-year survival of patients with cervical cancer, hospitalized at the Clinic of Oncology in the period from 2013-2015., treated with definitive and adjuvant HTRT: Experience of an oncology clinic

Authors: Ivana Milanovic, Tamara Drobnjak
Affiliation: University of Banja Luka
Trustee of the paper: Clinic of Oncology, Banja Luka

Corresponding author: Ivana Milanovic (icamilanovic4@gmail.com)

Introduction
According to data Globocan, cervical cancer is the second leading cancer in women and the fourth leading cause of dead.

Aim of the study
Aim of this study was determine the total five-year survival of patients with inoperable cervical cancer after chemoradiotherapy. The paper is conceived as an observational, retrospective, cross - sectional study and was conducted at the Oncology Clinic in Banja Luka.

Materials and methods
The data about patients with stage 1b to 4a cervical cancer were collected by examining the medical documentation, medical history and patohistological findings.

Results
It was found that 43% of patients were with stage 1b to 3a. The patients with stage 2b had a five-year survival rate of 75%, while the patients with stage 3a cancer had a five-year survival rate of 85.5%. The remaining 57% of the patients were with stage 3b to 4a. The patients with stage 3c cancer had a five-year survival rate of 58% and the patients with stage 3b cancer had a five-year survival rate of 57%.
One-year survival was recorded in 85% of patients, while three-year survival was recorded in 68% and five-year survival in 59%. The Kaplan-Mayer curve clearly shows that patients who are diagnosed with stage 3b to 4a cancer have a low chance of survival. The overall survival time was 37 months. Patients diagnosed with stage 1b to 3a cancer have a higher chance of survival and their average survival time is 54 months.

Conclusions
A high incidence of cervical cancer has been observed in the Balkans, which is associated with low levels of awareness.

[1425] Can blood count-derived inflammatory markers predict survival in patients with localized renal cell carcinoma?

Authors: Karolina Garbas, Łukasz Zapała, Aleksander Ślusarczyk, Piotr Zapała, Piotr Radziszewski
Affiliation: Department of General, Oncological and Functional Urology, Medical University of Warsaw, Poland
Trustee of the paper: Łukasz Zapała, MD PhD

Corresponding author: Karolina Garbas (zofiaajankowska@gmail.com)

Introduction
Localized or locally advanced renal cell carcinoma (RCC) remains a malignancy with a clinically significant rate of late recurrence, reaching up to 12%. Specific hematological markers of systemic inflammation are currently under investigation to be used in future prognostic models, as grading and staging alone appear to be insufficient when predicting patient's survival.

Aim of the study
We aimed at comparing the predictive value of various inflammatory markers as possible prognostic factors of survival in RCC.

Materials and methods
This was a retrospective single tertiary-center study. 495 patients diagnosed primarily with localized and locally advanced RCC, who underwent radical or partial nephrectomy, were included in the final analysis. The median follow-up time achieved 48 months.

Results
Patients who presented with higher neutrophil to lymphocyte ratio (NLR), platelet to lymphocyte ratio (PLR), systemic inflammatory response index (SIRI), systemic immune-inflammation index (SII), neutrophil to erythrocyte ratio (NER), derived neutrophil to lymphocyte ratio (dNLR), and lower lymphocyte to monocyte ratio (LMR) and hemoglobin to platelet ratio (HPR) had worse cancer-specific survival (CSS). In the multivariate analysis tumor stage, grade, age and high SIRI proved independent factors for CSS prediction. Tumor diameter and grade were independent predictors for recurrence-free survival (RFS). Age, grade and high NER were prognostic for overall survival (OS).

Conclusions
Markers of systemic inflammation, notably SIRI, SII, NLR and NER, may serve as prognostic factors, thus increase the predictive accuracy of already available and used models in localized and locally advanced RCC. Nevertheless, clinicopathological features (stage, grade and age) remain crucial prognostic factors for oncological outcomes in RCC patients treated with nephrectomy.

[1427] Clinical outcomes of patients with advanced soft tissue sarcomas treated with trabectedin – real-world evidence from a reference center

Authors: Paulina Filipowicz, Łukasz Lamparski
Affiliation: Medical University of Warsaw, Department of Soft Tissue/Bone Sarcoma and Melanoma, Maria Sklodowska-Curie National Research Institute of Oncology, Warsaw
Trustee of the paper: Paweł Sobczuk, MD

Corresponding author: Paulina Filipowicz (paulinafilipowicz7@gmail.com)

Introduction
Soft tissue sarcomas (STS) are a heterogeneous group of malignancies arising from mesenchymal tissues, of which the most prevalent histotypes are liposarcoma and leiomyosarcoma. Current guidelines indicate anthracycline-based chemotherapy as a first-line treatment in an advanced stage; however, there is a lack of consensus regarding next lines. Trabectedin constitutes one of the options for the second line and beyond.

Aim of the study
We aimed to analyze outcomes of patients with unresectable and metastatic STS treated with trabectedin in a routine clinical practice.

Materials and methods
Clinical and pathological data of consecutive patients diagnosed with STS and treated with trabectedin in the Maria Sklodowska-Curie National Research Institute of Oncology in Warsaw between 2008 and 2021 were used for retrospective analyses. Kaplan-Meier estimator, long-rank test and Cox regression were used for survival analyses.

Results
248 patients (138 females, 110 males), with a median age of 58 years (range: 25-87) at the start of the trabectedin treatment were included. The majority of patients had leiomyosarcoma (n=128, 51.6%), followed by liposarcoma (n=113, 45.6%). The most common localizations of the primary tumor were the abdominal cavity (38.3%), extremities (29%) and uterus (20.6%). 85.5% of patients underwent primary tumor resection. Trabectedin was administered mostly as a 3rd- or 2nd-line treatment in 49.2% and 34.3% cases, respectively. Patients received a median of 6 cycles (range: 1-77). A break or delay in a 3-week scheme occurred in 108 cases (43.5%) and dose reduction was necessary in 74 cases (29.8%). The treatment was discontinued in 222 patients (89.5%), mainly due to disease progression (72.6%). The median progression-free survival (PFS) was 5.1 months (95% CI: 3.7-6.4), with 1-year PFS rate of 29%. Factors significantly associated with longer PFS in multivariate analyses were age>60 years (HR 0.71, 95% CI: 0.53-0.95) and diagnosis of liposarcoma (HR 0.68, 95% CI: 0.51-0.92). The median OS was 19.1 months (95% CI: 16-22.1). Statistically longer OS was observed in females and patients who achieved at least disease stabilization.

Conclusions
In a real-world setting, outcomes of treatment with trabectedin are unsatisfactory but comparable to results of clinical trials. There are subgroups of patients who achieve better outcomes but there is a need for better characterization of prognostic factors for better personalization of the therapy

[1151] Male Breast Cancer after 20 Years of Treated Testicular Cancer, a Case Report

Authors: Mohammad Al-Share a* , Mohammad Abu-Jeyyab b* , Hanan Al-Asbahi c , Michleen Al-Awabdeh d and Maysaa Al-Khalaileh e
Affiliation: a Albasheer Hospitsl, Amman, Jordan. b Mutah University, Amman, Jordan. c G. Surgery Resident, Albasheer Hospital, Amman, Jordan. d JUST, Amman, Jordan. e BAU, Amman, Jordan.
Trustee of the paper: Al-Basheer Hospital

Corresponding author: Mohammad Abu-Jeyyab (mabujeyyab@yahoo.com)

Background

Breast cancer in male gender is rare with an incidence of 1% of all breast cancers. There are manytheories and risk factors that play a role in the development of breast cancer among males.The development of a second primary cancer is also rare. Herein we have a case of a male breast cancer that devolved after a 20 years of treated testicular cancer. There are many risk factors thatshould be studied to know correlation between the two diseases.In this case report we will show the presentation of the patient, discuss the risk factors and put our treatment plan.

Case Report

A 59-year-old male presented to the office complaining of a painful lump in his right breast. The patient noticed skin changes three months prior pain. The lump measured 15×20-mm and was firm and mildly tender (Picture 1) the patient stated that the lump had grown in the past three months. The patient has a history of orchiecdectomy surgery and radiotherapy for treatment of testicular cancer. The patient also had family history of the first degree with a cured testicular cancer

Conclusions

Male breast cancer is a rare condition that has abad prognosis than typical female breast cancer.There are many factors that can predispose the patient to develop a second primary cancer in hislife. There are a deficiency in the researchesabout the development of a second tumor afterhaving a testicular tumor. No enough data about
the epidemiology or prognosis of such a case

[1166] Refractory autoimmune hemolytic anemia - new drugs, a new life for the patient?

Authors: Marta Andrzejewska
Affiliation: Poznan University of Medical Sciences; Universidad de Murcia
Trustee of the paper: Elena Perez Ceballos, MD, PhD

Corresponding author: Marta Andrzejewska (78774@student.ump.edu.pl)

Background
Warm autoimmune hemolytic anemia (wAIHA) comprises 60-80% of all autoimmune hemolytic anemias. Erythrocytes are attacked by IgG autoantibodies or complement components. Approximately 50% of wAIHA are idiopathic, while the rest is secondary to an underlying disease. The condition presents with anemia symptoms and, in severe cases, jaundice and dark urine. Mild splenomegaly is relatively common. The diagnosis bases on clinical and laboratory evidence and the detection of autoantibodies with the direct anti-globulin test (DAT). Typically in wAIHA, the DAT pattern is solely IgG or IgG with complement C3. The first line treatment consists of corticosteroids.

Case Report
A 44-year-old female was admitted to the hematology clinic in January 2021 due to the diagnosis of wAIHA (anti-IgG, anti-C3c and anti-C3d: strongly positive). The patient started her treatment with prednisone 1 mg/kg/day with a poor outcome and recorded toxicity. The treatment was augmented with rituximab, resulting in a good response lasting for 3 months. The 3rd, 4th and 5th lines of treatment with various corticosteroids, immunosuppressants and chemotherapy were unfruitful. She also underwent partial splenic artery embolization. In September she started off-label treatment with daratumumab and sirolimus. Currently, the patient's laboratory results are normalizing (hemoglobin 9.6 g/dL, bilirubin 0.70 mg/dL, LDH 376 U/L) and transfusion support is no longer needed.

Conclusions
The management of wAIHA may be difficult and its outcome is very individual. The physician should propose the most effective treatment, if possible with new, off-label agents to make patient independent from transfusion support, increasing their quality of life.

[1204] Sudden blindness and severe neurological symptoms following second allogeneic hematopoietic cell transplantation in 23-year-old patient.

Authors: Julia Wierzbicka
Affiliation: Department of Hematology, Transplantation and Internal Medicine, Medical University of Warsaw, Poland
Trustee of the paper: Dr n. med. Jarosław Biliński

Corresponding author: Julia WIerzbicka (jjwierzbicka@gmail.com)

Background

Acute myeloid leukemia (AML) is the most common type of leukemia in adults, with a prognosis depending on the disease classification and its risk score. The established goals of the treatment are to obtain complete remission based on induction chemotherapy, maintain it after following consolidation cycles, and prevent the relapse of the disease. One of the relapse prevention method of is an allogeneic stem cells transplantation (allo-SCT) from HLA-matched related, haploidentical, or unrelated donor.

Case Report

A 23-year-old woman with relapsed AML, diagnosed 2 years earlier, was admitted to the hospital to perform haploidentical allo-SCT from her brother. The patient, due to high-risk disease has already undergone one allo-SCT from non-related donor 16 months ago. Actually, conditioning regimen consisted of fludarabine, cytarabine and total body irradiation with tacrolimus and mycophenolate mofetil as a graft-versus-host disease prophylaxis. Micafungin, acyclovir and ciprofloxacin were given as a prophylaxis for fungal, viral and bacterial infections. On day 3 post-transplant she developed fever, chills, hypotension and diarrhea. The blood test revealed Bacillus cereus and HHV-6 reactivation, therefore the combination of vancomycin, meropenem and sulfamethoxazole+trimethoprim were added. On day 11 post-transplant she suffered binocular vision loss accompanied by vomiting and nausea. Computed tomography reveled numerous hypodensive changes in left frontal and right occipital lobes and right cerebellar hemisphere. Left-sided muscle weakness and slight dysarthria occurred. All cerebrospinal fluid tests were negative. PRES syndrome (Posterior reversible encephalopathy syndrome) was most possible, but due to severe myelosuppression amphotericin B and voriconazole were initiated in the case of the CNS aspergillosis or cryptococcosis. In MRI done the nodular lesions with halo were visualized. Due to the breathlessness, decrease in saturation (82%) and possibility of severe cytokine release syndrome, oxygen therapy and steroids were added. As all the course of the disease could suggest CNS toxoplasmosis appropriate treatment was initiated. She gradually improved, with final resolution of all symptoms.

Conclusions

Diagnosis in severely immunosuppressed patients, is mostly based on indirect tests. Diagnostic workup must be broad, thorough and combined with empiric treatment.

[1416] Takotsubo Cardiomyopathy – a rare event in the course of lymphoma

Authors: Klaudia Zielonka
Affiliation: Student Scientific Association of Hematology, Medical University of Warsaw
Trustee of the paper: dr n. med. Joanna Drozd-Sokołowska

Corresponding author: Klaudia Zielonka (klaudiazielonka99@gmail.com)

Background
Treatment of lymphomas is associated with an increased risk of cardiotoxicity, especially when anthracyclines are administered. Takotsubo Cardiomyopathy (TC), a stress-induced reversible systolic dysfunction of the cardiac muscle, is however a rare cardiologic complication in lymphoma patients with only few case descriptions reported so far. Here we present a case of a patient with Hodgkin Lymphoma (HL) who developed TC.

Case Report
A 67-year-old woman reported a 2-year period of lymphadenopathy, with weight loss and fatigue. Several attempts to establish the diagnosis were undertaken, and a temporary diagnosis of sarcoidosis was made. Despite treatment with prednisone, the ailments did not subside. Eventually, biopsies of the lymph node and the liver were performed and HL, stage IVB according to the Lugano classification, was diagnosed.
On admission to the haematology department, the patient was cachectic, in a poor general condition (ECOG 4). On the second day of hospitalization, the patient developed dyspnoea. On auscultation, the crackles were present in the bases of the lungs, as well as signs of fluid in the right pleural cavity. Negative T waves were present in an electrocardiogram (ECG). Blood tests revealed elevated troponin concentration. An echocardiography (ECHO) was done showing widespread apical ballooning of the left ventricle with a left ventricular ejection fraction (LVEF) of 17%. The diagnosis of TC was made. Because of the condition of the patient, high clinical suspicion of TC, low platelet count, coronarography was not conducted. The patient received symptomatic treatment. The control imaging with ECHO showed a quick and sustained improvement of LVEF, reaching 57% after 9 days.
Despite the severe patient's condition, considered as a direct result of long-lasting HL, pre-phase CVP chemotherapy, without cardiotoxic anthracyclines was administered. The patient's cardiological condition, repeatedly controlled with ECHO, was stable. However, two days after chemotherapy initiation the patient's clinical status deteriorated due to septic shock, to which she succumbed on the next day. The blood culture specimens were positive for A. Baumani, susceptible solely to colistin.

Conclusions
This case highlights TC as an unusual complication in patients with lymphomas. Further research is needed to assess the real frequency of TS in haematological patients and to establish its impact on the outcome of lymphoma patients.

[1496] The definitive role of CEUS in an ambiguous case of renal cell carcinoma

Authors: Katarzyna Drelich
Affiliation: Students' Scientific Society at the Department of Interventional Radiology and Neuroradiology, Medical University of Lublin
Trustee of the paper: lek. Maryla Kuczyńska

Corresponding author: Katarzyna Derlich (k.drelich1111@gmail.com)

Background

Angiomyolipoma (AML) is a benign tumor consisting of abnormal vessels, smooth muscle and fatty tissue. Radiologically, AML is classified into three subtypes, according to the amount of fatty tissue, which is quantified by CT or MRI. Abundant adipose tissue is a characteristic feature on imaging. However, sometimes there is too little of it to be detected. This creates difficulties in differentiating AML from renal cell carcinoma (RCC), which is an insidious tumor accounting for approximately 2% of global cancer diagnoses.

Case Report

We present the case of a 60-year-old patient without clinical symptoms in whom a focal lesion in the parenchymal layer of the left kidney was detected by prophylactic ultrasound. The lesion was well-demarcated, hyperechoic, with no blood flow signals in the Doppler option. Based on the ultrasound findings a diagnosis of AML was made. In control US examinations the lesion remained stationary. To verify its nature, a CT scan was performed, revealing an isodense well-demarcated lesion with strong enhancement after contrast administration. In the axial projection, an area of adipose tissue was visible at the periphery of the lesion, identified as its component, supporting the diagnosis of AML. During a subsequent radiological consultation at the highly specialized medical center, another probable diagnosis was made - RCC. Coronal reconstruction of the CT showed that the renal capsule surrounding the tumor was distorted, allowing the subcapsular fatty tissue to protrude around the mass, thus mimicking the fatty component of the angiomyolipoma. CEUS examination with contrast agent was then performed three times. Rapid, robust contrast enhancement of the lesion was observed in the early arterial phase, followed by an earlier washout as compared to the surrounding renal parenchyma. Although the morphological US image was suggestive of AML, the enhancement pattern was suggestive of malignancy. The patient underwent laparoscopic resection of the renal tumor with organ sparing. Histopathological examination confirmed the diagnosis of RCC.

Conclusions

AML is most often detected incidentally during abdominal imaging examinations and patients are asymptomatic. Despite the "typical" picture of AML on ultrasound examination, further diagnostics is indicated to make a correct diagnosis and possibly confirm/exclude RCC.

Orthopedics & Traumatology

Date: 6th May 2022, 11:30 AM

Coordinator:
Olga Adamska

[1205] CLINICAL AND RADIOLOGICAL CHARACTERISTICS OF CONGENITAL VERTEBRAL DEFORMITY IN VACTERL SYNDROME: A SERIES OF 16 PATIENTS AND REVIEW OF THE LITERATURE.

Authors: Michał Markiewicz-Zahorski, Gonzalo Mariscal, Karen Weissman, Carlos Barrios, Eduardo Hevia
Affiliation: Jagiellonian University Collegium Medicum, Valencia Catholic University
Trustee of the paper: Gonzalo Mariscal

Corresponding author: Michał Markiewicz-Zahorski (1997markiewicz@gmail.com)

Introduction
VACTERL syndrome is a polymalformative disorder characterized by vertebrae, extremities, cardiac, airways and digestive tract defects. Due to small number of series addressing spinal deformities of patients with VACTERL syndrome, recommendations and guidelines of clinical management remain unclear.

Aim of the study
The objective of this study was to carry out a descriptive study of the clinical and radiological characteristics of congenital vertebral deformity in VACTERL syndrome as well as to compare conservative with surgical treatment. Additionally, a review of preexisting literature was performed.

Materials and methods
A multicenter retrospective study of patients with congenital scoliosis associated with VACTERL syndrome was carried out. We collected: type of deformity (formation, segmentation and mixed defects), associated anomalies, initial cobb angle, location of scoliosis, cobb angle at final follow-up, treatment (surgery group vs conservative group) and complications.

Results
We included 16 patients with VACTERL syndrome and congenital scoliosis. 50.0% of patients were female. The most frequent deformity was mixed vertebral defects (10/16, 62.5%) followed by formation defects (5/16 31.3%). Most frequent localization of deformity was the thoracic location (7/16 43.8%). 9 patients received surgical treatment versus 7 patients who were treated conservatively with progressive corrective casts. There were no differences in follow-up between the two groups. There were significant differences regarding the initial cobb (49.8±25.9 surgery group vs 25.3±9.4 conservative group; p=0.03). Regarding the total correction achieved at the end of follow-up, there were significant differences (-25.2±13.3 surgery group vs 5.1±18.0 conservative group; p=0.002).

Conclusions
There are no large case series dealing with congenital spinal deformity in VACTERL syndrome. We present a descriptive study of the characteristics of this uncommon association. Conservative treatment does not achieve satisfactory curve corrections compared to surgical treatment, although it prevents the progression of the deformity.

[1221] Is pole dance safe enough?

Authors: Katarzyna Kwas, Maciej Małolepszy
Affiliation: Medical University of Lodz
Trustee of the paper: MD PhD Adam Kwapisz

Corresponding author: Katarzyna Kwas (kwaskasia@gmail.com)

Introduction
Pole dance is a form of physical activity, which popularity has been growing among young females in Poland. This discipline is considered as a moderate-intensity exercise, improving health and cardiorespiratory fitness, which combines dance, sport, and physical recreations. However, due to its physical demand, pole dance may cause potentially severe injuries. According to literature 85% of all pole dancers reported some kind of trauma during training.

Aim of the study
Aim of the study was to determine the frequency and characteristics of the injuries in the female pole dance amateurs in Poland.

Material and methods
In this prospective, survey, case-control research, data were collected from young female pole dancers using online questionnaires. Survey was composed of 23 questions and concerned the type of injury, way of its treatment, complications, and the time of recovery. Approval of bioethics committee was acquired. Obtained data was assessed with the use of statistical tests.

Results
445 females (mean age = 30,8 years, SD= 5,67) were included into the study group. 42,9% of females reported injuries, amongst which the most common were contusions (60,2%) and luxations (19,9%). Shoulder (27,2%) and wrist (12%) were the most frequently affected structures. 80% of injuries required discontinuation in trainings, whereas 76% of all trauma cases demanded consultation with doctors or physiotherapists. The dependence of consultation frequency on the type of injury was statistically significant (p=0,0231). Further analysis stated that the risk factors for the injury were age (CI 95% 0,05 (0,01; 0,08), p= 0,0138) and the training frequency (CI 95% 0,39 (0,18; 0,61) p=0,003). The incidence of injury was also influenced by the duration of practice (CI95% 0,48 (0,29;0,66) p<0,0001). In 59,7% of cases, the injury considerably influenced respondents' daily activities.

Conclusions
Pole dance is a demanding sport with a high incidence of injuries, which most commonly affect upper extremity. Higher risk of injury may be determined by increasing age, duration of the training, and experience in this discipline.

[1222] Is ESIN that effective?

Authors: Katarzyna Kwas, Marcin Mostowy
Affiliation: Medical University of Łódź
Trustee of the paper: MD PhD Krzysztof Małecki

Corresponding author: Katarzyna Kwas (kwaskasia@gmail.com)

Introduction
Diaphyseal forearm fractures are a common injury resulting from a fall.
These fractures remain paediatric treatment challenge and may be treated non-surgically or surgically with use of intramedullary nails, plates or screws.

Aim of the study
The aim of the study was to assess the effectiveness of surgical treatment of forearm diaphysis fractures in paediatric population as well as the radiological parameters and follow-up.

Material and methods
Paediatric patients aged 1-17 diagnosed with forearm diaphysis fracture and minimal 12 months follow-up, were admitted to ward between 2018 and 2021. Patients with four X-ray pictures taken before and after surgery were qualified for the study. Statistical analysis was performed, bioethics committee approval was acquired.

Results
402 X-ray pictures of 201 patients (30,5% females, 69,5% males) with mean age 9,1 years old (SD = 3,2) were analyzed. 68% of fractures were caused by sport activity. All the patients had ESIN implanted, most commonly xswith TEN fi 2,0 fixation. 75% fractures affected both radius and ulna. Axial symmetry was preserved in AP and lateral view of all fixed bones. No statistical significance was noticed when comparing axial symmetry with ORIF or CRIF intervention, as well as comparing with open and close fracture or casting use. Complications occurred in 11,4% of patients (n=23). Etiology of the injury didn't influence the axial symmetry.
It was observed that statistically significant more complications were in the group with ORIF intervention ($p = 0,0025$).

Conclusions
ESIN stabilization is an effective way of forearm diaphyseal fractures management in children, with small rate of complication and proper axial symmetry.

[1255] Alpha angles changes in femoroacetabular impingement (FAI)

Authors: Tomasz Noras, Antoni Raciborski-Król, Jakub Wąsik, Katarzyna Kwas, Grzegorz Maciąg
Affiliation: Medical University of Lodz, Medical University of Warsaw
Trustee of the paper: MD PhD Radosław Grabowski

Corresponding author: Tomasz Noras (tomek.noras@gmail.com)

Introduction
Femoroacetabular impingement (FAI) is a pathological condition when contact between femur and acetabulum is increased, leading to gluteal pain and acceleration of osteoarthritis process. In order to stop these changes, the surgical management is necessary. The most common technique used is arthroscopic osteoplasty. Diagnosis of FAI is based on multiple parameters. According to the literature, angle created by long axis of femoral neck and line that connect center of the head of femur, socalled alpha angle may be helpful with FAI determination.

Aim of the study
The aim of the study was to determine the correlation between alpha angle and neck- head ratio in patients with femoroacetabular impingement (FAI).

Material and methods
Adult patients with diagnosed FAI, with set of X-ray pictures, leaded for hip arthroscopic osteoplasty were included into the study. 3 independent researchers with the use of RadiAnt Programme assessed X-ray pictures of alpha angles and neck-head ratios in affected sides before and after the surgery. Statistical analysis was performed, bioethics committee approval was acquired.

Results
83 patients (mean age = 44 years, SD= 10,7, MIN= 20, MAX=73) were included into the study. 69% of patients were males only 31% patients were females. 54,2% of patients had FAI in the right hip, and 45,8% left hip joint. The mean alpha angle presurgically was 83°(SD=16°) and postsurgically was 71°(SD=15°). The mean neck-head ratio before was 0,861 (SD=0,077) and after was 0,821 (SD=0,069). Positive correlation between postsurgically head-neck ratio and alpha angle was statistically insignificant and equalled (rs=-0,08, p=0,4). Positive weak correlation between these presurgical factors was observed (rs=0,124, p=0,12).

Conclusions
Observed results show that there was positive weak correlation between alpha angle and neck-head ratio. The normalization of the alpha angle was observed after the surgery as well as neck-head ratio values. Such results may indicate the positive effect of hip arthroscopic osteoplasty on measured parameters. However it is worth carrying out further research to observe the changes of mental and physical health of the patients who underwent surgery.

[1323] Can BMI predict the range of CMC joint arthroplasty?

Authors: Miss Klaudia Szatanik, Miss Magdalena Gomułkiewicz, Mr. Paweł Kamiński, Mr. Grzegorz Maciąg, Miss Katarzyna Kwas
Affiliation: SKN Ortopedii i Traumatologii
Trustee of the paper: MD Joanna Wojna, MD PhD Robert Rokicki

Corresponding author: Klaudia Szatanik (klaudia.szatanik@wp.pl)

Introduction

Arthroplasty of the carpometacarpal (CMC) joint is common procedure proposed to the patients with the carpometacarpal (CMC) joint arthritis. Such procedure includes the minimal resection of the base of the first metacarpal, reconstruction of ligaments and tendon interposition and insertion of the ball-in-socket total endoprosthesis. Depending on the width and height of the trapezium bone we are able to estimate the scope of resection the bone.

Aim of the study

The purpose of the study was to indicate the relationship between height, weight and Body Mass Index (BMI) and trapezium dimensions (height, width) in patients patient with performed CMC joint arthroplasty.

Material and methods

Adult patients with diagnosed osteoarthritis of the CMC joint and set of X-ray pictures were included into the study. The height and width of the trapezium were measured by 3 independent researchers. Statistical analysis was performed, bioethics committee approval was required.

Results

43 patients (mean age 56,3, SD=7,3) were included into the study, 95,4% of the patients were females. 32,5% of the patients had osteoarthritis of the left CMC joint. The mean weight of the patients was 71,31 (SD=12,6). The mean height was 163,36 cm (SD=5,7). The mean BMI was 26,74 (SD=4,8). The mean height of trapezium was 0,98 mm (SD=0,1) and the mean width was 1,45 mm (SD=0,1). The patients' BMI didn't influence height and width of trapezium ($p=0,64$, $rs=0,08$). Sex and age didn't have impact on height and width of trapezium ($p>0,05$). Also isolated height ($p=0,7$,$p=0,9$) and weight ($p=0,8$, $p=0,9$) didn't affect dimensions of the trapezium.

Conclusions

BMI, height and body mass of the patients did not influence the dimension of the trapezium, therefore parameters describing the study group cannot be used as predictors in trapezium presurgical assessment for CMC joint arthroplasty.

[1357] Analysis of the location of arterial perforators of the lower limb

Authors: Anna Kupczak, Jakub Adamus
Affiliation: Medical University of Warsaw, SKN Ortopedii Otwock
Trustee of the paper: Marcin Zlotorowicz, MD, PhD

Corresponding author: Anna Kupczak (akupczak01@gmail.com)

Introduction
The use of pedicled perforator flaps in the reconstruction of lower limb soft tissue defects allows it to be covered with tissue of similar skin appearance and subcutaneous layer thickness. This technique does not require microvascular anastomosis.

Aim of the study
The aim of the study is to determine the location of the largest arterial perforators of the anterior shin. The identification of the most common sites of perforators significantly shortens the time to pinpoint the exact location of perforators in an individual patient. It also allows to evaluate the feasibility of reconstruction with the use of flaps on the vascular pedicle.

Material and methods
Perforator locations were mapped on the anterior surface of the left lower limb in 20 healthy volunteers. Hand held Doppler was used. The 6 largest perforators were found and their selection was limited by the examination method. The location was determined in relation to two axes: the anterior margin of the tibia and the knee joint space.

Results
Dimensions measured in centimeters were summarized in three variants: 1) in cm as average distances from defined axes, 2) converted to percentages of tibial length and shin circumference, 3) in cm converted proportionally to average tibial length. On the anteromedial side 3 perforators were found with an average distances of 11.42 cm, 19.59 cm, and 31.6 cm from the knee joint space, respectively: 3.72 cm, 3.59 cm, and 4.13 cm from the anterior margin of the tibia. On the anterolateral side 3 perforators were also mapped at average distances of 11.6 cm, 16.98 cm, and 30.38 cm from the space of the knee joint and consecutively: 4.28 cm, 3.99 cm and 1.99 cm from the anterior margin of the tibia.

Conclusions
The arterial perforators on the anteromedial side of the shin are on average 3.81 cm and on the anterolateral side 3.42 cm from the axis defined by the anterior margin of the tibia. The distances from the axis of the knee joint space are more varied and define three levels of perforator position. On both the medial and lateral sides the uppermost of the perforators found are located on average at almost 1/3 of the tibial length. Going from the top, the next perforators are located approximately halfway along the length of the bone. The lowest perforators are located around the lower 1/5 of the length. Perforators in all patients were located in similar areas, however, with differences up to several centimeters. This allowed an average estimated determination of their occurrence on the anterior surface of the lower limb.

[1403] Hip hemiprosthesis due to femoral neck fracture in elderly population – are we doing it right ?

Authors: Dawid Jegierski, Krystian Żarnovsky, Grzegorz Maciąg, Olga Adamska, Hanna Tsitko, Maciej Świercz, Marcin Łapiński, Martyna Budzińska, Monika Dorocińska, Tomasz Kordyaczny,
Affiliation: Department of Orthopedics and Rehabilitation, Międzyleski Specialist Hospital, Medical University of Warsaw
Trustee of the paper: Bartosz Maciąg, MD

Corresponding author: Dawid Jegierski (jegierski.dawid@gmail.com)

Introduction
Femoral neck fracture (FNF) is one of the most common orthopaedic trauma affecting elderly population. In elderly population standard method is hip hemiarthroplasty and total hip arthroplasty. In hip hemiprostheses, where the acetabulum is not tampered with, surgeons mainly have to reconstruct the femoral offset and the length of the limbs. Surgeons are focused on this factors to obtain the correct gait biomechanics and a satisfactory surgical outcome for the patient.

Aim of the study
The aim of this study is to examine the radiological results of patients after partial hip arthroplasty for femoral neck fracture and to evaluate the reconstruction of the femoral offset using standard neck angle stems.

Material and methods
A consecutive series of 116 patients who were diagnosed with femoral neck fracture qualified for and treated with partial hip arthroplasty between January of 2017 and December of 2021 was identified. On preoperative images, the neck angle and the femoral offset on the healthy limb were measured, and the femoral neck fracture was classified using the Pauwels and Garden scales. The femoral offset of the operated limb was measured on the postoperative X-rays. It is a retrospective study in which standardized stems were used.

Results
There was significant positive moderate correlation between neck-shaft angle value and femoral offset change ($r=0.568$, $p<0.0001$). There was a statistically significant difference between femoral offset change and neck-shaft angle value (24:52 vs 14:7, $p = 0.005$). In patients with coxa vara (the neck-shaft angle <130 degrees) the change in femoral offset was more often <-5mm, whilst in patients with standard or coxa valga (neck-shaft angle =130 or >130 degrees) the femoral offset in most cases was >-5mm. Only less than half of operated patients had the femoral offset restored within safe range (between -5 to 5mm).

Conclusions
Our study proved that it is hard to achieve femoral offset within a safe range while performing partial hip arthroplasty in patients with coxa vara. The topic of using high offset stems in partial hip arthroplasty has not been thoroughly researched on the world. However, taking into account the results of our article, during a hip hemiprosthesis surgery due to femoral neck fracture, the neck-shaft angle of the healthy hip should be measured and the use of a high offset stem for varus hips should be considered in order to improve the clinical outcome of our treatment and improve the quality of life and functioning of the patient.

[1411] Joint line level and posterior condylar offset changes during total knee replacement with use of gap-balancing and measured resection techniques - matched cohort study

Authors: Tomasz Kordyaczny, Maciej Świercz, Dawid Jagierski, Marcin Łapiński Grzegorz Maciąg, Hanna Tsitko
Affiliation: Medical University of Warsaw, Department of Orthopedics and Rehabilitation
Trustee of the paper: Bartosz Maciąg, MD

Corresponding author: Tomasz Kordyaczny (tom.kordyaczny@gmail.com)

Introduction
Even little changes in joint line level can significantly alter postoperative outcomes of total knee replacement wherein elevation of the joint line is associated with more serious complications than its depression. Measured resection (MR) and gap balancing (GB) techniques are used to determine bone cuts intraoperatively. Both are considered good regarding restoration of anatomical relations in the knee joint.

Aim of the study
The study was conducted to determine which technique is superior in restoring joint line level and posterior condylar offset (PCO) in total knee arthroplasty procedure using asymmetrical prosthesis components.

Material and methods
A matched-cohort study with 99 patients after single-leg TKR included. The procedure was performed with use of asymmetrically designed components. MR technique was applied in 41 knees and GB technique was applied in 58 knees. Joint line level and posterior condylar offset were assessed pre- and postoperatively on radiographs with standard measurement protocol.

Results
Utilizing the GB technique was correllated with statistically significant (p value <0,0005) joint line elevation and more often resulted in over 2 mm elevation than MR technique application. Both techniques were comparable regarding PCO restoration.

Conclusions
With the use of asymmetrical components in TKR, MR technique is superior to GB in joint line level restoration but both appear to have similar outcome in PCO restoration.

[1424] Femoral component rotation of robotic- assisted total knee arthroplasty in comparison to conventional jig-based technique- a retrospective cohort study.

Authors: Olga Adamska (1), Jakub Świderek (2), Małgorzata Poniatowska (3)
Affiliation: 1. Medical University of Warsaw, 2. Medical University of Bialystok, 3. University of Zielona Góra
Trustee of the paper: Krzysztof Modzelewski, MD

Corresponding author: Olga Adamska (olgaadam98@gmail.com)

Introduction
Accurate alignment of the components and soft tissue balancing have been reported as keypoint parameters in Total Knee Arthroplasty (TKA). Fluctuations of rotation greater than 3° varus/valgus will increase the rate of loosening, which can further lead to abnormal soft tissue tension and alter the functioning. Robot-assisted TKA (RaTKA) has been designed to increase the precision of the implantation of the components. These effects are measurable by the patient's satisfaction and range of motion. It can also be evaluated immediately after the operation, using imaging methods.

Aim of the study
To investigate differences in between the results of femoral component rotation after conventional surgery and robotic systems- NAVIO and CORI.

Material and methods
244 patients were enrolled to participate in the study and allocated in two equal abundance groups. TKA procedures were performed in line with indications. Operations were held in a single- center hospital by one surgeon over a time from June 2020 to January 2022. The prosthesis implanted were identical, comprising Journey II BCS. Due to a strict recruitment regimen, patients were randomized. The post-operative measurements were performed according to the Berger protocol. Femoral rotation was defined as the angle subtended by a line in between the apices of the femoral epicondyles and the most posterior point of the condylar components. The alignment evaluation was measured via 3D CT scanning.

Results
In the knees that underwent RaTKA, the femoral components were rotated by 1.5° ± 1.16°. In the knees that underwent conventional technique surgery the results were 3.1° ± 1.22°. The RaTKA showed statistically significant smaller results in femoral rotational alignment ($p = 0.002$). All the measurements showed high intra- and inter-observer reliability.

Conclusions
RaTKA showed a different range of rotational alignment compared to the conventional surgery in the sagittal plane of the 3D CT scan. The results of the study show that robotic navigation development brings significant progress into TKA precision. The outcomes disagree with a dogma of 3° femoral external rotation, that was thought to be the desired value in TKA. The results show an urgency for a more individualized approach. The results of navigation implicate the accuracy of its use in the process of gaining experience by young doctors. Through the stepwise scheduled programme, the young specialist is protected from mistakes in gap balancing, by what facilitates proper fixation of femoral component.

[1434] Postoperative improvement in patients' lipidogram following arthroplasties of the big joints

Authors: Jakub Świderek (1), Olga Adamska (2)
Affiliation: 1. Medical University of Bialystok, 2. Medical University of Warsaw
Trustee of the paper: Artur Stolarczyk M.D., Ph. D.

Corresponding author: Jakub Świderek (j.swiderek98@gmail.com)

Introduction
The mechanism of action of anesthetics mainly consists of inhibition of lipid heterogeneity by reducing lipid raft formation. Preferable positions for anaesthetic molecules are cholesterol-poor, disordered domains. Thus, the site of action of general anesthesia seems to be not simply the cell membrane, but dense cholesterol molecules. It contributes to the improvement of patients' lipidograms.

Aim of the study
To evaluate prospectively an influence of total arthroplasty of the big joints and administered anaesthetics on the patients' lipidogram.

Material and methods
30 patients (age: 63,3 ± 9,92)(female 56,67%, male 43,33%) were referred to total knee arthroplasty (70%) or total hip arthroplasty (30%) due to osteoarthritis. Patients were hospitalized, taken blood tests, and operated from November 2020 to May 2021. The average body weight was: 82,4 ± 13,42kg, BMI: 29,70± 13,42. Patients had multiple comorbidities and presented untreated hypercholesterolemia. All of the participants obtained surgery. Agents utilized for regional anesthesia were: atropine, fentanyl, propofol and rocuronium or bupivacaine. The blood samples collection took place before the surgery and at 2, 6 and 12 weeks of the follow up period and were meant to analyze their lipidograms and hemoglobin(hb) values. Lipids parameters were determined with the ARCHITECT analyzer (ABBOTT). The analyzed values were marked by the enzymatic method: triglycerides (TG), total cholesterol (TC); using the ASD (Accelerator Selective Detergent): High-Density-Lipoprotein cholesterol (HDL); and using LSD (Liquid Selective Detergent) method: Low-Density Lipoprotein cholesterol (LDL). Hb value was tested with the XN-550 analyzer (SYSMEX) and determined using the SLS (Sodium Lauryl Sulfate) method.

Results
The majority of patients presented a developed lipid profile after the surgery in comparison to the preoperative results. The analysis revealed a significant decrease in serum LDL (105,41± 33,26), TG (127,41 ± 51,03), TC (183,29 ± 19,60) after 12 weeks of the follow up period, than before the surgery when values were: LDL (118,72±71,15), TG (144,21± 76,19), TC (194,72± 46,97). The HDL levels 12 weeks after the surgery (57,76± 9,69) did not meaningfully increase than before the surgery (55,17± 13,20).

Conclusions
Patients undergoing the orthopaedic operations presented advantageous lipid profile. The tendency was maintained for the 12 weeks. An improvement in outcomes shows probability a correlation with anaesthetics administration.

[1438] Can shift of the center of rotation of the hip joint after total hip replacement be determined by acetabular roof angle?

Authors: Martyna Budzińska
Affiliation: Department of Orthopedics and Rehabilitation, Medical University of Warsaw
Trustee of the paper: Bartosz Maciąg, MD

Corresponding author: Martyna Budzińska (martynabudzinska1@gmail.com)

Introduction
Total hip replacement (THR) is one of the most widely performed operation in orthopaedic surgery. It is also stated as the most efficient method of treating end-stage hip osteoarthritis. One of the goals of THR is to restore center of rotation (COR) of the hip joint, which affects muscle tension and distribution of forces in the joint. Several methods of reconstructing COR have been developed, but there is no study describing influence of acetabular roof angle on restoring COR and proper acetabular cup placement.

Aim of the study
To asses if there is any correlation between acetabular roof angle and reconstruction of the COR after THR.

Material and methods
This study included a cohort of 150 patients, diagnosed with end-stage hip osteoarthritis, who underwent THR in 2021. The group was subjected to retrospective analysis. To enable accurate measurements both preoprative and postoperative pelvic x-rays were made. Statistical analysis was conducted on the basis of measurements.

Results
There was a statistically significant positive weak association between acetabular roof angle and the acetabular offset (p=0.002). Analysis also revealed statistically insignificant positive correlation between the angle of the roof of the acetabulum and reconstruction of the COR (p=0.097), as well as between acetabular roof angle and total offset (p=0.29) and inverse relationship between acetabular roof angle and femoral offset (p=0.39).

Conclusions
The study determined that acetabular cup placement in relation to the transverse axis is determined by acetabular roof angle measured preoperatively. Medialisation of the acetabular cup may be caused by surgeon's subconscious intention to cover prosthetic cup by bone floor. However, restoration center of rotation remains unaffected by the angle of the roof of the acetabulum.

[1460] The effect of lockdown during the COVID-19 pandemic on proximal femur anatomic disruption: A multi-centre study in Kosovo.

Authors: D.Musliu, V.Komoni, R.Jashari, D.Hoti, E.Kelmendi, G.Elezi, J.Ajdini, A.Kafexholli
Affiliation: Institute of Anatomy, Faculty of Medicine, University of Prishtina. Clinic of Orthopedics, University Clinical Center of Kosovo.
Trustee of the paper: Dijon Musliu

Corresponding author: Dijon Musliu (dijonmusliu@gmail.com)

Introduction
The WHO on March 11, 2020 declared the outbreak of new coronavirus infections as a global pandemic. With the onset of the pandemic globally, measures to restrict movement were imposed in our country as well.
As is the case for the rest of the world, orthopedics and trauma services in Kosovo have been severely affected by the COVID-19 pandemic.
All planned interventions were postponed so that all hospital resources were directed towards the management of the COVID-19 pandemic. Due to restrictive measures the number of motor vehicle accidents was greatly reduced worldwide.
However, patients with fractures caused by low energy or fragility presented constantly in the emergency centers.

Aim of the study
The aim of this study was to determine the number of patients operated on due to proximal femur fracture (PFF) during the period when movement restriction measures (lockdown) were imposed in Kosovo. As well this study aims to compare the number of cases for the same period for the previous year (2019) and the coming one (2021) in order to have a better look on the impact of lockdown on low energy hip trauma.

Material and methods
Before starting the study, the permission for hospital record access was taken. This study includes 285 patients who underwent surgery due to PFF in one of the four centers included on the study. The data containing time of admission, patient age and gender as well as diagnosis and treatment of choice were recorded. Statistical processing was done through IBM SPSS v.23. For categorical data the chi-square test was used.

Results
62% of our patients were of female gender and we had a statistically significant difference between genders. The capital city of Prishtina had the largest number of admitted patients with 59%. The most common diagnosis was trans-cervical femoral neck fracture in 52% of cases. The most affected age-group was the 81-90 years old age-group.

Conclusions
Even though there was a national lockdown for the 13th of March - 1st of October 2020 period in our country the hip trauma in elderly patients continued to occur with almost the same ratio when compared to previous or coming year. Same studies were conducted in England, Spain, France, Italy and Turkey and our results generally compare with other results.

[1461] Impact of total knee replacement on ankle joint alignment

Authors: Marcin Łapiński
Affiliation: Medical University of Warsaw / Department of Orthopaedics and Rehabilitation
Trustee of the paper: Bartosz Maciąg, MD

Corresponding author: Marcin Łapiński (s071447@student.wum.edu.pl)

Introduction
Total knee replacement is regarded as the best treatment option for patients with end-stage osteoarthritis. This procedure corrects limb alignment and therefore improves biomechanical gait parameters. Restoration of the proper knee mechanical axis has a proven impact on the hip joint at least its range of motion. However, very little is known about its influence on other lower limb articulations

Aim of the study
The purpose of this study is to evaluate whether total knee replacement affects ankle joint alignment.

Material and methods
This prospective study included 32 patients (18 females, 14 males) who had undergone total knee replacement due to primary osteoarthritis. They were divided into two groups depending on the degree of knee coronal alignment deformity: group 1 (<10° varus deformity), group 2 (>10° varus deformity). All patients' coronal knee malalignment was corrected intraoperatively to restore native joint biomechanics. In every case a standard preoperative and postoperative (6 weeks following the surgery) radiological examination was performed. Obtained antero-posterior full-leg weight-bearing radiographs were used to measure lower limb mechanical axis (HKA), medial proximal tibial angle (MPTA), lateral distal femoral angle (LDFA), lateral distal tibial angle (LDTA), ankle joint line orientation angle (AJOA) and tibial plafond talus angle (PTA).

Results
Statistically significant difference was noticed only in terms of HKA ($p < 0.01$) and LDFA ($p < 0.03$) change. Alterations in the rest of analyzed parameters remained negligible. Comparison of group 1 and group 2 showed significant differences solely in MPTA ($p < 0.03$) and LDTA ($p < 0.02$).

Conclusions
The correction of knee joint malalignment does not significantly affect ankle joint parameters. Any discomfort, ankle pain or gait disorders after total knee replacement seem to have a different origin. For this reason surgeons should keep in mind that total knee replacement may not be the only surgery needed in multiarticular mechanical axis deviations and if necessary broaden the diagnostic process and engage other treatment methods in patients, especially those complaining about ankle joints.

Psychiatry & Clinical Psychology

Date: 6th May 2022, 11:30 AM

Coordinators:
Jędrzej Machtyl
Zuzanna Kamińska

Patronage:

National Consultant in the field of Psychiatry

Prof. dr hab. n. med. Piotr Gałecki

National Consultant in the field of Child and Adolescent Psychiatry

Dr n. med. Aleksandra Lewandowska

Director of the Institute of Psychiatry and Neurology

Prof. dr hab. n. med. Halina Sienkiewicz-Jarosz

Regional Consultant in the field of Psychiatry

Dr hab. n. med. Maria Teresa Radziwoń-Zaleska

Regional Consultant in the field of Child and Adolescent Psychotherapy

Dr n. med. Agnieszka Kałwa

[1161] Has the COVID-19 pandemic influenced individuals with Eating Disorders? Impact on the symptoms, treatment and mental health

Authors: Alicja Jodczyk
Affiliation: Medical University of Warsaw, Students' Scientific Group of Lifestyle Medicine, 3rd Department of Internal Medicine and Cardiology
Trustee of the paper: Dr Daniel Śliż

Corresponding author: Alicja Jodczyk (alicja.jodczyk@gmail.com)

Introduction

During the COVID-19 pandemic, eating disorders (ED) symptoms could be exacerbated by disruption to daily activities and routine, social isolation, media exposure, increased fear of food shortages or contagion and limitations in access to protective sources and treatment.

Aim of the study

To investigate the impact of prolonged COVID-19 pandemic on patients with the diagnosis of ED (AN-Anorexia Nervosa, BN-Bulimia Nervosa, AAN-atypical anorexia nervosa, BED-binge- eating disorder, and other specified or non-specified eating disorders) in Poland.

Materials and methods

The survey containing authors' questions was distributed between 7th April and 12th June 2021 in the tertiary care psychiatric clinic and via online methods. Sociodemographic data such as age, gender, diagnosed ED, living and occupational situation were collected. Other questions involved: the history of COVID-19 infection, the consequences of the pandemic on previous symptoms of ED and onset of the new ones, the impact on the treatment, general psychopathology symptoms and the impact of the pandemic and social media (SM) usage on mental health.

Results

198 (79.84%) participants met the study conditions. 195 (98.97%) were women and 3 (1.53%) did not want to specify their gender. The mean age was 21.72±9.00 years old. 50.51% (n=100) suffered from AN, 22.73% (n=45) BN, 11.62% (n=23) BED, 1.52% (n=3) AAN, 13.64% (n=27) other ED. 74.75% (n=148) reported previous or past SARS-CoV-2 infection. 78.79% (n= 148) agreed that the pandemic resulted in worsening of their ED symptoms, 42.93% (n=85) reported the onset of new symptoms of the ED. Negative impact of the pandemic on the treatment of ED was reported by 57.58 % (n=114). 81.82% (n=162) claimed that the pandemic caused a deterioration in the quality of their life. Negative changes in mental health were reported by 88.89% (n=176). 91.92% (n=182) increased the time spent on SM and 54.04% of them claimed that it had a negative impact on their mental health.

Conclusion

The results indicate the magnitude of deterioration in ED symptoms during the COVID-19 pandemic and suggest the possibility of increased help-seeking of individuals with ED after the pandemic. Raising the awareness of the problem in Poland and worldwide is crucial to provide comprehensive care for individuals with ED and to apply an appropriate treatment strategy.

[1177] Association of change in anxiety with beliefs in conspiracy theories in the Latvian student population during the COVID-19 outbreak.

Authors: Sindija Mairita Pīlāga, Prof. Konstantinos N. Fountoulakis, Assoc. Prof. Daria Smirnova, Asst. Prof. Jeļena Vrubļevska
Affiliation: Faculty of Medicine, Riga Stradins University, Riga, Latvia.
Trustee of the paper: Asst. Prof. Jeļena Vrubļevska

Corresponding author: Sindija Mairita Pīlāga (sindija.pilaga@inbox.lv)

Introduction

The COVID-19 pandemic has made an impact on every student` ordinary life, mental health, including anxiety. Not only pandemic but beliefs in different conspiracy theories have as well spread across the world.

Aim of the study

This study aims to investigate the effect of COVID-19 pandemic on self-reported changes in anxiety and their association with beliefs in conspiracy theories.

Material and methods

This was a cross-sectional international study where university and college students were asked to fill the self-report online questionnaire during the state of emergency from 08.12.2020. till 21.02.2022. Statistical analyses were made using Microsoft Excel, SPSS (Pearson's chi-square test).

Results

The study included 1047 students. Change in anxiety in comparison with time before COVID-19 experienced as worsening by 66% (N=691), 26.8% (N=281) had no change, and 7.2% (N=75) had improvement. In total 69.3% of all women reported the change in anxiety as worsening. A total of 63.5% of participants who did not have mental health problems in the past claimed that their mental health in terms of anxiety worsened. Noteworthy, 71.5% of students with previous mental health problems noted worsening in anxiety. Of those who`s anxiety had worsened, 58.0% were not working. In total 82.2% of those who believed in possibility that the earth is flat rather than a spherical had worsening in anxiety. Meanwhile, 8.2% students who did not believe and 2.6% who believed in the statement that secretly a chip will be included in the COVID-19 vaccine in order to mark people, reported improvement in anxiety. Of those participants who did not believe that COVID-19 outbreak is a deliberate creation of the world's powerful leaders to create a global economic crisis claimed improvement in anxiety comparing with those who believed a little bit (8.9% and 3.9%, respectively). Improvement in anxiety reported 8.8% of students who did not believe and 4% who believed a little bit in the statement that vaccines in general are dangerous and should be avoided.

Conclusions

The study showed that emotional has worsened in relation to anxiety. Participants who were female, not working and had history of mental disorder more often reported worsening of anxiety. Believes in different conspiracy theories are associated to worsen effect on change in anxiety rather than improvment. This study could help to evolve a plan in future for dealing with psychological support for students` population.

[1220] Evaluation of the patients' satisfaction with psychiatric health care service depending on the depression symptoms using adapted PIPEQ-OS tool

Authors: Sakele Nina; Taube Maris
Affiliation: Riga Stradins University
Trustee of the paper: Taube Maris

Corresponding author: Sakele Nina (nina.shakel@gmail.com)

Introduction

Patient satisfaction is an important and commonly used indicator for measuring the quality of health care. Numerous studies around the world have shown that it is the satisfaction of patient with inpatient care that correlates positively with the compliance and disease outcomes in the field of psychiatry (Köhler, Stephan & Unger, 2014; Kavalnienė R, Deksnyte A, 2018) . However, database on the influencing variables in a general psychiatric inpatient sample is still small.

Aim of the study

The aim of the study was to determine patients' satisfaction with the quality of mental health care services in Latvia in the subacute inpatient psychiatric ward in Jelgava, Latvia using the PIPEQ-OS (Psychiatric Inpatient Patient Experience Questionnaire) tool and examine its relationship to depressive symptom severity.

Material and methods

A cross-sectional study was conducted 01.01.20221-31.10.2021 in patients with Depressive episode (F 32.XX; F33.XX) and Adjustment disorders (F 43.2X) who have been hospitalised in hospital Gintermuiza. The study tool PIPEQ-OS was an adapted two-language (latvian and russian) questionnaire for self-assessment of patients' satisfaction with treatment. A total number of 99 respondents have been analysed in the thesis work.27 diagnosed with depressive episode, 40 were diagnosed with recurrent depressive disorder and 32 of respondents had Adjustment disorder diagnosis.

Results

The depression severity prevalence for patients was following: 29 study participants did not have depression symptoms, 43 of participants showed mild depression symptoms, 11 of participants showed moderate depression symptoms, 10 of participants showed moderately severe depression symptoms and 6 of participants showed severe depression symptoms. When analysing the questionnaire items, – the satisfaction rate being from 65.1%-98.0%. The lowest rated question was No.11 with 65,1% reporting good satisfaction. The highest rated questions were No.6 and No.14 with 98%. There was statistically significant correlation between depression symptom severity and reported satisfaction levels in questions No. 6 (r_s=-0.23, p=0.032), No. 8 (r_s=-0.39, p<0.005), No. 13 (r_s=-0.29, p=0.003), No. 19 (r_s=-0.51, p<0.005), No. 20 (r_s=-0.20, p=0.46).

Conclusions

Patient depressive symptom severity correlated negatively with five questions from the questionnaire. It supports the primary aim of the study, showing that more severe depressive symptoms correlated with lower satisfaction with received healthcare.

[1310] Occupational Burnout Among Polish Paramedics During the COVID-19 Pandemic

Authors: Wei-Ling Liu, Srishti Bhagat, Julia Zyzańska, Magdalena Łazarewicz
Affiliation: Psychological Student's Science Club PSYCHE, Department of Medical Psychology and Medical Communication, Medical University of Warsaw
Trustee of the paper: Magdalena Łazarewicz, MA, PhD

Corresponding author: Wei-Ling Liu (liujenny.lj@gmail.com)

Introduction
The COVID-19 pandemic has significantly increased workload of all frontline healthcare workers. As a consequence, mental distress and burnout have become a crucial concern for all frontline workers. Among all healthcare staff, paramedics are more susceptible to the negative impact of burnout due to the nature of their work environment.

Aim of the study
The aim of the study was to determine the prevalence of burnout and its associated factors among paramedics currently working in the healthcare facilities in Poland.

Material and methods
Self-reported data from a web-based sample of Polish paramedics (N=80, 69% male) was collected during the 4th period of the COVID-19 pandemic. The questionnaire consisted of socio-demographic questions and burnout assessment, which was performed using the Oldenburg Burnout Inventory (OLBI) and the customized questions related to work environment. SPSS Statistic 28.0 was used to analyze the data. Independent sample T test and Spearman's rho were run to investigate the relation between contributing factors and the severity of burnout.

Results
The mean total score of the OLBI scale was 43.9, which indicated a moderate severity of burnout (score > 44). The scores for OLBI disengagement and exhaustion subscales were 21.3 and 22.6, respectively. There was positive correlation between an OLBI score and the participants' salary compensations (r= .359, p=.001), increased workload outside of their duties (r= .288, p=.010), conflicts inside the team that affect the working environment (r= .245, p= .029), working with inadequately prepared new workers(r= .230, p=.040), and the lack of information given at the beginning of the pandemic (r= .260, p=.020). The negative correlation was seen in the risk factor linked to participants' health statuses (r= -.305, p = .006).

Conclusions
The COVID-19 pandemic highlights the prevalence in workplace burnout among paramedics. This study outlines the strong association between various contributing factors and the work environment of paramedics, and proper measures such as providing a higher remuneration and a better teamwork organization may lower the risk of occupational burnout.

[1417] Impact of rumination on subjective and objective memory impairment in major depressive disorder

Authors: Joanna Szyszkowska (1,2), Aleksandra Bala, PhD (2,3)
Affiliation: 1) Medical University of Warsaw 2) University of Warsaw, Neuropsychology Department 3) Medical University of Warsaw, Neurosurgery Department
Trustee of the paper: Aleksandra Bala, PhD

Corresponding author: Joanna Szyszkowska (szyszkowskaj1997@gmail.com)

Introduction
One of the main symptoms of depression is cognitive impairment (CI). It is divided into subjective, i.e. perceived by the patient, and objective CI, which is measured by neuropsychological tests. The intensity of subjective and objective CI is not correlated, and the subjective CI is more intense. Both types of cognitive impairment lower the quality of life and productivity. Rumination is one of the cognitive distortions in depression and could impact cognitive functioning.

Aim of the study
The purpose of the study was to investigate the link between rumination, depressive symptoms, objective memory deficits, and subjective cognitive impairment.

Material and methods
The study was performed through the online PsyToolkit platform. 93 patients with depression and 168 healthy controls were enrolled in the study. Participants completed questionnaires and performed a memory task that contained emotional words (from Nencki Affective Word List). Depression symptoms were measured using the Beck Depression Inventory-II, subjective cognitive impairment with the Perceived Deficits Questionnaire-20, and intensity of rumination with the Polish Questionnaire of Rumination. Data from the memory task were processed in RStudio 1.2.5 and SPSS 27 was used for statistical analyzes.

Results
Subjective cognitive impairment ($p < .001$) and rumination ($p < 0.001$) were higher in patients with depression. They also had a higher error rate than healthy controls ($p = 0.021$), especially in words from the neutral ($p = 0.008$) and happiness category ($p = 0.031$). However, there was no association between subjective cognitive impairment and performance in memory tasks. The regression analysis showed that depressive symptoms (Beta = 0.489), intensity of rumination (Beta = 0.187), and diagnosis of depression (Beta = 0.143) are better predictors of subjective cognitive deficits than objective performance on a memory task (Beta = -0.039; $p = 0.391$). The model explains 46.9% of the variance, $F(4,256) = 58.520$; $p < 0.001$.

Conclusions
The study shows that subjective cognitive impairment is more closely related to rumination than to actual cognitive deficits among healthy participants and patients with major depressive disorder. These findings can be used in the treatment of cognitive impairment in depression.

Surgery

Date: 6th May 2022, 11:30 AM

Coordinators:
Emilia Włoszek
Weronika Zając

Patronage:

Konsultant Krajowy w
dziedzinie Chirurgii Dziecięcej

Prof. dr hab. Janusz
Bohosiewicz

Konsultant Krajowy w
dziedzinie Chirurgii Ogólnej

Prof. dr hab. Grzegorz Wallner

[1129] Age and gender differences in sleeve gastrectomy results in long-term follow-up

Authors: Jan Maciej Kapała, Tomasz Maroszczuk
Affiliation: University of Warmia and Mazury in Olsztyn / Medical Department
Trustee of the paper: Natalia Dowgiałło-Gornowicz, MD PhD

Corresponding author: Jan Kapała (jas.kapala@gmail.com)

Introduction
Sleeve gastrectomy is an effective method of surgical treatment of obesity. Although a significant number of patients suffer from weight regain after surgery in long-term follow-up. Both age and gender of patients undergoing sleeve gastrectomy seem to be factors which predict the procedure's effectiveness.

Aim of the study
The purpose of study is to evaluate the results of sleeve gastrectomy in the term of weight loss in 6-year long follow-up with emphasis on differences between specific age and gender groups of patients.

Material and methods
A total of 1071 patients underwent sleeve gastrectomy in the Department of General, Minimally Invasive and Elderly Surgery in Olsztyn in 2013-2018 according to standard technique. 392 randomly chosen patients were also surveyed via personal or telephone consultations. The inclusion criteria gathered not reoperated patients with at least 5-year follow-up. The research examined changes in patients' body weight up to 6 years after the surgery.

Results
112 patients were included in the study according to specific criteria. 66 of them were attached to a 6-years follow-up group. Both 5- and 6-years follow-up have no significant differences between gender groups mean %EBMIL ($P > .05$). In terms of patients' age significant negative correlations with %EBMIL were observed at almost every stage of observation, although the values of this correlation were mostly low-moderate.

Conclusions
Patients' gender does not influence sleeve gastrectomy results in long-term follow-up. The expected result of bariatric treatment decreases with the patient's age. However, future research in those areas is needed.

[1189] The significance of bile microbial flora profiling in antibiotic selection following cholecystectomy

Authors: Mahsa Arabzadeh, Amir Ahmad Arabzadeh, Kazem Nejati
Affiliation: Department of Surgery, Ardabil University of Medical Sciences, Ardabil, Iran
Trustee of the paper: Mahsa Arabzadeh

Corresponding author: Mahsa Arabzadeh (Mahsalunaaa@gmail.com)

Introduction
Through evidence, it has been accepted that normal bile is usually sterile and becomes infected during gallbladder disease. Bactibilia is a common finding in patients with cholelithiasis.

Aim of the study
This study aims to identify the microflora profile and antibiotic resistance pattern in gallbladder bile and help to recommend an appropriate antibiotic.

Material and methods
A total of 1oo patients with the biliary disease who underwent cholecystectomy operation at Fatemi and Imam-Khomeini hospitals of Ardabil were included in the study. 5ml of bile were taken and transferred to the laboratory for culture and test for bacterial strains according to standard routines. Analysis was performed according to antibiogram results.

Results
The mean age of the patients was 47.3±14.7 years, and the number of females (59%) was higher than males (41%) in this study. A positive culture was seen in 35 (35%) of the 100 patients who underwent cholecystectomy operation (P=0.055). The most common organism isolated were E.coli (14%), Klebsiella (11%) and Enterococcus (10%). E.coli was the most resistant organism to antibiotics (42.8%). Antibiogram study indicated bacterial sensitivity of organisms to Ciprofloxacin, Cotrimoxazole and Amikacin and most resistant to Ceftriaxone and Cefixime.

Conclusions
In conclusion, it seems the species of isolated organisms and their antibiogram profiles changed because of epidemiological factors. This study indicates that fluoroquinolones, cotrimoxazole and aminoglycosides are effective as the first line for empirical antibiotic therapy in patients with the suspicion of bactibilia because of their excellent bacterial sensitivity. Cephalosporins are not suitable as an empirical treatment for bactibilia. The microbial study of the bile flora and determining their sensitivity to different antibiotics may reduce postoperative infectious complications.

[1223] Characteristics and Outcomes of Patients Undergoing Transplantation vs Hepatic Resection for Hepatocellular Carcinoma

Authors: Agnė Grigonytė
Affiliation: Vilnius University, Faculty of Medicine, Lithuania
Trustee of the paper: The paper has bioethics approval

Corresponding author: Agnė Grigonytė (agne.grigonyte.2@mf.stud.vu.lt)

Introduction

Hepatic resection (HR) and liver transplantation (LT) are the most common curative treatment options for hepatocellular carcinoma (HCC). Still, there are limited data to shed light on what characterizes patients who underwent HR or LT and which type of surgery has better outcomes for HCC.

Aim of the study

This study aims to compare characteristics of patients undergoing LT vs HR for HCC and determine in which group the outcomes are better.

Material and methods

Clinical, surgical and laboratory data of selected patients with HCC who underwent hepatic resection or liver transplantation at Vilnius University Hospital Santaros Klinikos between May 2007 and November 2020 were collected. In this correlational study, we used the Wilcoxon rank-sum test, chi-square, and Fischer exact tests of independence to compare HR vs LT.

Results

A total of 136 selected patients who went through HR (n=108) or LT (n=28) were analysed. Most of the patients (75%) were males and the median age at the time of operation was 63 years old. The median survival among the groups was over 40 months and the LT group had significantly better overall survival compared to the HR group (61 months for LT and 27 months for HR group, $p=0.003$), and disease-free survival was also significantly higher in the transplant group (61 months for LT and 14 months for HR group, $p<0.001$). Primary cancer (first time vs recurrence of HCC, $p=0.018$) and recurrence of this case ($p<0.001$), were significantly higher in patients who underwent HR compared to LT for HCC. LT was associated with longer duration of operation (7h32min for LT vs 2 h35min for HR, $p<0.001$), greater blood loss (1500 vs 500 ml, $p<0.001$), longer in-hospital stay (23 vs 12.5 days, $p<0.001$), and younger age at the time of operation (54.5 vs 66 years, $p<0.001$). Compared with HR, patients who underwent LT had higher laboratory findings: TBIL before and after surgery, AST before, ALP before and APTT after surgery, also had decreased platelet count before and after surgery, albumin and INR before surgery, and better laboratory findings such as TBIL, GGT, AST, ALT on the last follow-up ($p<0.05$ for all laboratory results).

Conclusions

There were significant differences between surgical and laboratory findings in liver transplantation vs resection cohorts. Liver transplantation may be associated with better overall and disease-free survival, a non-recurrent tumour, and better liver function on the last follow-up.

[1276] Postoperative outcomes in geriatric patients undergoing liver surgery

Authors: Julia Jurga, Agata Mazurek, Kuba Kupniewski, Jerzy Krzeszowiak
Affiliation: 1st Chair of General, Oncological, Gastroenterological Surgery and Transplantology of Jagiellonian University Medical College
Trustee of the paper: dr hab. Jakub Kenig, prof. UJ

Corresponding author: Julia Jurga (jjurga@outlook.com)

Introduction
In recent years the amount of elderly patients affected by liver tumors has been gradually increasing. Potential causes are: ageing of the society, overall higher incidence rate of liver malignancies and improvements in treatment of chronic liver diseases. Because of underrepresentation of elderly patients in clinical trials and general belief that older age is related with worse surgical outcomes, some surgeons are still hesitant to propose surgical management as a part of the treatment for this age group.

Aim of the study
The aim of the study was to investigate whether there are any preoperative factors increasing the risk of postoperative complications in geriatric population undergoing liver surgery.

Material and methods
The study included pre- and postoperative data of 52 patients who underwent liver surgery in our Department between 06.2016 and 10.2021. Only patients ≥65 years old who underwent liver resection or hepatic thermal ablation were included, while patients who underwent other procedures, were younger or their data was significantly incomplete were excluded. Patients were then divided into 2 groups regarding whether they suffered postoperative complications or not. Statistical analysis has been performed using Statistica and SPSS software.

Results
52 patients met the inclusion criteria. 15 patients (28,85%) suffered from postoperative complications with no 30-days mortality. The higher tumor grading score was the only statistically significant factor ($p = 0,05$) indicating further postoperative complications while male sex was slightly above statistical significance ($p = 0,055$). Patients with HCC ($n = 14$) suffered only from medical complications ($n = 5$), while the majority of patients with metastatic tumors ($n = 21$) suffered from surgical ones ($n = 4$) ($p = 0,023$). Differences in age, BMI, ASA score, Charlson Comorbidity Score, number of comorbidities, number of drugs taken, results of preoperative laboratory tests, type of tumor (primary or secondary) and TNM classification between groups were not statistically significant.

Conclusions
Our study showed that factors such as age, ASA score or number of comorbidities, which currently play a key role when qualifying patients for surgical procedures, should not be determinant when deciding whether elderly patients with liver tumors should undergo surgery. Chronological age should not be a contraindication for the surgery.

[1318] Histopathological characteristic of colon cancer in older and younger patients – what surgeon can learn from that

Authors: Natalia Zmysłowska, Sofiia Popovchenko
Affiliation: Department of General, Oncologic, Gastrointestinal Surgery and Transplantology; Jagiellonian University Medical College
Trustee of the paper: Jakub Kenig M.D. Ph.D. Prof. of Jagiellonian University

Corresponding author: Natalia Zmysłowska (n.zmyslowska@student.uj.edu.pl)

Introduction
Due to the constantly prolonging life expectancy, the number of elderly patients with colon cancer increases, with almost about 50% of the cases in patients aged 65 or more, that is why the problem of colon cancer is very topical. The population of older patients is very heterogeneous and often under-represented in publications.

Aim of the study
The goal of this investigation was to compare histopathological characteristics of colon cancer between younger patients and the elderly in order to assess their relevance for colon cancer in an aging population.

Material and methods
Histopathological Records of all patient with colon cancer managed at General, Oncological, Gastroenterological and Transplant Surgery Clinical Department between 2019 and 2021 were reviewed. Patients were divided into two groups according to their age: elderly (⩾65 yr of age; n=75) and younger patients (<65 yr of age; n=40) and then compared. Statistical analysis was performed using Chi-square and Mann–Whitney U tests.

Results
Out of 115 patients analysed in this study 75 (65.22%) were 65 years old or older whereas 40 (34.78%) were in the younger group. Gender distribution was similar in both group (p=0.539; 44% female in the elderly vs 50% in <65y.o. group). Cancer staging, histological type and presence of positive lymph nodes did not differ significantly between both age group (p=0.420; p=0.602; and p=0.400 respectively). Whilst lymphatic and neuroinvasion did not differ between the groups (p=0.220 and p=0.118 respectively), presence of angioinvasion was more common in the group of younger patients (50% vs 30.67%; p=0.041). The achievement of a curative resection (R0) was more frequent in the elderly group (92% vs 73%, p = 0.032) and there is a statistically significant negative correlation between age and radicality of resection (r = -0.266; p=0.004). Correlations between age and other factors were measured, but non of them were statistically significant.

Conclusions
The obtained data demonstrate that there is no statistically significant difference in histopathological features of colon cancer between the elderly and the younger group, apart from angioinvasion presence, indicating that the same surgical treatment should be also carried out.

[1338] Surgical analysis of anatomical variability within the mesenteric arteries - cadaveric study.

Authors: Adrian Balcerzak
Affiliation: Medical University of Łódź / Departament of Anatomical Preparation and Dissection
Trustee of the paper: prof. UG, dr. hab. Łukasz Hubert Olewnik

Corresponding author: Adrian Balcerzak (adrian.balcerzak@icloud.com)

Introduction

The inferior mesenteric artery (IMA) and superior mesenteric artery (SMA) are the second and third main branch of the abdominal aorta, normally arising at the level of L1 and L3, supplying respectively – SMA: the third portion of the duodenum, the jejunum, the ileum, the cecum, the ascending colon, and the proximal part of the transverse colon, IMA the large intestine from the distal transverse colon to the upper part of the anal canal. Preoperative knowledge of SMA and IMA branching patterns and their implications is essential to minimize the risk of complications.

Aim of the study

The aim of this study was to characterize the morphological variability, origin, course and morphology of the terminal branches of the mesenteric arteries (SMA and IMA), as well as creating a new classifications, which seem to be necessary for clinicians performing surgery in this area.

Material and methods

The anatomical variations in the branching patterns of the inferior mesenteric artery and superior mesenteric artery were examined in 30 cadavers showing no signs of surgical interventions, fixed in a 10% formalin solution. Morphometric measurements were then obtained twice by two researchers.

Results

Due to the proposed IMA classification system, Type I – normal anatomy - occurred in 56.67% of cases, Type II, Trifurcation Type, in 23,33%, Type III with the superior rectal arteries originating firstly from the IMA in 6,67%, Type IV with the ascending lumbar artery in 10% of cases and Type V, a novelty, in 3.33%. In the proposed SMA classification system, Type I, characterized by all normal branches occurred in 53.33% of the specimens. Type II, characterized by absence of the inferior pancreatoduodenal artery, was present in 26.67%. Type III, characterized by absence of the right colic artery, was present in 3.33%. Type IV, characterized by a common trunk for the inferior pancreatoduodenal artery and middle colic arteries, was observed in 3.33%. Type V, characterized by an aberrant hepatic artery and absence of the inferior pancreatoduodenal artery, was observed in 13.33%.

Conclusions

Mesenteric arteries are characterized by high morphological variability, the variants being associated with distinct clinical aspects. The presentation of a structured anatomical classifications, which seem to carry a potential clinical value.

[1340] Radical cystectomy pentafecta: reporting outcomes following cystectomy in a Polish cohort: a multicenter retrospective analysis

Authors: Łukasz Zapała, Aleksander Ślusarczyk, Paweł Kurzyna, Mikołaj Leki, Piotr Lipiński, Jerzy Miłow, Michał Niemczyk, Rafał Wolański, Piotr Zapała, Waldemar Różański, Piotr Radziszewski, et al.
Affiliation: Clinic of General, Oncological and Functional Urology, Medical University of Warsaw, Warsaw, Poland; 2nd Clinic of Urology, Medical University of Lodz, Łódź, Poland
Trustee of the paper: dr n. med Łukasz Zapała

Corresponding author: Jerzy Miłow (jerzy.milow@gmail.com)

Introduction
The worldwide results of the treatment of muscle-invasive bladder cancer (MIBC) bring the image of suboptimal management of the disease with 50% of patients undergoing radical cystectomy (RC) not surviving 5 years. The most efficient way of treatment nowadays remains radical cystectomy (RC) with neoadjuvant or adjuvant chemotherapy. As it has been shown in the recent publications, RC efficiency may be improved by applying criteria of so called pentafecta.

Aim of the study
We aimed at characterization of the patients undergoing radical cystectomy using the prognostic model (a modified pentafecta).

Material and methods
In the multicenter retrospective study, we enrolled 304 patients with bladder cancer (pTis-4N0-2M0) who underwent RC between 2015 and 2020 in experienced centers. The definition of the pentafecta was as follows: no Clavien–Dindo grade III–V complications at 90 days and no long-term complications related to urinary diversion <12 months, negative surgical margins, ≥10 lymph nodes (LNs) resected, and no recurrence ≤12 months.

Results
RC-pentafecta achievement rate was 22% (n = 67), varying from 47% to 88% attainment rate for different pentafecta components, and was the lowest for sufficient LN yield. Both 12-month recurrence-free survival (RFS) and cancer-specific mortality were compromised in pentafecta failers compared with achievers (57.8% vs. 100% and 33.8% vs. 1.5%, respectively). The following were identified as crucial predictors of RC pentafecta achievement: modality of the surgery, type of urinary diversion, histological type of bladder cancer, advanced staging, and elevated preoperative serum creatinine.

Conclusions
In conclusion, we found that the pentafecta achievement rate was low even in high-volume centers in patients undergoing cystectomy. The complexity of the procedure directly influenced the attainment rate, which in turn led to an increase in cancer-specific mortality rate among the pentafecta failers.

[1347] Advantages of Ilio-Inguinal Approach of Transversus Abdominis Plane block in Chronic Pain Treatment After Inguinal Hernia Repair

Authors: Ilia Mihaylov
Affiliation: Medical University Pleven
Trustee of the paper: Ivan Malkodanski

Corresponding author: Ilia Mihaylov (ili.michaylov@gmail.com)

Introduction

Trans-abdominal plane blocks are a method for acute and chronic pain treatment performed under the guidance of ultrasound. It's approaches including the subcostal TAP, the lateral TAP, the posterior TAP and the ilio-inguinal TAP blocks. For broader analgesic effect an application of four-quadrant TAP block is performed. The technique has a broad specter of applications for pre-, intra- and postoperative usages as well as management of chronic pain.

Aim of the study

The aim of this study is to evaluate the level of efficiency that TAP blocks offer in patients suffering from chronic pain syndrome after inguinal hernia surgery.

Material and methods

A prospective study of all cases of TAP block after inguinal hernia repair was performed in Saint Marina Hospital, Pleven. Bulgaria for the duration of 1 year.
The ilio-inguinal approach of the trans-abdominal plane block was performed via ultrasound visualization of the muscles of anterior abdominal wall and injecting a 20ml solution of 1 ampule dexamethazone and 50mg ropivacain. We then compared the results to a control group of patients with similar condition who were treated with 1 tablet of diclofenac 150mg.

Results

76 patients were identified and included in the study. The clinical data of all patients was collected from said patients' medical records. On all 76 patients with unilateral hernia a unilateral ilio-inguinal trans-abdominal plane block was performed. All nerve blocks performed were effective and none of the patients experienced complications of any kind. We compared them to the 19 patients control group all of whom experienced pain 24 hours after the intake of diclofenac.

Conclusions

The ilio-inguinal trans-abdominis plane block is an effective method for chronic pain treatment in patients after inguinal hernia repair. It is also highly cost- and time-efficient method especially compared to the classic methods for "analgesic ladder".

[1350] Is it possible to predict the position of the lips after orthognathic surgery based on the measurement of displacement of maxilla and mandible?

Authors: Ewa Stopa, Wojciech Stopa
Affiliation: Students' Scientific Group "Le Fort", Department of Cranio-Maxillofacial Surgery, Oral Surgery and Implantology MUW
Trustee of the paper: dr n. med. Zygmunt Stopa

Corresponding author: Ewa Stopa (e.stopa@onet.pl)

Introduction

Orthognathic surgery aims at correcting dysmorphia caused by growth disorders of the maxilla and mandible or trauma. It has a significant impact on a patient's occlusal conditions, facial aesthetics and the functioning of the entire stomatognathic system. Close collaboration between the maxillofacial surgeon and the orthodontist is necessary for an optimal treatment result. Usage of dedicated softwares can be helpful to predict the outcome of the surgical treatment.

Aim of the study

The aim of the study was to evaluate the data collected by measuring distance between selected points before and after orthognathic surgery based on Computed Tomography in order to determine whether it is possible to predict the position of the lips after surgery.

Material and methods

The study has been conducted retrospectively. Computed Tomography scans of patients with class II and III malocclusion who underwent orthognathic surgery between 2020 and 2021 has been evaluated. There were 13 patients, 11 females and 2 males. The mean age of patients was 26,2 years. For measurements DDS-Pro software was used. The Nasion Vertical Line (NVL) was established. The line was placed through nasion and was perpendicular to the natural horizontal head position. All measurements were evaluated on CT scans made before and after orthognathic surgery in reference to the NVL. Selected points were upper lip anterior, lower lip anterior, upper incisor anterior and lower incisor anterior. The results have been statistically evaluated.

Results

In a group of patients with class II malocclusion the mean difference between hard and soft tissue changes for upper arch was 0,43mm (median 0,85mm), for lower arch was 1,40mm (median 1,35). In a group of patients with class III malocclusion the mean difference between hard and soft tissue changes for upper arch was 1,48mm (median 1,6mm), for lower arch was 1,92mm (median 2,2).

Conclusions

On the basis of the range of displacement of bones it is not possible to precisely determine the changes of soft tissue position after orthognathic surgery. However, further research on a larger group of patients and a larger number of measuring points is necessary.

[1372] Finite element analysis in the personalized design of novel titanium implant for maxillofacial reconstruction with subsequent prosthetic restoration – proof of concept study

Authors: Mateusz Kawka (1), Paweł Pacek (2), Maciej Rysz (2)
Affiliation: (1) Reconstructive Team, Department of Breast Cancer and Reconstructive Surgery, Maria Sklodowska-Curie National Research Institute of Oncology, Warsaw, Poland; (2) MaterialsCare Sp. z o. o., Warsaw, Poland.
Trustee of the paper: dr n. med. Maciej Rysz

Corresponding author: JMateusz Kawka (mateusz.kawka@wum.edu.pl)

Introduction

Bone defects in the maxillofacial region as the outcome of surgical resections of tumors, mechanical injuries, post-radiation necrosis or congenital deformities are still a challenge for reconstructive surgeons. Besides being the cause of the aesthetic problem, resulting functional deficiency can exacerbate the social exclusion of patients and reduce their quality of life. The peculiarity of patients' maxillofacial anatomy makes personalized approach an exceptionally important condition for successful reconstruction but simultaneously requires the implementation of novel methods in the design and manufacturing process.

Aim of the study

The aim of the study was the implementation of the finite element analysis method in the personalized design process of maxillofacial titanium implants intended for subsequent prosthetic restoration.

Material and methods

Three patients with a history of bone defects caused by neoplasms were recruited for the study. CT scans of the head region were collected and used to generate patients' 3D skull virtual models. With the application of computer-aided design (Siemens NX) the 3D models of the implants with geometry matching the bone defect were created. Nests for dental crown fixation were added to the virtual model aiming to allow for subsequent prosthetic restoration. The resulting model was subjected to finite element analysis (ANSYS Mechanical APDL) of various bone, implant and screws loading scenarios. Collected data of mechanical stress were used to identify components exposed to mechanical overload and implants geometry was redesigned to optimize the distribution of mechanical forces.

Results

In the course of performed finite element analysis areas of elevated stress generated in response to applied strain according to loading scenarios were identified. The highest stresses were located in the regions of dental crown nests and implant-bone contact surfaces around screw fixation sites. Corrections of implant geometry by profile thickness and width reduction resulted in better strain transfer. Redesigned implant models were sent for 3D printing procedure, sterilization and device implantation.

Conclusions

The presented method of personalized implant design supported with finite element analysis allowed to obtain implants with geometry optimized for patient-specific strains distribution in the functional stomatognathic system for planned maxillofacial reconstruction surgeries.

[1376] Comparison of histopathological characterisitc between age groups in patients with rectal cancer – what surgeon can learn from it

Authors: Jerzy Krzeszowiak, Agata Mazurek
Affiliation: 1st Chair of General, Oncological, Gastroenterological Surgery and Transplantology of Jagiellonian University Medical College
Trustee of the paper: dr hab. Jakub Kenig, Prof. UJ

Corresponding author: Jerzy Krzeszowiak (jerzykrzeszowiak@docs.name)

Introduction

Rectal cancer is one of the most common malignant neoplasms in adult population. Its incidence is increasing with age, but despite the wide range of available multimodal treatment of rectal cancer data about tailored approach with regard to the biological age for elderly is still insufficient.

Aim of the study

The aim of the study was to investigate the differences in histopathological outcomes between <65 and ≥65 years old groups and determine whether there is a significant difference in cancer staging between these groups with attempt to explain its possible reasons.

Material and methods

73 patients operated due to malignant rectal neoplasms between December 2019 and October 2021 in our Department were included. Other diseases, lack of histopathological examination or only intraoperative examinations were exclusive for the study. Patients were divided into two age subgroups and analyzed in terms of histopathological outcomes using Chi2 or U Mann-Whitney tests and Spearman Correlation.

Results

There were 35 patients <65 and 38 ≥65. Age median and male percentage were 57 vs 71.5 and 77.14% vs 68.42% respectively. Most common etiologies were: adenocarcinoma (68.49% vs 71.43%), mucinous adenocarcinoma (11.43% vs 5.26%) and tubular adenocarcinoma (6.71% vs 10.53%). The difference in histopathological types distribution was not significant. In both groups most common histopathological features were: pT3, pN0 and G2 with no significant differences in distribution. Lymphatic, vessel and neural invasion were more often in younger group, but only difference in lymphatic invasion was significant. In both groups most common resection was R0, there were also no significant differences in numbers of resected and positive lymph nodes. In all patients age was significantly correlated with lower grading and lower number of resected nodes. In group <65 male sex was negatively correlated with lymphatic invasion.

Conclusions

Histopathological results of both groups are comparable. It proves that age is not a risk factor of greater malignancy in patients operated due to rectal cancer.

[1393] Significance of current preoperative factors in outcome prediction of older patients operated due pancreatic neoplasms.

Authors: Jerzy Krzeszowiak, Natalia Zmysłowska, Aleksandra Ożga
Affiliation: 1st Chair of General, Oncological, Gastroenterological Surgery and Transplantology of Jagiellonian University Medical College
Trustee of the paper: dr hab. Jakub Kenig, Prof. UJ

Corresponding author: Jerzy Krzeszowiak (jerzy.krzeszowiak@student.uj.edu.pl)

Introduction
Despite a huge improvement in surgical technique and perioperative care in the field of pancreatic oncological surgery, the risk of morbidity and mortality is still significant. Especially in the group of elderly patients in which natural reserves are depleted.

Aim of the study
The aim was to investigate preoperative prognostic factors predicting postoperative outcomes of elderly patients operated due to pancreatic neoplasm.

Material and methods
Preoperative, perioperative data and postoperative outcomes were collected. The inclusion criteria were: age ≥60, radical surgical treatment due to pancreatic neoplasm or periampullary area. Analysis was performed using chi2, U Mann-Whitney or Kruskall-Wallis tests and Spearman correlation

Results
103 patients met the inclusion criteria. The age median was 72 years (60-90) and there was a predominance of female (54.37%). Patients were divided into three age groups: 60-69 (n=39), 70-79 (n=53) and ≥80 (n=11). There were no significant differences in preoperative BMI, polypragmasy or number of comorbidities, but CCI and ASA were significantly higher in older groups. Perioperative outcomes including: operation time, estimated blood loss, intraoperative complications, 30-day mortality, ICU days, Clavien and Dindo (CD), number of packed RBC and TPN days were analyzed, but no significant differences were revealed. Only length of stay differed significantly with medians: 8, 13 ,8 days respectively (p=0.0432). Analyzing various laboratory results, the only significant difference referred to the lymphocytes, with median values decreasing with age (p=0.0256). Comparing patients with CD <3 or ≥3 there were no significant differences in preoperative features, laboratory or perioperative results. Correlations between preoperative features and laboratory tests vs postoperative outcomes were tested, but none of them were strong or moderate.

Conclusions
The results indicate that currently available preoperative data or laboratory tests do not allow to predict further postoperative course. We also did not reveal any differences between patients with severe or mild complications. In the light of the results, we conclude, that current methods used to describe elderly patients' status are insufficient to predict their outcomes.

PhD Basic & Preclinical Science

Date: 8th May 2022, 8:30 AM

Coordinator:
Szymon Lipiec

Patronage:

Konsultant krajowy w dziedzinie mikrobiologii lekarskiej

Prof. dr hab. n. med. Katarzyna Dzierżanowska-Fangrat

Polskie Towarzystwo Immunologii Doświadczalnej i Klinicznej

[1170] Selected monoterpenes as reductors and chelators of iron ions

Authors: Karolina Wojtunik-Kulesza
Affiliation: Medical University of Lublin, Department of Inorganic Chemistry
Trustee of the paper: Medical University of Lublin

Corresponding author: Karolina Wojtunik-Kulesza (karolina.wojtunik@umlub.pl)

Introduction

Natural antioxidants play major role in various parts of life such as medicine, pharmacy and food industry. Monoterpenes, being largest group of secondary plant metabolites, are characterized by good antioxidant and antiradical activities. From a medical point of view, iron ions plays important roles in several harmful oxidation processes within the human organism. This results from the fact that the Fe^{3+} is responsible for the aggregation of hyperphosphorylated tau, and is associated with neurofibrillary tangles, as well as progressive supranuclear palsy (PSP). Reduction of Fe^{3+} to Fe^{2+} can reverse this process and solubilize tau species characteristic of neurodegeneration. It is known that pro-oxidant or antioxidant activities of trace metals depend on the form of the elements. The first case is observed when iron occurs in Fe^{2+} form and can react with O_2 or H_2O_2 leading to the creation of superoxide and hydroxyl radicals.

Aim of the study

Determination of selected monoterpenes ability to reduction and chelation of iron ions.

Materials and methods

Basis of the studies was group of selected natural monoterpenes (α-phellandrene, α-terpinene, citral, menthone, carvone, γ-terpinene, isopulegol, terpinene-4-ol, linalool, eucalyptol, α- and β-pinene, p-cymene, citronellal). The studies were based on colorimetric assays: FRAP in order to determine ability of the terpenes to Fe^{3+} reduction and ferrozine-based assay used in order to determine ability of the terpenes to chalation of Fe^{2+}.

Results

The obtained study results revealed satisfactory activity of selected monoterpenes towards both reduction and chelation of iron ions. Among them, the highest reducing activity was observed for γ-terpinene, α-terpinene, α-phellandrene and carvone. Solubility improvement of the compounds by adding Tween 20 has led to highest reduction activity of the monoterpenes. In the case of chelation activity, izopulegol, terpinene-4-ol and menthone revealed the highest activity.

Conclusions

Monoterpenes can be view as active antioxidants, reductors as well as metal ion chelators. The metal ion chelation is strictly related with structure of the compounds and moieties involved in the reaction. Considering the high content of monoterpenes in numerous plant species, the valuable pro-health properties of the plants along with their secondary plant metabolites should be underlined.

[1187] Alteration of circulating platelet-related and diabetes-related microRNAs in individuals with type 2 diabetes: Results from a stepwise hypoglycaemic clamp study

Authors: Joanna Jarosz-Popek1,2, Zofia Wicik, Jenny Simon, Mikołaj Marszałek, Disha Keshwani, Anna Nowak, Marta Wolska, Faisal Aziz, Norbert J. Tripolt, Dirk von Lewinski, Jolanta M. Siller-Matula, Marek Postula*, Harald Sourij, Ceren Eyileten
Affiliation: 1) Department of Experimental and Clinical Pharmacology, Medical University of Warsaw, Center for Preclinical Research and Technology CEPT, Warsaw, Poland; 2) Doctoral School, Medical University of Warsaw, Warsaw, Poland
Trustee of the paper: Marek Postuła

Corresponding author: Joanna Jarosz - Popek (jjarosz@wum.edu.pl)

Introduction
In patients with type-2 diabetes (T2DM) association between severe hypoglycemic episodes and the risk of cardiovascular (CV) morbidity and mortality has been previously established.

Aim of the study
We aimed to investigate the impact of hypoglycemia on several diabetes-related and platelet-related miRNAs selected based on bioinformatic analysis and literature search, including hsa-miR-16, hsa-miR-34a, hsa-miR-129-2, hsa-miR-15a, hsa-miR-15b, hsa-miR-106a, miR-223, miR-126.

Material and methods
Selected miRNAs were validated by qRT-PCR in 14 patients with T2DM on metformin monotherapy, without established CV disease and antiplatelet therapy during a stepwise hypoglycemic clamp experiment and a follow-up seven days after the clamp event. In order to identify which pathways and phenotypes are associated with validated miRNAs we performed target prediction on genes expressed with high confidence in platelets.

Results
Circulating levels of miR-106a-5p, miR-15b, miR-15a, miR-16-5p, miR-223 and miR-126 were increased after euglycaemic clamp followed by hypoglycemic clamp, each with its distinctive time trend. On the contrary, miR-129-2-3p, miR-92a-3p and miR-34a-3p remained unchanged. MiR-16-5p was negatively correlated with interleukin (IL)-6, intercellular adhesion molecule (ICAM) and vascular cell adhesion molecule (VCAM) ($p=0.002$, $p<0.001$, $p=0.016$, respectively), whereas miR-126 was positively correlated with VCAM ($p<0.001$). There were negative correlations between miR-16-5p, miR-126 and coagulation factors, including factor VIII and von Willebrand factor (vWF). Among all studied miRNAs, miR-126, miR-129-2-3p and miR-15b showed correlation with platelet function.. Bioinformatic analysis of platelet-related targets of analyzed miRNAs showed strong enrichment of IL-2 signaling. We also observed significant enrichment of pathways and diseases related to cancer, CV diseases, hyperglycemia, and neurological diseases.

Conclusions
Hypoglycemia can significantly influence the expression of platelet-enriched miRNAs, with a time trend paralleling the time course of platelet activation. This suggests they could be exploited as biomarkers for platelet activation in response to hypoglycemia, as they are probably released by platelets upon activation by hypoglycemic episodes. Should they hold their promise in clinical endpoint studies, platelet-derived miRNAs might become helpful markers of CV risk in subjects with diabetes.

[1227] Analysis of changes in surfaceome of rituximab-resistant cell lines – implications for the efficacy of immunotherapies

Authors: Aleksandra Kusowska, Matylda Kubacz, Aleksander Ślusarczyk, Magdalena Winiarska, Małgorzata Bobrowicz
Affiliation: Department of Immunology, Medical University of Warsaw, 02-927 Warsaw, Poland
Trustee of the paper: Małgorzata Bobrowicz, Magdalena Winiarska

Corresponding author: Aleksandra Kusowska (ola.kusowska@gmail.com)

Introduction
CD20 is a molecular target for monoclonal antibodies (mAbs) widely used in hematooncology. Regimens comprising anti-CD20 mAb – rituximab (RTX) exhibit high efficacy as the first-line treatment, however, they are often followed by the acquirement of resistance. CD20 downregulation is one of the main hallmarks of RTX-resistance. We have observed that a decreased expression of CD20 correlates with low levels of CD37, a protein involved in regulating tumorigenesis in B cells. Although CD37 gained attention as a molecular target for patients resistant or refractory to anti-CD20 therapies, decreased CD20 expression may impair the efficacy of anti-CD37 regimens.

Aim of the study
The study aimed to explore the mechanisms of regulation of CD20 and CD37 in malignant B cells and to identify their role in the modulation of the efficacy of anti-CD37 immunotherapies based on mAbs and chimeric antigen receptor (CAR) T cells.

Material and methods
To mimic changes specific to CD20 loss, CD20 knock-out cells (CD20 KO) were established with CRISPR/Cas9 system. sgRNA for CD20 gene was designed using Brunello and Brie library and cloned into Lenti-CRISPR-V2 plasmid. B-cell lymphoma cell lines were transduced with sgCD20 plasmid. CD20 and CD37 expression were determined using flow cytometry (FCM), western blotting, and qPCR. The second-generation CD37CAR construct kindly provided by Dr. Sébastien Wälchli from Oslo University Hospital consists of scFv containing: leader sequence–light chain–(G4S)4–heavy chain, CD8 hinge and transmembrane domain fused to 4-1BB-CD3ζ signaling domains. Peripheral blood mononuclear cells stimulated with anti-CD3/CD28 mAbs were used as a source of T cells for transduction with CD37CAR. Expression of CAR construct and cytotoxicity of CAR-modified T cells were evaluated in vitro using FCM.

Results
CD37 is significantly downregulated on the surface of all CD20 KO cell lines. We have observed downregulation of CD37 protein levels in whole-cell lysates from CD20 KO cells, but CD37 mRNA levels remain unaltered. CD20 loss results in impaired efficacy of anti-CD37 mAbs in inducing complement-dependent cytotoxicity. However, despite decreased CD37 expression, CD20KO cells are still efficiently eradicated by CD37 CAR-T cells.

Conclusions
Low expression of CD37 on malignant B cells compromises anti-CD37 mAbs efficacy, but not CD37 CAR-T cell cytotoxicity. Therefore, CD37 emerges as a promising therapeutic target for CAR-T cell therapy following CD20-negative relapse.

[1237] The association between vitamin D hydroxy metabolites and echocardiographic markers

Authors: Mohamed Abouzid 1, Paweł Burchardt 2,3, Franciszek Główka 1, Marta Karaźniewicz-Łada 1*
Affiliation: 1-Department of Physical Pharmacy and Pharmacokinetics, Poznan University of Medical Sciences; 2-Department of Hypertension, Angiology, and Internal Medicine, Poznan University of Medical Sciences; 3-Department of Cardiology, J. Struś Hospital
Trustee of the paper: dr hab. n. farm. Marta Karaźniewicz-Łada

Corresponding author: Mohamed Abouzid (mabouzid@outlook.com)

Introduction
The correlation between vitamin D and cardiovascular diseases is debatable. It is suggested that vitamin D may affect the differentiation and proliferation of cardiomyocytes and protect against myocardial dysfunction.

Aim of the study
This study aims to measure vitamin D hydroxyl metabolite concentrations in blood plasma and assess their relation to the markers of systolic and diastolic function.

Material and methods
Blood samples of 58 cardiac patients were collected twice in autumn-winter and spring-summer. Ultra-high performance liquid chromatography-MS/MS was applied to determine 25-hydroxyl metabolites of vitamin D in patients' plasma. Echocardiographic measures, particularly comprehensive evaluation of diastolic function, were performed with tissue Doppler technics. Statistica coupled with a Medical Bundle was applied for data analysis.

Results
Patients with deficient levels of vitamin D (<10 ng/mL) measured in summer-spring period had lower left ventricle lateral a' velocity than patients with the vitamin D insufficiency (10-20 ng/mL) [0.06 (0.04-0.06) vs. 0.11 ± 0.03, P=0.025]. A negative correlation was noticed between 25-hydroxyvitamin D3 concentrations and right ventricle diameter (r2=0.74, P=0.028). Concentrations of 3-epi-25-hydroxyvitamin D3 measured in summer-spring were correlated with tricuspid annular plane systolic excursion (TAPSE) (r2=0.74, P=0.01).
Patients with insufficient levels of vitamin D in autumn-winter had lower left ventricle lateral a' velocity than patients with sufficient concentrations (>20 ng/mL) [0.06 ±0.02 vs. 0.09±0.03, P=0.039]. We also found a positive correlation between the isovolumic relaxation time (IVRT) and 3-epi-25-hydroxyvitamin D3 levels (r2=0.81, P=0.014).
When splitting patients into two groups only (below and higher than 20 ng/mL vitamin D), we found that patients with vitamin D levels below 20 ng/mL had lower intraventricular septum e' velocity [0.05(0.045-0.065) vs. 0.076±0.022, P=0.024] and higher E/e' ratio (10.84±3.54 vs. 7.99±1.987, P=0.048).

Conclusions
Analysis of vitamin D metabolites may provide insights to understand how vitamin D influences the cardiovascular system. Reduced vitamin D levels were associated with worse diastolic function, as well as with right ventricle function. Acknowledgments: Mr Mohamed Abouzid is a participant of STER Internationalisation of Doctoral Schools Programme from NAWA Polish National Agency for Academic Exchange No. PPI/STE/2020/1/00014/DEC/02

[1293] Influence of nanosilver and disinfecting agents on activity of therapeutic staphylococcal phages

Authors: Hubert Kasprzak1, Ryszard Międzybrodzki1,2,3, Barbara Bubak1, Andrzej Górski1,2
Affiliation: (1) Bacteriophage Laboratory, Hirszfeld Institute of Immunology and Experimental Therapy PAS, (2) Phage Therapy Unit, Hirszfeld Institute of Immunology and Experimental Therapy, (3) Department of Clinical Immunology, Medical University of Warsaw
Trustee of the paper: Ryszard Międzybrodzki

Corresponding author: Hubert Kasprzak (hubertvon@gmail.com)

Introduction
Bacteriophages are viruses that specifically infect and destroy bacteria, including those which are resistant to antibiotics and cause life-threatening infections. Due to global increase in resistance of bacteria to antibiotics, the use of bacteriophages to cure bacterial infections (phage therapy) is more and more often considered one of the alternatives for antibiotics. Hirszfeld Institute has at its disposal methods for isolation of bacteriophages and for preparation of phage formulations that may be used with some success in treatment carried out at its Phage Therapy Unit.

Aim of the study
Our aim was to determine if disinfectants or nanosilver preparations universally used in treatment of wounds infected with bacteria may affect the activity of phages.

Materials and methods
Phage lysates containing therapeutic staphylococcal phages P4/6409, P4/6409ppf, A5/80, 1N/80, and 1N/80ppf were incubated for 60 min at 37C with serial dilutions of one of the two popular disinfectants (Octenisept, Prontosan), or nanosilver preparation (Ranispetol). Phage activity after incubation was determined on the basis of the spot test of serial dilutions of incubation mixture on a lawn of an phage bacterial host. The phage titer in mixtures was also determined after incubation using the double-layer agar technique.

Results
Both Octenisept and Prontosan completely deactivated phages up to 100x. Raniseptol showed much less phagicidal activity. The mean decrease in phage titer after incubation with the silver preparation for all tested phages ranged between 68% and 86%. Analysis using a U test additionally indicated that there were significant differences in titers between phages alone and phages incubated with Raniseptol ($p=0,019$). The spot test results also showed a decrease in the rank of lysis in all dilutions tested. Wilcoxon signed-rank test performed for different phage dilutions for representative independent experiments showed significant differences in the ranks between phages and phages incubated with Raniseptol.

Conclusions
When using phage preparations on infected wounds, it is not advisable to apply disinfectants as concomitant treatment. Nanosilver preparation also reduce the phage titer, but at clinically acceptable level (below one log). Because these preliminary studies concern only some of our most popular staphylococcal bacteriophages, therefore it is necessary to tests other phages to generalize our observations.

[1239] Differentiation of Adipose Derived Mesenchymal Stem Cells into chondrocytes, an in vitro study

Authors: Damian Kasiński1, Marta Rasmus1, Daria Balcerczyk1, Justyna Durślewicz2, Dariusz Grzanka2, Tomasz Drewa1, Marta Pokrywczyńska1
Affiliation: 1. Department of Regenerative Medicine Cell and Tissue Bank, Chair of Urology 2. Department of Clinical Pathomorphology, Ludwik Rydygier Medical College in Bydgoszcz, Nicolaus Copernicus University in Torun, Poland
Trustee of the paper: prof. dr hab. Marta Pokrywczyńska

Corresponding author: Damian Kasiński (kasinski.damian1916@gmail.com)

Introduction
Articular cartilage defects due to injury or other pathology are difficult to heal. The results of the clinical treatment used today are not satisfactory. Adipose Derived Mesenchymal Stromal/Stem Cells (AD-MSCs) are multipotent stem cells with the multilineage differentiation capacity. Tissue engineering methods based on the ability of AD-MSCs to differentiate into chondrocytes provides a new idea for regeneration of articular cartilage defects.

Aim of the study
The aim of the study was to compare the effectiveness of two methods of differentiation of AD-MSCs into chondrocytes and to analyze the expression of selected genes - markers of chondrogenesis.

Material and methods
Cells were isolated from lipoaspirate collected from 3 patients and cultured up to the third passage in MEM. After the third passage, cells were immunophenotypically evaluated and chondrogenically differentiated by two methods: in aggregates and in alginate beads. The negative control for chondrogenic differentiation was undifferentiated stem cells, while the positive control was human CRL 2846 chondrocytes. After the differentiation process, its efficiency was evaluated using hematoxylin and eosin, toluidine blue and alcian blue staining. The expression of genes characteristic for chondrogenic differentiation COL1A1, COL2A1, COL10A1, ACAN, SOX9 was evaluated.

Results
Chondroblast-like cells were observed in cytological preparations of cells differentiated in aggregates, while chondroblast-like and chondrocyto-like cells were observed in cytological preparations of cells differentiated in alginate beads. Gene expression analysis showed a statistically significant higher expression of COL2A1 and SOX9 genes in cells differentiated by both three-dimensional culture methods compared to negative and positive control cells. Cells differentiated in aggregates showed statistically significant higher SOX9 gene expression compared to cells cultured in alginate beads. ACAN gene expression was only observed in positive control cells. The expression of COL1A1 and COL10A1 genes was not observed in any of compared methods.

Conclusions
AD-MSCs are capable of chondrogenic differentiation in in vitro culture. Physical factors such as the dimensional structure in which the culture of AD-MSCs is carried out has a influence on the process of chondrogenic differentiation of cells.

[1252] Molecularly imprinted polymers as boron carriers of potential use in boron-neutron capture therapy - design, synthesis optimization and properties assessment.

Authors: Emilia Balcer (1,2), Joanna Giebułtowicz (1), Piotr Luliński (3)
Affiliation: 1 Medical University of Warsaw/Department of Bioanalysis and Drug Analysis; 2 National Centre for Nuclear Research/Nuclear Facilities Operations Department; 3 Medical University of Warsaw/Department of Organic Chemistry
Trustee of the paper: Piotr Luliński

Corresponding author: Emilia Balcer (emilia.m.balcer@gmail.com)

Introduction
Treatment of cancerous diseases still remains one of the biggest challenges of modern medicine. One of the most promising alternative therapies is boron-neutron capture therapy (BNCT), which utilizes a nuclear reaction occurring between 10B isotope, selectively delivered to the tumour site, and thermal neutrons from the external beam. Numerous reports can be found on the effectiveness of BNCT in the treatment of head and neck tumours and there is a great potential of BNCT application in other types of cancers, such us breast, lung, or many different metastatic types. A significant limitation, however, is the lack of an effective boron carrier. The use of a boron compound already implemented in clinical practice and combining it with modern drug delivery systems, such as those based on polymers, may be a promising solution.

Aim of the study
The goal of the research was to design, optimize the synthesis and obtain modern drug delivery system based on molecularly imprinted polymer (MIP) with appropriate capacity and selectivity towards selected boron compound, and perform an assessment of its morphological properties.

Material and methods
The design and synthesis process involved obtaining: optimized block copolymer imprinted with L-phenylalanine as a template for 4-borono-L-phenylalanine (BPA, the selected boron compound), for which the influence of different monomers was investigated; core-shell imprinted microparticles produced from siloxane core; and three-dimensional polymeric periodic structures, for which the influence of different cross-linkers was investigated. Binding capacities and imprinting factors of the materials were calculated with the use of liquid chromatography coupled with mass spectrometry (LC-MS/MS) method. Morphology analysis was performed with the use of scanning electron microscope (SEM).

Results
Binding capacity studies revealed that block MIP formed from methacrylic acid copolymerized by ethylene glycol dimethacrylate possesses the highest specificity towards BPA. Morphology studies have shown that the desired structure of a three-dimensional periodic structure consisting of MIP and possessing hollow cavities was successfully obtained.

Conclusions
The obtained materials exhibit specificity towards BPA that indicates the possibility of using MIPs as boron carriers. The construction of three-dimensional periodic structure consisting of MIP shows the possibility of an increase of the binding surface achieved by the presence of hollow cavities, and will be evaluated in further studies.

[1289] Human keratinocyte cells with podophyllotoxin and its derivative - study on mechanism of adaptation of cells.

Authors: Piotr Strus, Karol Sadowski, Julia Kostro, Izabela Młynarczuk-Biały
Affiliation: DOCTORAL SCHOOL OF MUW
Trustee of the paper: Izabela Młynarczuk-Biały MD PhD, Department for Histology and Embryology, MUW

Corresponding author: Piotr Strus (struspiotrek@gmail.com)

Introduction
The new drug under our study is a derivative of podophyllotoxin (PPT), which is a natural compound originally obtained from the Podophyllum Palatum plant. PPT is used in the treatment of HPV-induced anogenital warts. PPT stabilizes microtubules and stops replication of cellular DNA, however the exact mechanism of action is unknown. Due to its highly toxic effect, it can only be applied topically. Our KL3 derivative turns out to be not only more effective in killing cancer cells in vitro, but also less toxic to non-tumorogenic cells.

Aim of the study
The aim of the study was to describe the changes in the structure of non-tumorogenic, human keratinocytes (HaCaT) under the incubation with PPT and its derivative.
Material and methods
The changes of the structure of HaCaT cells were described on the basis of photos taken by electron microscopy. HaCaT cells were cultured in accordance with the ATCC and treated with the corresponding concentrations of PPT (Sigma Aldrich) and a new derivative - KL3, synthesized in cooperation with the University of Warsaw.

Results
PPT causes a stronger cytotoxic effect on HaCaT cells than KL3 in the corresponding concentration. After a 24-hour incubation, both compounds lead to mitochondrial swelling, stress of the endoplasmic reticulum and elongation of the cytoplasmic processes, but in cells incubated with KL3 after 48 hours the changes regress and autophagosomes are formed. We did not observe a similar regression effect in cells after incubation with PPT. In addition, in PPT incubated cells the vacuolization of the cytoplasm and the loss of cell membrane continuity were observed.

Conclusions
Due to the cell adaptive mechanisms of reversal of changes and the formation of autophagosomes, when incubated with the KL3, the new derivative appears to be less cytotoxic than the parental PPT. Based on that and our previous research, we have already known KL3 is more effective on cancer cells and less toxic on non-tumorogenic cells than PPT, which make the KL3 more likely to be used not only topically.

[1451] Detection of arginase containing small extracellular vesicles in biological fluids of endometriosis patients as a potential immunosuppressive factor

Authors: Karolina M. Soroczyńska1, Tobias Tertel2, Oumaima Stambouli2, Bernd Giebel2, Małgorzata Czystowska-Kuźmicz1
Affiliation: 1Chair and Department of Biochemistry, Medical University of Warsaw, Warsaw, Poland 2Institute for Transfusion Medicine, University Hospital Essen, University of Duisburg-Essen, Essen, Germany
Trustee of the paper: Małgorzata Czystowska-Kuźmicz, PhD

Corresponding author: Karolina M. Soroczyńska (k.m.soroczynska@gmail.com)

Introduction
Endometriosis is a chronic gynaecological disorder characterized by the growth of the endometrium outside its cavity. Reports suggest that it may be related to the impaired immune response. Our preliminary results indicate an increased level of two isoforms of arginase (ARG) enzyme, arginase-1 (ARG1) and arginase-2 (ARG2) as well as increased ARG activity in the peripheral blood of patients. Arginases are well-known regulators of amino acid metabolism, with a strong immunosuppressive effect. We assume that an immunosuppressive mechanism mediated by (ARG)-carrying extracellular vesicles (ARG+EVs), may be responsible for the observed immune dysfunction in endometriosis, resulting in the disease progression.

Aim of the study
The aim of the project is to identify ARG+EVs in the serum and peritoneal fluid (PF) of endometriosis patients and to decipher their impact on the immune dysfunction in endometriosis.
Material and methods
Small EVs were isolated from serum and PF of endometriosis and control patients using SEC and were verified by Western blotting, NTA and imaging flow cytometry (IFC). The presence of arginases in EVs was determined by Western blotting, ELISA and IFC. The functionality of ARG+ EVs was investigated using a multi-donor mixed lymphocyte reaction (mdMLR) assay.

Results
We detected small EVs in serum and PF samples from endometriosis patients and controls. According to NTA measurements, there was a trend towards higher total number of particles in endometriosis patients in comparison to controls both in serum and PF. We confirmed the presence of ARG1 and ARG2 in single EV samples from serum and PF of patients along with the detection of some classical markers of small EVs. Based on single EV analyses by IFC, we showed a decrease in ARG1 expression in serum-derived EV samples after the laparoscopic surgery. According to ELISA results, the concentration of vesicular ARG2 was several times higher than the ARG1 concentration, that was in the range of several ng per ml of serum or PF. In addition, EVs showed a minor immunomodulatory effect in the mdMLR, with a decline in activated CD4 and CD8 cells (CD25+CD54+), which was reversed by ARG inhibitor.

Conclusions
Our findings provide the first evidence for the presence of the immunosuppressive enzyme-ARG in the cargo of small EVs isolated from serum and PF of endometriosis patients. We believe that ARG+EVs may impact endometriosis progression, in terms of immune dysfunction, as well as provide a potential diagnostic biomarker or therapeutic target.

PhD Clinical & Health Science

Date: 8th May 2022, 9:30 AM

Coordinators:
Aleksandra Hyży
Bożena Pezała

Patronage:

Biuletyn Wydziału Farmaceutycznego Warszawskiego Uniwersytetu Medycznego

[1200] The impact of COVID-19 pandemic on STEMI treatment and outcomes in single-centre from Poland.

Authors: Jakub Bychowski, Tomasz Michalski, Tutor: Miłosz J. Jaguszewski
Affiliation: Ist Clinic of Cardiology, Faculty of Medicine, Medical University of Gdańsk
Trustee of the paper: Jakub Bychowski

Corresponding author: Jakub Bychowski (jakub.bychowski@gumed.edu.pl)

Introduction

Despite challenging circumstances due to COVID-19 pandemic in many healthcare systems the major purpose in ST-segment elevation myocardial infarction (STEMI) management remained consistent. The onset-to-door time (OTDT) should be maintained less than 12 hours and the door-to-balloon time (DTBT) should be less than 90 minutes for patients transported by emergency medical services. Slight modifications including routine SARS-CoV2 testing before the procedure and tolerable prolongation of primary PCI pathway of maximal 60 minutes were proposed by the European Society of Cardiology.

Aim of the study

Our study purposed to estimate the impact of the COVID-19 pandemic on the healthcare system in Poland by assessing the most reliable indicators of care quality, including measurement of treatment time prolongations, and comparing these values in patients treated in the pre- and pandemic period.

Materials and methods

This was a single-centre, retrospective study. We enrolled 480 patients with a mean 63.59±12.44 years of age admitted to the University Clinical Centre in Gdańsk with the initial diagnosis of STEMI and treated with primary PCI in two time frames (pre-pandemic group, n=331; pandemic group, n=149). Patients were evaluated by OTDT, DTBT, in-hospital mortality, and established predictors of aforementioned time delays, such as age, sex, comorbidities, and laboratory tests. Therefore, pre-pandemic and pandemic group were analysed in search for discrepancies in values of OTDT, DTBT, and in-hospital mortality.

Results

Our analysis revealed the prolongation of OTDT (median 3 hours; IQR 1.5–12.0 vs. median 5 hours; IQR 2.0–24.0, p=0.011), DTBT (median 92 minutes; IQR 65.0–187.0 vs. median 115.0; IQR 73.0–233.0, p=0.025), increase of in-hospital mortality (7.85% vs. 14.09%, p=0.033) and incidence of cardiogenic shock/cardiac arrest (16.62% vs. 26.85%, p=0.009) when comparing pre-pandemic and pandemic group, respectively. Moreover, the number of patients with prolonged OTDT (24.45% vs. 35.71%, p=0.019) and DTBT (51.96% vs. 65.77%, p=0.005) increased during the pandemic.

Conclusions

The results of the study indicate the statistically significant prolongation in both OTDT and DTBT at the time of the COVID-19 pandemic. Moreover, in-hospital mortality and the incidence of cardiogenic shock/cardiac arrest in the pandemic group were increased. Our study revealed the negative impact of the pandemic on treatment time and outcomes in patients with the diagnosis of STEMI.

[1206] What is the impact of the personality in Big-Five dimensions - on the emotional labour?

Authors: Dorota Koper1, Rafał Maciąg1, Agnieszka Nowakowska-Kaliszuk2, Tomasz Kryczka1
Affiliation: (1) Medical University of Warsaw, Department of Development of Nursing, Social and Medical Sciences, (2) University of Bialystok, Department of Psychology
Trustee of the paper: Tomasz Kryczka MSc, MD, PhD

Corresponding author: Dorota Koper (dorotakoper73@gmail.com)

Introduction

Emotional labour is defined as an effort made by employees to regulate emotions in their working environment as part of their professional role characteristic of social, service and commercial professions. Surface acting, which involves hiding and faking emotions, and deep acting have been identified as emotional labour strategies. Research to date shows that hiding emotions is associated with exhaustion, while faking emotions with cynicism, both of which are components of burnout. Many researchers point to the beneficial effects of deep acting for both the employee, as it increases the sense of personal achievement and job satisfaction, and for the employer, as it helps build a positive company image in the eyes of customers.

Aim of the study

To assess whether undertaking various forms of emotional labour depends on employee's personality.

Materials and methods

This anonymous, voluntary online survey was conducted in February/March 2021 among 215 professionally active nurses from all over Poland. We used the Scale of Surface and Deep Emotional Labour (SPGPE) and the NEO-FFI personality inventory. Statistica 13.3 package was used for statistical analyses, with particular emphasis on the correlation between SPGPE and NEO FFI.

Results

Weak to moderate positive correlations were found between neuroticism and all types of emotional labour, with stronger correlation with both forms of surface acting. Extraversion and agreeableness were poorly negatively correlated with surface acting. Conscientiousness was weakly negatively correlated only with faking emotions. None of the forms of emotional labour had a statistically significant relationship with Openness.

Conclusions

The nurse's involvement in various forms of emotional labour increased with increasing neuroticism, with surface acting twice as intense as the deep acting. Extroversion was significantly less likely to induce faking and hiding emotions. Conscientiousness in performing duties did not allow for faking emotions, while Agreeableness did not allow for surface acting when caring for patients. Only Openness, as a dominant trait, was irrelevant in undertaking emotional labour by nurses.

[1207] Organizational climate as a key factor leading to burnout in nurses

Authors: Dorota Koper1, Rafał Maciąg1, Agnieszka Nowakowska-Kaliszuk2, Tomasz Kryczka1
Affiliation: (1) Medical University of Warsaw, Department of Development of Nursing, Social and Medical Sciences, (2) University of Bialystok, Department of Psychology
Trustee of the paper: Tomasz Kryczka MSc, MD, PhD

Corresponding author: Dorota Koper (dorotakoper73@gmail.com)

Introduction

Organisational climate is the dominant atmosphere in the work environment, contributing to efficiency and effectiveness of performance and determining current organisational conditions. In workplaces, organisational climate affects not only the satisfaction of employees or the quality of services they provide, but, with a high intensity of various unfavourable factors, it may contribute to employee burnout. Burnout is defined as a prolonged response to chronic emotional and interpersonal stressors on the job, leading to fatigue and/or frustration arising from devotion to a cause, way of life, or relationship that failed to produce the expected reward. Previous research highlighted the role of management and work organisation in the development of burnout, which has been regarded as an occupational disease since 2022.

Aim of the study

To assess correlations between organisational climate and burnout in nurses.

Materials and methods

This nationwide, anonymous, voluntary online survey was conducted in the spring of 2020. A random sample of 181 Polish nurses was included in the study. OCE II measuring the organisational climate along with its six dimensions, i.e. Conformity, Responsibility, Standards, Rewards, Clarity, and Team Commitment, and OLBI assessing two dimensions of burnout, Exhaustion and Disengagement, were used for data collection. Statistica 13.3 was used for statistical analysis with particular focus on the correlations between the analysed factors.

Results

All dimensions of organisational climate and the overall value of this parameter showed a weak negative correlation with both burnout (overall score) and its two components, i.e. Exhaustion and Disengagement. A detailed analysis showed the weakest negative correlation of -0.206 for Responsibility vs Exhaustion and the strongest correlation of -0.374 for Rewards vs Disengagement. The correlation value was -0.410 for the overall score for OCE vs OLBI variables.

Conclusions

Our research confirmed the impact of management and work organisation on the development of burnout. All dimensions of organisational climate included in the OCE II analysis showed weak to moderate negative correlations both with the overall score for the burnout variable and with its two dimensions, i.e. Exhaustion and Disengagement.

[1324] Does the level of e-health competence affect the self-assessment of knowledge about vaccination against COVID-19 among nursing students in Poland?

Authors: Ilona Cieślak1, Mariusz Panczyk1, Marcia Kirwan2, Dominik Wawrzuta1, Mariusz Jaworski1, Joanna Gotlib1
Affiliation: (1) Department of Education and Research in Health Sciences, Faculty of Health Sciences, Medical University of Warsaw, (2) Dublin City University, School of Nursing, Psychotherapy and Community Healthy
Trustee of the paper: prof. dr hab. n. o zdr. Joanna Gotlib

Corresponding author: Ilona Cieślak (ilona.cieslak@wum.edu.pl)

Introduction
The ability to assess the reliability of health information found on the Internet is one of the health literacy components. The high level of competences in the field of e-health is particularly important among students, including students of medical faculties, who are the group that uses the Internet to the greatest extent. Health literacy skills among students may have a direct impact on their willingness to be vaccinated and on the level of knowledge about vaccination against COVID-19.

Aim of the study
Analysis of the correlation between the level of eHealth literacy skills and the level of self-assessment of knowledge about vaccination against COVID-19 in the group of undergraduate Nursing students in Poland.

Materials and methods
679 first-cycle Nursing students from 11 Medical Universities in Poland (First year: 58.7%, N = 397; Second year: 26%, N = 176; Third year: 15.2%, N = 103). Women constituted 87% of the respondents. The average age was 21 years (min. 18, max. 60, SD=4,049). Polish eHealth Literacy Scale and an original questionnaire were used in the study. The research tool was placed on the Limesurvey platform. The methods of descriptive statistics and correlation analysis were used for the analysis (Pearson's r). The level of statistical significance was adopted at alpha = 0,05. The calculations were made in the STATISTICA 13.3 program (TIBCO Software). The study was carried out as part of the NAWA project „VACCINATION, NOT HESITATION!" (NAWA 14, BPN/GIN/2021/1/00020/U/DRAFT/00001).

Results
Most of the respondents were vaccinated with an mRNA vaccine at the time of the study (67.9%, N = 459). 39% of students rated their level of knowledge about vaccination against COVID-19 as high. More than half of respondents (51.4%) indicated the websites of governmental institution as the main source of knowledge on vaccination against COVID-19. The average level of eHealth skills among nursing students was 29.94 (SD: 5.82). The study showed that respondents with higher levels of eHealth skills also had a higher level of self-assessment of knowledge about vaccination against COVID-19 ($r= 0.43$, $p < 0.001$).

Conclusions
The study showed that the level of eHealth skills positively correlates with the level of self-assessment of knowledge about vaccination against COVID-19 and may be one of the reasons for its high level. Therefore, it is important to strengthen the eHealth competences among students, especially nursing students, due to the educational role of a nurse in the health care system.

[1413] Restrained eating and overeating regulation : similarities, differences and correlations with food intake

Authors: Aleksandra Małachowska, Marzena Jeżewska-Zychowicz
Affiliation: Department of Food Market and Consumer Research, Institute of Human Nutrition Sciences, Warsaw University of Life Sciences (SGGW-WULS)
Trustee of the paper: prof. dr hab. Marzena Jeżewska-Zychowicz

Corresponding author: Aleksandra Małachowska (ola.malach@gmail.com)

Introduction

Restrained eating (RE) and overeating regulation (OR) are two constructs related to self-regulation of eating. Few previously conducted studies have found that these constructs are not strongly correlated, which suggests that they may be differently related to food intake. However, so far, no studies have investigated the relationship between RE, OR and food intake to confirm or reject this hypothesis.

Aim of the study

The study aim was to assess the correlation between RE and OR and, then, to examine the association between these constructs and intake of selected food groups, both favorable and unfavorable.

Materials and methods

The study was conducted in February 2020. The questionnaire with the 'Restrained eating' (RE) subscale from the Dutch Eating Behaviour Questionnaire, the Overeating Regulation Scale (ORS), questions regarding intake of both favorable (fruit, vegetables) and unfavorable foods (sweets, salty snacks) and metrics was administered to a representative group of Polish adults (500 women and 500 men), with the use of the CAWI technique. Spearman's correlation coefficient, Mann-Whitney's U Test and ANOVA test were used to analyse the data.

Results

Weak significant correlations were found between RE and all 3 ORS subscales ($r= 0.110$ to 0.160, $p<0.001$). RE score was significantly higher among current dieters in comparison to non-dieting respondents (3.33 ± 0.86 vs. 2.71 ± 0.89, $p<0.001$), while no differences were observed for all 3 ORS subscales depending on dieting status ($p>0.05$). Participants with the lowest intake of fruit and vegetables (1st tercile) scored the lowest in the RE and all 3 ORS subscales, while the highest scores were noted among those with the lowest intake of sweets and salty snacks (1st tercile) ($p<0.01$). Adequate intake of fruit and vegetables (>400g/day) favored higher scores for both RE and all 3 ORS subscales ($p<0.001$).

Conclusions

Despite being weakly correlated, RE and OR may similarly explain intake of fruit, vegetables, sweets, salty snacks and adequacy of fruit and vegetable intake. Further studies on the relationship between RE, OR and dietary intake should also include other physical and psychological parameters to compare those constructs more precisely.

[1435] Lung involvement in computed tomography alone or combined with additional imaging signs for predicting mortality in COVID-19

Authors: Schmidt Wiktor, Pawlak-Buś Katarzyna
Affiliation: Poznan University of Medical Sciences/Doctoral School/Department of Rheumatology, Rehabilitation and Internal Diseases
Trustee of the paper: Leszczyński Piotr

Corresponding author: Wiktor Schmidt (wiktorpawelschmidt@gmail.com)

Introduction
The degree of lung involvement in chest computed tomography (CT), either as a percentage or various scores, was proven to predict mortality associated with COVID-19. So were many additional diagnostic imaging signs. However, few risk scores comprise both.

Aim of the study
Development and validation of chest CT risk score to predict mortality in COVID-19.

Materials and methods
The development group included one hundred seventy-seven consecutive adult patients with confirmed COVID-19 and ground-glass opacities in chest CT, hospitalized between Mar 2020 and Jan 2021 in our ward. Chest CT of lungs of all patients was analyzed. Logistic regression analysis was conducted to develop a prediction model for COVID-19 in-hospital mortality. One hundred ninety consecutive patients hospitalized between Feb 2021 and Feb 2022 who fulfilled the abovementioned criteria comprised validation cohort.

Results
In univariate analysis, we encountered 12 predictive factors (9 risk and 3 protective). In multivariate analysis, we developed a radiological score predicting in-hospital COVID-19 mortality risk comprising lung involvement percentage, presence of pleural effusion, and domination of consolidation-type changes in chest CT. Our score was superior in prediction COVID-19 mortality to the percentage of lung involvement alone, Chest Computed Tomography Severity Score (CTSS), and modified Total Severity Score (mTSS).

Conclusions
The presented model is simple and regards often reported imaging signs in chest CT on admission. Moreover, it allows immediate and accurate assessment of COVID-19 mortality risk, which is essential in reducing the healthcare burden during SARS-CoV-2 pandemics.

Gynecological Case Report

Date: 8th May 2022, 8:30 AM

Coordinators:
Emilia Piotrkowicz
Klaudia Łuczak

Patronage:

Konsultant Krajowy w dziedzinie Endokrynologii ginekologicznej i rozrodczości

Prof. dr hab. Robert Zygmunt Spaczyński

[1173] A case study of low-grade appendiceal mucinous neoplasm (LAMN) – a challenge for physicians

Authors: Weronika Kawecka, Katarzyna Nowak
Affiliation: Student's Scientific Association at the II Department of Gynecology, Medical University of Lublin
Trustee of the paper: Professor Andrzej Semczuk, MD PhD, II Chair and Department of Gynecology, Medical University of Lublin

Corresponding author: Weronika Kawecka (weronika.kaw98@gmail.com)

Background
Low-grade appendiceal mucinous neoplasm (LAMN) is an aggressive, malignant tumor primarily originated from an appendix. It is usually diagnosed incidentally after appendectomy. In half of the female patients LAMN metastasizes to the genital tract organs. The patients' prognosis depends on the tumor stage, clinical symptoms, and the surgical management. The most dangerous complication is pseudomyxoma peritonei. The differentiation between primary ovarian mucinous tumors and metastases of LAMN to the ovary poses a challenge for physicians of different specializations (gynecologists, surgeons, and pathologists).

Case Report
A 61-year-old woman was admitted to the IInd Department of Gynecology, Medical University of Lublin, Lublin, Poland, with the diagnosis of right ovarian tumor. The patient underwent a total abdominal hysterectomy with salpingo-oophorectomy, omentectomy and appendectomy. Resection of the Douglas peritoneum was also performed. The patient was discharged after five days in a good condition. It was a surprise when postoperative pathological assessment revealed LAMN with metastases to the right ovary and omentum. A small perforation of the appendix was observed, and neoplastic cells were found on the appendiceal serosa. Immunohistochemically (IHC), CK20 and the CDX2 were both positive, whereas PAX8 was negative.

Conclusions
The detection of LAMN is incidental and post-operative, in general, and the diagnosis is a real challenge. Investigation of the IHC markers during the differentiation research between the primary mucinous ovarian tumor and ovarian LAMN metastasis is strongly recommended.

[1244] Pulmonary benign metastasizing leiomyoma: a case report of 48-year-old patient.

Authors: Natalia Szmigielska, Karolina Karoń, Ewelina Bornio
Affiliation: Uniwersytet Technilogiczno-Humanistyczny im. Kazimierza Pułaskiego
Trustee of the paper: dr n. med. Szymon Piątek

Corresponding author: Natalia Szmigielska (natalia.szmigielska@vp.pl)

Background
Leiomyoma is the most common benign neoplasm of the uterus. An extremely rare form of leiomyoma is benign metastasizing leiomyoma (BML), which may spread to the lungs.

Case Report
48-year-old woman with a tumor of unknown origin was admitted to the Department of Gynecologic Oncology at the Maria Sklodowska-Curie National Research Institute of Oncology in Warsaw. CT scan showed an irregular solid-cystic mass in the abdominopelvic cavity that measured 307x225x302 mm; additionally, multiple suspicion lesions in the lungs were found. A tru-cut biopsy of the uterine tumor was performed. Pathologic assessment indicated cellular leiomyoma. Tumor histology did not correlate with clinical examination and radiological results, which were characteristic of advanced leiomyosarcoma. The patient was qualified for surgical treatment - hysterectomy with bilateral salpingooopherectomy. The postoperative histopathologic assessment confirmed uterine leiomyoma. Due to suspicion of metastases to the lungs of unknown origin, thoracotomy with open biopsy of lesions was done. The result of histopathological examination of the lung biopsy confirmed leiomyoma. The patient was diagnosed with benign metastasizing leiomyoma. Gonadotropins analogs were administered.

Conclusions
In Poland until now, only 2 cases of BML were reported, but lesions in the lungs were diagnosed many years after uterine leiomyoma (26 and 15 years later). In the presented case uterine tumor and lung metastases were diagnosed at the same time.

[1272] HELLP syndrome and preeclampsia in patient with neurofibromatosis type 1 - case report

Authors: Maja Kłopecka
Affiliation: Student's Scientific Group affiliated to the 1st Department of Obstetrics and Gynecology, Medical University of Warsaw, Poland
Trustee of the paper: Prof. Dorota Agata Bomba-Opoń, MD, PhD

Corresponding author: Maja Kłopecka (klopeckamaja12@gmail.com)

Background
HELLP syndrome is a rare condition that affects 0.17-0.9% of pregnant women. It is characterized by hemolysis, elevated liver enzymes, and low platelets. Most cases are related to preeclampsia. Both HELLP syndrome and preeclampsia may impact the mother as well as the fetus, even resulting in death. Their pathogenesis is unclear, but chronic systemic diseases and genetic disorders such as neurofibromatosis type 1 (von Recklinghausen's disease) may be contributory factors.

Case Report
A 33-year-old woman was admitted to the clinic in the 17th week of pregnancy with suspected intrauterine growth restriction (IUGR) and signs of pregnancy-induced hypertension (PIH) but without significant proteinuria. The patient suffered from genetic Recklinghausen's disease. Her past obstetric history included 2 premature pregnancies, HELLP syndrome, gestational hypertension, IUGR in all previous pregnancies and postnatal infant deaths. During the current pregnancy, PAPP-A test and amniocentesis were performed. Their results excluded genetic diseases in the fetus. A thorough cardiological examination was performed, intensive antihypertensive treatment started, and agents such as pravastatin, encortone, neoparin and acetylsalicylic acid were administered. Despite the above therapy, severe inhibition of fetal intrauterine growth was observed. In week 29 of pregnancy, prenatal steroid therapy was used to enhance maturation of the fetus. Several days later, the patient developed fully-symptomatic HELLP syndrome and it was decided to perform an emergency cesarean section. A baby girl with a body weight of 330g was delivered through CS. Intensive neonatal therapy was given, but the child died on the 7th day of life due to pneumothorax complications. In the postpartum period, the patient's blood pressure and hepatic parameters returned to normal.

Conclusions
Women with preeclampsia and HELLP syndrome typically have worse outcomes than preeclamptic women without HELLP, which is why pregnancy and childbirth are a major challenge for the former. In both disorders, the vascular system is compromised; vasculopathies are also present in von Recklinghausen's disease. Thus, all three conditions are characterized by vascular complications. There is no suitable treatment for the above-mentioned diseases. The only treatment to ensure the mother's health is a prompt delivery of the baby.

[1322] Prenatal diagnosis of rare dural sinus malformation

Authors: Natalia Pacocha
Affiliation: Student's Scientific Group affiliated to the 1st Department of Obstetrics and Gynecology, Medical University of Warsaw, Poland
Trustee of the paper: Michał Lipa PhD MD

Corresponding author: Natalia Pacocha (natalia.pacocha99@gmail.com)

Background
Dural sinus malformation (DSM) is a rare congenital vascular malformation among central nervous system associated with an arteriovenous shunt and severe dilatation of the dural sinus. The most common arteriovenous malformation is the vein of Galen malformation (VGAM), which accounts for the 30% of vascular malformations in paediatric patients. We present an unique case of DSM involving superior sagittal sinus (SSS)- only several cases had been published previously.

Case Report
32-years-old patient (gravida 2, para 1) was referred to the 1st Department of Obstetrics and Gynecology Medical University of Warsaw at 21 weeks of gestation due to abnormal middle cerebral artery (MCA) Doppler velocity (fetal viral infection suspected). Ultrasound scan revealed single fetus in cephalic presentation with estimated weight appropriate for gestational age and no major morphological defects. Peak systolic velocity in MCA 118cm/s corresponded to the 4,4 multiples of median (MOM). However transvaginal ultrasonographic approach revealed abnormal shunt and severe dilatation of the superior sagittal arteriovenous malformation. Beside AVM, hyperechogenic periventricular lining of the lateral ventricles suggested cerebral damage. Fetal echocardiographic evaluation was normal. At 25 week of gestation, intrauterine fetal demise (IUFD) ocurred. After pharmacological induction of labour the patient was discharged within 24h in good general condition.

Conclusions
Fetuses diagnosed with DSM usually have poor neurological prognosis due to cortical damage, however an early prenatal diagnosis may point the most appropriate timing of the delivery in terms of progressing cardiac failure and high risk of fetal demise. On the other hand, materal hemodynamics shall be monitored carefully as well due to increased risk of mirror syndrome. Only multidisciplinary team and care may bring the most benefits in such cases.

[1374] Pheochromocytoma in pregnancy associated with neurofibromatosis type 1

Authors: Wiktoria Stańska, Karolina Jarząbek
Affiliation: Student's Scientific Association, Department of Gynecological Endocrinology, Medical University of Warsaw
Trustee of the paper: Monika Grymowicz, MD, PhD

Corresponding author: Wiktoria Stańska (wstanska@gmail.com)

Background
Neurofibromatosis type 1 is a genetic disorder that might affect multiple organ systems and increase the risk of causing a rare neuroendocrine tumor - pheochromocytoma. Even though there are inconsistent views about the effects of neurofibromatosis on pregnancy, pheochromocytoma-related hypertension and the release of catecholamines during pregnancy jeopardize both mother's and child's health.

Case Report
We present a case report of a 30-year-old primigravida with a rare presentation of pheochromocytoma associated with neurofibromatosis type 1, diagnosed before pregnancy, who was admitted to the outpatient clinic at Szpital Kliniczny Karowa in Warsaw in the first trimester of her first pregnancy. The patient had hemartomas in the central nervous system, optic nerve glioma, and multiple neurofibromas. CT performed a year before revealed 36x25mm size mass, 50jH, in the right adrenal gland. MRI showed no signal dropout. 24h urine collection revealed high metoxycatecholamine concentration. Additionally, somatostatin receptor scintigraphy and 123-metaiodobenzylguanidine confirmed the diagnosis of pheochromocytoma. Doxazosin and metoprolol were administered. Elective adrenalectomy was planned before the pregnancy. However, due to the onset of the COVID-19 pandemic, it was canceled. Pharmacological treatment was continued during pregnancy as a pretreatment before the removal of the adrenal gland. No peaks of blood pressure were observed. In the 27th week of gestational age, the patient underwent adrenalectomy. The patient's general condition was good, her BP was 110/70, without orthostatic hypotension and her heart rate was 92/min. The surgery was uneventful. During the hospitalization period, cardiotocography was normal and an ultrasound scan showed an eutrophic fetus. At 39 weeks of gestational age, she gave birth by an elective cesarean section. Spinal anesthesia was administered. A 3170g healthy girl was born, Apgar's score was 10. Perioperative and early postnatal period was uneventful. The patient was discharged with a newborn.

Conclusions
Our study clearly shows that the course of pregnancy can be uneventful despite having pheochromocytoma related to neurofibromatosis. Although the rare cause of hypertension in pregnancy, physicians should bear in mind the pheochromocytoma as a potential cause. Early diagnosis and proper management with pharmacology and adrenalectomy result in good maternal and neonatal outcomes.

[1400] A rare case of musculoskeletal endometriosis with bilateral location: left buttock and the lower third of the right thigh

Authors: Theresa Margarethe Buchta, Johanna Bauer, Eva-Maria Sophia Haftstein, Annika Ulrike Pfeiffer, Prof. Dr. Lucian Puşcaşiu
Affiliation: UMFST Targu Mures/Obstetrics and Gynecology Department
Trustee of the paper: Prof. Dr. Lucian Puşcaşiu

Corresponding author: Theresa Margarethe Buchta (theresa.buchta@muenchen-mail.de)

Background
Endometriosis is characterized by the presence of endometrial tissue outside of the uterine cavity with associated fibrosis and inflammatory reactions. Such endometrial ectopic tissues are generally found in the pelvis constructions close to the uterus. Musculoskeletal endometriosis is an extremely rare condition.

Case Report
The purpose of this paper is to report the unusual location of endometriosis, being in the left buttock and the right thigh muscles of a patient with Fallot Tetralogy.
This case report presents a female patient, who was diagnosed at the age of 31. She complained about regular menstruation pain in the left buttock and right thigh, first noticed in May 2016. A Surgical excision was performed, to remove the endometriosis outbreaks.
The patient had no previous history of such symptoms before a term cesarean section performed for her cardiac disease. Soft tissue ultrasound was performed revealing a nodular, hypoechogenic, non-homogeneous image with an irregular contour with some 30/15/20 mm vascular spots at the left buttock. A similar intramuscular nodular lesion of 22/10/15 mm was revealed at the lower third of the right thigh, both suspecting a malignant lesion. Six months after surgery, the patient reports normal menstrual periods, devoid of pain in the former endometriosis outbreaks. Now being able to perform regular daily activities without any discomfort.

Conclusions
We report an isolated case of extragenital endometriosis with two implantation sites in the striated muscle system in the left buttock muscles and in the right thigh muscles, after a cesarean section, in a patient with tetralogy of Fallot. We were not able to find another case of extragenital endometriosis located bilaterally on the body in the medical literature. Extrapelvic endometriosis is a rare condition, but clinicians need to be aware of its existence.

[1419] Cesarean section in a patient with twin pregnancy complicated with Twin Anemia-Polycythemia Sequence (TAPS)

Authors: Michał Zygarowicz, Samuel Jung
Affiliation: 1'st Cathedral and Clinic of Obstetrics and Gynaecology at Medical University of Warsaw
Trustee of the paper: Iwona Szymusik PhD MD, Nicoletta Iłowska-Grzechnik MD

Corresponding author: Michał Zygarowicz (m.zygarowicz@o2.pl)

Background
Twin-To-Twin Transfusion Syndrome (TTTS) is a pathology of the placenta that relies on the blood transfusion between the twins in a case of monochorionic pregnancies. A recently discovered new variant of this pathology, named Twin Anemia-Polycythemia Sequence (TAPS) is a state when this blood transfusion results in a big difference in the levels of hemoglobin concentrations in twins' blood, and no significant difference in the amniotic fluid volume at the same time.

Case Report
A 31-year-old pregnant woman at the 27'th week of twin gestation was admitted to the hospital due to premature rupture of membranes (PROM). Before the admission, pregnancy was complicated with TTTS, which was treated by laser therapy without complications, and then monitored by ultrasonography examination on an outpatient basis. In the hospital, she was diagnosed with TAPS in II degree. Due to the impairment of placenta blood flow and no possibility of intrauterine TAPS treatment, the patient was qualified for cesarean delivery. Two living daughters were delivered. First with a 1350 g birth weight, and Apgar score of 7/9/9/9. Second with 1020 g birth weight, and Apgar score of 1/1/6/8. Both children were transported into the intensive care unit of the neonates. Neonates usually need a blood transfusion, and that was done in the blood donor daughter. Mother was in good general condition after delivery and discharged from the hospital 3 days after delivery.

Conclusions
Placenta disorders related to vascular connections between twins may lead to serious life-threatening fetal complications, such as fetal anemia and polycythemia, so it is important to make an early diagnosis, observe the fetal condition, and prepare for the possible earlier end of pregnancy.

[1440] Myectomy during cesarean section: is it a safe procedure?

Authors: Aleksandra Słowakiewicz
Affiliation: 2nd Department of Obstetrics and Gynecology, Medical University of Warsaw, Poland
Trustee of the paper: Agnieszka Dobrowolska-Redo PhD MD, Ewa Romejko-Wolniewicz PhD MD

Corresponding author: Aleksandra Słowakiewicz (aleksandraslowakiewicz@gmail.com)

Background
Leiomyomas are the most common benign gynecologic tumors in women of reproductive age and subsequently during pregnancy. Nowadays, as more cases are qualified for cesarean section, more attention has been paid on whether to remove the fibroids at the time of cesarean section. The procedure remains controversial as it may raise the concerns about uncontrollable hemorrhage, which then brings about the necessity of hysterectomy. However, obstetricians are increasingly choosing to perform myomectomy during cesarean delivery.

Case Report
A 34-year-old primigravida at 38+4 gestational week diagnosed with breech presentation of the fetus and uterine fibroids constituting an obstacle to delivery, was admitted to the maternity ward in 2nd Department of Obstetrics and Gynecology of Medical University of Warsaw for planned caesarean section.
On admission the patient's condition was good. On the CTG examination fetal movements were recorded, fetal heart rate was 140 per minute, uterine contractions were absent. Performed ultrasound examination presented a single live fetus in the longitudinal breech presentation. Placenta was located on the front wall and myomas were not visualized. The patient was qualified for caesarean section with enucleation of the uterine fibroids.
Surgical delivery was performed under spinal anesthesia. During cesarean section the female baby was taken out without difficulty. The uterus was extended above the abdominal wall and on the posterior wall of the uterus, in the area of uterine isthmus, a pediculated myoma of 6-7cm in diameter was localized. The myoma stalk was coagulated, cut off and sutured. Also, a submucosal myoma about 1 cm in diameter was removed by coagulation. Bleeding sites and small subserial fibroids in the fundus of the uterus were electrocoagulated. In haemostasis control no bleeding was noted and estimated total blood loss was 300ml.
Childbed proceeded without complications. Uterus was hard and shrunken, peristalsis conservative, postoperative faeces normal and wound healed properly. Postoperative maternal hemoglobin level was 12g/dl. The patient in good general condition was discharged home with the child.

Conclusions
Although myectomy during cesarean section always entails greater risks as a result of uncontrollable bleeding, when performed by an experienced operator with careful case selection it can be a safe and effective procedure. Moreover, the long-term effect of cesarean myomectomy still needs to be studied.

[1457] Pregnancies in post-transplant patients with analysis of placental pathology: case series

Authors: Bartosz Korzeb
Affiliation: 1st Department of Obstetrics and Gynecology, Medical University of Warsaw
Trustee of the paper: Natalia Mazanowska, MD, PhD

Corresponding author: Bartosz Korzeb (bartoszkorzeb@gmail.com)

Background
Despite progress in perinatal care, post-transplant pregnancy remains a high-risk one. Abnormal placentation lies in the background of often encountered pregnancy complications, characterized by placental lesions, including features of chronic inflammation of the placental bed. The immunosuppressive therapy may modify the maternal response in early pregnancy leading to disturbed placentation, which may cause maternal vascular malperfusion. The weakened maternal immune response may also decrease the prevalence of chronic inflammation features in the placenta.

Case Report
The study aimed to analyze nine post-transplant pregnancies and placental pathology in these cases. Our study group consisted of 4 kidney and 5 liver recipients, all patients aged 31,11+-2,69, delivered in our clinic in 2020-2021, at 36,67+-3,06 weeks of gestation. The primary immunosuppressive regimen was tacrolimus-based. During the pregnancy, 4 patients developed gestational diabetes mellitus, 3 hypertensive disorders of pregnancy, 3 anemia and 2 intrahepatic cholestasis of pregnancy. Moreover, 2 women delivered preterm (33 and 30 weeks) and the majority (6/9) via cesarean section, mainly due to previous operative delivery. Mean birthweight was 2745+-758,67 grams, cord arterial blood pH - 7,28+-0,06, and all newborns got at least 9 points in the 5th minute Apgar score. The pathology examination of the placenta revealed that the average weight of the placenta was 490+-102.12 grams, and placental volume was 1598.02+-691.13 cm3. The mean placental weight/neonatal weight ratio was 0,1785. Furthermore, it revealed lesions that were classified as characteristic of maternal or fetal vascular malperfusion.

Conclusions
Pregnancies of post-transplant patients are more prone to obstetric complications and should be provided by a multidisciplinary team. Pathological examination of the placenta affords an opportunity to investigate the pathophysiology underlying the increased prevalence of these complications in graft-recipient women, but this method is limited due to insufficient data.

[1463] Evaluation of Pregnant Patients with Chronic Kidney Disease (CKD)

Authors: Aleksandra Śliwka, Joanna Ciećwierz
Affiliation: Medical University of Warsaw
Trustee of the paper: prof. dr hab. n. med. Bronisława Pietrzak

Corresponding author: Aleksandra Śliwka (ola.sliwka@icloud.com)

Background

Since the first successful childbirth in a patient after kidney transplantation, the number of pregnant patients with CKD has been on the increase. The purpose of this case report is to show the differences in pregnancies and their outcomes in two different patients, both of them suffering from kidney injury. One of the patients recovered good renal function in the transplanted kidney, and the other one was treated with repetitive dialysis sessions.

Case Report

The 1st patient was diagnosed with amyloidosis-induced renal failure and underwent the kidney transplantation in 2011. 3 years later her right kidney was removed due to cancer. In 2017 the patient (33 yo) had a good renal function (cr 0.9mg/dl) and got pregnant. The pregnancy was uneventful except for anemia. In the 37th week of gestation, the delivery was induced due to the deterioration of fetal well-being. The patient went into a natural labour. A baby was born with the weight of 2130g. In 2018, the patient became pregnant with her 2nd child. The pregnancy was uneventful except for anemia. A baby was born with the weight of 3010g, in the 38th week of pregnancy. During both pregnancies, the patient was treated with CsA, Aza and prednisone. The function of the transplanted kidney remains good.

The 2nd patient was diagnosed with renal failure due to polycystic kidney disease and had a kidney transplant in 2011. In 2019, the patient (32 yo) got pregnant. Investigations revealed proteinuria (2.5g/day), elevated levels of creatinine (2.2mg/dL), hypertension and anemia (Hgb 5,7mg/dL). The patient was treated with TAC, prednisone, dopegyt, and EPO and had packed red blood cell transfusions. The patient received repetitive dialysis. C-section was performed in the 29th week. The baby weighed 980g. 7 months after delivery the patient was found to be 17 weeks into her 2nd pregnancy. Dialysis as well as hypertension and anemia management were continued. C-section was performed in the 30th week of pregnancy. The baby weighed 1120g. Currently, the patient is still waiting for a kidney transplant.

Conclusions

1The evaluation of patients with kidney failure of similar age and time of recovery from kidney transplantation confirms the need for pregnancy planning.
2Close monitoring of general health of the patients and their fetuses is required for positive delivery outcomes.
3Good function of the transplanted kidney at the time of conception influences a favourable prognosis for pregnancy and for the general health of the patient.

[1475] What does hyperthyroidism have to do with the ovary? A case report of a mature ovarian teratoma

Authors: Monika Stradczuk
Affiliation: Medical University of Warsaw
Trustee of the paper: Monika Grymowicz MD, PhD

Corresponding author: Monika Stradczuk (moonia.s@wp.pl)

Background
Teratomas are a common subtype of germ cell tumours composed of cells from three germ layers: ectoderm, mesoderm, and endoderm. According to the degree of differentiation of their elements, mature and immature teratomas can be distinguished. Mature teratomas among ovarian neoplasms account for 10-20% of the total. The tumours usually occur in cystic form and are widely known as "dermoid cysts." Although often asymptomatic, teratomas can present nonspecific symptoms such as abdominal pain or pelvic mass and be complicated with torsion. Thyroid tissue can be found in benign cystic teratomas in small quantities or constitute more than 50% of neoplasm, then defined as struma ovarii. Hyperthyroidism due to autonomous secretion by teratoma composing cells represents a small number of cases reported in the literature.

Case Report
A 32-year-old woman was urgently admitted to the hospital with lower left-quadrant abdominal pain. Before then, for many years, the patient suffered from periodic episodes of hyperthyroidism manifested as weight loss and hair loss and lower TSH. Ultrasonography revealed a left ovarian cyst with features of a dermoid cyst. Due to the symptoms of ovarian torsion, the patient was scheduled for semi-elective surgery, but she declined consent. The transvaginal ultrasonography confirmed the presence of a heterogeneous cyst with no vascularity and dimensions of 49x48 mm in the left ovary. A month later, the patient consented to laparoscopic surgery with cyst removal. Intraoperative histopathological examination revealed a benign lesion, which contained sebaceous masses and hair. In pelvic assessment, the right ovary, bilateral fallopian tubes, parametria and abdominal organs were not altered. The peritoneal surface was smooth. No enlargement of retroperitoneal lymph nodes was detected. Postoperative histopathology confirmed the benign mass character with the diagnosis of a mature teratoma with focal thyroid tissue. Laboratory findings revealed normal TSH and FT4 serum levels. All the correlations suggest that the former thyroid hormone excess came from the functional thyroid tissue contained in the ovarian neoplasm. The patient remains under supervision.

Conclusions
The study presents a rare case that contributes to the literature. It reminds us about the rare cause of thyrotoxicosis, which should be included in the differential diagnosis. To successfully treat patients, emphasis must be placed on thorough medical history and not disregarding any patient complaints.

[1490] A rare case of retroperitoneal paraganglioma diagnosed in pregnancy

Authors: Zuzanna Wojtczak
Affiliation: 1st Department of Obstetrics and Gynecology, Medical University of Warsaw
Trustee of the paper: Michał Lipa MD, PhD

Corresponding author: Zuzanna Wojtczak (zuzannawojtczak5@gmail.com)

Background
Pheochromocytomas and paragangliomas (PPGLs) are vascularized neuroendocrine tumors derived from the chromaffin cells of the adrenal medulla or neural crest cells originating from outside of the adrenal gland. PPGLs are rarely diagnosed throughout the pregnancy and occur in one out of 54 000 pregnancies (paragangliomas account for about 20% of PPGLs). As their clinical manifestations depend on the location, size and the hormonal secretion, they remain a clinical challenge not only to diagnose but also to treat. Approximately 40 cases of PGL in pregnancy were reported and best to our knowledge this is the first case report regarding an asymptomatic retroperitoneal paraganglioma diagnosed prenatally.

Case Report
We present a case of a 27-year-old primigravida who was referred to the Outpatient Department in the 1st Department of Obstetrics and Gynecology, Medical University of Warsaw at 15-16 weeks of gestation due to suspicion of the uterine mass, most likely a fibroid. The referral ultrasound revealed a single fetus in cephalic position with normal anatomy, normal uterine myometrium and ovaries. A vascularized mass with dimensions corresponding to 10.24 x 6.47 x 9.80 cm, located in the paraaortic retroperitoneal space was identified. Subsequent MRI confirmed the diagnosis. Due to unknown type of the tumour and significant growth patient underwent a laparotomy at 22 weeks of gestation and a complete excision of the tumor was performed. Pathological examination revealed a paraganglioma. Further course of the pregnancy was unremarkable - at 38 weeks patient delivered vaginally a healthy female neonate 2740g/51cm with Apgar score of 10/10. Currently, the infant is 20 months old with normal neurodevelopment.

Conclusions
Since a PPGLs during pregnancy are such a rare findings, current management strategies are based on the case reports and expert opinions. Early diagnosis, treatment in a referral center and individual approach remain the key elements to improve perinatal outcomes in such cases. Before 24 weeks of the gestation a laparoscopic approach may be a first choice, however patients affected with prominent tumours shall undergo laparotomy due to technical limitations. On the other hand, tumour excision shall not affect the method of the delivery - caesarean section and vaginal delivery are possible. In patients diagnosed with PPGLs in the third trimester the treatment shall be administered after the delivery.

Internal Case Report

Date: 8th May 2022, 8:30 AM

Coordinators:
Monika Polkowska
Monika Ryglewicz

Patronage:

Konsultant Krajowy w dziedzinie Chorób zakaźnych

Prof. dr hab. n. med. Andrzej Horban

Polskie Towarzystwo Lekarskie

Prezes Polskiego Towarzystwa Lekarskiego

prof. Waldemar Kostewicz

[1155] MILLER-FISHER SYNDROME IN 78 YEAR-OLD WOMAN PRESENTING AS A STROKE MIMIC – a rare case report

Authors: Raminta Šulskutė1, Giedrius Šulskus1, Jurga Jagminaitė2, Justina Petraškaitė2
Affiliation: 1Lithuanian University of Health Sciences, Academy of Medicine, Faculty of Medicine, Kaunas, Lithuania; 2The Hospital of Lithuanian University of Health Sciences Kaunas Clinics, Department of Internal Medicine, Kaunas, Lithuania
Trustee of the paper: Rasa Sadeckaitė, MD

Corresponding author: Giedrius Šulskus (giedrius.sulskus@gmail.com)

Background
Miller-Fisher syndrome (MFS) is a rare neurological disorder and a clinical variant of Guillain-Barré syndrome (GBS), typically characterized by ophthalmoplegia, ataxia and areflexia. In elderly patients with an atypical presentation without limb weakness and preceding infection the diagnosis is often delayed. The aim of this report is to present a case of MFS and analyze characteristic symptoms that may be helpful in the diagnosis of rare neurological diseases.

Case Report
A 78-year-old female (negative for SARS-CoV-2) was admitted to the Neurology Department with an acute focal neurologic signs like unsteady gait and partial left ptosis. Acute brainstem stroke was suspected. Brain CT at onset and after few days was performed to confirm cerebrovascular disease, however no ischemic changes were found. Brain MRI also didn't show evidence of stroke. Later, due to patient's worsening neurological condition (bilateral external ophthalmoplegia, diminished deep tendon reflexes) and observed progression of respiratory failure (RF), she was referred to Intensive Care Unit. Based on these findings, a MFS was suspected. Diagnosis was confirmed with decreased distal motor and sensory amplitudes on electroneuromyography and elevated protein with a normal white blood cell count in CSF. Patient was successfully treated with intravenous immunoglobulin along with rehabilitation and permanent tracheostomy due to persistent RF.

Conclusions
Our patient presented with the classic triad of clinical features in MFS with gradually progressive RF. This case highlights that patients with this syndrome may present with progressive RF needing intensive care therefore early diagnosis is crucial for successful treatment. Furthermore, MFS may be complicated to diagnose as the syndrome is rare. However, it is important to include this syndrome in the differential diagnosis of anyone presenting with ataxia, ophthalmoplegia and areflexia. The gradual onset and progressive nature of MFS symptoms may help to distinguish from an acute brainstem stroke.

[1212] Doctor, I don’t eat because it hurts - typical symptoms of abdominal angina

Authors: Weronika Cyranka
Affiliation: Students’ Scientific Society at the Department of Interventional Radiology and Neuroradiology, Medical University of Lublin
Trustee of the paper: Maryla Kuczyńska, Anna Drelich-Zbroja

Corresponding author: Weronika Cyranka (weronika.cyranka@gmail.com)

Background
Visceral atherosclerosis occurs very often, even in 6-10% of population. Despite frequent atherosclerotic lesions in the aorta and its branches, debilitating symptoms of abdominal angina are very rarely observed, mostly in patients with occlusion of at least two visceral organs. In other cases, a rich collateral circulation allows homeostasis to be maintained.

Case Report
50-year-old female patient was admitted to the ER due to severe abdominal pain. Postprandial exacerbation of symptoms resulted in limited food intake. Urgent abdominal CT was performed in native phase, which indicated severe atherosclerotic lesions at the origin of both celiac trunk and superior mesenteric artery, raising the suspicion of a complete occlusion. Findings were further confirmed with DSA, which depicted retrograde contrast inflow to hepatic artery, splenic artery and distal via collateral circulation. Successful Balloon angioplasty of the proximal SMA followed by stent implantation was performed.
After initial clinical improvement, patient started to observe relapse of the postprandial symptoms just 4 months following the intervention. Doppler US evaluation of the celiac arteries indicated progressive restenosis of the SMA.
3 years following the initial treatment, when patient started to experience the magnitude of symptoms comparable to the first admission, the residual lumen of the stent was equal to 2.5 mm and hemodynamic parameters psv 4.8ms and edv 2.2 m/s indicated severe in-stent restenosis. Post-stenotic blood flow with tardus-parvus wave was observed in distal SMA, HA and splenic artery. Marked post stenotic dilatation of SMA to 10 mm was visible as well.
The patient was qualified for endovascular treatment of the in-stent restenosis

Conclusions
Abdominal angina has variety of symptoms. A debilitated patient on ER, who reports postprandial abdominal pain should always be diagnosed for this disease. Although CT angiography is the method of choice to assess the patency of visceral vessels, Doppler ultrasound provides valuable information on hemodynamic conditions and collateral circulation capacity, especially in the case of massively released atherosclerotic lesions, which may make it difficult to unequivocally assess the tissue. Currently, endovascular treatment is the method of choice in the angina and its recurr
ences.

[1218] Adenoid cystic carcinoma of the main carina – a rare cause of chronic cough.

Authors: Łukasz Banaszek, Monika Rudzińska
Affiliation: Students' Research Group 'Alveolus', Medical University of Warsaw, Poland Department of Internal Medicine, Pulmonary Diseases and Allergy, Medical University of Warsaw, Poland
Trustee of the paper: Marta Dąbrowska, MD, PhD

Corresponding author: Łukasz Banaszek (likethebanan@gmail.com)

Background
Although cough is a common symptom of lung cancer, the latter is not a common reason of chronic cough (CC). Adenoid cystic carcinoma (ACC) is a rare type of lung cancer, comprises less than 1% of all lung cancers. It is a low-grade tumour arising from the bronchial wall glands. Therefore, it is infrequently taken into consideration as a cause of CC. We report a case of patient with CC who has been diagnosed with ACC.

Case Report
A 54-year-old woman, ex-smoker was admitted to the Department of Internal Medicine, Pulmonary Diseases and Allergy with history of 12 months productive CC. Her medical history included arterial hypertension, osteoarthritis and history of 25 pack-years of smoking. Physical examination revealed no abnormality. The chest X-ray was normal. In spirometry moderate irreversible airway obstruction was found and eosinophilia was documented in induced sputum analysis. Thus, non-allergic bronchial asthma was preliminary diagnosed and inhaled corticosteroids with long-acting beta-agonists were introduced. Due to relevant smoking history chest CT was performed and revealed a slight swelling of main carina and small tree in bud opacities in both lungs. During bronchoscopy with endobronchial ultrasound (EBUS) the rough swelling of main carina was confirmed and biopsy was performed. Additionally, bronchoalveolar lavage fluid and EBUS-TBNA of the tumour and subcarinal (N7) lymph node were done. Pathologic examination confirmed ACC, while there were no pathological findings in the N7 lymph node. BAL was negative for any bacterial culture. FDG-PET/CT did not reveal enhanced FDG uptake neither in the main carina lesion nor in other tissues. Patient was referred for surgery.

Conclusions
In conclusion, a thorough differential diagnosis is crucial in patients with CC. Moreover, in adults with cough and smoking history lung cancer should be considered in the differential diagnosis. Adenoid cystic carcinoma, a rare type of lung cancer, may also be a reason of CC.

[1234] Surprise, surprise! – Single coronary artery diagnosed in 83-year-old woman

Authors: Olga Jakubik, Paulina Putowska, Aleksandra Gąsecka, Arkadiusz Pietrasik
Affiliation: Medical University of Warsaw
Trustee of the paper: Aleksandra Gąsecka

Corresponding author: Olga Jakubik (o.jakubik.99@gmail.com)

Background
Single coronary artery (SCA) is one of the rarest congenital coronary artery anomalies, with the incidence ranging from 0.01% to 0.07%. SCA can be either an isolated anomaly or associated with other congenital abnormalities such as bicuspid aortic valve. The malignant variety of SCA is the type in which SCA is located between the aorta and the pulmonary artery.

Case Report
An 83-year-old woman with suspected chronic coronary syndrome (CCS) was admitted to the cardiology department for elective coronary angiography. While performing the procedure, it was difficult to cannulate the left main artery in the left aortic sinus with JL4 and JL3.5 standard catheters. The right coronary ostium was engaged with a JR4 catheter, demonstrating a superdominant right coronary artery with additional left anterior descending and circumflex arteries arising from the right coronary ostium. There were no significant atherosclerotic lesions in any of the branches. The patient received conservative treatment and was discharged from the hospital 1 day later.
Based on the site of origin and anatomical distribution of the branches, SCA is classified into 2 main categories: "R," right type, and "L," left type. In 75% of the cases, the artery is located between the aorta and the pulmonary artery, leading to an increased risk of sudden cardiac death due to its compression. Therefore, additional assessment of the course of the vessel using computed tomography should be considered as a routine diagnostic approach. Approximately 30% of the patients with malignant artery course die during the first 2 decades of life. However, the clinical course in our patient was uneventful. The co-existence of SCA with CCS can have a significant impact on the course of CCS and prognosis. The anomaly may pose a diagnosis and treatment challenge during coronary catheterization and revascularization procedures.

Conclusions
An anomalous course of coronary artery should not be excluded in the diagnostic process even in elderly patients, who have been asymptomatic for most of their life. Medical practitioners performing coronary catheterization are ought to be capable of facing the challenges that may arise during the procedure due to the occurrence of the previously undiagnosed coronary artery anomaly.

[1236] Anabolic steroids abuse-induced heart failure and toxic hepatitis in a young weightlifter

Authors: Katarzyna Anna Skorupska
Affiliation: Poznan University of Medical Sciences
Trustee of the paper: Marta Kałużna-Oleksy

Corresponding author: Katarzyna Anna Skorupska (katarzynaanna.skorupska@gmail.com)

Background

The use of anabolic–androgenic steroids (AAS) by athletes is a recurring problem in the media. We present a rare case of 32-year-old bodybuilder with AAS induced heart failure (HF) and toxic hepatitis.

Case report

A previously healthy 32-year-old bodybuilder referred to cardiology clinic with symptoms of acute HF. The patient has been intensively training weightlifting 4-5 times a week for over five years. He had a history of AAS abuse over the last 4 years. He had no family history of cardiovascular or liver diseases. The first symptoms appeared a year earlier, and ambulatory echocardiography (ECHO) showed left ventricle end diastolic diameter (LVEDD) of 63mm and ejection fraction (EF) of 49%. Despite the symptoms and cardiological consultation, the patient did not stop intensive weightlifting training and taking AAS.
At admission to hospital ECHO showed EF of 25% and LVEDD of 78mm. Laboratory tests revealed significantly elevated troponin levels (42,2pg/ml), NT-proBNP (2288pg/ml) creatine kinase levels (583,8 U/l) and serum transaminases Aspat (45,80U/l), Alat (106,90U/l).
Sex hormones analysis showed elevated levels of testosterone >15ng/ml, prolactin 29,73ng/ml and estradiol 522pg/ml. After pharmacological therapy, clinical improvement was achieved and he was discharged home at his own request.

Six months later, the patient was admitted to the hospital with jaundice, liver enlargement and heart failure deterioration. Laboratory tests revealed significantly elevated Alat 211U/l, Aspat 77U/l and bilirubin 12,36umol/l. Toxic hepatitis induced by AAS was diagnosed. ECHO showed LVEDD enlargement of 83 mm and EF of 15% with global hypokinesis. Coronary angio-CT was normal. Cardiac magnetic resonance confirmed diagnosis of dilated cardiomyopathy, presented LVEDD of 90mm, EF of 10% with signs of myocardial fibrosis. Successful ICD implantation was performed. The patient was discharged in stable clinical condition. At 3 months of follow-up ECHO showed LVEDD of 87mm and EF of 15%. The patient was qualified for the Poltransplant list. After 7 months, a significant reduction in HF symptoms, as well as an increase in the left ventricular EF (up to 30%) and a decrease in the LVEDD to 63 mm, were observed.

Conclusions

This case is indicative of the potential catastrophic effects of AAS and reinforces the warning against use of these drugs.

[1246] A rare course of invasive pulmonary aspergillosis caused by Aspergillus Niger found in the oral cavity of patient with COVID-19 pneumonia

Authors: Dominika Kondyjowska, Aleksandra Włodarczyk
Affiliation: Jagiellonian University Medical College - Department of Angiology
Trustee of the paper: dr hab. Paweł Maga, prof. UJ

Corresponding author: Dominika Kondyjowska (d.kondyjowska@student.uj.edu.pl)

Background
Invasive pulmonary aspergillosis (IPA) is a severe fungal disease of the lung parenchyma. Risk factors include neutropenia, immunosuppression, antibiotic therapy, prolonged treatment with corticosteroids, and lung epithelial damage. There have been limited data about the association of COVID-19 with pulmonary aspergillosis. Therefore, we present a very rare clinical, microbiological, and radiologic course of invasive pulmonary aspergillosis caused by Aspergillus Niger found in the oral cavity of patient with COVID-19 pneumonia.

Case Report
A 64-year-old man was admitted to the emergency department with symptoms of dyspnea and general weakness. Pneumonia was diagnosed, and due to worsening symptoms of acute respiratory failure, non-invasive mechanical ventilation (NIV) was started. The RT-PCR of a nasopharyngeal swab was positive for SARS CoV-2. The patient was transferred to the intensive care unit (ICU). Due to worsening condition, the patient was intubated and assist-control ventilation was used. Material for microbiological screening of tests (blood, urine, bronchial washes-BAL, rectal swab) was routinely collected. An additional examination was to take a smear from the gingival pocket of the teeth in the oral cavity. Laboratory tests showed high inflammatory parameters (IL-6-329.7pg/ml, procalcitonin 24.30ng/ml, WBC 13,47x10 ^{3}/μL), thrombocytopenia (platelets count of 65x10^{3}/μL) and renal failure (eGFR 7). Chest radiograph (X-ray) revealed a shading with speckled and streaked thickenings, partially confluent infiltrative-atelectic lesions, and partially obliterated pulmonary cavities. On day 1, the cultures were positive for Neisseria Meningitidis, Hemophilus Influenzae in bronchoalveolar lavage (BAL), and Aspergillus Niger in the gingival pocket fluid. The serum antigen test (galactomannan, mannan, anty-candida) was negative. In BAL, Aspergillus Niger was not recognized until the 15th after intubation. At that time, the features of an invasive fungal infection were found in the lung CT examination, and was diagnosed with IPA.

Conclusions
The presence of Aspergillus Niger in an oral swab may be a predictor of bronchopulmonary aspergillosis. Untreated, invasive pulmonary aspergillosis usually is fatal so the proper microbiological diagnostics combined with correctly diagnosed clinical symptoms is the key to success in the treatment of IPA.

[1261] Bilateral DBS Vim surgery in ET patient previously treated with Vim gamma thalamotomy without structural post interventional consequences

Authors: Barbara Buchalska
Affiliation: Neuromodulation Section, Students Scientific Group, Department of Neurology, Faculty of Health Science, Medical University of Warsaw
Trustee of the paper: Stanislaw Szlufik, MD, PhD

Corresponding author: Barbara Buchalska (buchalskabarbara@gmail.com)

Background
The essential tremor (ET) is a condition diagnosed in a patient who has history of action tremor and comprises one of the most commonly diagnosed movement disorders. The medical treatment is often inefficient and recently several advanced therapies have been introduced. These include the Gamma Knife thalamotomy and DBS Vim, which were proven to be effective, but some patients still do not benefit from these treatment methods.

Case Report
A 63-year old woman reported in the 2016 postural and kinetic tremor of upper limbs which have been present for years. The MRI did not reveal any abnormalities. The patient was diagnosed as ET and started to take respectively propranolol, primidone and gabapentin. The prescribed drugs did not noticeably reduce the tremor, so in the 2017 the patient underwent the Gamma Knife thalamotomy to alleviate her symptoms. However this procedure did not bring any improvement – what is more, postinterventional MRI procedure revealed no structural changes in the patient's brain besides the fact that the normal rate of radiation has been used in case of radiothalamotomy. Therefore patient was qualified to unilateral left Vim deep brain stimulation which was performed in 12.2019. DBS-Vim noticeably reduced the tremor and the device was set to C+ 1- 0- 1,3V 60us 130Hz, but the patient still had to take propranolol and gabapentin due to left hand tremor. Therefore, due to an enhanced tremor of the left upper limb, patient was qualified to right Vim DBS surgery in 06.2021, in which the Medtronic Activa electrodes were placed in the right thalamus. After that surgery the patient stopped taking drugs and her symptoms disappeared. The electrodes were set to C+ 1- 0- 1,9V 60us 130 Hz in the left thalamus and to C+ 1- 0- 1,4V 60us 130Hz in the right thalamus.

Conclusions
Some patients with ET may be refractory to Gamma Knife thalamotomy, but might respond well to DBS Vim surgery. Both of these methods can be safely used in one patient if there is no structural change after radio-thalamotomy.

[1285] Intramyocardial dissection of the left ventricle - a case report of a rare complication of myocardial infarction

Authors: Joanna Katarzyna Pergoł, Julia Dróżdż
Affiliation: Medical University of Warsaw, Students' Scientific Group, 1st Department of Cardiology
Trustee of the paper: Anna Fojt

Corresponding author: Joanna Katarzyna Pergoł (joanna.pergol8@gmail.com)

Background

Intramyocardial dissection (IMD), although extremely rare, may be a fatal complication of myocardial infarction (MI). The cause can also be non-ischemic, e.g. iatrogenic, as a result of a trauma or an aortic aneurysm. The pathophysiology of IMD involves the dissection of myocardial fibres and blood inflow that leads to neocavitation within the myocardial wall. IMD is a difficult entity to diagnose, since only 40 cases were described in the literature.

Case Report

A 61-year-old man with a history of ischemic cardiomyopathy, with an implantable cardioverter defibrillator, was admitted to the Intensive Cardiac Care Unit because of worsening symptoms of heart failure to NYHA Class IV and nonspecific chest pain. On admission, the patient was distressed with severe dyspnoea. He also presented pale skin, tachypnoea, massive ecchymosis, swelling and vast bullae within the left lower extremity, and swelling of the right leg (caused by an injury and frostbite from two days earlier). The vital signs were: BP 70/50 mmHg, HR about 80, irregular. The heart sounds were quiet. A bedside transthoracic echocardiography showed a depressed left ventricular ejection fraction of 10-15%, as well as a large, balloting structure visible in the light of the left ventricle. The patient was treated with noradrenaline, furosemide, and antibiotics. He was also given fondaparinux, considering thrombocytopenia (83x10^3/µl) and comorbid thromboembolic risk. The decision was made to perform sustained low-efficiency dialysis due to acute kidney injury.
On the next day, the patient's condition was critical with circulatory failure despite the infusion of pressor amines. There was a multi-organ failure followed by metabolic acidosis and elevated levels of rhabdomyolysis parameters.
Ventricular fibrillation occurred and resulted in a cardiac arrest. The rhythm was successfully defibrillated. The patient's condition was critical, he remained in cardiogenic shock with peripheral hypoperfusion. Later that night, the cardiac arrest in the mechanism of pulseless electrical activity occurred, which led to the death of the patient.

Conclusions

The IMD is a rare complication of MI, which can be diagnosed via echocardiography or other imaging techniques, such as computed tomography or magnetic resonance imaging. Management includes conservative treatment and surgical approach for hemodynamically unstable patients. In this case, the patient was not eligible for a surgery due to cardiogenic shock, sepsis and comorbidities.

[1286] A Case Of Double Outlet Right Ventricle With Rare Anatomical Features

Authors: Shreyans Singhvi, Preksha Singh, Gautam Bhandari
Affiliation: Department of Medicine, Manidhari Hospital and Maloo Neuro Centre, India
Trustee of the paper: Dr. Gautam Bhandari

Corresponding author: Shreyans Singhvi (shreyanssinghvi4@gmail.com)

Background
Double outlet right ventricle (DORV) is found in a group of complex heart lesions, which are unified by the characteristic that both great arteries arise predominantly from the right ventricle. The physiology of the DORV after birth is determined mainly by the location of the ventricular septal defect (VSD) in relation to the great arteries as well as the presence or absence of outflow tract obstruction

Case Report
A 27-year-old male patient presented to the emergency room of a tertiary care clinic in Jodhpur, India with chief complaint of dyspnea on rest. The general physical examination was performed and found within normal limits. On physical examination, the patient had tachypnea and appeared cyanotic, with clubbing of fingers and toes along with facial edema. Patient gave a past history of multiple hospital visits for the complaints of growth retardation and breathlessness, but no diagnosis was made.Further, cardiovascular examination was performed, during auscultation the following results were obtained— S2 was loud and single, mid systolic murmur (ejection) along the left sternal border was present. His laboratory investigation reports are as follows- hemoglobin (Hb: 19.4gm/dl) indicating polycythemia, increased levels of hepatic enzymes due to congestive liver and marked hypoxemia with pO2-50 mmHg. Further, Chest Xray-thorax was performed and revealed an enlarged cardiac silhouette due to enlarged right cavities without increased pulmonary vascular markings. His Electrocardiogram showed right ventricular hypertrophy.Echocardiography was found to be the best diagnostic method for the patient. The echocardiography revealed the following findings: situs solitus, blood from SVC and IVC draining into right atrium then to right ventricle, from the right ventricle blood going to aorta and pulmonary arteries, from the pulmonary veins oxygenated blood draining into the left atrium to left ventricle and from the left ventricle it was going to the right ventricle through sub aortic Ventricular Septal Defect (VSD). Right atrium and right ventricle were found dilated with left ventricular ejection fraction (38%) with normal left ventricle size. Infundibular stenosis was found at the pulmonary valve. Normal relationship was found in the great arteries.

Conclusions
Double outlet right ventricle can be quickly diagnosed with echocardiography and treated promptly by surgical intervention.

[1287] A rare case of hydatid cyst of the inter-ventricular septum

Authors: Preksha Singh, Shreyans Singhvi, Gautam Bhandari
Affiliation: Department of Medicine, Manidhari Hospital and Maloo Neuro Centre, India
Trustee of the paper: Dr. Gautam Bhandari

Corresponding author: Preksha Singh (prekshasingh1213@gmail.com)

Background
A Hydatid disease or Echinococcosis is a zoonotic disease caused by the larvae of the cestode species of the genus Echinococcus. Humans are the accidental hosts of the disease, while canines are the definite host. It can present with a systemic cyst and the cardiac manifestation of the disease is rare, due to contractile property of the heart's muscle fibers which provide resistance.

Case Report
A 36-year-old female patient presented to the department of medicine of a tertiary care hospital with chief complaints of occasional chest pain and dyspnoea on accustomed exertion since the past 1 month. General physical examination was performed and found within normal limits. Further, cardiac and radiological examinations were performed. Cardiac auscultation revealed an ejection systolic murmur in left parasternal region. A MSCT Angiogram revealed a large, rounded, well-defined, thin-walled, minimally enhancing, cystic lesion involving inter ventricular septum- projecting towards both the ventricles at mid- cavity level with external compression over ventricular cavities (left ventricle more than right ventricle)- This suggested the diagnosis of hydatid cyst of approximate size 48.3 x 36.5 mm in axial plane with craniocaudal extent of 44.2 mm.

Conclusions
Surgical management with oral albendazole therapy remains the mainstay of treatment. The main principle of surgical treatment is to empty the cyst, remove daughter cysts and the germinative membrane, excise the pericyst, and then obliterate the residual cavity with sutures (capitonnage).As, inter ventricular septum hydatid cyst occurs in only 0.5-2% cases, it's a unique case and its successful treatment and diagnosis can help physicians to treat a similar case.

[1331] Combining advanced therapies and botulinum toxin injections as a possible treatment in Parkinson's disease patient – a case study.

Authors: Karolina Jaros
Affiliation: Neuromodulation Section, Students Scientific Group, Department of Neurology, Faculty of Health Science, Medical University of Warsaw
Trustee of the paper: Stanisław Szlufik, MD, PhD

Corresponding author: Karolina Jaros (karolinajaros99@gmail.com)

Background
Parkinson's disease is a progressive condition. Gradually patients require increasing doses of oral medications to manage the occurrence of symptoms. Nevertheless, patients may reach a point when such treatment is insufficient. Some of them may undergo advanced therapies such as deep brain stimulation (DBS) and infusion pumps with apomorphine or duodopa.

Case Report
A 60-year-old male patient was diagnosed with Parkinson's Disease in 2001. The patient was treated with oral levodopa and dopamine agonist for 15 years. Due to gradually rising doses of oral medicaments and the presence of motor complications such as dyskinesias and motor fluctuations patient was qualified for subthalamic DBS. Initially, with good results, symptoms were alleviated, and doses of oral medicament were lowered.
However, after 5 years, recurrence of dyskinesias and motor fluctuation was observed. The patient suffered from postural instability and dystonia of the left lower limb. Despite alternating stimulation parameters, high doses of medicaments were needed. To manage those symptoms decision upon installing PEG-J and beginning infusions of duodopa was taken. Additionally, due to dystonia, it was decided to perform injections of botulin toxin. A satisfactory effect was reached. The combination of advanced therapies enabled a significant reduction of symptoms and improved patients' quality of life.

Conclusions
The progression of PD is connected with the accumulation of symptoms more difficult to deal with. Combining advanced therapies, oral medication, and injections of botulin toxin may give a chance to reach satisfactory effect and significant improvement in the quality of patients' life.

[1363] Myocardial infarction with multi-vessel thrombosis – is COVID-19 to blame?

Authors: Jakub Komorowski-Roszkiewicz, Natalia Krajewska
Affiliation: Medical University of Warsaw, 1st Department of Cardiology
Trustee of the paper: Anna Fojt MD

Corresponding author: Jakub Komorowski-Roszkiewicz (j.komorowski.roszkiewicz@gmail.com)

Background
Infection with SARS-CoV-2 increases risk of thrombotic complications. Research showed that COVID-19 infection increases the risk of myocardial infarction (MI) and is connected with worse prognosis. Type 1 MI is caused by atherosclerotic plaque disruption, while type 2 is a result of an imbalance between oxygen supply and demand, which potentially arises from embolism to the coronary arteries, respiratory failure or others.

Case Report
A 52-year-old man with a history of hypertension was admitted to the cardiac intensive care unit due to pulmonary oedema. He reported crushing retrosternal pain and severe dyspnea that occured during strenuous physical activity. Auscultation revealed fine crackles in the inferior lobe of the left lung and diminished sound of the right.
The laboratory findings indicated elevated troponin levels (>250 ng/ml).
In ECG there were negative T waves in II, III, aVF and V5-V6, decreased ST segments in leads V2-V4. Echocardiography revealed akinesis of lateral and inferolateral walls with ejection fraction 25%. Chest X-ray disclosed interstitial infiltration in both lungs. The patient was diagnosed with NSTEMI complicated by acute heart failure. Due to hypercapnic pulmonary failure (pCO_2=71mmHg, pO_2=53mmHg, pH=7,11) the patient was intubated and respiratorotherapy was implemented. Despite 100% oxygen being applied, his arterial blood gas did not improve.
In coronarography multivessel disease was present with massive thrombus in left circumflex artery (LCX), left anterior descending artery and right coronary artery. Angioplasty of circumflex branch and balloon catheterization were attempted, which did not restore epicardial blood flow and it ended with asystolic cardiac arrest. RT-PCR test detected gene N2 of SARS-CoV-2, but gene E of the virus was not. Taking into account respiratory failure and the described radiological changes, it was consistent with COVID-19 infection.

Conclusions
COVID-19 has both influence on the pulmonary and cardiovascular system.
In literature a connection between COVID-19 and higher risk of cardiovascular disease with thromboembolism has been established. MI in COVID-19 patients usually occur with massive thrombosis, most often in more than one coronary artery and is connected with poorer outcome.

[1402] Fever in traveler returning from tropical region. Case report

Authors: Aleksandra Bętkowska, Julia Hanke
Affiliation: Students' Scientific Society of the Department of Infectious and Tropical Diseases and Hepatology, Medical University of Warsaw
Trustee of the paper: Dagny Krankowska MD

Corresponding author: Julia Hanke (hanke.julia00@gmail.com)

Background
Diagnosis of fever in travelers returning from tropical areas might be challenging and studies show that in about one third of such cases the cause of fever are tropical infections, of which malaria is the leading cause. Dengue virus (DENV) and chikungunya virus (CHIKV) are hard to distinguish because they are prevalent in the same regions, are spread by the same mosquito species, and have similar clinical manifestations. Patients' education concerning effective protection against mosquito bites are an important element of prophylaxis prior to traveling.

Case Report
A 52-year-old man was admitted to our department due to fever and severe headache, following a trip to Laos and Thailand. Prior to his travel the patient has not consulted a travel medicine doctor. Laboratory blood tests revealed leucopenia, lymphocytopenia, elevated C-reactive protein (CRP) of 59 mg/L, and elevation of ALT 194 u/L, AST 177 u/L, GGTP 230 u/L, ALP 132 u/L. Meningitis was excluded based on normal cytosis in cerebrospinal fluid. Hepatitis A, HBV, HCV, CMV, EBV, and HIV infections were ruled out by serological or molecular tests. Due to elevated CRP and procalcitonin (PCT) of 2,02 ng/mL, the patient was started on ceftriaxone empiric therapy.
Dengue and malaria were ruled out with rapid diagnostics tests (RDT) and no Plasmodium parasites were detected in microscopy. On the 7th day of the disease, the patient developed a rash on the chest and back, and antibiotic treatment was changed to levofloxacin. Another RDT for dengue was negative. Serum IgM antibody titers for CHIKV were positive, which confirmed the diagnosis of chikungunya. After 2 weeks of hospital stay the patient's condition improved, laboratory results were normal, and he was discharged home without any complications.

Conclusions
When diagnosing patients with fever, a question about recent travels is essential in the diagnostic process. Exclusion of malaria should be the gold standard of care of travelers returning from tropical regions with fever. In these situations, dengue and chikungunya should be considered in the differential diagnosis and an infectious disease specialist should be consulted. Prior to departure, travelers require education on preventive measures against arthropod-borne infections including use of mosquito screens, nets, and repellents.

[1412] FMD as a cause of drug-resistant hypertension in young patients – case report.

Authors: Monika Zbroja
Affiliation: Students' Scientific Society at the Department of Interventional Radiology and Neuroradiology, Medical University of Lublin
Trustee of the paper: Maryla Kuczyńska MD, Michał Sojka MD, PhD

Corresponding author: Monika Zbroja (m.zbroja8888@gmail.com)

Background

Fibromuscular dysplasia (FMD) is a rare nonatherosclerotic and noninflammatory vascular disease that can lead to stenosis, occlusion, dissection or aneurysmal dilatation of the affected arteries. It mostly involves the renal, carotid, and visceral vessels. FMD is classified into five categories according to the vessel wall layer affected: intima (5%) - intimal fibroplasia, media: (90-95%) - medial dysplasia, perimedial (subadventitial) fibroplasia, medial hyperplasia and adventitia (rare) - adventitial fibroplasia. Doppler US is the first-line diagnostic modality, while CT angiography is still considered the "gold standard".

Case Report

This case presents a female patient, aged 24, who was diagnosed with high blood pressure values unresponsive to pharmacotherapy. Imaging diagnostics revealed string of beads morphology of the middle and distal renal arterial segments, consistent with FMD. The patient was qualified for endovascular treatment - successful balloon angioplasty was performed resulting in short-term normalization of the BP value, however clinical complaints reappeared.
A CT angiography revealed bilateral short-segment stenosis of renal arteries which prompted the decision about reintervention.The symptoms temporarily disappeared, however after a few months, the problem appeared again. The patient underwent 2 follow-up Doppler ultrasound examinations: first 4 months after the procedure and second 6 months afterwards.
In both examinations the image was pathologic with numerous aliasing areas in color Doppler and accelerations of blood flow up to 200 cm/s, however no local areas of critical stenosis were identified, which was indirectly indicated by normal intra-renal systolic acceleration time.

Conclusions

Depending on the histological form, FMD responds differently to endovascular treatment; with a string of beads lesions the results are worse than with "focal stenosis". The method of choice in the treatment of FMD is balloon angioplasty, whereas stenting is not applicable in this case. In patients with FMD, regular controlling of blood pressure and imaging examinations results are essential to monitor the course of the disease in the renal vessels and to identify possible restenosis

[1441] Patient with cardiodepressive type with asystole of vasovagal syndrome

Authors: Weronika Kowalczyk
Affiliation: Medical University of Warsaw/ Cardiology Department of UCK WUM
Trustee of the paper: Bartosz Krzowski, MD

Corresponding author: Weronika Kowalczyk (wk.weronikakowalczyk@gmail.com)

Background
Syncope is common in clinical practice. It might pose a clinical challenge because of different mechanisms. The most common type is vasovagal syncope (VVS), which mostly occurs in young women, but there are also exceptions to this rule.

Case Report
A 29-year-old man was admitted to hospital because of COVID-19 infection and loss of consciousness without any obvious prodromal symptoms. The episode was not preceded by chest pain, dyspnoea or palpitations. During in-hospital Holter-ECG recording the patient again lost consciousness in a standing position. Holter-ECG showed sinus rhythm 45-105/min, average 60/min, 3 pauses - max 23s. Atrioventricular blocks are more likely to occur in the elders. ECHO showed normal left ventricular ejection fraction, significant valvular defects. There was no fall injury, as confirmed by CT scan. There were no deviations in neurological examination. 15 days later he was transferred to the Cardiology Department of UCK WUM for further diagnostics and potential qualification for pacemaker implantation. Electrophysiological examination showed no atrioventricular conduction disturbance and sinus node automaticity disturbances. Subsequently a tilt test appeared in the 14th minute of upright standing, accelerated sinus rhythm was observed (HRmax 114/min) with slightly decreased arterial pressure, followed by gradual slowing of sinus rhythm with pre-fainting symptoms and sinus asystole of 23.4s with fainting. Sinus rhythm and consciousness returned immediately after the patient was horizontalized. Afterwards, carotid sinus massage was performed without bradyarrhythmia. The patient was diagnosed with cardiodepressive type with asystole of vasovagal syndrome (VASIS type 2B). After consultation with the electrostimulation team, the patient was qualified for further conservative treatment and disqualified from pacemaker implantation. Patient was given specific recommendations regarding lifestyle.

Conclusions
Due to the atypical clinical presentation of the patient, it was a diagnostic challenge. Comprehensive diagnostics, including highly specialized tests, had to be made to plan further treatment. As a result it was possible to avoid a pacemaker implantation and therefore also avoid potential dangerous complications in the young man.

[1484] What could be the origin of an intracerebral hemorrhage in young patient?

Authors: Anna Burban
Affiliation: 1st Chair and Department of Cardiology, Medical University of Warsaw
Trustee of the paper: doc. Agnieszka Kołodzińska

Corresponding author: Anna Burban (s071386@student.wum.edu.pl)

Background

Infectious endocarditis (IE) is a rare disease with high mortality percentage.It usually regards patients from risk groups: those with prosthetic material after cardiosurgery operations or with congenital heart disease and those with previously diagnosed IE. IE can have various manifestations.

Case Report

38-years old man without history of chronic diseases was admitted to the hospital due to acute gastrointestinal symptoms: nausea, lack of appetite, emesis, diarrhoea without bleeding. The onset of symptoms were 2 days prior to the admission without any improvement after previously advised symptomatic treatment.Accompanying symptoms were: fever up to 39o, muscles pains and limbs parestesis.In laboratory findings inflammation markers were remarkably increased (CRP 427 mg/l, PCT 5,17 ng/ml).Conducted tests from faeces for adenovirus, rotavirus, norovirus and c.difficile gave negative results. The decision to conduct computed tomography (CT) before lumbar puncture was made. The CT revealed intracerebral hemorrhage in the left parietal lobe which reached also to the subarachnoid space. Due to aggravation of neurological symptoms (paresis, limited mobility of eyeballs, abnormal extension) the patients underwent a left craniotomy which was done by neurosurgeon. After operation improvement (GCS – 7) was observed but patient remained in a coma for 20 days. The echocardiography was conducted and revealed severe mitral regurgitation with vegetations as typical image of endocarditis on the mitral valve. The perforation of anterior leaflet was observed with leak as a complication. According to the antibiogram of blood culture (S.aureus) antibiotic treatment was implemented: firstly cloxacillin and later ceftriaxon. The decrease of inflammation markers and improvement of patient's general condition was observed in the course of 8 weeks antibiotic therapy. Control echocardiography revealed that mitral regurgitation was moderate hence „heart team" qualified patient for the conservative treatment.

Conclusions

The cerebral haemorrhage was retrospectively assessed as a probably raptured infectious (mycotic) aneurysm. Neurological complications of IE can be the first manifestations of disease. As raptured infectious aneurysm is associated with excess mortality in patients with IE, the special vigilance should be paid to early recognition of patients with endocarditis. As in described case also patients without any past medical history can suffer from IE.

Pediatric Case Report

Date: 8th May 2022, 8:30 AM

Coordinators:
Liwia Rogalewicz
Karolina Piwko

Patronage:

Konsultant Krajowy w dziedzinie Gastroenterologii dziecięcej

Prof. dr hab. Mieczysława Czerwionka-Szaflarska

Konsultant krajowy w dziedzinie pediatrii

Prof. dr hab. n. med. Teresa Jackowska

Polonorum Societas Neonatologica

Instytut Centrum Zdrowia Matki Polki

Prezes: Profesor Ryszard Lauterbach

[1445] Pulmonary nodules – an uncommon extraintestinal manifestation of Crohn's disease: case report

Authors: Karolina Stachyra
Affiliation: Medical University of Warsaw / Department of Gastroenterology, Children's Nutrition and Paediatrics of MUW
Trustee of the paper: dr n. med. Marcin Dziekiewicz

Corresponding author: Karolina Stachyra (kk.stachyra@gmail.com)

Background
Crohn's disease is a chronic inflammatory disorder of unknow aetiology that may affect any part of the digestive tract. Extraintestinal manifestations occur in more than 25% of patients. The musculoskeletal system, skin, in the form of erythema nodusum and pyoderma gangrenosum, as well as liver are frequently involved. Lung involvement is a rare manifestation of Crohn's disease. It could be asymptomatic as well as it could present as bronchiectasis, bronchiolitis, interstitial lung disease or pleuritis.

Case Report
16 years old patient was admitted to the gastroenterology department due to the aggravation of Crohn's disease that had been diagnosed 5 months before. According to the guidelines, chest X-ray was done before the beginning of systemic glucocorticoids treatment. It revealed multiple nodular lesions in the lungs. To enhance diagnostics, chest HRCT and bronchoscopy were performed. Tuberculosis was excluded. Because of the most likely fungal aetiology, empirical treatment with voriconazole was administered. After one week in the control CT an increased number of enlarged nodules was noted. The patient was referred to surgical biopsy in order to perform histopathological examination which confirmed the lung manifestation of Crohn's disease. Monoclonal antibody anti-TNFα, Infliximab, was added to the therapy. In the control chest imaging examinations, the regression of pulmonary nodules was observed..

Conclusions
Inflammatory lesions in the course of Crohn's disease could be located not only in the digestive tract, but also in the other organs. Involvement of respiratory system affects the bronchial tree, pulmonary parenchyma and pleura, causing various clinical symptoms. Whereas lung manifestation is rare, it should not be forgotten in patients with Crohn's disease. On the other hand, inflammatory bowel diseases should be taken into account in the differential diagnosis of atypical lesions or symptoms of the respiratory system.

[1349] Rare neurological complication of antibiotic treatment in 16-year-old girl with Crohn's disease

Authors: Karolina Maria Rybak, Aleksandra Warchoł
Affiliation: Medical University of Warsaw / Department of Pediatric Gastroenterology and Nutrition
Trustee of the paper: Marcin Dziekiewicz MD, PhD

Corresponding author: Karolina Maria Rybak (karolinar789@gmail.com)

Background
Metronidazole is an antibiotic with activity against anaerobic bacteria and protozoa. In patients with Crohn's disease (CD), metronidazole is recommended to treat perianal fistulas, abdominal abscesses and to use in postoperative period. It could be also used in a combination with azithromycin for induction of remission in a mild-to-moderate CD where nutritional therapy is not an option. Metronidazole-induced encephalopathy is a rare complication, most commonly reported in adults. The symptoms are diverse, but magnetic resonance imaging findings are usually distinctive. This is the first case of metronidazole-induced encephalopathy in a patient treated with rectal metronidazole together with its oral form.

Case report
A 16-year-old girl with CD treated with enteral nutrition, mesalazine and metronidazole in oral and rectal forms for three and a half weeks was admitted to the hospital for surgical treatment of perianal fistulas and abscesses. The surgery proceeded without complications. The patient received intravenous metronidazole in the perioperative period. Two days after the surgery, the patient's general condition deteriorated, and symptoms of cerebellar syndrome appeared. She presented with an inability to coordinate balance and gait. Though she was in full logical contact, her speech was slow, slurred, and scanning. Finger-nose test was positive. The laboratory tests results were normal. As there were no abnormalities in computed tomography, the MRI was performed. The T2/TIRM images showed an increased symmetrical signal of white matter together with dentate nuclei of the cerebellum and in the corpus callosum lobe. The changes were characterized by restricted diffusion. Based on the clinical picture and MRI findings, metronidazole-induced encephalopathy was diagnosed. Treatment with metronidazole was discontinued; neurological symptoms resolved after six days.

Conclusions
Physicians treating their patients with metronidazole should be aware that it can cause neurological side effects including metronidazole-induced encephalopathy. Immediate cessation of treatment may resolve symptoms.

[1355] Hantavirus as the cause of haemorrhagic fever with renal syndrome.

Authors: Benedykt Baljon, Justyna Bogdan
Affiliation: University of Rzeszów
Trustee of the paper: Katarzyna Wiącek, MD

Corresponding author: Benedykt Baljon (baljonbenek@gmail.com)

Background
Hantaviruses are single-stranded RNA pathogens whose reservoirs are mainly rodents. Most often, infection occurs by inhalation through contact with the faeces or urine of an animal carrying the virus. In Poland, hantavirus infections are usually caused by the Puumala and Dobrava serotypes. We report a case of a 15-year-old girl with haemorrhagic fever with renal syndrome (HFRS) caused by hantavirus.

Case report
A 15-year-old patient with suspected generalized infection and symptoms of gastrointestinal infection was transferred from the Specialist Hospital in Sanok to the 1st Pediatrics and Pediatric Gastroenterology Clinic in Rzeszów for further diagnosis. The patient reported a fever, vomiting, abdominal pain, diarrhea and anuria. During hospitalization, numerous petechiae on the girl's body were found, as well as single lesions caused by rat scratches. Blood analysis revealed also high inflammatory markers, thrombocytopenia, elevated transaminases and ferritin, and decreased level of serum complement C3. Urine tests were performed showing microscopic hematuria and proteinuria. HFRS was taken into consideration in the differential diagnosis because patient have been exposed to rodents. The diagnosis of hantavirus infection was confirmed by serological tests. The results of performed tests allowed for the implementation of appropriate treatment and the girl made full recovery.

Conclusions
Haemorrhagic fever with renal syndrome is rapidly progressive and requires prompt diagnosis and appropriate treatment. Hantavirus infections should be considered as a possible cause of acute kidney injury in children, especially with fever and thrombocytopenia.

[1264] A rare case of an infant with Wilms tumor

Authors: Daniel Bałut
Affiliation: Students Scientific Circle within Warsaw Medical University's Pediatric and Nephrology Clinic, Warsaw Medical University
Trustee of the paper: Agnieszka Szmigielska, MD, PhD

Corresponding author: Daniel Bałut (daniel.balut@interia.eu)

Background

Wilms tumor (nephroblastoma) is the most common renal cancer among children. In Poland there are reported about 70-80 new cases yearly. It can have various symptoms, the most important is bump in abdomen. Others include haematuria or erythrocyturia, rarely impairment of urine flow and associated with urinary tract infections. Due to the risk of dissemination, biopsy of the kidney to confirm the cancer isn't performed during diagnosis. The most important tool is methods of diagnostic imaging such as ultrasound, renal scintigraphy and abdomen CT. According to SIOP (International Society of Paediatric Oncology) guidelines, recommended method of treatment of Wilms tumor includes pre- and postoperative chemotherapy, radiotherapy and surgery of removal of remains of the tumor and visible lymph nodes.

Case report

4 months old girl was admitted to Nephrology Clinic due to abnormal ultrasound (US) findings in the left kidney. In controlled US, performed a month later, enlarged pyelocalyceal system was observed again and vascularized homogeneous structure sized 12x9x7mm in the pelvis. When she was 3 months old, renal scintigraphy was performed and revealed possible cyst or other lesion in the left renal hilum which caused partially difficulties in outflow from its superior calyx. The patient was consulted during multidisciplinary meetings, but a structure in kidney didn't arouse oncologic suspicion. At the age of 9 months abdomen CT was performed and showed enlargement of the structure to 26x20x28 mm and enlargement of the pyelocalyceal system to 10-12 mm. The structure filled the left renal hilum completely, it was quite homogeneous, without calcifications, moderately homogeneously contrast enhanced and renal pelvis pressured. Due to the suspicion of Wilms tumor preoperative chemotherapy was started. 4 weeks later left nephrectomy was performed. In histopathological examination nephroblastoma was confirmed. Chemotherapy was continued for next 6 months. Currently a girl is 6 years old. Her controlled abdomen US is normal. The right kidney is compensatively overgrown and has proper echostructure and thickness of renal parenchyma and without enlargement of the pyelocalyceal system.

Conclusions

Wilms tumor is diagnosed most often in children between 1 and 4 years old and very rarely below 6 months old.
A tumor localizes usually around the pole of the kidney, however our patient had it in the middle of the renal pelvis.
US plays key role in early diagnosis of tumors among children.

[1352] GIST in children as a rare cause of upper gastrointestinal bleeding

Authors: Paulina Woźniak, Zuzanna Mikus
Affiliation: Medical University of Warsaw/ Department of Paediatric Gastroenterology and Nutrition
Trustee of the paper: Marcin Dziekiewicz PhD

Corresponding author: Paulina Woźniak (paulinawoz777@gmail.com)

Background

Gastrointestinal tumours are an extremely rare condition in children and may present with several nonspecific symptoms such as vomiting, anaemia or abdominal pain. We present a case of a paediatric patient diagnosed with gastrointestinal stromal tumour as a rare cause of upper gastrointestinal bleeding.

Case report

An 11-year-old girl was admitted to the Department of Paediatric Gastroenterology and Nutrition, Medical University of Warsaw with a suspicion of bleeding from Meckel's diverticulum. She presented anaemia, fatigue, syncope, periodic episodes of moderate abdominal pain and hematemesis. Before the onset of those symptoms, the patient required an oral iron supplementation due to slightly lowered haemoglobin concentration (HBG 12,4 g/dl), otherwise she was healthy.
In physical examination the patient presented pallor, no enlargement of lymph nodes or liver and spleen was found. The laboratory testing indicated severe anaemia (HBG 4.5 g/dl) and positive Faecal Occult Blood Test. Transfusion of 4 units of red blood cells concentrates elevated haemoglobin concentration to 7.8 g/dl.
Abdominal ultrasound and chest X-ray did not expose any pathologies. A scintigraphy was performed though it revealed no ectopic gastric mucosa. As a next step gastro- and colonoscopy were conducted. Multiple tumours protruding into the gastric lumen were found. The MRI scan demonstrated numerous lesions in stomach, peritoneum and liver, presumably of neoplastic aetiology.
The patient was consulted by an oncologist. Endoscopic tumour biopsy revealed a Gastrointestinal Stromal Tumour (GIST) and imaging tests showed that the neoplastic process was diffuse. The girl was qualified for imatinib treatment however, despite one-month therapy, the results were unsatisfactory. She required several blood transfusions and parenteral nutrition due to profuse hematemesis. The patient has scheduled a follow-up visit after 3 months and needs further oncological treatment.

Conclusions

The presented case highlights the importance of thorough diagnostics, despite a patient presenting with common symptoms such as abdominal pain or vomiting. Despite numerous more common causes of hematemesis in the paediatric population we must keep oncological vigilance, as early diagnosis of neoplastic processes can significantly improve patients' prognosis.

[1314] Challenges of treating an adolescent with early-onset schizophrenia: managing of inadequate effect of scarce medication and multiple suicide attempts

Authors: Gintė Gaižauskaitė
Affiliation: Vilnius University, Faculty of Medicine
Trustee of the paper: Evelina Petrauskaite, MD

Corresponding author: Ginte Gaizauskaite (ginte.gaizauskaite@mf.stud.vu.lt)

Background
Early-onset schizophrenia is considered to have worse course and prognosis than later onset schizophrenia. Additionally, selection of medication when treating adolescents is limited due to lower amount of research on drugs and shorter officially approved list of antipsychotic drugs depending on country to country.

Case report
16-year-old female was admitted to Vilnius Republican Psychiatric hospital following her fourth suicide attempt. Her psychiatric disorder manifested when she was 11 years old with eating and affective disorders. When she was 13 delusion of persecution manifested, later visual and auditory hallucinations appeared and she was diagnosed with paranoid schizophrenia at 14. She was hospitalised 7 times. Patient was treated with haloperidol, olanzapine, aripiprazole, risperidone, tiapride, and combinations of neuroleptics. Patient constantly took trihexyphenidyl due to extrapyramidal symptoms, she also had hyperprolactinemia when treated with risperidone. Antidepressants such as sertraline, mirtazapine and fluvoxamine were tried for improving her mood but every time discontinued due to worsening symptoms of psychosis. Patient's suicidal attempts were followed by states of prepsychosis, when she starts to intensively experience depersonalisation, formal thought disorder, nihilistic delusion and extremely low mood. She has a long history of self-harm using razors and knives to cut her arms, legs, chest, breasts, groin and genitals. Patient is constantly anaemic despite iron supplementation. 3 of her suicide attempts were self-cutting of wrists or ankles and 1 was trying to overdose with drugs. After her fourth suicide attempt it was decided to start treatment with reserve antipsychotic clozapine due to inadequate effect of other medication. At the end of hospitalisation positive early effect was noted – patient had redacted positive symptoms, her mood was more stable, she had no suicidal thoughts.

Conclusions
Adolescent patient was treated for paranoid schizophrenia with all suitable and available in Lithuania antipsychotic drugs. Reserve treatment with clozapine seems to be successful at the moment but it is unclear what awaits in the future. Mood stabilising effect of clozapine is expected to reduce the risk of another attempt of suicide. Early-onset schizophrenia poses difficult challenges in treatment, managing side effects and prevention of suicide.

[1167] Time matters in pediatric oncology: an unusual case of an aggressive tumor and a happy end

Authors: Marta Andrzejewska, Jakub Czarny
Affiliation: Poznan University of Medical Sciences / Department of Pediatric Oncology, Hematology and Transplantology
Trustee of the paper: Magdalena Samborska MD, PhD; Prof. Katarzyna Derwich, MD, PhD

Corresponding author: Marta Andrzejewska (78774@student.ump.edu.pl)

Background
A rapid tumor diagnosis is required, particularly when it comes to pediatric oncology, as most pediatric cancers develop turbulently. Early diagnosis and treatment application increase the chances of recovering from neoplastic disease. Numerous factors influence the diagnostic delays, including telemedicine, which involvement rose significantly in COVID-19 pandemic time. It led to a significant decline in oncological screening and new diagnoses, with more advanced cancer stages observed.

Case report
We present a case of a 17-year-old male complaining of a watery leak from the right nasal aperture since June 2020. The symptoms did not alleviate after the administration of antihistaminic drugs. In September 2020 he noticed nasal occlusion, followed by an online laryngological appointment during which nasal polyps were diagnosed. In October 2020, an unpleasant smell and pinkish color of the leak, enlarged right carotic lymph nodes and occlusion of the left nasal aperture were observed. The patient was then referred for nasal polyps removal. However, a CT scan showed a soft tissue mass filling the nasal cavity, destroying its bones, protruding into the nasal sinus and other adjacent anatomical structures. Rhinoscopy showed the tumor in the right nasopharynx. Due to such suspicion, a biopsy was taken. Preliminary histopathological diagnosis indicated olfactory neuroblastoma G3/G4. Due to the tumor progression manifesting with the further right cheek edema, right exophthalmos and left carotid lymph nodes enlargement, one dose of vincristine was administered. Finally, the diagnosis of olfactory neuroblastoma/biphenotypic sinonasal sarcoma was established, allowing for the implementation of treatment according to CWS Guidance 2014 Protocol - VAIA III group. The patient completed treatment in November 2021 and remains in remission under the care of the outpatient children oncology clinic.

Conclusions
The described case shows unacceptable delays in diagnosing an uncommon pediatric cancer with a potential for rapid progression. More advanced stage of the disease at the moment of diagnosis contributes to adverse prognosis, especially concerning soft-tissue sarcoma and older children. It emphasizes the need for onsite medical consultations in order to detect disturbance early and to apply proper treatment.

[1265] Ansa pancreatica - a case report of a pediatric patient with pancreatitis.

Authors: Daniel Bałut, Jan Jankowski
Affiliation: Students' Scientific Group GEKON, Department of Pediatric Gastroenterology and Nutrition, Medical University of Warsaw, Warsaw, Poland
Trustee of the paper: Jan Bukowski, MD

Corresponding author: Daniel Bałut (daniel.balut@interia.eu)

Background
Ansa pancreatica (AP) is a rare anatomical variant of pancreatic ducts. The frequency of it is 0.25-1.1% among adults who had an imaging of bile ducts performed and 3-3.4% among children with recurrent pancreatitis. We reviewed all 19 cases of AP using Medline and Embase. Only one case concern pediatric patient. We would like to present a case report of boy from our Department with AP.

Case report
12-years-old male patient was admitted to the hospital in due to recurring episodes of pancreatitis. In magnetic retrograde cholangiopancreatography (MRCP) was described an anatomical variant - ansa pancreatica. The other potential causes of chronic pancreatitis were excluded: no predisposing mutations of genes were found; the lipid panel, level of calcium and immunoglobulin G4 (IgG4) were correct; alpha-1 antitrypsin deficiency, cholelithiasis and coeliac disease were excluded; no medication and stimulants were noticed. During endoscopic retrograde cholangiopancreatography (ERCP) sphincterotomy and stent positioning were performed. During the 19-months observation, the stent was replaced in gradually increasing diameter every 3-4 months. The patient was still asymptomatic between hospitalizations. In follow-up no strictures of the main pancreatic ducts were described in ERCP; the stents were removed. To date, the patient has had no recurrence of pancreatitis.

Conclusions
AP may be related to pancreatitis in children.
MRCP is a diagnostic tool for AP.
ERCP may be a diagnostic as well as therapeutic procedure in children suffered from pancreatis.
Further research is needed.

[1300] Type 1 diabetes in an adolescent with social problems and mental disorders – case report

Authors: 1 Agnieszka Grobelczyk, 2 Ewa Rusak, 2 Sebastian Seget, 3 Agata Chobot
Affiliation: 1Pediatrics' Students Scientific Association, University of Opole 2Department of Children's Diabetology, Medical University of Silesia 3 Department of Pediatrics, Institute of Medical Sciences, University of Opole
Trustee of the paper: Agata Chobot

Corresponding author: Agnieszka Grobelczyk (agnieszka.grobelczyk@gmail.com)

Background
Discontinuation of type 1 diabetes (T1DM) treatment rapidly leads to diabetic ketoacidosis (DKA) which is a life-threatening condition. Our case report is intended to draw attention to persons with T1DM and significant social/psychological problems. The case of our patient highlights the need for relevant legal and administrative regulations that would allow for quick, safe and adequate care.

Case report
Our patient was diagnosed with T1DM at the age of 17 years (July 2019). She was admitted to the regional diabetes centre with typical symptoms of hyperglycaemia, dehydration, and compensated metabolic acidosis. Standard symptomatic treatment and insulin therapy were implemented according to the current recommendations of Diabetes Poland. The consulting psychiatrist diagnosed behavioural and emotional disorders and polytoxicomania. Within 7 months of the diagnosis she was 7 times hospitalized due to DKA. In December 2019 she was again admitted to the diabetes centre. She ran away from the hospital. A few weeks later emergency services brought her in a critical state to hospital. On admission she was unconscious (GCS: 6), with symptoms of hypovolaemic shock and severe DKA. As her state improved she was moved to the paediatric ward. The consulting psychologist concluded that she showed self-destructive behaviour related to the lack of treatment and ostentatious consumption of excessive amounts of sugar. Taking all of the above into consideration, the patient was transferred to a psychiatric ward in another hospital. The attending psychiatrist refused to admit her to hospital so she was temporarily sent to the Police Emergency Youth Centre (PEYC). The PEYC was not able to ensure supervision over T1DM treatment so the girl was readmitted to the paediatric department - this time under 24-hour police supervision. Finally, after numerous interventions the court ordered an obligatory observation in the psychiatric ward.

Conclusions
In T1D the lack of insulin treatment is a direct threat to life. Mental disorders and/or social problems impair self-management and treatment or make it completely impossible. It also represents a significant challenge for the diabetes team, which needs support from consulting doctors of other specialties, social workers, or other services. The case of our patient shows that currently there are no relevant legal regulations that would allow quick and adequate care for such a child.

[1271] Complete precocious puberty induced by classic congenital adrenal hyperplasia in a boy

Authors: Zuzanna Lubczyńska
Affiliation: Medical University of Warsaw, Clinic of Pediatrics and Endocrinology
Trustee of the paper: Anna Kucharska MD PhD

Corresponding author: Zuzanna Lubczyńska (zuzanna.smiech@gmail.com)

Background

We present a case of complete precocious puberty induced by classic simple virilization congenital adrenal hyperplasia (CAH) in a boy. CAH is defined as a group of AR hormonal disorders associated with impaired cortisol synthesis. Most common mutation in patients with classic CAH causes disturbances in synthesis of the adrenal steroid 21-hydroxylase enzyme, which leads to accumulation of the cortisol precursors, that are redirected to sex hormone synthesis pathway, causing excessive androgenic stimulation. As a result, precocious puberty and increased bone age can occur. Although currently at-birth screening for CAH is common, some patients may still receive late diagnosis and face poor growth prognosis.

Case report

Patient presented at the age of 6 6/12 with symptoms of precocious puberty: seborrhea and acne. General exam, abdominal US and head MRI showed no abnormalities. Testicular US showed prepubertal testicular volume. In Tanner scale, pubarche PIII and gonadrache GII was determined. Hormonal workup revealed normal cortisol level of 10.9 mcg/dl, but elevated levels of 17-hydroxyprogesterone (1600 ng/dl), ACTH (62.2 pg/ml), testosterone (29 ng/dl) and androstenedione (8.7 ng/ml). Blood serum sodium and potassium levels were normal. Gonadotropin stimulation test and GS-MS urinary steroid profile were conducted and confirmed the diagnosis of classic simple virilization CAH.
At presentation, increased bone age of 12.5 y was determined. This can be attributed both to excessive androgenic stimulation and massive adrenal androgen surplus leading to the onset of true precocious puberty which caused further bone maturation and worsened growth prognosis. Patient received hydrocortisone supplementation and GnRH analogue therapy. As a result of the treatment, bone age maturation velocity was reduced with only minimal decrease of the growth rate. Close supervision led to significant improvement of growth prognosis. At 17 11/12 years boy achieved satisfactory midparental height of 177.3 cm.

Conclusions

Presented case is an example of dramatic improvement of the growth prognosis in a boy with classic simple virilization CAH. Accurate diagnosis and introduction of proper therapy allowed to reduce the velocity of bone age maturation and led to satisfactory endpoint height. Is it therefore of vital importance, that children with advanced bone age should be treated under close supervision in order to obtain satisfactory clinical results.

[1343] Esophageal atresia in a preterm neonate with birth asphyxia and inferior vena cava thrombosis – a case report

Authors: Jeremi Zając
Affiliation: Medical University of Warsaw / Klinika Chirurgii Dziecięcej, Urologii Dziecięcej i Pediatrii
Trustee of the paper: Marek Wolski, MD PhD

Corresponding author: Jeremi Zając (jeremi.zajac99@gmail.com)

Background
Esophageal atresia, appearing in roughly 1 in 3000 live births, is a long-known birth defect. In isolation, it has good prognosis, but comorbidities may lower it significantly. Here I present a case complicated by premature birth and coagulopathy – with a successful outcome.

Case report
A female neonate of 1900 grams at 36 weeks of gestation was delivered via a C-section with an Apgar score of 0-0-2-3-5-5 at 1-2-3-5-10-15 minutes. The baby was cyanosed, gasping, no neonatal reflexes nor muscle tone were present and only single heart tones were heard.
Examination after successful reanimation revealed resistance while inserting a gastric tube. X-ray scans showed signs of esophageal atresia and pneumonia, and antibiotic therapy was introduced. An echocardiogram showed no cardiac abnormalities.
The baby was transferred to a Neonatal Intensive Care Unit to undergo therapeutic hypothermia, which lasted 72 hours. Then, on the 4th day of life, she was qualified for the surgery during which a tracheoesophageal fistula was ligated. Anastomosing of the esophagus was delayed due to a long gap and insufficient tissue elasticity – likely because of the hypothermia. The baby was thus equipped with a Replogle tube.
On the 26th day of life, the baby's inflammation parameters increased and A. junii was found in her blood culture – necessitating an antibiotic therapy. At the same time, oedema of the baby's thigh alarmed the staff. An ultrasonography scan revealed inferior vena cava thrombosis spanning the whole vein. Facing the spread of thrombosis to the right atrium, the decision was made to insert a microcatheter to the atrium and deploy a stent retriever. A 48-hour course of thrombolytic treatment was introduced, fortunately without central nervous system bleeding, followed by unfractionated heparin.
On the 45th day of life, the girl was transferred to the Pediatric Surgery Department and an esophageal anastomosis was successfully created. The baby was in good condition in the following days. A contrast study revealed no anastomotic leak and the girl tolerated oral nutrition.
In the second month of her life, she remained in good condition, her vaccination schedule was completed, and she was sent home under hematological, nephrological and neurological supervision.

Conclusions
The case described above showcases multifaceted nature of premature infants. The diseases impact each other, which stresses the need to remain flexible in treating such children.

[1299] Obesity in adolescents - complications may appear even in childhood

Authors: Agnieszka Grobelczyk1, Aleksandra Pławiak1, Agata Chobot2
Affiliation: 1Pediatrics' Students Scientific Association, School of Medicine, University of Opole, Poland 2Department of Pediatrics, Institute of Medical Sciences, University of Opole, Poland
Trustee of the paper: Agat Chobot

Corresponding author: Agnieszka Grobelczyk (agnieszka.grobelczyk@gmail.com)

Background
Obesity is an increasingly common civilization disease faced by developed and developing countries. Obesity develops in children and adolescents, directly increases the risk of obesity and related diseases in adulthood. Out of 4 obese 6-year-olds, one will also be obese as an adult (25% risk), while in the case of 12-year-olds, as many as 3 will not overcome obesity in adulthood (75% risk).

Case report
Two boys were seen by a pediatrician - a 13-year-old (patient 1, P1) and a 17-year-old (patient 2, P2), both were overweight (P1: 103.5 kg, 172 cm tall, body mass index (BMI) 35; P2: 111 kg, height 172 cm, BMI 37.5,). The physical examinations revealed excessively developed subcutaneous tissue, acne lesions, stretch marks, and elevated blood pressure. Both of them were aware of their illness and dietary mistakes. However, in-depth diagnostics showed differences between the patients:
P1 has been found to have hyperlipidemia. Morphology, renal and hepatic markers, ionogram, triglycerides, cholesterol, vitamin D3, TSH and FT4 levels remained normal for age. Additionally, glycemia in OGTT and HbA1c 5.5 - normal. Due to insulin resistance metformin 500 mg was included in the treatment. In the past, the boy attempted suicide. In the case of P2, due to impaired fasting glucose, abnormal OGTT, HbA1c (5.9%) and antibodies specific for type 1 diabetes (negative) type 2 diabetes was diagnosed - oral medications were introduced. Additional studies showed hypercholesterolemia, lack of optimal hypothyroidism compensation and D3 hypovitaminosis.
The two cases presented emphasize that there is no single standard clinical picture of obese patients. Our patients, despite similar initial states and the lack of any ailments, struggle with completely different health problems, which, however, are typical consequences of obesity.

Conclusions
The course of obesity depends on the individual conditions of the patient - genetic predisposition, mental health, and external factors. Doctors caring for pediatric patients in addition to the ability to correctly diagnose and treat obesity and its complications in children, they should also remember to implement prevention and educate their patients and their caregivers from an early age, which could partially contribute to inhibiting the alarmingly high percentage of obese children and adolescents.

[1296] Esophageal achalasia in an 11-year-old patient with persistent respiratory symptoms and suspected bronchial asthma.

Authors: Julia Skulimowska, Agnieszka Strzelak, Agnieszka Szczukocka-Zych
Affiliation: Medical University of Warsaw / Department of Pediatric Pulmonology and Allergology
Trustee of the paper: Julia Skulimowska

Corresponding author: Julia Skulimowska (julia.skulimowska@gmail.com)

Background
Cough can be classified into acute, when lasts less than 4 weeks, and chronic, when present for longer than 4 weeks. The most common cause of chronic cough in pediatric population is bronchial asthma, with estimated prevalence of 11% of school-age children in Poland. It must be differentiated with other pulmonary diseases such as airway lesions, recurrent viral bronchitis, atypical pneumonia and tuberculosis, as well as with diseases of non-pulmonary origin, including gastrointestinal reflux, postnasal drip and psychogenic cough. Esophageal achalasia is a disease characterized by the inability of the lower esophageal sphincter to relax, which results in persistent contraction and the lack of peristaltic movement in the esophageal body. Most common symptoms include dysphagia, aspiration, persistent cough with sputum expectoration and rapid breathing. The occurrence of this disease is rare, especially in pediatric population, therefore its identification may be challenging.

Case report
An 11-year-old patient with chronic cough, post-exercise rapid breathing and a history of aspiration was admitted to the Pediatric Pulmonology Department with suspected bronchial asthma. The diagnosis was rejected since the patient showed the signs of upper/central airway obstruction in spirometry. Videobronchoscopy was performed, visualizing a severe narrowing of the trachea, leading to its periodic luminal collapse. Gastroscopy revealed the dilation of the lower esophagus. Final diagnosis of esophageal achalasia was given after performing contrast-enhanced upper gastrointestinal tract X-ray. The patient was referred to the Children's Surgery Department to receive appropriate treatment.

Conclusions
Rare diseases may be the cause of common symptoms, therefore special caution needs to be taken in order to avoid misdiagnosis. Esophageal achalasia should be suspected when the patient complains about chronic cough and rapid breathing with accompanying dysphagia and a history of aspiration. Despite the rare occurrence of esophageal achalasia, this disease should be included in differential diagnosis of bronchial asthma in children.

[1174] Thoracoscopic anastomotic technique in treatment of long-gap esophageal atresia: case report

Authors: Zofia Kędzierska
Affiliation: University of Warmia and Mazury in Olsztyn, Collegium Medicum, School of Medicine, Paediatric Surgery Students' Association, Poland
Trustee of the paper: Michał Puliński, MD, PhD

Corresponding author: Zofia Kędzierska (zo.kedzierska@gmail.com)

Background
Long-gap esophageal atresia (LGEA) is a congenital anomaly in which the gap between both ends of the esophagus exceeds three intervertebral spaces, or is too long for early primary repair. One of the most high-tech surgical techniques is the thoracoscopic esophageal reconstruction method. In all cases, the aim should be to preserve the patients' own esophagus. The most common, both early and long-term, complication of surgical treatment is anastomotic stenosis, which requires endoscopic dilation at later stages of treatment.

Case report
This case describes a male newborn with congenital LGEA admitted to the hospital on the first day of life for the diagnosis and treatment of the congenital defect. The patient was born at 39 weeks of gestational age by cesarean section. He was a first child, from a second pregnancy, which was complicated with suspected esophageal atresia (as seen in prenatal ultrasound) and polyhydramnios. A gastrointestinal tract X-ray with iodine contrast showed a contrast stop at the Th1 level with the esophageal lumen widening up to 14 mm. The image corresponded to pure atresia (Gross type A) at this level. The procedure was a four-stage endoscopic approach followed by delayed esophageal anastomosis. At each stage, the technique of thoracoscopic internal traction of the proximal and distal esophagus was used. The follow-up series showed efficient esophageal passage to the stomach; at the level of Th6, the esophageal lumen was narrowed to 1 mm over a length of 8 mm, and above the stenosis it widened to 13-15 mm. Due to clinical deterioration and feeding difficulties the patient was qualified for endoscopic esophageal dilation. The attempt to insert the endoscope was unsuccessful, and therefore the Rehbein procedure was performed with the oro-esophageal-gastro-cutaneous 'endless' thread leading out. Thanks to this method, it is possible to safely expand the constricting anastomosis every few days without the need for esophagoscopy. Due to facial dysmorphia and the congenital defect of the esophagus, the patient underwent an array CGH test. A heterozygous interstitial duplication of a fragment of the long arm of chromosome 14 was detected.

Conclusions
An effective surgical method in LGEA is the thoracoscopic technique with the use of internal traction. A common complication of surgical treatment is anastomotic stenosis which requires further surgical interventions. Congenital esophageal obstruction may be an isolated defect or coexist with genetic defects.

[1479] An unusual presentation of orbital abscess associated with an extensive dental caries and pulp gangrene in a 14-years old boy with asthma.

Authors: Sonia Demianiuk, lek. Maciej Pilch
Affiliation: Medical University of Warsaw / Pediatric Otolaryngology
Trustee of the paper: lek. Maciej Pilch

Corresponding author: Sonia Demianiuk (demiason@gmail.com)

Background
Extensive dental caries with pulp gangrene in seventeen teeth resulting in an orbital abscess is rare in children. This case study seems extraordinary as it required an oral surgeon's intervention and could be connected with asthma treatment. The objective of this clinical presentation is to highlight that infection from decayed teeth in children can cause severe complications such as an orbital abscess.

Case report
A 14-years-old boy was admitted to the hospital with dextral orbital complications (eyelids swelling, exophthalmos, restricted eye movements), buccal swelling, unilateral sinusitis and impaired breathing. Two days before admission to hospital, a patient was taking Clindamycin. Despite the antibiotic, the symptoms escalated. The patient suffers from severe asthma from the 7th month of age. Treated with Budesonide/Formoterol, Bilastine, Ciclesonide and Salbutamol in case of dyspnoea. The bronchodilatory test was negative. Underwent SARS-Cov-2 infection in December 2021. Reported obesity. Allergic to Penicillin and Augmentin. Bilateral Otitis Externa was present. Examination showed extensive dental caries and pulp gangrene. Contrast Enhanced CT scanning revealed large abscess of right orbit and unilateral right sinusitis. Patient was qualified for surgical treatment including drainage of an abscess from external approach, endoscopic sinus surgery of maxillary sinus, extraction of teeth with a pulp gangrene and reconstruction of an oroantral communication using periosteal-mucous flap. Culture grew resulting in S.Epidermidis and S.Intermedius clindamycin-resistant infection. A systemic antibiotherapy was given (Ceftriaxone) with Dexamethasone (IV), topical treatment of Ciprofloxacin in the ear canal and Xylometazoline to the nasal cavity. The treatment was successful and all symptoms resolved. However, the patient was further referred not only for dental and prosthetic treatment, but also required to remain under the supervision of a pulmonologist, allergologist and dietician.

Conclusions
This case should serve to emphasize the impact of dental caries and unilateral sinusitis as predisposing factors for orbital abscess. Interestingly, massive dental decay may be connected with long term inhaled corticotherapy. Moreover, obesity can increase the risk for severe asthma, so therefore lifestyle modification is crucial to avoid acute complications. We should put more effort into prevention - especially in asthmatic patients.

[1302] Secondary refractory lymphoblastic leukemia in the patient with Li-Fraumeni syndrome

Authors: Julia Białowąs
Affiliation: Spherocyte, Medical University of Warsaw
Trustee of the paper: Katarzyna Smalisz, MD, PhD

Corresponding author: Julia Białowąs (juliabialowas25@gmail.com)

Background

Li-Fraumeni syndrome is an autosomal dominant genetical disorder. The germline alterations in the TP53 gene are associated with the occurrence of neoplasms. The risk of developing cancer by the age of 20 is 30-40%.

Case report

5-year-old boy, was admitted to the hospital due to fever, lymphadenopathy, pancytopenia.
Past medical history: The patient was diagnosed with the Choroid plexus carcinoma at the age of 4 months and underwent chemotherapy and surgery. Because of the diagnosis he was referred for genetic testing. The result of NGS described a heterozygous c.469G>A mutation in the TP53 gene. He was found to have a Li-Fraumeni syndrome. The patient's father was then diagnosed. After a year he developed prostate cancer and then glioblastoma multiforme. He died as a result of chemotherapy toxicities.
On admission, the child was in general good condition. Physical examination showed: small petechiae, supraclavicularly lymphadenopathy, hepatosplenomegaly. In laboratory tests: anaemia (HGB 10g/dl), thrombocytopaenia (PLT 28000/mm3), neutropenia (NEUT 530/mm3), negative ATLS markers. The child's condition deteriorated quickly. Under local anaesthesia, an urgent biopsy of the nodal mass and bone marrow was performed and T-cell lymphoblastic infiltration were detected. He presented features of superior vena cava syndrome. Life-saving steroid therapy was recommended. Chemotherapy with AIEOP BFM 2017 was started. Because of the bad response, the patient was classified in the HR group. Before the second block MRD showed features of molecular relapse. It was decided to modify the chemotherapy to 2nd and 3rd line. Venetoclax - a selective inhibitor of anti-apoptotic protein Bcl-2 - was included. The boy was qualified for hematopoietic stem cells transplantation.

Conclusions

Secondary malignancies are often resistant to treatment. Trials of new drugs with low toxicity (kinase inhibitors, monoclonal antibodies) may increase patient survival. The bone marrow transplant offers hope for a cure of leukaemia. The patient cannot undergo radiotherapy due to his diagnosed Li-Fraumeni syndrome. It could increase the chance of developing another cancer. The boy will require three-stage very strict oncological monitoring.

Surgical Case Report

Date: 8th May 2022, 8:30 AM

Coordinator:
Robert Kołaczyński

[1133] Comparison of emergency vs elective femoro-femoral extracorporeal membrane oxygenation in transcatheter aortic valve implantation – two case reports

Authors: Kawthar Safi
Affiliation: Department of Cardiac Surgery, Medical University of Warsaw, Warsaw, Poland
Trustee of the paper: Radosław Wilimski, MD, PhD

Corresponding author: Kawthar Safi (kawthar.bs15@gmail.com)

Background
Femoro-femoral extracorporeal membrane oxygenation (ECMO) has been used to support hemodynamically unstable patients undergoing Transcatheter Aortic Valve implantation (TAVI). ECMO's role as rescue or bridging therapy is of particular importance in patients with severe cardiac dysfunction and those at high risk of cardiogenic shock. We present two cases in which ECMO was performed in both emergency and prophylactic settings.

Case Report
Case 1 was a 68 year old male qualified for TAVI due to severe aortic stenosis (Vmax 4.55 m/s, AVA 0.24 cm/m2). Patient history included chronic heart failure (NYHA class III, EF 40-45%), pulmonary hypertension, two ischemic strokes, arterial hypertension, diabetes type II and obesity (STS score 1.7%, EuroScore II 1.5%). A 26 mm Medtronic Evolut R bioprosthesis implantation with femoral artery access was attempted and complicated by severe mitral regurgitation, asystole and acute respiratory failure. Emergency veno-arterial ECMO was implemented alongside external cardiac massage. Due to severe paravalvular leak a second aortic bioprosthesis implantation was performed with good final result. Total ECMO duration time was 54 hours. Postoperative echocardiography revealed minor paravalvular leak (Vmax 1.6 m/s, AVA 2.1cm2 , EF 54 %). Wound infection in the left groin was treated with antibiotics. Hospitalization time was 40 days. Case 2 was a 78 year old female with severe aortic stenosis (Vmax 3.3 m/s, AVA 0.65 cm2), dyspnea at rest and refractory hypotension, resistant to fluid and catecholamine administration, admitted for TAVI procedure with elective ECMO support (STS score 4.3%, EuroScore II 4.9%). Prior patient history includes coronary artery disease, coronary artery stent implantation, chronic heart failure (EF 22%) and chronic obstructive pulmonary disease. Due to inadequate diameter (too small) of the implanted aortic Abbott Portico 25 mm bioprosthesis second valve implantation was performed successfully with the 27 mm bioprosthesis. ECMO duration was 1 hour and it was explanted immediately after TAVI. Postoperative echocardiography revealed insignificant paravalvular leak, Vmax 1.6 m/s, AVA 1.8 cm2, EF 20%. No complications were observed. Total hospitalization time was 8 days.

Conclusions
Although ECMO indications are well known, there remains scarce data regarding elective ECMO use for selected, high risk TAVI patients. Given the presented cases, elective ECMO use may improve TAVI procedure outcome and reduce hospitalization time.

[1158] Refractory peripancreatic fluid collections suggestive of Disconnected Pancreatic Duct Syndrome

Authors: Apolonia Miążek
Affiliation: Department of General, Oncologic, Gastrointestinal Surgery and Transplantology
Trustee of the paper: Tutor: Jakub Kenig M.D. Ph.D. Prof. of Jagiellonian University; Head of the Department: Prof. Piotr Richter M.D. Ph.D.

Corresponding author: Apolonia Miążek (pola.miazek@student.uj.edu.pl)

Background
Disconnected Pancreatic Duct Syndrome (DPDS) is a rare complication of acute necrotizing pancreatitis (ANP). Symptoms develop from the co-occurrence of focal pancreatic duct necrosis with the preservation of viable pancreatic tissue. Restricted evacuation of pancreatic juice leads to the formation of fluid collections and external pancreatic fistulas. Complications of pancreatitis accompanied by DPDS require more sophisticated management and have a higher recurrence ratio than pancreatitis alone. Nonspecific clinical presentation and little awareness account for the underdiagnosis of DPDS.

Case Report
A 44-year-old male was admitted to a local hospital with severe dyspnea caused by the left-sided pleural effusion. Imaging results led to the recognition of pancreatic-pleural fistula, which was successfully closed by implementing conservative medical therapy. Abdominal MRI revealed extensive fluid collections in the left abdomen and abnormalities of the pancreas. With suspected complications of acute pancreatitis, the patient was transferred to our department. His laboratory findings were anemia, elevated procalcitonin, and CRP levels. Both GGTP and blood serum amylase were above the normal range. CT scans and EUS confirmed many fluid collections surrounding the spleen and pancreatic tail. Images of the pancreas displayed tail atrophy with calcifications and irregularly lobular parenchyma. Radiographic results were suggestive of chronic pancreatitis complicated with episodes of acute pancreatitis. A distal pancreatectomy procedure resulted in the uncomplicated removal of the pseudocyst together with the pancreatic tail and body. Histopathological examination supported acute pancreatitis as the trigger for observed pathologies.

Conclusions
DPDS complicates up to 20% of acute necrotizing pancreatitis episodes, constituting a clinically significant issue. CT scans, routinely performed in ANP, are not sufficient to distinguish pancreatic duct disruption. Hence the diagnosis requires confirmation in ERCP or MRCP. Also, EUS, carried out for our patient, has been recently suggested as a method of equivalent significance. Despite ever-developing endoscopic techniques for DPDS management, surgery remains the preferred treatment.

[1164] A rare indication for liver transplantation? - Calcifying Nested Stromal Epithelial Tumor in young female.

Authors: Emilia Kruk, Konrad Kobryń, Paweł Rykowski, Benedykt Szczepankiewicz, Waldemar Patkowski, Krzysztof Zieniewicz
Affiliation: Department of General, Transplant and Liver Surgery, Medical University of Warsaw, Poland
Trustee of the paper: Konrad Kobryń MD

Corresponding author: Emilia Kruk (emiliakruk1@gmail.com)

Background
Calcifying Nested Stromal Epithelial Tumor (CNSET) is an extremely rare (45 reported cases) primary tumor of the liver occurring mainly in children and young females. Microscopic characteristics consist of defined nests of spindle and epithelioid cells in desmoplastic stroma with variable calcification and ossification. CNSET management lacks established treatment strategies, the most common and the most successful being liver resection, that provided recurrence free survival in 31/35 reported cases. Various implemented treatments include neo-adjuvant and adjuvant chemotherapy, radiofrequency ablation, chemoembolization, and liver transplantation.

Case Report
28-old female presented for further diagnosis of incidentally detected hepatic tumor. Computed tomography scan (CT) revealed lesion measuring 20x18x15cm that was claimed unresectable. Core needle biopsy was performed, and patient was diagnosed with CNSET. Patient did not qualify for systemic therapy and was re-evaluated for surgical treatment but given local progression of the disease she was once again disqualified from liver resection. Patient's condition began to deteriorate with severe abdominal pain and elevated liver enzymes. Given no evidence of extrahepatic disease and no other treatment options available, patient was approved for liver transplantation and underwent a procedure 1 year after initial presentation. Patient was discharged from hospital on postoperative day 42, and on follow-up she remained well 15 months after liver transplantation.

Conclusions
Scarcity of information and rarity of CNSET result in no established standards of care for patients diagnosed with this neoplasm. Most of implemented treatment strategies are either of preservative or experimental nature. Chemoembolization, ablation, and chemotherapy that have been implemented turned out to be unsuccessful. Even though in most cases course of the disease is mild and liver resection is optimal and definitive resolution, there are reports of highly aggressive course of the disease and emergence of distant metastases. There are 8 known cases of liver transplantation for CNSET, 2 of those cases report recurrence and are the only known cases of distant CNSET metastases. Liver transplantation can be considered as an appropriate treatment strategy for CNSET, but it is mandatory to rule-out any possibility of extrahepatic disease beforehand to provide the best clinical outcome.

[1179] The type B aortic dissection with in situ laser fenestration and off-label stenting.

Authors: Adrian Bednarek ; Jerzy Leszczyński ; Oskar Gąsiorowski
Affiliation: Medical University of Warsaw
Trustee of the paper: PhD Jerzy Leszczyński

Corresponding author: Adrian Bednarek (adibednarek@gmail.com)

Background
Aortic dissection is a life-threatening disease occurring in 3.5 of 100,000 patients. 30% of cases are determined as Stanford type B, which treatment is based on medical supplementation or the stent-graft implanting surgery. Sometimes, a close position to the aortic arch contributes to insufficient stent sealing, which can be overcome by covering the left subclavian artery (LSA) ostium. In these cases, to minimize the risk of left upper limb ischemia and stroke, the revascularization of the LSA should be performed. When there is no time to wait for branch stent-graft deliverance, the usage of a custom-made device can be an effective technique. Here we present the case of extensive type B aortic dissection, with the LSA revascularization approach by in situ laser fenestration and off-label implantation of aortic BeGraft stent.

Case Report
A 62-year man was admitted to the department of general surgery, endocrinology, and vascular diseases for the recommended surgical treatment of Stanford type B aortic dissection. A computed tomography scan revealed extreme narrowing of the true canal on the level of visceral arteries and the obstruction of the superior mesenteric artery, which was associated with a high risk of visceral impairment. Dissection reached up to the left common iliac artery and the right external iliac artery. The thoracic endovascular repair (TEVAR) with ZENITH TX2 thoracic stent-graft was performed for the closure of the primary entry. Due to the short neck of the aneurysm localized close to the ostium region of the LSA, the coverage of this part for a better stent-graft seal was carried out. To ensure blood flow, the in situ laser fenestration was performed in the on-shelf thoracic stent-graft. To prevent ischemia, the self-expanding ZILVER and covered BeGraft stents were implanted across fenestration to the LSA. The control aortography revealed the elimination of the dissection's primary entry, enlargement of the true canal, and improved circulation in the visceral arteries with the restoration of the superior mesenteric artery. The patient in stable condition, without the limbs and viscera ischemia symptoms, was qualified for the home discharge and further observation.

Conclusions
The in situ laser fenestration and implantation of BeGraft stent to the LSA connected with the TEVAR procedure may be a functional approach for preventing the left upper limb and cerebral ischemia, even in extensive acute type B aortic dissections.

[1209] A case report: inflammatory myofibroblastic tumour of the bladder.

Authors: Ugne Mickeviciute
Affiliation: Vilnius University Faculty of Medicine, Lithuania
Trustee of the paper: Dr. Albertas Cekauskas

Corresponding author: Ugne Mickeviciute (mickeviciute.ugne@gmail.com)

Background
The inflammatory myofibroblastic tumour is known since 1939 and significant knowledge about it has been generated during the last few decades. Unfortunately, more than eight decades later we are still incapable to answer questions regarding the pathophysiology and aetiology of this condition as well as to understand the possible behaviour of these tumours. All the cases of inflammatory myofibroblastic tumours should be recognised thoroughly because of the importance to accumulate knowledge and experience regarding diagnostics and treatment of these cases.

Case Report
A 54-year-old male who has not been previously diagnosed with any illnesses was consulted for haematuria. A bladder tumour was suspected after ultrasound examination which showed papillary masses in the bladder. Pelvic computed tomography showed 6 x 5 cm homogenous mass in the anterior wall of the bladder with clear margins and wall infiltration. The patient was hospitalized for transurethral tumour biopsy to clarify the diagnosis and to decide whether the systematic neoadjuvant treatment is necessary. Histopathological analysis confirmed the diagnosis of inflammatory myofibroblastic tumour spreading in the urothelial stroma and ALK (2p23) rearrangement was also confirmed with the molecular FISH technique. It was decided to perform a open partial cystectomy. The patient has completely recovered. A follow-up plan is scheduled for six months.

Conclusions
Knowledge about the inflammatory myofibroblastic tumour was firmly expanded during the last few decades. Single case reports must be recognized, and larger-scale research should be initiated particularly to build awareness of the existence of such lesions, as well as the education of medical staff which should make a significant change in expanding perception of IMT and management of new cases.

[1216] Massive deceleration injury of the thoracic aorta: a case report.

Authors: Chukwudum Igbokwe, Aleksandra Fryncel
Affiliation: Medical University of Warsaw
Trustee of the paper: Jerzy Leszczyński MD

Corresponding author: Chukwudum Igbokwe (igbokwechukwudum@yahoo.com)

Background
Massive deceleration injuries are life-threatening concerns in collision accidents and the understanding of the human anatomy that are at high risk of damage, proves valuable in the rapid and successful treatment in emergency situations. In our case study, we draw focus to the part of the thoracic aorta, about 1cm inferior to the left subclavian artery and stretches about 5cm along the thoracic aorta, the region of aortic isthmus.

Case Report
A 21-year-old man was admitted to the hospital after a car crash with symptoms of respiratory failure and hemorrhagic shock. Urgently performed CT-scan showed ruptured thoracic aorta and the patient was qualified for urgent intravascular operation. During surgery, Surgeons had difficulties with passing the leader through because of the stenosis of the aorta caused by the accident. Finally, the surgeons managed to insert a catheter pig-tail into the ascending aorta and ordered arteriography. The patient received 3000 heparin units, then through the right inguen they inserted stent-graft Zenith Alpha 24x105 into the thoracic aorta, the loss of pulse on the left internal carotid artery (LICA) appeared. Consequently, the decision about applying the second stent-graft Bentley into LICA was made, which is rather complicated due to the short sealing zone for the thoracic-stent graft, thus occlusion of the LICA. Therefore, the supplementary implantation of a covered stent with the use of chimney technique to LICA as emergency procedure to maintain patency is necessary and unusual.

Conclusions
Stabilization of the vessel wall is the main goal as time is of the essence to restore homeostasis and adequate hemodynamics of the ruptured traumatic thoracic aorta. Vascular reconstruction using the Zenith Alpha and Bentley stent grafts is a practical, safe and commonly used surgical technique. However, it is not uncommon to have complications as in the aforementioned case, which must be corrected using the chimney technique.

[1280] Congenital Intramuscular Arteriovenous Malformation In The Gluteal-Femoral Region Treated With Combination Treatment: A Case Report

Authors: Ugnė Katiliūtė, Birutė Vaišnytė MD PhD
Affiliation: Department of Cardiovascular medicine, Vilnius University, Vilnius, Lithuania.
Trustee of the paper: Ugne Katiliute

Corresponding author: Ugnė Katiliūtė (ugne.katiliute@mf.stud.vu.lt)

Background
Intramuscular arteriovenous malformations (AVMs) are a rarely encountered high-flow pathology that manifest with a rather complex vascular anatomy. Due to this reason, treatment often presents challenges and requires individual approach. Several treatment options are discussed in the literature, including surgical excision or resection, endovascular treatment with various embolic and sclerosing agents. The purpose of this case report is to demonstrate our center experience in dealing with such cases and focus on the most relevant AVMs management options.

Case Report
Male patient (57) presented to the clinic with a painful tumor like mass in the right gluteal-femoral region, that was previously thought to be lipoma. Physical examination revealed pulsatile nature of the tumor. Suspecting AVM, ultrasound (US) was further carried out, revealing vascular mass with tortuous veins and arterial blood flow. Dynamic contrast-enhanced MRI (DCE-MRI) uncovered well vascularized high-flow shunting vascular mass amid gluteus maximus and adductor magnus muscles, possibly with adipose tissue inserts. Size 128x68x32mm. It was determined to perform a multi-stage approach surgical treatment, starting with Onyx embolization. After two days, excision of congenital AVM was successfully accomplished. Follow up examination based on symptoms, US and DCE-MRI uncovered complete resection without relapse. Patient is happy with overall treatment results.

Conclusions
Although, surgical excision provides the best long-term treatment results for AVMs, it's not always feasible. In this case, regarding functional muscle involvement and AVMs infiltration into surrounding tissues, embolization with Onyx was conducted first to achieve the best clinical outcome. Therefore, the lesion became smaller and more attainable for complete surgical excision. This is a successful case of individualized surgical treatment strategy for intramuscular AVM.

[1344] Negative pressure wound therapy of an extensive neck carbuncle – a case report

Authors: Jeremi Zając
Affiliation: Medical University of Warsaw / Katedra i Klinika Chirurgii Ogólnej, Gastroenterologicznej i Onkologicznej
Trustee of the paper: Katarzyna Mech, MD PhD

Corresponding author: Jeremi Zając (jeremi.zajac99@gmail.com)

Background
Diabetic patients are especially prone to developing nuchal boils and carbuncles. Neglected, they may spread to the face and require aggressive surgical treatment to prevent intracranial infection. The following case report outlines an unconventional line of treatment of such a carbuncle.

Case Report
A 60-year-old male suffering from ill-controlled type 2 diabetes was admitted to the Department from the A&E because of an 8-day-long history of worsening pain and swelling at the nape of his neck. He reported having a fever on the day of admission and denied having any other chronic diseases. The patient mentioned having similar, albeit less severe, symptoms 2 years prior to the admission. Physical examination revealed a large lesion in the nuchal region, which was oozing with pus upon palpation. The lesion reached the right margin of the patient's face and was surrounded with inflamed tissues. An ultrasound scan revealed a 20 mm deep layer of a thick fluid in his subcutaneous tissue. A diagnosis of a carbuncle was made, empiric antibiotic treatment was introduced, and the patient was qualified for wound debridement under general anaesthesia. The lesion was drained and lavaged, dead tissues in channels penetrating from the carbuncle were debrided and proper drainage was secured. A pus culture was taken. On the fourth post-operative day painfulness and inflammation in the patient's occipital and facial region were increasing. Palpation revealed additional fluid reservoirs, separate from the main cavity. The patient was thus qualified for reoperation and all new lesions were drained. On the 8th day after admission the patient's inflammation parameters were steadily decreasing and the decision was made to begin negative pressure therapy. Pus cultures came positive for S. aureus, antibiotic therapy was adjusted accordingly. After two weeks the wound was healing correctly, the patient was in good condition and was judged ready to continue treatment as an outpatient. He was informed about the importance of blood sugar management in the healing process and was referred to a plastic surgeon to tackle his remaining, although no lesser, cosmetic issue.

Conclusions
The described case not only showcases negative-pressure wound therapy as a viable part of treatment of nuchal carbuncles, but also stresses the importance of proper diabetologic care – which may have significantly decreased this patient's risk of developing a serious staphylococcal infection in the first place.

[1346] Da Vinci Robot System surgery as the optimal treatment of the lingual thyroid: a case study.

Authors: Maria Rutowicz
Affiliation: Medical University of Warsaw; Otolaryngology and Otolaryngological Oncology Department in Military Institute of Medicine in Warsaw
Trustee of the paper: ppłk dr hab. n. med. Kornel Szczygielski; Łukasz Skrzypiec, MD

Corresponding author: Maria Rutowicz (marysiarut131@gmail.com)

Background
Lingual thyroid is a rare anomaly where a thyroid gland tissue fails in descending from the foramen caecum to pre-laryngeal site during embryogenesis. The ectopic thyroid gland tissue is usually located at the base of the tongue, which determines its clinical image. It can also be asymptomatic.
Da Vinci Robot System can be an option in many medical fields but due to less common accessibility, it is not that widely used, especially in otorhinolaryngology. It provides greater precision of the surgeon's movements and better visualization and access to some structures than other types of surgery, which was used in this patient's case.

Case Report
A 62 years old female, treated for hypothyroidism, presented at the clinic with a tumor at the base of the tongue previously diagnosed as an ectopic thyroid. It was diagnosed at the age of 10 but left with no treatment. Prior to the hospitalization she had suffered from occasional dyspnoea, dysphagia, sensation of fullness in her throat, which all led also to insomnia. She had also noticed more frequent throat infections prior to the hospitalization and hypernasal speech. The diagnosis of ectopic thyroid gland tissue, measuring 27 x 28 mm with an elongated bottom part 12 x 10 mm and enlarged lingual tonsil, was confirmed with imaging and scintigraphy. A trans-oral robotic surgery (TORS) with da Vinci Robot System was performed. The lesion with lingual tonsil were removed up to lingual pits. In the control visits the patient claims resolution of all the previous symptoms.

Conclusions
Due to the localisation of lingual goiter/ectopic thyroid gland tissue in this patient's case there would have been very difficult to access the lesion in a classic trans-oral endoscopic approach, so an external neck procedure would have been discussed. The use of the da Vinci robot system gave the patient a chance for a less invasive surgery which led to reduced risk of complications of the procedure, quicker convalescence and lesser scarring.

[1358] Intraperitoneal localization of the whole large colon causing acute abdomen- a case report

Authors: Monika Lis
Affiliation: Medical University of Warsaw/ Katedra i Klinika Chirurgii Ogólnej, Gastroenterologicznej i Onkologicznej
Trustee of the paper: Katarzyna Mech, MD PhD

Corresponding author: Monika Lis (monikalis1267@gmail.com)

Background
Transverse colon volvulus is an unusual cause of the colon obstruction. This case report presents transverse colon malformation formed as a result of a rare anatomical abnormality. The anomaly manifests itself in intraperitoneal localization of the whole large colon. Additionally the mesentery of the large colon isn't attached to a posterior wall of the abdominal cavity.

Case Report
An 18-year-old woman arrived at the Emergency Department showing symptoms of the acute abdomen. Patient's condition was moderately severe . On examination the patient was oriented and her chief complaint was an abdominal pain. The abdomen was tender and distended. No bowel sounds were detected and the muscle guarding was increased, especially in the left lower quadrant. Past medical history revealed gastroschisis surgery in the first day of life, an episode of the colon obstruction caused by a vulvulus about 5 years ago and numerous hospital admissions due to painful abdomen. CT showed signs of the colon obstruction and the malrotation of the sigmoid colon. The patient was qualified for an immediate laparotomy. The abdominal cavity was full of a brown, translucent fluid and the transverse colon was necrotic. Further inspection revealed intraperitoneal localization of the large intenstine. Its mesentery wasn't attached to the posterior wall of the abdominal cavity. Extraordinarily, the colon loops were hanging in perforations located in the mesentery of the transverse colon. Extended resection of the colon was performed and the side-to-side anastomosis was created beetwen the ascending colon and the sigmoid colon. A control of hemostasis didn't reveal any hemorrhage. Postoperative condition was stable, although requesting long recovery.

Conclusions
Anatomical abnormalities ,which may lead to life threatening complications, are difficult to diagnose using the imaging studies in spite of the contributory past medical history. The laparotomy happens to be the only way to expose them. Th case report shows the importance of the awareness of the rare medical conditions as their unexpected finding during surgery is challenging for the operators.

[1362] How far can we walk with non-diagnosed DDH?

Authors: Kacper Kuczyński, Katarzyna Kwas
Affiliation: (1) SKN Ortopedii i Traumatologii Uniwersytetu Medycznego w Łodzi; (2) KLINIKA ORTOPEDII Z PODODDZIAŁEM ORTOPEDII DZIECIĘCEJ, Centralny Szpital Kliniczny Uniwersytetu Medycznego w Łodzi
Trustee of the paper: MD PhD Błażej Pruszczyński

Corresponding author: Kacper Kuczyński (kacper.kuczynski@stud.umed.lodz.pl)

Background
Developmental dysplasia of the hip, which is also called congenital hip dislocation, is a disorder leading to disability in childhood and early adult life. It can disturb child development by affecting its locomotor system. Child with that condition might not get its milestones on time. Adequate growth and development of the hip depends on two main factors: concentric positioning of the femoral head into the acetabular cavity and adequate balance in growth between triradiate and acetabular cartilage. Any alteration in these two conditions leads to hip dysplasia.

Case Report
The 6 years old patient presented a rocking gait lasting 1,5 year. Before, she walked normally. Physical examination showed that left ASIS outran 20 degrees right ASIS. Right lower limb was 15 mm shorter than the left. X-ray showed right hip sprain and scoliosis. Three months later, patient was admitted to the hospital on a scheduled basis, CT was performed, oblique position of the pelvis advanced dysplasia of the hip with its full sprain was observed. Right femur was located laterally and upwards by 21mm. The loss was filled with fat tissue, right acetabulum was significantly shallow, features of smaller dysplasia in the left hip joint were present. The patient was qualified for surgery that took place 6 months later. An open surgical repair method was chosen - open reposition of the right hip joint with osteotomy of femur and pelvis with immobilization with plaster cast of the hip. Three months after the surgery, rehabilitation has begun.

Conclusions
Screening of infants helped significantly reduce the incidence of late diagnosed hip dysplasia and reduced invasive methods of treatments in favor of less invasive treatments such as the wearing of orthoses. However, despite such well-developed screening tests, there are still cases of late detection of hip dysplasia.

[1397] Onyx embolization of a Cognrad IV arteriovenous fistula. A case report.

Authors: Hanna Schreiber, Theresa Margarethe Buchta, Lucy Zimmermann, Vlad Vunvulea, Dr. Lucian Mărginean
Affiliation: UMFsT Târgu Mureş / Department of Interventional Radiology
Trustee of the paper: Dr. Lucian Mărginean

Corresponding author: Hanna Schreiber (snotra1@web.de)

Background

Dural arteriovenous fistulas (dAVFs) represent approximately 10% of all cerebral vascular abnormalities. They are arteriovenous connections between a dural/epidural artery and a dural vein and/or dural venous sinus and can cause a variety of symptoms, as well as a high risk of aggressive symptoms like cerebral hemorrhage and venous infarction. An effective treatment option for dADFs is represented by endovascular embolization.

Case Report

The purpose of this paper is to show the effectiveness of OnyxTM embolization even in high flow dAVFs with a large diameter. A 45-year-old men presented to the Mures County Hospital with Jacksonian seizures and headache inflicted by a dural arteriovenous fistula. We performed a diagnostic angiography at the interventional radiology department, which highlighted a Cognard IV dAVF fed by the middle meningeal artery as well as branches of the superficial temporal artery with venous drainage provided by a cortical vein draining into the superior sagittal sinus, located at the level of the fronto-parietal lobe with venous ectasia. For the therapeutic angiography we performed bilateral approach puncturing both femoral arteries. On the right a 6F Chaperon catheter with 0.035 guide wire was used, while on the left, a VER 4F catheter was used in order to highlight the vascular anatomy. Catheterization of the middle meningeal artery's posterior branch was performed using an Apollo 1.5F microcatheter supported by a 0.010 microguide. Afterwards OnyxTM-Liquid embolic system was injected at this level until the dAVF is totally embolized. The control injection did not reveal any outstanding components of the fistula and there were no intraoperative complications.

Conclusions

Transarterial glue embolization is a feasible and effective treatment option for arteriovenous fistulas, as it stops the vessel from rupturing and allows for a quick and efficient clinical recovery.

[1399] Management of acute ischemic stroke caused by tandem occlusion, a case report

Authors: Theresa Margarethe Buchta, Hanna Schreiber, Karl Luis Schaefer, Vlad Vunvulea, Dr. Lucian Mărginean
Affiliation: UMFST Targu Mures/Interventional Radiology Department
Trustee of the paper: Dr. Lucian Mărginean

Corresponding author: Theresa Buchta (theresa.buchta@muenchen-mail.de)

Background

Internal carotid artery (ICA) dissection is a common cause of stroke in young adults. During a dissection, the layers of the arterial wall are spontaneously separated, which compromises the blood flow to certain areas of the brain. Tandem lesions define the simultaneous presence of stenosis or occlusions in the cervical segment of the internal carotid artery, and a thromboembolic occlusion of an intracranial branch. This latter occlusion mainly affects the middle cerebral artery (MCA).

Case Report

The purpose of this paper present the case of a tandem stroke with dissection of the left ICA and thrombembolism of the left MCA treated by endovascular procedure at the Interventional Radiology Department in March 2022. The 25 year old male patient presented with hemiparesis grade 1/5 MRC on side. Furthermore the patient presented with global aphasia and skew deviation of the eyes towards the lesion. Having an ASPECTS score >7 endovascular intervention was the treatment of choice. The ICA dissection was traversed and a self-expandable Wallstent 7x40mm was implanted, obtaining a complete recanalization of the cervical segment and visible flow improvement. A thrombaspiration maneuver was performed with a Sofia 6F catheter at the level of the MCA. After acquiring a red thrombus fragment and recanalization of the MCA, a filling defect was noticed in the left ACA A2 segment. Complete recanalization was achieved after two more thrombectomy maneuvers, using a stent retriever at the level of the left A2, with a final revascularization score eTICI 3. The patient had a favorable postoperative evolution, without any complications. He presented a minor frontal lobe infarction but fully recovered without further impairments.

Conclusions

Endovascular treatment is an effective and powerful alternative to classic thrombolysis for stroke patients, especially for tandem oclusion with a favorable recovery for the patient.