



Abstract Book

18th Warsaw Medical Congress

21st – 23rd April 2023
Warsaw, Poland

Congress Internet Service

Website: www.wimc.wum.edu.pl

Facebook: Warsaw International Medical Congress

Instagram: _WIMC

wimc@wum.edu.pl

Contact

The Students' Scientific Association
at Medical University of Warsaw
1a Oczki St., 02-007 Warsaw, Poland
www.stn.wum.edu.pl
stn@wum.edu.pl

Content

Strategic Partner
Honorary Patronage
Patronages
Sponsors
Organisers
Basic & Preclinical Science
Cardiology & Cardiac Surgery
Dentistry & Maxillofacial Surgery
Dermatology & Allergology
Endocrinology & Diabetes
Infectious Diseases
Internal Medicine
Laryngology, Audiology & Phoniatics
Lifestyle Medicine & Public Health
Laboratory Medicine
Neonatology
Neurology & Neurosurgery Obstetrics,
Gynecology & Perinatology Oncology
& Hematology
Online Poster
Ophthalmology
Orthopedics & Traumatology
Pediatrics
Pharmacy
PhD Basic&Preclinical Science
PhD Clinical & Health Science
Radiology
Surgery
Cardiology Case Report
Emergency Case Report
Gynecological Case Report
Internal Case Report
Neurological Case Report
Pediatric Case Report
Surgical Case Report

Strategic Partner



NOVARTIS

Honorary Patronage



MEDICAL
UNIVERSITY
OF WARSAW

His Magnificence Rector of Medical University of Warsaw
Professor Zbigniew Gaciong, MD, PhD



National Representation of Doctoral Candidates



Dean of the Faculty of Medicine

Professor Rafał Krenke, MD, PhD



WARSZAWSKI
UNIwersYTET
MEDYCZNY

—
WYDZIAŁ NAUK
O ZDROWIU

Dean of the Faculty of Health Sciences

Professor Mariusz Gujski, MD, PhD



WARSZAWSKI
UNIwersYTET
MEDYCZNY

—
WYDZIAŁ
FARMACEUTYCZNY

Dean of the Faculty of Pharmacy

Piotr Luliński, PhD

Patronages









NeuroLOGIA
PRAKTYCZNA

Sponsors



WYDAWNICTWO
CZELEJ

Wydawnictwo Czelej Sp. z o.o.

Oddział: ul. Saska 9J, 03-968 Warszawa

Sąd Rejonowy Lublin-Wschód w Lublinie z siedzibą w Świdniku

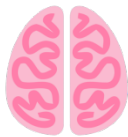VI Wydział Gospodarczy Krajowego Rejestru Sądowego KRS 0000027988

NIP: 712-24-12-888, REGON: 431091919, wysokość kapitału zakładowego: 1 542 700 zł

🌐 www.czelej.com.pl 📘 @czelej.wydawnictwo

edra
URBAN & PARTNER

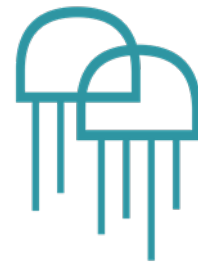WUM
.SHOP.PL



EgzaminLEK.pl



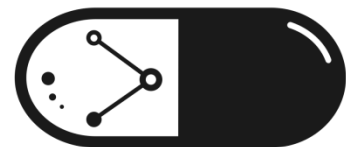
DEIN SCHLÜSSEL ZUM ERFOLG
KASTEL&GERMANY



LEPOLEK

MEDUSES

Medcases 



więcej niż LEK

Organisers

The Students' Scientific Association at Medical University of Warsaw



STN
WUM

Head of the Organizing Committee: Anna Krawczyk

President of the 18th Warsaw International Medical Congress: Mikołaj Marszałek

Scientific Programme:

Bartosz Korzeb, Jędrzej Machtyl, Szymon Lipiec, Kaja Kłopecka, Emilia

Włoszek, Magdalena Justyniarska

Workshops:

Mateusz Nawrocki, Emilia Włoszek, Weronika Skoneczna

Social Media:

Mikołaj Marszałek, Michał Kurp

Gala Dinner:

Marcin Jaworski, Emilia Piotrkowicz

Social Programme:

Agnieszka Ozdarska, Barbara Uflewski, Kaja Kłopecka

Corporate Partnerships, Fundraising:

Julia Iwoła, Anna Ziobro, Wiktor Możarowski

International Relations and Patronages:

Agata Gawęł, Hanna Piekarczyk, Weronika Skoneczna

Session Coordinators

Maciej Pawlica	Katarzyna Szawłoga
Jakub Góra	Elena Sztemberg
Katarzyna Gozdera	Oliwia Wróblewska
Jakub Zabłocki	Karolina Baracz
Maja Kłopecka	Patryk Pindłowski
Natalia Perz	Magda Skudzińska
Anna Rapiejko	Zofia Głowniak
Malwina Wojtas	Michał Koprowski
Kinga Dziobiak	Weronika Górską
Zuzanna Karczmarzyk	Paweł Tyrna
Klaudia Zielonka	Aleksandra Kowalska
Kamil Tkacz	Katarzyna Mączka
Ada Piwko	Zofia Czartoryska
Weronika Stachera	Łukasz Sęczyk
Julia Śladowska	Bulganmaa Enebish
Zofia Jędral	Aleksandra Śliwka
Magdalena Kędrak	Weronika Fortuniak
Zuzanna Warzywoda	Wiktoria Niegowska
Dorota Słupik	Monika Ryglewicz
Aleksandra Reda	Maja Kaczan
Weronika Zając	Julia Petelska
Aleksandra Kulczyk	Jakub Rochoń
Julia Sieńczyk	Karolina Kowalczyk
Natalia Rosół	Karolina Puerto Cardozo
Mateusz Ziomek	Aleksandra Serafin
Michał Cholewiński	Mateusz Kopczyński
Maria Żmijewska	Kacper Majczak
Sylwia Adamus	Julia Wiśniewska
Robert Kołaczyński	Szczepan Wąsik

Basic & Preclinical Science

Date: 21st April 2023, 10:00 AM

Coordinators:
Maciej Pawlica
Jakub Góra

Patronage:

Polskie Towarzystwo Immunologii Doświadczalnej i Klinicznej
Polskie Towarzystwo Genetyczne
Polskie Towarzystwo Biofizyczne Warszawskie Stowarzyszenie Biotechnologiczne
„Symbioza”
Narodowy Instytut Onkologiczny im
Mari Skłodowskiej-Curie - Państwowy Instytut Badawczy

[1579] **ADAR1 expression in different cancer cell lines and its change under heat shock**

Authors: Michał Fornalik, Anna Małkiewicz, Dominka Adamczak, Julia Pestka

Affiliation: Poznań University of Medical Sciences, Department of Biochemistry and Molecular Biology

Trustee of the paper: Michał Fornalik

Corresponding author: Michał Fornalik (michalfornalik.contact@gmail.com)

Introduction

The RNA-editing enzyme ADAR1 is responsible for the adenosine-to-inosine posttranscriptional modifications and inhibition of IFN-mediated apoptosis and the response to cellular stress factors. All activities of this protein affect the regulation of gene expression, including those involved in cell cycle regulation, cell division, and apoptosis. Multiple studies have reported its role in cancer. High expression of ADAR1 is associated with poorer survival of oncological patients. The aim of the study was to assess the differences in ADAR1 expression among various cancer cell lines and check whether it changes under cellular stress factors such as heat shock.

Aim of the study

To assess ADAR1 expression among different cancer cell lines and its change during heat shock

Materials and methods

Cell culture was performed, and baseline ADAR1 expression was assessed in various tumor lines using RT-qPCR and Western-Blot. The change in expression under heat shock was evaluated in A549 and Calu-1 cell lines using the same methods.

Results

The study has shown significant differences in ADAR1 expression among different cancer cell lines, with the highest mRNA expression in HCT116 and the lowest in HGC, while the highest protein expression in MCF-7 and the lowest in HGC. There was no statistical significance in the change of the ADAR1 expression under heat shock in both mRNA and protein levels.

Conclusions

ADAR1 is expressed differently among various cancer cell lines, and heat shock does not alter its expression. However, more extensive studies are required to assess whether the expression is tissue conservative and if other stress factors may influence its level in the cell.

[1611] Effects of chronic alcohol use on the glial cells and neurons in the striatum of human brain

Authors: Annija Kliemane

Affiliation: Rīga Stradiņš University, Latvia

Trustee of the paper: Sandra Skuja, PhD

Corresponding author: Annija Kliemane (annija74@gmail.com)

Introduction

Astrocytes and microglia are important in the central nervous system (CNS) for maintaining a balanced environment for the neurons. It is known that alcohol consumption leads to alterations in CNS homeostasis. In the striatum, the glial cell interaction and response to alcohol are not fully understood.

Aim of the study

The aim of the study was to evaluate the interplay between glial cells and neurons in striatal grey (GM) and white matter (WM), evaluating both the diffuse and perivascular location of microglial cells, and their relationship with the number of neurons. We evaluated the expression of nuclear factor kappa B (NFκB) likely involved in the immune and inflammatory responses to alcohol consumption.

Materials and methods

The study included 36 striatal autopsies, which were divided in control, young alcohol (YA), and chronic alcohol (CA) users' groups. Anti-Iba-1 and anti-GFAP antibodies were used to detect microglia and astrocytes, respectively, and an NFκB antibody was used to assess NFκB activity. IBM SPSS 27.0 and GraphPad Prism 9 were used for statistical analysis.

Results

More diffuse Iba-1-positive (Iba-1+) cells were observed in the WM of the CA and YA groups compared to controls ($p < 0.001$, $p < 0.05$). More GFAP-positive (GFAP+) astrocytes were found in the WM of the CA group in comparison with the GM and WM of other groups ($p < 0.001$). In controls, negative correlations were found between a number of neurons and both GFAP+ astrocytes ($r = -0.581$; $p < 0.001$) and diffuse Iba1+ cells ($r = -0.469$; $p < 0.001$). In YA group, similar correlation was only between neurons and astrocytes ($r = -0.613$; $p < 0.001$), but in the CA group, a negative correlation was found between neuron count and diffuse microglia ($r = -0.336$; $p < 0.001$). In comparison to the CA group's GM, in the YA group and controls, a significant part of the GM was immune-negative to anti-NFκB ($p < 0.001$). In the YA group and controls, there was negative NFκB immunoreactivity in the GM in comparison to the CA group ($p < 0.001$). The most intense NFκB activity was noticed in the WM of the CA group when compared to other groups' WM and GM immunostaining ($p < 0.001$).

Conclusions

Different correlations between glial cell types and neurons in each group suggest differences in the ability of healthy and alcohol-dependent striatal cells to synchronize and adapt to toxicity. The increased activity of NFκB, a larger number of astrocytes and microglial cells in the WM of the CA group than in the YA group and controls suggest striatal WM sensitivity to long-term alcohol use.

[1637] EVALUATING AN ENZYMATIC PROTECTION OF NIGRAL NEURONS IN CHRONIC ALCOHOLISM CONDITIONS

Authors: Anita Ilze Gulbe

Affiliation: Rīga Stradiņš University, Latvia

Trustee of the paper: Sandra Skuja, PhD

Corresponding author: Anita Ilze Gulbe (gulbe.anita.ilze@gmail.com)

Introduction

Chronic alcoholism is a severe and disabling disorder, that can be associated with a variety of medical sequelae. Each year 3 million deaths occur from harmful use of it. One of the two subregions in the substantia nigra (SN) is pars compacta (SNpc), which contains densely packed dopaminergic neurons that convey neuronal signalling to the striatum. Superoxide dismutase (SOD-1) is an enzyme that protects the cell from reactive oxygen species (ROS) toxicity. It is known that chronic alcohol use is linked to an increase in ROS, thus altering brain activity, neuronal content, and quantity, but the effect on the SNpc neurons remains to be identified.

Aim of the study

To analyse the presence and distribution of SOD1 in SNpc neurons.

Materials and methods

Brain autopsy samples (SNpc) from the Latvian State Centre of Forensic Medical Examination were included in control (n=10), age-matched alcohol users (n=12), and chronic alcohol users' groups (n=17). Immunohistochemical staining by the anti-SOD-1 antibody was evaluated by counting both total and positive cells as well as the intensity of SOD-1 in neuronal cytoplasm (1 - low, 2 – medium, and 3 – high-intensity coloration) in 10 randomized visual fields per area. The IBM SPSS 28.0 program was used for statistical data analysis.

Results

Compared to controls, age-matched and chronic alcohol users demonstrated a notable decline in neurons per visual field ($p < 0.001$), but also a comparative rise in the number of SOD-1 positive cells ($p < 0.001$). When compared with controls, both the young and chronic alcoholic groups had a statistically significant increase in SOD-1 intensity in neurons ($p < 0.001$). In the young alcoholic group, there were correlations between SOD-1 positive neurons and medium and high SOD-1 intensity in them ($r = 0.476$, $p < 0.001$ and $r = 0.388$, $p < 0.001$, respectively), but a negative correlation for low-intensity coloration ($r = -0.317$, $p < 0.001$). Overall, a statistically significant correlation between SOD-1 positive cells and medium-intensity coloration was found in the chronic alcoholic group ($r = 0.447$, $p < 0.001$).

Conclusions

Alcohol consumption correlates with an elevated number of SOD-1 positive neurons and increased intensity of enzyme depositions, but also a decrease in the overall number of neurons. Altered SOD-1 expression could be more of an early sign than a toxic agent, suggesting reduced antioxidant capacity in neurons and indicating cell damage.

[1638] IMMUNOPHENOTYPICAL CHARACTERIZATION OF KUPFFER CELLS IN THE CHANGED LIVER MICROENVIRONMENT

Authors: Anita Ilze Gulbe

Affiliation: Rīga Stradiņš University, Latvia

Trustee of the paper: Sandra Skuja, PhD

Corresponding author: Anita Ilze Gulbe (gulbe.anita.ilze@gmail.com)

Introduction

More than 90% of consumed alcohol is metabolized by the liver. Chronic alcohol consumption can activate immune response-related hepatic macrophages that are fundamental for maintaining tissue homeostasis. Resident macrophages in the liver display immense plasticity. Kupffer cells are a powerful component of both liver injury and repair – found at the luminal side of the sinusoidal endothelium, with a slightly higher density around the portal vein than in the central vein regions. These cells play a crucial role in providing a prompt response to hepatic tissue injury and can show phagocytic properties.

Aim of the study

To analyse Kupffer cell subtypes and their distribution in different liver tissue areas in chronic alcoholism conditions.

Materials and methods

Hepatic autopsy samples from the Latvian State Centre for Forensic Medical Examination were collected. CD68+ and Iba-1+ cells in the lobular, portal, and central vein areas of the postmortem liver tissue of controls (n=11), age-matched alcohol users (n=15) and chronic alcohol users (n=30) were investigated using immunohistochemistry (IHC) and relevant antibodies. IHC staining results were analysed quantitatively by a light microscope using ×400 magnification. The samples were evaluated by counting positively stained cells in 5 randomised visual fields per area. The IBM SPSS 28.0 program was used for statistical data analysis.

Results

Compared to controls, chronic alcohol users demonstrated a highly significant rise in both CD68+ and Iba-1+ cell count in all hepatic areas ($p < 0.001$). Overall, statistically significant correlations between Iba-1+ and CD68+ cells were found in the central vein and lobular areas of all groups (controls $r = 0.272$, $p = 0.049$ and $r = 0.405$, $p = 0.003$; age-matched alcohol users $r = 0.268$, $p = 0.032$ and $r = 0.528$, $p < 0.001$; chronic alcohol users $r = 0.384$, $p < 0.001$ and $r = 0.399$, $p < 0.001$, respectively). Correlations between both Kupffer cell subtypes in the portal region were only found in age-matched and chronic alcohol user groups (age-matched alcohol users $r = 0.580$, $p < 0.001$; chronic alcohol users $r = 0.404$, $p < 0.001$, respectively).

Conclusions

Increased numbers of Iba-1+ cells in the lobular, portal, and central vein areas of liver tissue could be associated with an earlier indication of an active immune response, in the chronic alcohol users' group. Overall, increased Iba-1+ and CD68+ cell expression in the portal region of age-matched and chronic alcohol users could be a considerable risk factor responsible for the development of fibrosis.

[1659] Understanding the role and molecular mechanisms of ferroptosis in human T cells

Authors: Natalia Leśniowska 1,2,3, Marta Kłopotowska 2, Anna Jurga 2,3, Małgorzata Bajor 2

Affiliation: (1) Faculty of Biology and Biotechnology, Warsaw University of Life Sciences, (2) Laboratory of Immunology, Mossakowski Medical Research Institute Polish Academy of Sciences, (3) Immunooncology Students' Science Association MUW

Trustee of the paper: Małgorzata Bajor PhD

Corresponding author: Natalia Leśniowska (s200129@sggw.edu.pl)

Introduction

Ferroptosis is a form of regulated cell death resulting from iron-dependent excessive peroxidation of membrane lipids. Recently, extensive research has been done regarding the use of ferroptosis as a promising treatment strategy for cancer patients. However, it is important to consider how such treatment might affect immune cells present in the tumor microenvironment (TME). Moreover, oxidative stress, inflammation and nutrient deficiencies, all hallmarks of the TME, predispose immune cells to undergo ferroptosis, thus leading to the loss of their cytotoxic capacity following tumor progression. Therefore, the study of ferroptotic cell death in an immune context might be key to developing new or improving current therapeutic approaches.

Aim of the study

The aim of this study was to evaluate the sensitivity of human T cells to ferroptosis-inducing compounds and assess the level of characteristic markers and regulators of this cell death modality.

Materials and methods

CD3+ T cells were isolated from peripheral blood mononuclear cells (PBMC) and stimulated or not with anti-CD3/CD28 antibodies and interleukin 2. The sensitivity of human T cells to ferroptosis-inducing compounds such as RSL3 and ML162 in the subsequent weeks of cell culture was determined by flow cytometry. Liproxstatin 1 (LIP-1), a selective inhibitor of ferroptosis, was used to verify the specificity of cell death. In addition, markers representing ferroptosis, including the production of reactive oxygen species (ROS), the level of membrane lipid peroxidation and labile iron pool (LIP) were assessed using specific fluorescence probes and analyzed by flow cytometry. The levels of characteristic ferroptosis regulators ACSL4 and GPX4 were determined by Western blotting.

Results

The study showed that over time, stimulated T cells became more sensitive to ferroptosis inducers, and the observed decrease in cell viability was significantly reversed by LIP-1 treatment. Moreover, stimulated T cells compared to unstimulated ones were characterized by increased levels of intracellular ROS, lipid peroxidation and labile iron pool. Additionally, elevated levels of ACSL4 protein and decreased GPX4 were observed in stimulated T cells.

Conclusions

T cells can undergo ferroptosis and over time become sensitive to ferroptosis-inducing compounds as reflected in changes in characteristic markers of this cell death. Our studies indicate that induction of ferroptosis as anticancer strategy might affect T cells and potentially T cell-based immunotherapies.

[1663] KL3 - new, better alternative to podophyllotoxin?

Authors: Piotr Strus, Julia Kostro, Karol Sadowski, Izabela Młynarczuk-Biały

Affiliation: The Department of Histology and Embryology, Medical University of Warsaw

Trustee of the paper: Izabela Młynarczuk-Biały

Corresponding author: Julia Maria Kostro (julikostro00@gmail.com)

Introduction

Podophyllotoxin (PPT) is a cell proliferation inhibitor used to treat anogenital warts (HPV infection). PPT leads to cell cycle arrest by stabilizing microtubules and stopping replication of cellular DNA. It can be applied only topically because of adverse effects. In search of safer drugs, the structure of PPT is modified to create novel podophyllotoxin derivatives.

Aim of the study

We studied PPT and its derivative KL3, synthesized in cooperation with the University of Warsaw. In the past, we have shown that KL3 is more effective against cancer cells *in vitro* and less toxic to healthy cells than PPT. In this research we further checked the safety, effectiveness and mechanisms of KL3 and PPT.

Materials and methods

Our research was conducted on the human keratinocyte line (HaCaT). We tested them with PPT (Sigma Aldrich) and KL3. We assessed the cell viability (PrestoBlue Assay) in 6 different concentrations: 0,25; 0,5; 1; 2,5; 5 and 25 μ M. We used two kinds of microscopy to observe cells treated with PPT and KL3. In electron microscopy we analyzed features of the processes, ER, mitochondria and Golgi apparatus after 24 and 48h. In confocal microscopy we studied the process of entering each compound with attached fluorescein into the cell after: 5; 10; 30; 60; 90; 120; 180; 240; 360min and 24h. The toxicity, number and size of organelles and vesicles were compared by One-way ANOVA test in PRISM and ImageJ.

Results

PPT and KL3 both induce time-dependant cytotoxic/cytostatic effect. KL3 was less toxic than PPT in 0,25; 0,5 and 1 μ M concentrations, at higher there were no differences. Electron microscopy shows dose-dependant changes in cellular morphology. The changes were more advanced in PPT-treated cells - we observed irreversible vacuolization of the cytoplasm and disintegration of cell membrane. 24h treatment with 1 μ M KL3 induced transient ER stress, mitochondrial swelling and elongation of cytoplasmic processes. After 48h most of those changes disappeared, autophagy started and cells remained alive. Confocal microscopy proved that both compounds entered the cells as endocytic vesicles before the fifth minute.

Conclusions

Based on our previous research, we knew that *in vitro* KL3 is more effective in killing cancer cells and less toxic to non-tumorigenic cells. Our present study supports that conclusion. Additionally, most KL3 changes are reversible in contrast to PPT. Finally, we confirmed that both compounds enter the cell equally effectively. Therefore it may suggest that KL-3 is a potential alternative to PPT.

[1701] Chimeric antigen receptor expressing macrophages interact with natural killer (NK) cells to increase tumor killing

Authors: Attila Tibor Gerencsér, Péter Áron Tóth, Zsuzsanna Polgár, Endre Kókai, László Virág

Affiliation: Department of Medical Chemistry, Faculty of Medicine, University of Debrecen, Debrecen, Hungary

Trustee of the paper: Endre Kókai

Corresponding author: Attila Tibor Gerencsér (drgerati@gmail.com)

Introduction

The development of cell therapy has opened new horizons in the treatment of cancer. Chimeric antigen receptor T-cell (CAR-T) therapy is already available for the treatment of some types of leukemia but has proven ineffective against solid tumors. CAR-expressing macrophages (CAR-M), however, may have the potential to fight solid tumors. CARs consist of an extracellular antigen-binding domain, an intracellular effector domain and a transmembrane domain. Through their chimeric antigen receptors, CAR-Ms can recognize tumor-specific antigens, triggering the activation of signaling pathways leading to increased anti-tumor immune cell activity through elevated cytokine production. To model this, HER2-recognizing CAR-M cells were co-incubated with NK cells and HER2-expressing JIMT-1 breast tumor cells. In this project, we expressed CARs in monocyte-derived THP1 cells whose intracellular domains induce M1 (“inflammatory”) differentiation.

Aim of the study

Our aim was to demonstrate the ability of CAR-M cells to enhance the tumor killing ability of NK cells.

Materials and methods

Transduced, CAR-expressing THP-1 cells were differentiated with phorbol 12-myristate 13-acetate (PMA) and activated with lipopolysaccharide (LPS) to induce an M1 polarized macrophage phenotype. To verify the effect of CARs, we examined the changes in the levels of M1 polarization marker IL-1 β produced by macrophages in response to co-incubation with JIMT-1 cells. Activated CAR-M cells were co-cultured with NK-cells and mCherry-expressing JIMT-1 tumor cells. Tumor cell death count was measured using high-content analysis (HCA).

Results

CAR-M cells showed elevated IL-1 β cytokine production compared to control un-transduced macrophages after 4 hours of co-incubation with JIMT-1 cells. CAR-M – NK cell co-cultures showed significantly decreased tumor cell count compared to control NK cells after 96 hours.

Conclusions

Our results showed that CAR-s are effective in polarizing differentiated macrophages in the M1 direction and CAR-Ms increase the tumor killing potential of NK cells.

Support: NTP-SZKOLL-22-0063

[1724] **The attempt to reconstruct the bladder wall and a three-dimensional urinary bladder tumor**

Authors: Karolina Ławkowska, Tomasz Kloskowski, Marta Pokrywczyńska

Affiliation: Collegium Medium im. Ludwika Rydygiera w Bydgoszczy Uniwersytetu Mikołaj Kopernika w Toruniu, Katedra Urologii i Andrologii, Zakład Medycyny Regeneracyjnej

Trustee of the paper: Tomasz Kloskowski

Corresponding author: Karolina Ławkowska (karolinalawkowskaa@gmail.com)

Introduction

In cancer research, re-creating the tumor microenvironment, including cell-cell adhesion, and cellular communication, is critical. Conventional two-dimensional (2D) cell culture and animal models have been shown to be useful in explaining malignant cell behavior and assessing theories of potential causes. However, conventional 2D culture systems cannot replicate the complexity, diversity and dynamic nature of the tumor microenvironment. Cancer cells spheroids are an increasingly used model for drug screening and studies of tumor growth and proliferation, studies of invasion, matrix remodeling, and angiogenesis. Spheroids mimic cell-cell and cell-matrix interactions, as well as transport features, between tumor cells and the microenvironment. Spheroids also exhibit tumor-like growth gradients and zones. Because of these features, tumor cell protein and gene expression profiles in spheroids are substantially more similar to clinical and in vivo gene expression profiles than those in 2D culture.

Aim of the study

Aim of the study is to recreate a hybrid of cancer cells spheroids with the microenvironment of the bladder wall reconstructed using tissue engineering techniques is an in vitro model that provide controlled microenvironments to study cancer progression.

Materials and methods

In the study, we reconstructed the bladder wall using SV40LT-SMC cells (normal smooth muscle) and SV-HUC-1 (normal urothelial epithelium), to which we included HTB-9 and T-24 invasive bladder cancer cells, cultured as compact spheroids, placed on a previously prepared bladder wall model. To confirm the effectiveness of reconstructing the artificial tumor microenvironment, an immunocytochemical analysis was performed applying antibodies against type I collagen, alpha-myosin, and pancytokeratin.

Results

As analyses shown our (three-dimensional) 3D model is characterized by a multi-layer structure of the bladder wall with visible anchored spheroids of cancer cells.

Conclusions

Our 3D model could be used as a reliable model to assess drug response, potentially reducing or partially replacing animal experiments, and therefore should find application in identifying the effectiveness of new drugs as well as in the toxicological evaluation of anti-cancer therapies.

Moreover, application of patient derived tumor cells can enable the progress of personalized medicine. This would allow for the identification of different phenotypes as well as vulnerability to anti-cancer medications and molecularly targeted cancer therapy.

[1733] Knockout of lncRNA-CCAT1 with the use of CRISPR-Cas9 system and G7 PAMAM dendrimers influences apoptosis and proliferations of NSCLC cells.

Authors: Konrad Wróbel¹, Konrad Kwaśniak², Joanna Olszewska², Mateusz Iwański¹, Anna Głowacka¹, Stanisław Wołowicz³, Jacek Tabarkiewicz^{2,4}

Affiliation: College for Medical Sciences of University of Rzeszow, Poland.

Trustee of the paper: My paper is original work

Corresponding author: Konrad Michał Wróbel (konradwrobel300@gmail.com)

Introduction

Colon cancer-associated transcript 1 (CCAT-1) is an oncogenic lncRNA that has been emerged as a vital biomarker for diagnosis, prognosis and therapeutic interventions in multiple malignancies. The previous studies showed that lncRNA-CCAT1 was upregulated in NSCLC cells and its expression was related to tumor growth and reduced survival rate. Utilization of PAMAM (polyaminoamide) dendrimers as macromolecular system for drug and gene delivery is one of extensively investigated strategies nowadays. Terminal amine groups of PAMAM may be replaced with OH, COOH, and others functional groups. They can be functionalized by covalent attachment of drugs, polyols or targeting molecules.

Aim of the study

The aim of our study was to evaluate influence of the knockout of lncRNA-CCAT1 with the use of CRISPR-Cas9 system and G7 PAMAM dendrimer on apoptosis and proliferations of NSCLC cells.

Materials and methods

We used two human lung adenocarcinoma cell lines: A549, H1975 and H1703 squamous cell carcinoma cell line. The knockout of the lncCCAT expression was performed using the CRISPR-Cas9 system and G7 PAMAM dendrimer. G7 was derivatized by reaction with R-glycidol in methanol. The product of the reaction was characterized by NMR spectroscopy (¹H, ¹³C, 2-D). We used 4 combinations of gRNAs. The apoptosis of NSCLC after lncRNA-CCAT1 knockout was estimated with the use of flow cytometry and Annexin V staining, evaluation of caspase-3/7 and measurement of mitochondrial membrane potential changes. Expression of Ki67 was measured by flow cytometry to evaluate NSCLC cells proliferation. All mentioned above parameters were evaluated 24, 48 and 72 hours after transfection. Nonparametric ANOVA tests was used for statistical analysis.

Results

We found that transfection with conjugates of G7 PAMAM dendrimers and px459 v2.0, the appropriate gRNAs, and pcDNA3.1 plasmid are downregulating expression of lncRNA-CCAT1. We confirmed that apoptosis of NSCLC was increased after transfection and cells proliferation was reduced. We also found differences in timing and intensity of biological effects when different combination of gRNAs are used in particular NSCLC cell lines.

Conclusions

The complexes of R-glycidylated G7 PAMAM dendrimer and the appropriate gRNAs, and pcDNA3.1 plasmid can be used for knockout of the expression of lncRNA-CCAT1. On the other hand the gRNAs shall be individually chosen for particular NSCLC cells according to their genetic mutation status.

[1753] Enalapril reduces diabetes-associated changes in gut morphology, SCFA levels and intestinal RAS in rats.

Authors: Wojciech Kopacz, Kinga Jaworska, Mateusz Koper, Mateusz Szudzik, Marcin Ufnal

Affiliation: Department of Experimental Physiology and Pathophysiology, Medical University of Warsaw, Pawinskiego 3c Street, 02-106 Warsaw, Poland

Trustee of the paper: Kinga Jaworska

Corresponding author: Wojciech Kopacz (wojtekkop1@gmail.com)

Introduction

Growing evidence suggests the microbiota-derived metabolites including trimethylamine-oxide (TMAO) and short chain fatty acids (SCFAs) may affect the course of diabetic multiorgan pathology. We hypothesized that diabetes disrupts intestinal renin-angiotensin systems (RASs), which contributes to intestinal pathology and increases plasma level of bacterial metabolites.

Aim of the study

To evaluate the changes in intestinal RAS, Intestinal Morphology and bacterial metabolites Concentration Associated with Diabetes as well as the therapeutic potential of Enalapril in diabetes-induced Intestinal pathology.

Materials and methods

12-week-old rats were divided into three groups: controls, diabetic (streptozotocin-induced) and diabetic treated with enalapril, an ACE-I. Histological examination and RT-qPCR were performed to evaluate morphology and the expression of RAS in jejunum and colon, respectively. TMAO and SCFAs levels in stools, portal and systemic blood were evaluated with HPLC-MS.

Results

Diabetic rats showed hyperplasia and hypertrophy of mucous membrane in jejunum, increased height and cellularity of the colonic mucosa, significantly higher SCFAs blood concentration, and slightly increased TMAO levels in comparison to controls. The size of the diabetes-associated changes was smaller in enalapril treated rats. In comparison to controls, diabetic rats had lower expression of MAS receptor and angiotensinogen in jejunum while in the colon the expression of MAS and renin was higher in diabetic rats. Enalapril-treated animals had lower expression of MAS in colon. AT1a, AT1b, and AT2 receptors expressions were similar between groups.

Conclusions

In conclusion, diabetes in rats induces pronounced morphological changes in intestines, increases plasma concentration of SCFAs, and alters the expression of renin and MAS receptors. These alterations are reduced in enalapril-treated diabetic rats. Further research is needed to better understand the clinical significance and the mechanisms behind intestinal pathology in diabetes.

[1771] The impact of protein arginine methyltransferase 5 mutations on carcinogenesis

Authors: Mihály Székely; Attila Makai; Ilka Keller; Dániel Horváth; Evelin Major; Ádám Ungvári; Klaudia Tóth; Beáta Lontay

Affiliation: University of Debrecen, Faculty of Medicine, Department of Medical Chemistry

Trustee of the paper: Mihály Székely

Corresponding author: Mihály Székely (mihaly.szekely2@gmail.com)

Introduction

Over- and under-activation of enzymes responsible for maintaining the cell cycle and gene expression is a major cause of tumor development and can be triggered by mutations and abnormal post-translational modifications. The protein arginine methyltransferase 5 (PRMT5) catalyzes the symmetric arginine dimethylation of histone proteins, resulting in the inhibition of gene expression. It is regulated by RhoA-activated kinase (ROK) and myosin phosphatase (MP) via the Thr80 phosphorylation of its MYPT regulatory subunit. Mutations in the Thr80 regulatory side chain of PRMT5 have been identified in several tumor types using the COSMIC database.

Aim of the study

The aim of our studies is to investigate the effect of mutations in PRMT5 Thr80 biochemically.

Materials and methods

We transfected tsA201 cells with a plasmid encoding Flag-tagged wild-type and mutant PRMT5 and purified them by Flag affinity chromatography. By mass spectrometry analysis, a new phosphorylation site, PRMT5 Ser74, was described for PRMT5 Thr80 mutant proteins under ROK treatment compared to wild-type PRMT5 enzyme. To investigate the effect of PRMT5 Thr80 mutations on enzyme activity, overexpressed proteins were bound to affinity gels. In vitro ROK kinase assay was conducted on the immobilized PRMT5 and then examined for phosphorylation by Western blotting.

Results

While WT PRMT5 showed no increase in the phosphorylation of Ser amino acid residues upon ROK treatment, an increase was detected in Thr80 mutants. The mutant PRMT5 showed clear PRMT5 Ser phosphorylation by in vitro ROK enzyme activity assay, which was reduced by the addition of MP. We analyzed the amount of histone substrates bound by WT and mutant PRMT5 proteins and found that ROK induced mutant PRMT5 to bind significantly more histone substrates, which was not altered by further phosphorylation. We validated our results with a liver carcinoma tissue array and other tumor cell lines using an anti phospho-Ser74 antibody and observed a grade- and status-dependent correlation in the phosphorylation of tissue samples.

Conclusions

Our data suggest that mutations in tumors may regulate the increased activity of PRMT5 by the amount of substrate bound by the enzyme and that this may result from spatial structural changes and exposure to new activating phosphorylation sites caused by the mutations.

Supported by: NTP-HHTDK-22-0051

[1780] Downregulated UPR pathway and iNOS overexpression as a link between obesity and aggravated post-myocardial infarction heart failure

Authors: Jakub Tomaszewski, Karol Momot, Katarzyna Czarzasta, Małgorzata Wojciechowska, Liana Puchalska

Affiliation: Medical University of Warsaw / Chair and Department of Experimental and Clinical Physiology, Laboratory of Centre for Preclinical Research

Trustee of the paper: Katarzyna Czarzasta, Małgorzata Wojciechowska, Liana Puchalska

Corresponding author: Jakub Tomaszewski (j.p.tomaszewski19@gmail.com)

Introduction

The consumption of "energy-dense" products is continuously growing worldwide. Dietary fat overload promotes cardiac remodeling leading to unfavorable outcomes after myocardial infarction (MI). Recent studies on an animal model unveiled the critical role of nitrosative stress (NS) in the development of heart failure (HF) with preserved ejection fraction. It consists of two important elements: the overexpression of inducible nitric oxide synthase (iNOS) and the inefficient unfolded protein response (UPR) pathway – particularly the XBP1s-IRE1 α branch.

We examined the impact of high fat diet (HFD) on the myocardial NS after MI-HF.

Aim of the study

To find the link between HFD and NS -iNOS overexpression- and inhibition of IRE1 α -XBP1s branch of UPR pathway.

Materials and methods

We performed the study on 29 male adult Sprague Dawley rats. We assigned them to groups and fed them for 8 weeks with normal diet (NFD) and HFD. Then, on the 12th week of age, we performed surgical procedures: evoking of MI (HF NFD, HF HFD) and sham operation (SO NFD, SO HFD). 4 weeks past the procedures, we sacrificed the animals, collected heart tissue and blood for further analysis. NT-proBNP concentration in blood was measured using ELISA assay to confirm the HF development. We performed Western blot to evaluate the levels of the following proteins in the heart tissue: IRE1 α , phosphorylated IRE1 α (pIRE1 α), iNOS and β -actin as a control.

Results

Both HF HFD and HF NFD groups developed post-MI HF according to higher plasma NT-proBNP concentration compared to control groups (SO HFD/NFD).

The HF HFD group presented the highest expression of iNOS of all the groups, significantly higher when compared to the control (SO NFD). The results correspondence to the development of NS in this group. Our data imply that the combination of HFD and MI generates the most severe MI-HF compared to isolated HFD and MI.

The ratio of pIRE1 α to IRE1 α represents the activity of the UPR pathway. The IRE1 α activity was downregulated in HF-HFD, but not in the HF-NFD. The data suggest that HFD significantly downregulates the UPR pathway after MI-HF.

Conclusions

Our findings suggest that MI increases NS and downregulates the UPR pathway in HFD rats, but not NFD. Therefore, it can be implied that patients after MI should be highly restricted from high-fat products to prevent inducing NS and impairing UPR. This is a new perspective in future studies – the NS and UPR pathway as a therapeutical target in HF development.

[1807] Morphologic Analysis of Normal Human Lumbar Dorsal Root Ganglion- a story about biganglia, and where to find them?

Authors: M. Misiak 1,2

Affiliation: 1 Faculty of Medicine, Collegium Medicum, Cardinal Stefan Wyszyński University in Warsaw; 2 Department of Descriptive and Clinical Anatomy- Center for Biostructure Research (Student's Scientific Circle), Medical University of Warsaw

Trustee of the paper: misiak.m2022@gmail.com

Corresponding author: Marek Misiak (vincent200mr@gmail.com)

Introduction

Dorsal root ganglia (DRG), have increasingly been considered novel targets for clinical neural interfaces, both for neuroprosthetic and pain applications. Effective use of either neural recording or stimulation technologies requires appropriate spatial position relative to the target neural element, whether axon or cell body. However, the internal three-dimensional spatial organization of human DRG neural fibers and somata has not been described. The DRG of the spinal nerve has been also considered a key structure in understanding mechanisms of many diseases like low-back pain, and sciatica.

Aim of the study

The purpose of this study was to clarify the normal morphologic features and variations of the lumbar DRGs in a healthy population.

Materials and methods

In this study, microanatomic dissections of the lumbar nerves were performed in 5 embalmed human cadavers. We analyzed morphologically dorsal root ganglia of human cadavers focusing mostly on L3, L4 and L5 DRG. Dissections were performed using a Zeiss surgical microscope.

Results

The L1 and L5 DRGs were dissected bilaterally. The architecture of DRGs was classified into 3 types according to their composition as singular ganglion, biganglia, and triganglia. The majority of DRG could be defined as monoganglia. Biganglia were identified in L3 and L4 or L5, whereas the singular ganglion, was in the L5 and L1 DRGs. They were separated by distinct connective tissue layers.

Conclusions

Our data show the presence of biganglia in human lower lumbar DRG, supporting the findings of (Shen et al. 2006). It is currently unclear if the presence of bi- or triganglia would affect the accurate delivery of electrical stimulation to DRG neurons, or if the separate ganglia are functionally distinct. We can speculate that connective tissue between multi-ganglia, could affect the DRG's current spread. Future studies should explore the existence of functionally-distinct biganglia, which may be important for electrode placement for DRG stimulation.

[1812] Investigation of globotriaosylceramide accumulation in circulating T cells of Fabry patients

Authors: Luca Kamilla Li

Affiliation: Semmelweis University Department of Pediatrics Tűzoltó utcai Unit

Trustee of the paper: Árpád Ferenc Kovács, MD, PhD

Corresponding author: Luca Kamilla Li (lilucakamilla17@gmail.com)

Introduction

Fabry disease is the most common lysosomal storage disorder being caused by pathogenic variants in the GLA gene. Due to the pathogenic variants insufficient/reduced function of alpha-galactosidase (AGAL) can be observed, resulting in accumulation of globotriaosyl-ceramide (Gb3) substrate. A chronic, subclinical inflammation can be seen in Fabry patients.

Aim of the study

Development of a new diagnostic assay suitable for assessment of Gb3 substrate accumulation in the circulating T cells of Fabry patients.

Materials and methods

In the circulating peripheral immune cells of Fabry patients (N=15) and healthy controls (N=10) followed up and treated at Semmelweis University Department of Pediatrics Tűzoltó utcai Unit, we determined the Gb3 substrate accumulation on the cell surface and intracellularly with flow cytometer. The inflammatory C-reactive protein, ferritin and lyso-Gb3 biomarker parameters were also correlated. To further develop the assay, we designed sgRNA guides targeting exon 2 of alpha-galactosidase (GLA) gene, and then transfected Jurkat T cells with CRISPR-Cas9-based nucleofection.

Results

In Fabry patients, we detected a significantly increased scale of plasma membrane Gb3 positive CD19+ B-cells, CD3+CD4+ T-cells, and CD3+CD8+ T-cells compared to the control group. In Fabry patients, who receive enzyme replacement therapy, intracellular Gb3 accumulation showed a decreasing trend in CD3+CD4+ T cells and CD3+CD8+ T cells. Jurkat cells showed 95% viability after transfection, transfection efficiency was 46.41%.

Conclusions

We developed a method suitable for measuring substrate specific accumulation at the single-cell level in T cells of Fabry patients. A GLA gene knockout (Jurkat GLA KO) cell line to fine tune the method was generated.

[1894] Development of an innovative method of preparing iPSC cells for gene-cell therapy of hereditary diseases based on the Osteogenesis imperfecta model

Authors: Jagoda Hofman, Michał Hutny

Affiliation: Medical University of Silesia, Department of Medical Genetics

Trustee of the paper: Karolina Bajdak-Rusinek, Agnieszka Fus-Kujawa

Corresponding author: Jagoda Maria Hofman (jagoda.hofman98@gmail.com)

Introduction

The viral vectors have been widely used in genetic engineering in the last decades, despite safety concerns, such as their mutagenicity and severe inflammatory response. With the increasing possibilities of using gene therapy in various fields of medicine, the need to create new, safer carrier solutions is becoming an important issue in biomedical sciences.

Aim of the study

The aim of the study was to evaluate effectiveness of a novel carrier in inducing gene repair in induced pluripotent stem cells obtained from human skin fibroblasts, where mutation in COL1A1 gene was identified.

Materials and methods

Human skin fibroblasts were obtained from patients with Osteogenesis imperfecta type II and further reprogrammed into iPSC using Thomson factors (Oct3/4, Sox2, Lin28, Nanog), which were introduced to the fibroblasts in the form of proteins. Pluripotent cells were selected by the single cell colony method. Pluripotency was assessed by flow cytometry analysis of pluripotency markers SSEA-4 and Tra-1-81. The star-like polymer was used as carrier of genetic material and introduced to the cell in order to repair the deleterious mutation in COL1A1 gene in obtained iPSC.

Results

Fibroblasts were successfully reprogrammed. Small cell clusters were visible 5 days after reprogramming, showing typical pluripotent cell morphology. They were also successfully differentiated into mesenchymal stem cells. The mutation (del TGGTGCTCC g:18047-18055) in COL1A1 gene was corrected using the star-like polymer as a carrier of genetic material.

Conclusions

Non-viral carrier with star-like structure successfully repaired mutation in the COL1A1 gene of the obtained iPSCs, suggesting their potential for gene-cell therapy of congenital diseases. This research was funded by the Polish National Science Center under contract no. 2020/37/N/NZ2/01125.

[1905] Effects of danicamtiv, a novel myosin activator on the contractility and Ca²⁺ transients of isolated canine left ventricular cardiomyocytes

Authors: Dávid Pásztor, Zoltán Papp, Fruzsina Sárkány

Affiliation: Division of Clinical Physiology, Department of Cardiology, Faculty of Medicine, University of Debrecen, 4032 Debrecen, Hungary

Trustee of the paper: Fruzsina Sárkány

Corresponding author: Dávid Pásztor (davidka999@gmail.com)

Introduction

Advanced stage systolic heart failure (HFrEF) remains a disease with a very poor prognosis. Its treatment is based on improving cardiac systolic dysfunction and myocardial contractility. Our current research has focused on a new pharmacological agent, danicamtiv directly influencing the cross-bridge cycle.

Aim of the study

To study the effects of danicamtiv on the contractility and Ca²⁺ transients in isolated left ventricular cardiomyocytes.

Materials and methods

The effects of danicamtiv were investigated on freshly isolated left ventricular canine cardiomyocytes. Cells were loaded with Fura-2-AM calcium sensitive fluorescent dye before the experiments. Different concentrations of danicamtiv (10 nM - 2 μM) were applied in the experiments. Cell contraction was induced by field stimulation (0.5 Hz), then a set-up capable of recording the shortening of the sarcomere length as well as the changes in intracellular Ca²⁺ concentration simultaneously was used.

Results

In the presence of 0.5 Hz stimulation and 2 μM danicamtiv, both the contraction duration (0.66±0.03 s vs. 2.06±0.22 s, P<0.001, n=18) and the systolic ejection time were prolonged (0.51±0.02 s vs. 1.57±0.21 s, P<0.001, n=18), while the kinetics of contraction and relaxation were both decelerated (1.16±0.10 μm/s vs. 0.18±0.03 μm/s and 1.63±0.15 μm/s vs. 0.20±0.05 μm/s, P<0.001, n=18). Treatment with 2 μM danicamtiv showed a positive inotropic effect: a shortening could be observed in diastolic (1.91±0.01 μm vs. 1.57±0.04 μm, P<0.001, n=18), as well as in systolic sarcomere lengths (1.65±0.02 μm vs. 1.45±0.03 μm, P<0.001, n=18). The lowest effective danicamtiv concentration was 0.01 μM. Danicamtiv treatment was not associated with an increase in intracellular Ca²⁺ concentration.

Conclusions

Our results suggest that the positive inotropic effect of danicamtiv is accompanied by a significant reduction in resting sarcomere length of isolated cardiomyocytes and deceleration of relaxation kinetics, which may impair diastolic function. All these may limit the clinical efficacy of this novel myosin activator agent.

[1937] Molecular characterization of liver cysts

Authors: Monika Dybicz, Marta Tokaj, Albert Gandurski, Michał Jerzak, Weronika Stachera, Magdalena Szuba

Affiliation: Medical University of Warsaw, Department of General Biology and Parasitology

Trustee of the paper: Monika Dybicz

Corresponding author: Albert Miłosz Gandurski (s082426@student.wum.edu.pl)

Introduction

A number of cestode species can develop in the liver of pigs. Pigs are intermediate hosts of the larval stage of the genus *Echinococcus* maintaining the parasite cycle on farms and consequently infecting dogs. Dogs are able to disperse the parasite eggs and cause a risk of human invasion. The other species of tapeworms found in the liver of pigs are *Taenia hydatigena* and *T. solium*. The larval form of *T. hydatigena* is a common species that causes cysts which are similar to *E. granulosus*. Both *E. granulosus sensu lato* and *T. hydatigena* have the same intermediate hosts including sheep, cattle and pigs. When these animals are slaughtered in abattoirs with sanitary inspection, they are subjected to rigorous examination in order to identify the cysts in viscera. The method to detect parasite is based on visual macroscopic observation in tissues. This method usually does not allow to distinguish the etiology of the lesion. The diagnosis of these parasitosis is very important since these infections generate economic losses and cystic echinococcosis is a problem for public health.

Aim of the study

The aim of the study was to identify the parasite species in visceral cysts collected from swine slaughtered under veterinarian inspection located in eastern/northern regions of Poland.

Materials and methods

A total of 74 cysts were isolated from liver fragments and indicated morphological features similar to hydatid cysts. The cysts ranged in size from 0.8 to 3.2 cm in diameter, most of them was over 1 cm in diameter. Total DNA was extracted and used for amplification of NADH dehydrogenase 1 gene fragment. PCR products were purified and sequenced. The *nad1* sequences were compared using NCBI GenBank.

Results

Forty eight out of 74 DNA samples used as the template in separate PCRs yielded a single product. The sequences of 39 isolates (52.70%) were highly similar to *T. hydatigena*, 9 (12.16%) were identical to *E. canadensis* G7 which is probably the main genotype infecting pigs in many European countries. Twenty six samples (35.13%) provided no PCR product indicating no parasitic origin.

Conclusions

This study demonstrates that the most common species causing liver lesions in pigs was *T. hydatigena* (over 50% of cases) and then *E. canadensis* (about 10%). The final host of both species is the dog and other canids, therefore it suggests that the main pig invasion source are the farm dogs which do not undergo regular antihelminthic treatment.

[1949] Questioning the necessity of blocking background staining in whole organ immunohistochemistry

Authors: Jacek Tomczuk, Paweł Matryba, Jakub Gołąb

Affiliation: Medical University of Warsaw Department of Immunology

Trustee of the paper: Paweł Matryba

Corresponding author: Jacek Krzysztof Tomczuk (jacektomczuk1997@gmail.com)

Introduction

Since its inception in 1930s' tissue section staining with antibodies remains a fundamental technique in both research and diagnostics. Although the immunohistochemistry technique is constantly being improved, some aspects of immunostaining process have persisted unchanged and controversial. Blocking background staining to theoretically prevent acquisition of non-specific signal during the imaging process, remains one of them.

Aim of the study

Using standard, thin histological slices, Buchwalow et al. (2011) proved that the high specificity of currently manufactured antibodies prevents non-specific binding. Thus, it was determined that traditionally used protein blocking steps are unnecessary in the immunostaining of routinely fixed cell and tissue samples.

Recently presented tissue optical clearing techniques allow for imaging thick tissue slices or even whole organisms. However, time that is required for immunostaining of such thick specimens, potentially uneven distribution of signal and significantly multiplied amount of required reagents limit its wide adoption.

Hence, we expanded upon the work of Buchwalow et al. to verify whether the removal of background signal blocking step in case of thick, optically cleared murine tissue sections can be performed without negative impact on the quality of acquired data.

Materials and methods

Thick (100-200 μm) murine tissue slices were prepared from paraformaldehyde fixed organs, namely lymph nodes, brain, kidney, liver and thymus.

Next, the sections were subjected to immunostaining with either directly conjugated or unconjugated antibodies using one of the commonly used blocking solutions (containing bovine serum albumin (BSA), normal goat serum (NGS), FcR blocking antibody, combination of NGS and FcR blocking antibody) and phosphate-buffered saline (PBS)).

Immunostained specimens were imaged using Leica SP8 confocal microscope. The resulting images were compared with dedicated computer software (ImageJ, Imaris and Bitplane).

Results

In case of all tested antibodies, no non-specific signal was observed, irrespectively of the solution used during the blocking step.

Conclusions

Here we have shown that the removal of blocking step performed on thick, optically cleared tissue specimens does not impact the quality of obtained images in a negative manner. Therefore, the omission of this time and resource consuming step in the immunostaining protocols should be considered.

[3000] The volume of intracerebral hemorrhage determines reactive astrocyte morphology.

Authors: Oleksandra Bashyrova

Affiliation: O. O. Bogomolets National Medical University, Department of Histology and Embryology, Kyiv, Ukraine

Trustee of the paper: Serhii Savosko, Ph.D., Associate professor

Corresponding author: Oleksandra Bashyrova (sadcurlyfry@gmail.com)

Introduction

Astrocyte reaction to intracerebral hemorrhage (ICH) can be perceived as a universal astrocyte response to brain injury, which remains insufficiently researched. Morphological changes are termed astrogliosis and manifest as cellular hypertrophy, polarization of astrocyte branches, and increased expression of the glial fibrillary acidic protein (GFAP). Astrocyte hypertrophy is particularly pronounced at the border of damaged and intact brain tissue, where astrocytes form a glial scar, that delineates the affected area. Our research focuses on the role of ICH volume in astrocyte reaction, which is essential for discerning the role of astrogliosis in hemorrhagic stroke outcome.

Aim of the study

To analyze astrocyte reaction following ICH.

Materials and methods

ICH was modeled in Wistar rats by a two-step unilateral autologous blood injection into the internal capsule (0,02 ml with a 10-minute interval, with an overall volume of 0,04 ml), animals were anesthetized with sodium thiopental (50 mg/kg, i.p.). The animals were removed from the experiment by administering a lethal dose of sodium thiopental on days 1, 3, and 10 following the injury. Astrocyte reaction was assessed using GFAP immunohistochemistry in deparaffinized coronal brain slices. An assay of changes in astrocyte perimeter, length, and branching of processes was performed using ImageJ 1.46. Correlational analysis was conducted between ICH volume and the specific density of astrocytes in the penumbra. Statistical data processing was done using one-way ANOVA, Bonferroni posthoc test, and Spearman's rho correlation.

Results

We investigated the relationship between ICH volume and isolated astrocyte perimeter in the penumbra and found a strong positive correlation between these two factors on day 1 ($r=0,86$, $p<0,01$) and day 3 ($r=0,99$, $p<0,01$) following the injury. On day 10 such correlation was absent ($r=0,37$, $p>0,05$), which is attributable to changes in hematoma morphology and modulation of surrounding reactive changes. In the sham group correlation was not detected either ($r=-0,27$, $p>0,05$).

Conclusions

There is a positive correlation between ICH volume and astrocyte reaction in the first three days following the stroke, the absence of such correlation in the sham group permits us to conclude that the hemorrhage is the main determining factor of astrocyte reaction.

Cardiology & Cardiac Surgery

Date: 22nd April 2023, 9:00 AM

Coordinators:
Katarzyna Gozdera
Jakub Zabłocki

Patronage:

Polskie Towarzystwo Kardiologiczne

Sponsor:

Novartis



[1533] Ticagrelor downregulates the expression of proatherogenic and proinflammatory microRNA-125-b compared to clopidogrel

Authors: Ewelina Blazejowska (1), Ceren Eyiletlen (2), Marek Postuła (2), Krzysztof J. Filipiak (3), Aleksandra Gasecka (1)

Affiliation: (1,2) Medical University of Warsaw, Poland, (3) Maria Skłodowska-Curie Medical Academy in Warsaw, Poland

Trustee of the paper: Aleksandra Gasecka

Corresponding author: Ewelina Błażejowska (eb.blazejowska@gmail.com)

Introduction

Platelet P2Y₁₂ antagonist ticagrelor reduces mortality after acute myocardial infarction (AMI) compared to clopidogrel, but the underlying mechanism is unknown. Because activated platelets release proatherogenic and proinflammatory microRNA-125b (miR-125b) we hypothesized that the release of miR-125b is more efficiently inhibited by ticagrelor compared to clopidogrel.

Aim of the study

Prove that release of miR-125b is more efficiently inhibited by ticagrelor compared to clopidogrel.

Materials and methods

We compared miR-125a, miR-125b and miR-223 concentrations and these miRNAs procoagulant activity in plasma of patients after AMI treated with ticagrelor or clopidogrel. After percutaneous coronary intervention, 60 patients with first AMI were randomized to ticagrelor or clopidogrel. The concentration of miR-223, miR-125a-5p, miR-125b was evaluated in platelet-depleted plasma using quantitative polymerase chain reaction at randomisation, after 72 hours and 6 months of treatment. Multiple electrode aggregometry using ASPI test and the ADP test was used to determine platelet reactivity in response to dual antiplatelet therapy.

Results

The expression of miR-125b was higher in patients with AMI at all timepoints from 24 hours to 6 months, compared to healthy volunteers ($p=0.001$). The expression of other miRNA subtypes did not differ between AMI patients and healthy volunteers. In patients who switched from clopidogrel to ticagrelor, expression of miR-125b decreased at 72 hours ($p=0.007$) and increased back to baseline at 6 months ($p=0.005$). The expression of miR-125a-5p and miR-223 was not affected by the switch from clopidogrel to ticagrelor.

Conclusions

Ticagrelor attenuates the increase of miR-125b concentrations in plasma after acute myocardial infarction compared to clopidogrel. The ongoing release of miR-125b despite antiplatelet therapy might explain recurrent thrombotic events after AMI and worse clinical outcomes on clopidogrel compared to ticagrelor.

[1535] Predictors of periprocedural myocardial infarction after rotational atherectomy

Authors: Michał Błaszkiwicz, Kamila Florek, Dawid Głodek, Lidia Jurczenko, Aleksandra Mikołajczak, Jakub Więclaw; Supervisors: prof. dr hab. Krzysztof Reczuch, dr Wojciech Zimoch

Affiliation: Students' Scientific Group, Cardiology Department, Wrocław Medical University, Wrocław, Poland.

Trustee of the paper: Michał Błaszkiwicz

Corresponding author: Michał Jakub Błaszkiwicz (michalbl26@wp.pl)

Introduction

Rotational atherectomy has been proven as an effective tool in management of severely calcified coronary lesions. This procedure is more effective than traditional balloon angioplasty in inelastic, calcified plaques, however it is considered more aggressive and connected with higher risk of periprocedural complications including periprocedural MI.

Aim of the study

The aim of this study is to evaluate frequency and predictive factors of periprocedural MI occurring after rotational atherectomy procedures.

Materials and methods

This was a retrospective observational study. We revised the data of 534 consecutive patients who underwent rotational atherectomy in two major centers. Definition of periprocedural MI was consistent with 4th universal definition of myocardial infarction.

Results

Periprocedural MI occurred in 45 (8%) patients. These patients were older ($74,6 \pm 8,2$ vs $72 \pm 9,3$ $p=0,04$) and their SYNTAX Score more often was higher than 33 points (18% vs 7% $p=0,01$). In this group we observed higher rates of no/slow flow during the procedure (9% vs 1% $p=0,0003$), nondilatable lesion was a less often indication for the procedure in this group. Incidence of traditional risk factors was similar in both groups: hypertension (80% vs 87% $p=0,4$), diabetes (40% vs 73% $p=0,2$), renal failure (18% vs 21% $p=0,68$), heart failure (33% vs 38% $p=0,7$).

Univariate logistic regression models revealed: male gender (OR 0,53; CI 0,29-0,98; $p=0,04$) SS greater than 33 (OR 2,8; CI 1,21-6,50; $p=0,02$), age (OR 1,04; CI 1,00-1,07; $p=0,04$) no/slow flow (OR 7,85; CI 2,12-29,04; $p=0,002$), CABG in the past (OR 0,07; CI 0,01-0,56; $p=0,01$) nondilatable lesion (OR 0,41; CI 0,21-0,82; $p=0,01$) as positive and negative predictors of periprocedural myocardial infarction after rotational atherectomy. Multivariable model showed that occurrence of no/slow flow (OR 6,70; CI 1,38-32,48; $p=0,02$), high SS (>33) (OR 2,95; CI 1,19-7,35; $p=0,02$), nondilatable lesion (OR 0,42; CI 0,21-0,85; $p=0,02$) and CABG in the past (OR 0,08; CI 0,01-0,62; $p=0,02$) were independent predictors of periprocedural MI.

Conclusions

Periprocedural MI after rotablation was not an uncommon complication as it was present in almost every twelfth patient. It was connected with female sex, older age and more severe coronary disease (as described by SS). Occurrence of no/slow flow also increased the risk of periprocedural MI. Prior CABG and nondilatable lesion as an indication for the procedure were connected with lower risk of this complication.

[1536] Predictors of Carotid Atherosclerosis in Asymptomatic Patients with Coronary Artery Disease

Authors: Kamila Florek, Michał Błaszkiwicz, Supervisors: Joseph A. Moutiris MD, MSc, PhD, FESC

Affiliation: Wroclaw Medical University, Wroclaw, Poland; Paphos Hospital, University of Nicosia, Nicosia 8100, Cyprus.

Trustee of the paper: Michał Błaszkiwicz

Corresponding author: Michał Jakub Błaszkiwicz (michalbl26@wp.pl)

Introduction

Atherosclerosis is considered a generalized disease and the connection between coronary artery disease and peripheral atherosclerosis is significant. There are not many guidelines for the patients with asymptomatic carotid artery stenosis.

Aim of the study

The aim of this study is to evaluate frequency and predictive factors of carotid atherosclerosis in patients with coronary artery disease.

Materials and methods

This was a prospective observational study. We as pre-trained students, under doctor supervision, used the carotid ultrasound to detect the stenosis. We examined 20 consecutive patients, 5 females (25%) and 15 males (75%); the mean age was: 71,5. Carotid atherosclerosis was defined according to the newest guidelines.

Results

Plaque in Carotid arteries occurred in 14 out 21 patients (67%). Those were older ($74,9 \pm 7,9$ vs $71,5 \pm 10,4$ $p=0,03$) and their BMI more often was lower ($27,1 \pm 3,4$ vs $28,6 \pm 4,3$ $p=0,01$) as well they were less often obese (14% vs 43% $p=0,02$). Although moderate plaques were observed with lower frequency in obese patients- BMI ≥ 30 (14% vs 43% $p=0,02$), in patients using antiplatelet drugs (57% vs 71% $p=0,02$). Plaques in carotid arteries were more common in patients taking anticoagulant medications (14% vs 0% $p=0,02$).

In stenosis positive population univariate logistic regression models revealed: age (OR=1,1; CI 1,0-1,3; $p=0,004$) as positive, BMI (OR=0,6; CL 0,3-1,02; $p=0,05$), obesity (OR=0,3; CL 0,06-1,01; $p=0,05$) as negative predictors. In patients with moderate plaque it was revealed: antiplatelets (OR=0,25; CI 0,6-0,97; $p=0,04$) as a negative predictor. The multivariable model showed that age (OR=1,12; CI 1,001-1,25; $p=0,04$) was an independent predictor.

Conclusions

The results of our analysis showed that carotid atherosclerosis was more often in patients with lower BMI, while obesity was a negative predictor. Older age was an independent positive predictor. Antiplatelet drugs were revealed as a negative predictor of moderate carotid stenosis.

[1567] Photoplethysmography wave morphology in patients with Atrial Fibrillation

Authors: 1 Mikołaj Basza, 2 Weronika Kowalczyk, 2 Aleksandra Bożym, 2 Michalina Ciurla, 2 Małgorzata Krzyżanowska, 2 Cezary Maciejewski, 1 Wojciech Bojanowicz, 3 Mateusz Soliński, 3 Damian Wałąg, 2 Łukasz Kołtowski

Affiliation: 1 Medical University of Silesia in Katowice; 2 1st Chair and Department of Cardiology, Medical University of Warsaw; 3 Faculty of Physics, Warsaw University of Technology

Trustee of the paper: Cezary Maciejewski

Corresponding author: Aleksandra Bożym (aleksandra.bozym@gmail.com)

Introduction

Photoplethysmography (PPG) allows of blood flow assessment in subcutaneous blood vessels. This non-invasive investigation has found its application in commonly used pulse oximeters. Most current algorithms for detecting Atrial Fibrillation (AF) rely on Heart Rate Variability (HRV), and only a few studies analyse the variability of PPG waveform.

Aim of the study

This study aimed to compare morphological features of the PPG curve in patients with AF to those presenting a normal sinus rhythm (NSR) and evaluate their usefulness in AF detection.

Materials and methods

10-minute PPG signals were obtained from patients with AF and NSR. Nine morphological parameters ($1/\Delta T$, Pulse Width [PW], Augmentation Index [AI], b/a , e/a , $[b-e]/a$, Crest Time [CT], Inflection Point Area [IPA], Momentary Heart Rate) and four HRV parameters were calculated.

Results

Eighty subjects, including 33 with AF and 47 with NSR were recruited. In univariate analysis five morphological features and all HRV parameters were significantly different between the study groups. In three multivariate analysis, the model including both PPG and HRV morphological parameters showed the best fit to the data (AIC=80) and the highest efficiency (AUC=0.988 [95%CI: 0.974-0.999]) in identifying AF, in comparison to models using only morphological parameters or only HRV parameters.

Conclusions

There are significant differences in PPG waveform between AF and NSR, which are useful in AF detection algorithm. Moreover adding those features to HRV-based algorithms may improve their specificity and sensitivity.

[1575] The link between cardiovascular and periodontal diseases

Authors: Benedek Bianka Krisztina, Horvath Lukas, prof. dr. Benedek Imre, dr. Rodean Ioana

Affiliation: Clinic of Cardiology, Emergency Clinical County Hospital, "George Emil Palade" University of Medicine, Pharmacy, Science and Technology,

Trustee of the paper: Benedek Bianka Krisztina

Corresponding author: Bianka Krisztina Benedek (benedekb.krisztina@gmail.com)

Introduction

Periodontal disease is considered a risk factor for cardiovascular disease.

Aim of the study

The purpose of this study was to explore the association between the severity of periodontal disease (PD), unstable plaque features and acute coronary events, focusing on the role of periostin. [1]

Materials and methods

In the first part of this study, the target group consisted of 52 patients who presented with unstable angina and an obstructive coronary lesion confirmed by a CCTA examination. Patients were subjected to a dental examination where the severity of their periodontal disease was assessed based on the Periodontal Index (PI). Patients were divided in 2 groups: patients with a low periodontal index (LPI) and patients with a high periodontal index (HPI). To the second part of this study 92 patients were enrolled based on the same criterias. The patient population was divided into two groups based on the median serum Pn value: patients with low Pn levels and in group high Pn levels. [2]

Results

Plaque volume and non-calcified plaque volume were more prominent on CCTA in HPI patients. Furthermore, PI was strongly associated with the presence of susceptibility features in atherosclerotic plaques. Among all periodontal indices, the papillary bleeding index and loss of gingival attachment were in strong correlation with high-risk plaque. Furthermore, the high Pn group presented with more STEMI-type ACS and a more frequent incidence of heart failure. Myocardial necrosis was more prominent in the high Pn group, reflected in elevated CK-MB serum levels and a longer need of hospitalisation. Group 2 patients had elevated levels of serum albumin, MMP9 and LDL-cholesterol, indicating that patients with high Pn levels had an increased cardiovascular risk.

Conclusions

In conclusion, patients suffering from an advanced periodontal disease and an unstable angina had a more vulnerable phenotype of their culprit plaques. Also, the high levels of periostin, is directly linked to a more severe type of myocardial infarction.

[1576] Innovation of Cardiac Imaging Techniques

Authors: Horvath Lukas, Benedek Bianka Krisztina

Affiliation: Clinic of Cardiology, Emergency Clinical County Hospital, "George Emil Palade" University of Medicine, Pharmacy, Science and Technology

Trustee of the paper: Horvath Lukas

Corresponding author: Lukas Horvath (11032000lh@gmail.com)

Introduction

Cardiovascular disease is a major cause of death worldwide. The development of hybrid imaging techniques has improved the precision of diagnosis for these conditions, potentially leading to better prognoses.

Aim of the study

This study aimed to investigate the relationship between coronary plaque vulnerability, systematic inflammation, and myocardial viability in patients who had experienced a heart attack.

Materials and methods

The study included 45 patients who had suffered a myocardial infarction within the past month. All patients underwent both coronary computed tomography angiography (CCTA) and cardiac magnetic resonance (CMR) imaging to generate a hybrid imaging model. Using this model, we identified various plaque vulnerability features, such as positive remodeling, spotty calcification, the napkin-ring sign, and low attenuation. Based on the presence of these features, patients were classified into three groups: Group 1 had no vulnerability features (15%); Group 2 had 1-2 vulnerability features (60%); and Group 3 had more than 2 vulnerability features (25%).

Results

There was no significant correlation between the study groups and the Syntax score ($p = 0.7$) or the Ca-score ($p = 0.4$). However, we found a strong correlation between plaque vulnerability markers and the size of the infarct as measured by CMR ($p = 0.007$), the Duke jeopardy score as determined by CCTA ($p = 0.01$), and inflammation biomarkers measured in the first day after the infarct (hs-CRP $p = 0.007$; MMP-9 $p = 0.038$).

Conclusions

Our findings suggest that non-culprit plaque vulnerability detected by hybrid imaging is directly related to the size of the infarct and the level of inflammation markers detected in the peri-acute period following a coronary event.

[1619] Use of statins in cancer patients following acute myocardial infarction and its impact on long-term clinical outcomes.

Authors: Alicia del Carmen Yika, Natalia Kachnic, Grzegorz Horosin, Piotr Walczak, Aleksandra Karcińska,

Affiliation: Students' Scientific Group at the Department of Coronary Artery Disease and Heart Failure, Jagiellonian University Medical College, Cracow.

Trustee of the paper: Konrad Stępień,MD,PhD;Karol Nowak,MD;Jarosław Zalewski,MD,PhD;Jadwiga Nessler,MD,PhD

Corresponding author: Alicia del Carmen Yika (alicia.yika@student.uj.edu.pl)

Introduction

Statin use on long-term clinical outcomes in cancer patients following acute myocardial infarction (MI) remains insufficiently elucidated

Aim of the study

We sought to analyze the prevalence of statin use in MI patients with cancer hospitalized in a tertiary cardio-oncology center and their influence on long-term mortality

Materials and methods

Of the 1,011 consecutive acute MI patients hospitalized between 2012 and 2017, cancer was found in 134 (13.3%) subjects . Within a median follow-up of 69.2 (37.8-79.9) months, a mortality rate, and its determinants were analyzed

Results

Compared with non-cancer population, MI patients with cancer were older (73 [66-79] versus 68 [60-78] years, $P<0.001$), had lower hemoglobin level (12.8 [11.2-14.0] vs 13.8 [12.8-15.0], $P<0.001$), lower total cholesterol (4.1 [3.4-4.8] vs 4.4 [3.6-5.3], $P=0.006$) and lower HDL cholesterol (1.1 [0.9-1.4] vs 1.2 [1.0-1.6], $P<0.001$), without significant differences in LDL cholesterol (2.5 [1.9-3.1] vs 2.6 [1.7-3.4], $P=0.70$). Statins were prescribed less frequently in MI patients with cancer as compared with non-cancer MI population (80.5% versus 92.1%, $P<0.001$). Atorvastatin was the most frequent statin in both cancer and non-cancer groups (68.4% vs 75.1%, $P=0.13$). In the cancer group, simvastatin was more frequently (16.7% vs 5.9%, $P<0.001$) prescribed. The independent determinants of no use of statins were anemia ([HR] 2.3, [95% CI] 1.3-4.2, $P=0.006$), no coronary artery stenosis $>50\%$ (HR 5.0, 95% CI 2.5-10.1, $P<0.001$) and cancer (HR 1.9, 95% CI 1.01-3.7, $P=0.049$) but not LDL cholesterol. The mortality rates were significantly higher in MI patients not treated with statins, both in the non-cancer population (29.5%/year vs 6.7%/year, $P<0.001$) as well as in the cancer group (53.9%/year vs 24.9%/year, $P<0.05$) as compared to those treated with statins. No statin use (HR 2.3, 95% CI 1.8-3.0, $P<0.001$), active cancer (HR 2.3, 95% CI 1.8-3.0, $P<0.001$), patient's age (HR 2.3, 95% CI 1.8-2.9, $P<0.001$, per year) and anemia (HR 1.7, 95% CI 1.4-2.1, $P<0.001$) independently increased long-term mortality while no coronary artery stenosis $>50\%$ (HR 0.65, 95% CI 0.44-0.96, $P=0.03$) and better LVEF (HR 0.97, 95% CI 0.96-0.98, $P<0.001$, per 1%) improved long-term survival

Conclusions

Active cancer, anemia, and lack of significant coronary lesions were associated with no use of statins in patients following MI. By multivariable approach both no statins use in MI patients independently on an active malignancy were associated with unfavorable long-term outcomes.

[1630] **Clinical characteristics and long-term outcomes of patients with heart failure with improved ejection fraction. First Polish report from LECRA-HF registry.**

Authors: Aleksandra Karcińska, Alicia del Carmen Yika, Natalia Kachnic

Affiliation: Jagiellonian University Collegium Medicum, Department of Coronary Artery Disease and Heart Failure

Trustee of the paper: Konrad Stępień, Jarosław Zalewski

Corresponding author: Aleksandra Karcińska (aleksandrakarcinska@gmail.com)

Introduction

Heart failure with improved ejection fraction (HFimpEF) is a new subgroup of HF patients established by the newest ESC guidelines. However, their clinical characteristics and long-term outcomes remain insufficiently elucidated, especially among the Polish population.

Aim of the study

Our study aimed to characterize these patients based on the single-center Lesser Poland Cracovian Heart Failure Registry (LECRA-HF).

Materials and methods

Among 1186 patients enrolled in the LECRA-HF and hospitalized due to HF exacerbation (2009-2019), 340 (28.7%) were those with HF with reduced ejection fraction (HFrEF) who remained in treatment in our outpatient clinic. Based on the control echocardiography and following the new universal definition of HF, HFimpEF (61, 17.9%) and HFnon-impEF (279, 82.1%) groups were distinguished. Their baseline clinical characteristics and long-term overall mortality have been compared.

Results

Patients with HFimpEF were more commonly females (32.8 vs 14.7%, $P<0.001$), less often had diabetes (37.7 vs 54.2%, $P=0.02$), severe chronic kidney disease (0.0 vs 6.5%, $P=0.03$) and prior myocardial infarction (34.4 vs 53.1%, $P=0.008$). On admission HFimpEF patients presented less severe symptoms (NYHA III/IV: 78.7 vs 90.7%, $P=0.008$), higher values of LVEF (30 (25-35) vs 20 (15-28), $P<0.001$) and more frequent significant aortic stenosis (14.8 vs 3.9%, $P=0.003$). HFimpEF had lower levels of creatinine on admission (95 (79-118) vs 106 (88-138.5) $\mu\text{mol/l}$, $P=0.003$) along with its lower maximal values during hospitalization (97 (86-127) vs 115 (93-154) $\mu\text{mol/l}$, $P=0.007$). In the multivariate analysis, the HFimpEF diagnosis was independently predicted by the lower NYHA scale ($P=0.045$), non-ischemic HF etiology ($P<0.001$), lack of diabetes ($P=0.033$) and higher baseline values of LVEF ($P<0.001$). The long-term survival was significantly higher in HFimpEF than in HFnon-impEF ($P=0.004$). The independent mortality predictors among HFrEF were the lack of HFimpEF ($P=0.033$) and higher creatinine levels on admission ($P<0.001$).

Conclusions

The baseline clinical characteristic of HFimpEF is different from those with HFnon-impEF. HFimpEF constitutes an independent predictor of improved long-term outcomes.

[1813] Comparison of adverse effects associated with left atrial appendage closure between LARIAT and AtriClip device based on MAUDE database.

Authors: Jakub Rusinek, Jakub Batko, Daniel Rams

Affiliation: CAROL - Cardiothoracic Anatomy Research Operative Lab, Department of Cardiovascular Surgery and Transplantology, Institute of Cardiology, Jagiellonian University Medical College, Krakow, Poland

Trustee of the paper: prof. Krzysztof Bartuś, MD, PhD; Radosław Litwinowicz, MD, PhD

Corresponding author: Jakub Mikołaj Rusinek (jakub.rusinek@student.uj.edu.pl)

Introduction

Left atrial appendage closure (LAAC) is an alternative treatment to reduce the risk of thromboembolism in patients with atrial fibrillation who are contraindicated for oral anticoagulation (OAC). Epicardial closure can be performed with LARIAT or AtriClip devices. Manufacturer and User Facility Device Experience (MAUDE) database contains medical device reports submitted to the U.S. Food and Drug Administration (FDA) by mandatory reporters (manufacturers, importers, and device user facilities).

Aim of the study

The aim of this study was to evaluate and compare the adverse effects of epicardial LAAC performed with Lariat and AtriClip device based on MAUDE database.

Materials and methods

Two independent researchers queried the MAUDE database to obtain LARIAT and AtriClip device reports from November 2011 to July 2022. Duplicates, reports based on research, social media and without significant data on patient outcome/complications were excluded. Collected data was further statistically analyzed.

Results

460 reports were obtained from the MAUDE database, 173 were excluded per study protocol. 287 studies were further analyzed – 62 about LARIAT and 225 about AtriClip. Device malfunction occurred in 46.8% of reports for LARIAT and in 67.1% of reports for AtriClip ($p < 0.001$). It coexisted with patient complications in 100.0% of cases in LARIAT and in 14.6% of cases in AtriClip ($p < 0.001$). Pericardial effusion and hemorrhage appeared significantly more often in LARIAT group (43.5% vs. 2.2%, $p < 0.001$; 45.2% vs. 14.4%, $p < 0.001$; respectively). Stroke occurred in AtriClip group more often (0.0% vs. 7.8%, $p = 0.042$). Perforation occurred in 40.3% of patients in LARIAT and 42.2% in AtriClip ($p = 0.868$). Left atrial appendage and right ventricle were perforated significantly more often during LARIAT procedure (80.0% vs. 31.6%, $p < 0.001$; 16.0% vs. 0.0%, $p = 0.021$).

Conclusions

Adverse effects of the procedure with the usage of two different devices differ significantly. Patients who undergo LARIAT procedure are more prone to pericardial effusion and hemorrhage, as well as left atrial appendage and right ventricle perforation. This knowledge should put the emphasis on the development of procedure modifications which may help to avoid those complications or recognize them faster during or after the procedure.

[1868] Ductus arteriosus anatomy in duct-dependent pulmonary circulation – a virtual reality volume rendering study

Authors: Antoni Ludew, Maksym Helman, Nikola Topuzov

Affiliation: Medical University of Warsaw, Department of Descriptive and Clinical Anatomy

Trustee of the paper: Adam Koleśnik MD

Corresponding author: Antoni Ludew (antekludew@gmail.com)

Introduction

Congenital heart defects with duct-dependent pulmonary circulation comprise a considerable amount of patients requiring early surgical or interventional palliative treatment. The increasing popularity of transcatheter ductus arteriosus (DA) stenting raises a question – what patterns of anatomy can be found in this group of patients?

Aim of the study

The aim of our study was to assess the morphology of the DA, pulmonary arteries (PA) and aortic arch in patients with duct-dependent pulmonary circulation using direct virtual reality volume rendering.

Materials and methods

30 anonymised CT scans of patients aged from 1 to 47 days (median = 11) were obtained and analysed in virtual reality using VMersive software (VR-Learning, Warsaw, Poland). The group consisted of 13 patients with tetralogy of Fallot, 7 with double outlet right ventricle, 2 with tricuspid atresia and 8 with pulmonary stenosis or atresia.

The morphology of DA and aortic arch was analysed and categorised. Following measurements were performed: DA diameter and length, number of DA segments and angles between them, aorta and PAs diameters, PA length. All measurements were verified using virtual reality MPR mode provided by the software.

Results

DA shape was categorised into 3 categories: straight (6.7%), single-bend (46.7%, divided into L-shaped and U-shaped) and tortuous (46.6%, divided into S-shaped and spiral), depending on the number of segments and their spatial relations. Mean DA length was 16.3 mm and ostial diameter 4.1 mm.

The morphology of the aortic arch and DA was categorised into 3 types: left-sided arch and DA (70%), right-sided arch and DA (6.7%) and right-sided arch with left sided DA (23.3%). DA originated from the aortic arch in 43.3%, aortic isthmus in 16.7%, descending aorta in 16.7%, left brachiocephalic trunk in combination with right aortic arch in 20% and from persistent Vth pharyngeal arch in 3.3%. DA joined the respective PA in the pulmonary trunk bifurcation in 43.3% and distal to the bifurcation in 56.7%. In the latter case, on average the proximal segment of the PA accounted for 26% of the total PA length. Mean LPA diameter was 4.05 mm and RPA was 4.08 mm.

Conclusions

Virtual reality volume rendering allows for spatial recognition of shape and topographic relations of DA and aortic arch, as well as performing various measurements. The method allows for precise assessment of DA ostium, its distal connection site and pulmonary arteries anatomy, which could prove valuable for planning transcatheter DA stenting.

[1918] The influence of body composition on the length of hospitalization among patients with low surgical risk qualified for coronary artery bypass surgery – a pilot study.

Authors: Bartosz Walkowski, Wojciech Michalski, Zuzanna Przekop, Mikołaj Marszałek

Affiliation: Department of Cardiac Surgery UCC MUW

Trustee of the paper: Radosław Wilimski

Corresponding author: Mikołaj Marszałek (mszalek.m@gmail.com)

Introduction

Bioelectrical impedance analysis (BIA), is a non-invasive method for measuring altered electrical properties of biological tissues. It has been recognised as an objective prognostic marker of disease severity and frailty.

Aim of the study

The aim of this study was to determine whether BIA determines postoperative length of hospital stay in low operative risk patients undergoing coronary artery bypass grafting.

Materials and methods

A prospective pilot study was conducted in a tertiary hospital. The nutritional state of the cardiac surgery patients was evaluated using BIA the day before the scheduled surgery and on the 4th-7th day after off-pump coronary artery bypass grafting. After applying selection criteria, 55 low operative risk patients were selected and classified into two groups in accordance with the length of hospital stay: ≤ 7 days and > 7 days. Associations between the nutritional state of the cardiac surgery patients and postoperative outcomes were analysed.

Results

The length of hospital stay > 7 days was detected in 35 (63.6%) patients in the selected group, which consisted of low operative risk patients with a median Euroscore II value of 1.38 (IQR: 0.94-2.04). Body mass index (BMI) did not differ significantly between the compared groups of patients [mean 29 (95% CI 27.1-30.9) vs. 28.9 (27.7-30.1) $p=0.73$]. The hospitalization time > 7 days was associated with preoperative higher body fat mass (%) [mean 29.9 (95% CI 27.3-32.6) vs. 25.6 (22-29.2) $p=0.02$], lower fat-free mass (%) [70 (67.4-72.7) vs. 74.4 (70.9-77.9) $p=0.02$] and lower total body water (%) [51.3 (49.3-53.2) vs. 54.5 (51.9-57) $p=0.02$]. Significant decreases in body fat mass and significant increases in body fat-free mass and body water were observed in both groups in the postoperative period.

Conclusions

A low preoperative body fat-free mass and a high body fat mass are indicators of prolonged hospitalization in low-risk patients accepted for heart revascularisation. Further research is needed to evaluate clinical applications of BIA in more accurate identification of subclinically malnourished cardiac surgery patients.

[1945] Safety and effectiveness of very-high-power, short-duration ablation in patients with atrial fibrillation: Preliminary results

Authors: Karolina Mitrzak*, Michał Peller*, Bartosz Krzowski, Cezary Maciejewski, Paweł Balsam, Michał Marchel, Marcin Grabowski, Piotr Łodziński

Affiliation: 1st Department of Cardiology, Medical University of Warsaw, Poland

Trustee of the paper: Karolina Mitrzak

Corresponding author: Karolina Mitrzak (karolina.mitrzak95@gmail.com)

Introduction

Pulmonary vein isolation (PVI) is at the forefront of rhythm control strategies in patients with atrial fibrillation (AF). A very-high-power, short-duration (vHPSD) catheter, QDot Micro™ (Biosense Webster) was designed to improve the effectiveness of AF ablation within a shorter procedure time.

Aim of the study

The aim of this study was to compare the effectiveness and safety of PVI ablation between this vHPSD ablation mode and conventional ablation-index-guided ablation (ThermoCool Smarttouch SF catheter).

Materials and methods

This single-center, retrospective, observational study enrolled 108 patients with AF, referred for catheter ablation between December 16, 2019 and December 3, 2021. In 54 procedures (mean age: 58.0 ± 12.3 ; 66.67% male), a QDot Micro™ catheter was used (vHPSD-group), and 54 patients (mean age: 57.2 ± 11.8 ; 70.37% male) were treated with a ThermoCool Smarttouch™ SF catheter (AI-group). The primary endpoint was freedom from AF 3 months after ablation.

Results

Atrial fibrillation was found to recur in 14.81% of patients in the vHPSD-group and in 31.48% of patients in the AI-group ($p = 0.07$). There was no difference in treatment-emergent adverse events between the two groups (6.3% vs. 0%; $p = 0.10$). One severe adverse event (a cerebral vascular accident) was observed in the vHPSD-group. The mean dose of remifentanyl was reported to be lower during QDot Micro™ catheter-based PVI ($p < 0.001$). The vHPSD-based PVI was associated with shorter radiofrequency application time ($p < 0.001$), fluoroscopy time ($p < 0.001$), and total procedure time ($p < 0.001$).

Conclusions

This study suggests vHPSD ablation is safe, can reduce the dosage of analgesics during significantly shorter procedures and may enhance the success rate of catheter-based PVI.

[1968] Sex-related differences in acute pulmonary embolism patients treated by a pulmonary embolism response team – a multicenter retrospective cohort study.

Authors: Grzegorz Procyk, Paweł Kurzyna, Karolina Jasińska, Katarzyna Wrona, Szymon Darocha, Marta Banaszekiewicz, Dariusz Zieliński, Michał Florczyk, Krzysztof Wróbel, Marcin Grabowski, Adam Torbicki, Marcin Kurzyna, Aleksandra Gąsecka, Arkadiusz Pietrasik

Affiliation: 1st Chair and Department of Cardiology, Medical University of Warsaw, 02-097 Warsaw, Poland.

Trustee of the paper: dr Arkadiusz Pietrasik

Corresponding author: Grzegorz Procyk (grzegorzprocyk@gmail.com)

Introduction

Pulmonary embolism (PE) is the third most frequent acute cardiovascular condition worldwide. PE response teams (PERTs) were created in 2013 to facilitate treatment implementation in PE patients, particularly those at high risk of early death. Because of the short PERTs' existence time, there is limited data about the characteristics of patients treated by PERTs.

Aim of the study

We aimed to analyze sex-related differences in baseline characteristics, applied treatment, and prognosis of acute PE patients treated by a PERT.

Materials and methods

235 patients diagnosed with PE in any of the 3 participating hospitals between September 2017 and December 2021 were included in the study. Clinical and treatment data were obtained from medical records. Patients' outcomes were assessed until death or hospital discharge. Mann-Whitney U test was used for nonparametric continuous variables and Fisher's exact test/chi-squared test was performed for categorical variables. The Kaplan-Meier method was used to draw the survival curve, and the log-rank test was used to compare the difference in survival probability.

Results

Women were older than men (median 66.0 years, IQR 49.5-77.0 vs. 58.5 years, IQR 49.0-69.3; $p=0.023$). Among analyzed symptoms at admission, the cough was the only one that differed in frequency between sexes – it was more prevalent in men (OR 3.77; 95%CI 1.63-8.12; $p=0.001$).

Among 22 analyzed risk factors, we found nicotine addiction more frequent in men (OR 2.61; 95%CI 1.37-4.97; $p=0.004$) and hormonal therapy more frequent in women (OR 15.46; 95%CI 2.75-167.1; $p=0.001$).

Hospitalized women required intubation more often than men (OR 2.92; 95%CI 1.28-6.68; $p=0.020$).

Proximal deep vein thrombosis (DVT) was more common in men (OR 1.71; 95%CI 1.00-2.89; $p=0.047$) although total DVT (proximal and distal analyzed together) did not differ between the sexes ($p=0.050$).

Low molecular weight heparin (LMWH) was more often used in men (OR 2.43; 95%CI 1.33-4.47; $p=0.004$). Other anticoagulants were used with the same frequency in both sexes.

The survival probability did not differ between the sexes ($p=0.436$).

Conclusions

Most of the analyzed parameters did not differ between men and women treated by a PERT. However, we found some distinctions. Cough and nicotine addiction were more often in hospitalized men, while hormonal therapy was more common in women. Men received LMWH more frequently than women

while women were intubated more often than men. Significantly, the survival probability did not differ between the sexes.

[1971] Excessive exercise increases metabolites associated with pathophysiologic changes in ultramarathon runners

Authors: Zofia Wicik, Ceren Eyileten, Anna Nowak, Mikołaj Marszałek, Andrzej Ciechanowicz, Piotr Szwed, Disha Keshwani, Lukasz Malek, Wiecha S, Marek Postula, Prof. Magdalena Kucia

Affiliation: Department of Experimental and Clinical Pharmacology, Medical University of Warsaw, Center for Preclinical Research and Technology CEPT, 02-091 Warsaw, Poland

Trustee of the paper: Ceren Eyileten

Corresponding author: Mikołaj Marszałek (mszalek.m@gmail.com)

Introduction

Regular physical exercise is analogous to improved cardiovascular health and increased longevity. However, if in excess it can act as a double edged sword. Acute bouts of extreme physical activity trigger complex molecular responses reflected by changes in inflammatory markers and metabolic pathways that are believed to yield detrimental effects on the cardiovascular system.

Aim of the study

We aimed to assess the effects of high-intensity and long-lasting exercise prototype (100km run) on the metabolomic changes in a unique population of high-level long-term ultra-marathon runners.

Materials and methods

Plasma samples were collected from ultramarathon runners (n=22) with 2-time points: before and after the run (Completion (100 km) or exhaustion (52 - 91 km, median 74 km)). For untargeted metabolomic analysis we used ultra-high resolution Fourier-Transform Ion Cyclotron Resonance Mass Spectrometry with an electrospray ion source in direct injection. Mass spectra were analyzed by T-Rex2D algorithm in the MetaboScape5.0.

Results

Mann-Whitney test (FDR<0.05) identified 1601 up and 1030 downregulated metabolites with at least a 2 fold difference after high-intensity run. Enrichment analysis showed that the top pathways affected by analyzed metabolites were the TCA cycle (FDR=0.0442), metabolism of; Sphingolipids (p=0.00774), Glyoxylate and dicarboxylate (p=0.0249) and Butanoate (p=0.0352). Top disease phenotypes associated with differentially regulated metabolites were critical illness (major trauma, severe septic shock, or cardiogenic shock) (p=0.00154) and multiple CVS-related diseases (Fig1).

Top after the run up-regulated metabolites identified in the study included heart failure associated acetylcarnitines[2] CAR(14:2) (log₂FC=11.57; AUC=0.97), Dodecanoylcarnitine (2.00;0.960), 9-Decenoylcarnitine (1.78;0.95), CAR(DC8:0) (14.99;0.94).

Interaction network analysis focused on genes associated with CVS identified atherosclerosis/ obesity-related Phospholipase A2 Group IB (PLA2G1B) as potentially the most affected gene by analyzed metabolites (Fig2).

Conclusions

Results show a twofold post run increase in metabolites that are both potential markers for acute exercise and that are strongly associated with CV diseases. This calls for consideration of the detrimental effects of excessive exercise and implementation of monitoring in amateur athletes.

[1973] Long-term survival after Transcatheter Aortic Valve Implantation (TAVI)

Authors: Julia Kozakiewicz, Małgorzata Duzinkiewicz, Michał Kuźma, Tomasz Januszko

Affiliation: Studenckie Koło Naukowe przy Klinice Kardiologii Inwazyjnej USK w Białymstoku, Klinika Kardiologii Inwazyjnej USK w Białymstoku

Trustee of the paper: Paweł Muszyński MD, Krzysztof Struniawski MD, PhD, Ass.Prof Łukasz Kuźma, Ass.Prof Marcin Kozuch, prof. Sławomir Dobrzycki

Corresponding author: Julia Anna Kozakiewicz (kozakiewiczjulia99@gmail.com)

Introduction

A TAVI was created as a less invasive alternative to surgical aortic valve replacement (SAVR) for patients with symptomatic, severe aortic stenosis, especially elderly with high surgical risk. Lately, the number of patients treated with this procedure is constantly growing, therefore increasing knowledge about long-term survival is crucial.

Aim of the study

The goal was to evaluate survival after TAVI in a single-centre setting.

Materials and methods

90 consecutive patients treated with TAVI, between 09-04-2010 and 12-02-2018, at the Medical University of Białystok Clinical Hospital, after local Heart-Team qualification were included in the study. The survival was calculated using Kaplan–Meier estimation and Cox Proportional Hazards Regression.

Results

The mean age of the subject was 79.8 years, with nearly equal representation of both genders (55.56% male).

75.56% of patients were suffering from hypertension, 51.11% from Chronic Kidney Disease (CKD), 35.56% from Atrial Fibrillation (AF) and 26.67% from Diabetes mellitus (DM). The 30-day, 1-year, 3-year, 5-year and 10-year survival were, respectively, 84.44%, 71.1%, 53.31%, 34.87% and 14.78%. Atrial fibrillation ($p = 0.7800$), chronic kidney disease ($p = 0.8918$) and gender ($p = 0.6916$) had no significant impact on survival.

Conclusions

Atrial fibrillation, chronic kidney disease and gender did not affect survival after TAVI. Our results show the TAVI outcome in single-center, mild-volume settings.

[1977] Impact of coronary artery disease and heart revascularization on outcomes in patients with aortic valve stenosis treated with transcatheter aortic valve implantation.

Authors: Kamil Krauz, Maciej Mazurek

Affiliation: Department of Cardiac Surgery, Medical University of Warsaw

Trustee of the paper: Radosław Wilimski

Corresponding author: Kamil Krauz (kamilkrauz01@gmail.com)

Introduction

Coronary artery disease (CAD) and degenerative aortic stenosis often coexist. However, the impact of CAD and its management on the prognosis after transcatheter aortic valve implantation (TAVI) remains uncertain.

Aim of the study

The aim was to evaluate the impact of obstructive CAD treated with percutaneous coronary intervention (PCI) or coronary artery bypass grafting (CABG) prior to TAVI on the outcome based on the experience of a high-volume academic center over the period of 10 years.

Materials and methods

Overall, 507 patients who underwent TAVI after heart team decision were included. Patients were divided into three groups: no CAD, PCI and CABG. Baseline, procedural and follow-up data was acquired from the national POL-TAVI registry.

Results

Patients with PCI (n=127) or CABG (n=59) prior to TAVI had similar all-cause mortality as those without obstructive CAD (n=321) at 30 days (6.7 vs. 8.6 vs. 10.4%, P=0.5, respectively) and at 1 year follow-up (15.8 vs. 16.0 vs. 16.4%, P=0.98, respectively). The PCI and CABG groups showed a similar to the no CAD group incidence of myocardial infarction at 30 days (2.5 vs. 3.4 vs. 2.0% P=0.79, respectively) and at 1 year follow-up (3.5 vs. 6.0 vs. 2.5% P=0.42, respectively). The PCI and CABG groups showed a higher incidence of stroke at 30 days (5.0 vs. 8.6 vs. 2.0% P=0.03, respectively) and at 1 year follow-up (7.1 vs. 10.0 vs. 2.5% P=0.02, respectively). Patients with obstructive CAD treated with PCI and CABG had a higher hospitalization rate due to heart failure at 1 year as compared with the remaining patients (15.3 vs. 8.4%, P= 0.02).

Conclusions

In conclusion, revascularization prior to TAVI seems to improve survival to levels comparable with patients without obstructive CAD at baseline. Obstructive CAD treated with PCI or CABG prior to TAVI has a negative impact on cerebrovascular and heart failure events rate.

Dentistry & Maxillofacial Surgery

Date: 21st April 2023, 10:00 AM

Coordinators:
Maja Kłopecka
Natalia Perz

Patronages:

Polskie Towarzystwo Chirurgii Stomatologicznej i Szczękowo-Twarzowej
Polskie Towarzystwo Periodontologiczne
Polskie Towarzystwo Studentów Stomatologii
Polskie Towarzystwo Stomatologii Dziecięcej
Polskie Towarzystwo Stomatologiczne
Będąc Młodym Dentystą
dr hab. n. med. Mariusz Szuta - Konsultant Krajowy w dziedzinie Chirurgii
Szczękowo-Twarzowej

[1640] Evaluation of the condylar position in the temporomandibular joint in patients undergoing orthognathic surgery

Authors: Ewa Stopa, Wojciech Stopa

Affiliation: Students' Scientific Group "Le Fort", Department of Cranio-Maxillofacial Surgery, Oral Surgery and Implantology MUW

Trustee of the paper: Łukasz Stopa M.D.

Corresponding author: Ewa Jadwiga Stopa (e.stopa@onet.pl)

Introduction

Orthognathic surgery has a significant impact on occlusal conditions, facial aesthetics and functioning of the entire stomatognathic system. The positioning of bone segments during orthognathic surgery can result in the changes of the position of the mandibular condyle in the mandibular fossa. Maintaining the condyle in the preoperative anatomical position after orthognathic surgery is considered as one of the determinants of a stable outcome, which can prevent temporomandibular joint complications.

Aim of the study

The aim of the study was to evaluate the position of the mandibular condyle before and after orthognathic surgery by measuring distance between selected points based on Computed Tomography.

Materials and methods

The study has been conducted retrospectively. Computed Tomography scans of 4 patients with class II and 10 patients with class III malocclusion who underwent orthognathic surgery between 2020 and 2021 have been evaluated. There were 11 females and 3 males. The mean age of the patients was 25,1 years. For measurements DDS-Pro software was used. Linear measurements of anterior space (AS), superior space (SS), and posterior space (PS) were made to determine the position of the condyle for each joint both before and after the surgery. The change was considered significant if it exceeded 2 Standard Deviations (SD). The results have been statistically evaluated by means of the Fisher exact test. The significance level was set to $p < .05$.

Results

In the group with class II malocclusion the mean difference of the AS, SS, and PS values before and after surgery were 0.3 mm (SD \pm 0.3 mm), 1.2 mm (SD \pm 1.0 mm), and 1.6 mm (SD \pm 1.2 mm) and in the group of with class III malocclusion 0.3 mm (SD \pm 0.2 mm), 0.3 mm (SD \pm 0.2 mm), and 0.3 mm (SD \pm 0.3 mm). The Fisher exact test has shown that a significant change in the position of the condyle was more likely in patients with class II malocclusion ($p=0.0003$).

Conclusions

These findings highlight the demand for modification of planning and performing orthognathic surgery in patients with class II malocclusion.

[1643] Evaluation of knowledge about oral hygiene and pro-health behaviors based on a survey

Authors: Zuzanna Jończyk, Karolina Zalisz, Filip Budnik, dr n. med. Ewa Rusyan, dr hab. inż. Antoni Grzanka, prof. dr hab. n. med. Agnieszka Mielczarek

Affiliation: Medical University of Warsaw

Trustee of the paper: dr n. med. Ewa Rusyan

Corresponding author: Zuzanna Jończyk (zuza.jonczyk@wp.pl)

Introduction

Studies of pro-health behaviors are one of the important methods of assessing factors influencing the health of the population. Even though over the years there has been a constant increase in the pro-health awareness of the Polish society, the epidemiological picture of the dentition of adult Poles is still unsatisfactory.

Aim of the study

Assessment of knowledge of the study population regarding caries prevention, the role of fluoride compounds and hygienic habits.

Materials and methods

The study was conducted on the basis of a self-authored questionnaire contained 16 questions about demographic data, awareness and pro-health attitudes, sources of health information and hygiene habits. Responses were collected over 2 months. Participants accessed the final questionnaire via a link in the emails and information in the Messenger application. Data were collected using a specially prepared Google Forms questionnaire. Consent was implied upon completion and submission of the questionnaire. Submitted surveys were collated in a directory and de-identified prior to analysis. Statistical analysis was performed based on R package version 4.1.2 and RStudio environment version 2022.12.0.

Results

569 people aged 18-75 took part in the survey, including 139 men and 430 women. The vast majority of respondents adhere to the proper principles of oral prophylaxis, but less than half of the respondents admitted that the source of information on oral health is a dentist. For over 37% it is a family member, a TV commercial, rarely a school, while 12% of respondents have never received such information. A significantly greater share of electric and sonic toothbrushes was observed compared to manual brushes, but an important determinant of the level of pro-health awareness, i.e. regular flossing, turned out to be a permanent element of daily oral hygiene for only a quarter of the respondents. The role of fluoride in the prevention of caries, based on the research results, is unsatisfactory.

The conducted statistical analysis showed that sociodemographic factors had a significant impact on the behavior and pro-health awareness of the surveyed population.

Conclusions

Oral health knowledge among study population appears to be insufficient (despite some improvement when compared with the results of other Polish studies). It is necessary to introduce more comprehensive programmes of oral health education in schools and dental offices.

[1707] Evaluation of the course of the inferior alveolar canal in relation to the roots of fully and partially impacted lower third molars on Cone Beam Computed Tomography

Authors: dr med. Anna Pogorzelska [1], Mike Lee [2], prof. dr hab. med. Kazimierz Szopiński [1], dr med., inż. Piotr Regulski [1]

Affiliation: [1] Department of Dental and Maxillofacial Radiology, Medical University of Warsaw, [2] Students' Scientific Circle "Paralaksa" at the Department of Dental and Maxillofacial Radiology, Medical University of Warsaw

Trustee of the paper: dr med. Anna Pogorzelska

Corresponding author: Mike Lee (s079670@student.wum.edu.pl)

Introduction

Impacted mandibular third molars are frequently encountered in dentistry, as extraction is often the treatment of choice, knowledge of the proximity and relationship of the inferior alveolar canal (IAC) with the tooth is essential. Iatrogenic damage to the inferior alveolar nerve during surgical treatment may lead to temporary or permanent neurosensory disturbances. The rise in popularity of Cone Beam Computed Tomography (CBCT) in dentistry allows us to evaluate the tooth and its surroundings in a 3-dimensional view, and is often employed as an additional examination when an intimate relationship between the tooth and IAC is seen on a pantomogram.

Aim of the study

This study aims to determine the course of the inferior alveolar canal in impacted lower third molars using CBCT, and evaluate if there are any factors associated with the positioning of the canal in relation to the root.

Materials and methods

In this retrospective study, CBCT images from 100 patients (39 males and 61 females, mean age 37 years, range 22-82 years) with 140 impacted lower third molars from the period of 2016-2017 meeting the inclusion criteria (complete root development or $\frac{3}{4}$ length, field of view including the second and third molar with the IAC) were evaluated. The number of roots, type of impaction (using Winter's classification), positional relationship of the IAC in relation to the roots (lingual, buccal, inferior, in between roots), and shape of the canal (round, oval, teardrop, dumbbell) were examined.

Results

The most common type of impaction was mesioangular, two-rooted molars. Most often the canal runs below and in contact with the root, and the canal is most commonly oval-shaped. The type of impaction and the number of roots did not depend on gender. Single-rooted ($p = 0,025$) and distoangularly ($p = 0,019$) impacted molars were more statistically common in older age. There was a statistical relationship between the number of roots and the canal running in between the roots ($p < 0,0001$). There was no relationship found between the shape of the IAC with the number of roots and type of impaction.

Conclusions

Based on the results, the interesting correlation between age with type of impaction and the number of roots requires further investigation and explanation. The lack of statistically significant factors associated with the positioning of the canal and the high frequency of canals in contact with the root in our study emphasizes the importance of CBCT imaging for pre-operative visualization.

[1727] Retrospective assessment of the presence and stage of development of third molar buds based on dental radiographs of children aged 3-18 in the Polish population

Authors: Anna Pogorzelska, Anna Grochowska, Mariusz Gołębiowski, Kazimierz Szopiński

Affiliation: Department of Dental and Maxillofacial Radiology, Medical University of Warsaw, Warsaw, Poland

Trustee of the paper: dr n. med. Anna Pogorzelska, prof. dr hab. med. Kazimierz Szopiński

Corresponding author: Anna Grochowska (agrochowska26@wp.pl)

Introduction

Knowledge about the exact development of third molars has wide application in various fields of science. Therefore, many studies have been carried out on this subject in different countries.

Aim of the study

The aim of the present study was to establish the age of the third molars' appearance and to determine the stage of development of these teeth in patients of a certain age in Poland.

Materials and methods

We conducted a retrospective study based on the analysis of the dental radiographs of children aged 3-18 years which were performed at the Department of Dental and Maxillofacial Radiology of the Medical University of Warsaw in 2018. We have qualified 984 dental radiographs of patients (493 males and 491 females). Developmental stages of the third molars were based on the 13-grade modified Moorrees classification. Dental radiographs were evaluated by two researchers.

Results

It has been noted that the buds of the third molar appear at the earliest at age of 6. The left mandibular third molar is most often visible at this age. The bud in the 1st stage was noticed in a 14-year-old patient at the latest. Third molars occur with similar frequency in both sexes and are 10.1% more common in the mandible than in the maxilla. At the age of 6-8, the most common developmental stage is stage 1. At the age of 9/10, the most common developmental stage is stage 3. At the age of 11-13, the most common developmental stage is stage 5. At the age of 14/15, the most common developmental stage is stage 8. At the age of 16/17, the most common developmental stage is stage 9. At the age of 18, the most common developmental stage is stage 11.

Conclusions

This is the first study assessing the developmental stage of the third molar bud among the Polish population. Based on the obtained results, we can more accurately estimate the age of the child by analyzing the dental radiographs, which can be useful, for example, in forensic medicine. Moreover, in patients aged 15 and more without the third molar bud visible on the radiograph, there is a higher probability that this patient has a lack of this bud at all. The above conclusions may help in planning orthodontic and surgical treatment, which will result in a better health effect for the patient.

[1756] Influence of mixing technique of alginates on dimensional changes

Authors: A. Szczepanik, J. Brulińska

Affiliation: Medical University of Warsaw / Dentistry Division

Trustee of the paper: M. Szerszeń

Corresponding author: Aleksandra Szczepanik (szczepanik.ola@interia.pl)

Introduction

Alginate masses are the basic impression materials used in dental offices. Due to the conditions present in surgeries and the available instrumentation, doubts have arisen about the effect of the mixing method on the dimensional change of alginates. The existing two options assume mixing the mass manually or using specially designed devices (automatic or semi-automatic mixers). The methods differ in the time of compounding, which translates into setting time and the accuracy of the combination of soluble salts of alginic acid with distilled water.

Aim of the study

The aim of the study was a three-dimensional evaluation of impressions of alginate masses depending on the mixing technique.

Materials and methods

Three different alginate masses (Orthoprint, Neocolloid, Hydrogum 5; Zhermack SpA, Badia Polesine, Italy) were used in the study. A total of 42 identical impressions of the toothed training model (ANA4, Frasaco GmbH, Tettang, Germany) were made using the NS-ASA tool standardizing the position of the tooth model in relation to the impression tray. The test material was divided according to the alginate mass used and the method of mass preparation (manual or using an automatic alginate mixer). Then, a series of scans was performed immediately after releasing the impression from NS-ASA tool and after 7 days, using a laboratory scanner (E3, 3Shape, Copenhagen Denmark). Impressions were kept individually in string bags without external sources increasing the ambient humidity. The obtained three-dimensional images were divided into groups depending on the method of mixing and the type of powder used and then exported from the native software in the form of DICOM files. Using the superimposition option of the graphic software, deviations were calculated on the 1st day and 7 days after the impression was made. The data obtained in this way were subjected to statistical analysis (PQStat v.1.8.4.; PQStat Software, Poznan, Poland).

Results

Twenty-five percent of measurements were taken, based on which a trend is evident, indicating a smaller change in spatial dimensions over 7 days for impressions made with compound mixed by an automatic mixer. The largest difference in measurements occurred in the distance between the first molar and the canine (0.465mm), and the smallest between the two central incisors (0.031mm).

Conclusions

The automatic mixer significantly speeds up clinical work, as it takes 6-8 seconds to obtain the mass. This translates into volumetric changes in the alginate mass regardless of its type.

[1760] Estimation of chronological age and aesthetics based on smile appearance

Authors: Monika Bąk; Aliaksei Babko

Affiliation: Medical University of Warsaw, Student Research Group at the Department of Conservative Dentistry of the Medical University of Warsaw SKN supervisor - Ewa Rusyan, MD, PhD, e - mail: erusyan@wum.edu.pl

Trustee of the paper: lek-dent. Magdalena Sobecka-Frankiewicz

Corresponding author: Monika Justyna Bąk (monikabak-98@wp.pl)

Introduction

There are many methods of chronological age estimation. Most methods are time-consuming and invasive (collecting of samples, irreversible destruction of tissues) or require radiation exposure. This often excludes the possibility of their clinical application. The study was to determine the possibility of estimating the age and aesthetics basing on the smile analysis and correlation between age and smile aesthetics. Study can contribute to creating simple, non-invasive for patient tool useful in dentistry, anthropology and criminology. In addition, proving that smile is very important for age estimation and attractiveness can be a convincing argument for patients to take care of teeth and oral health.

Aim of the study

The aim of the study is to find answers to the questions:

- 1) Is it possible to estimate chronological age strictly basing on smile appearance?
- 2) Are there any differences in estimating of chronological age between professionals and the group of people who are not related to dentistry profession basing on smile appearance?
- 3) Are there any differences in estimating of teeth aesthetics between professionals and the group of people unrelated to dentistry profession?

Materials and methods

The study included photographic images of 20 randomly selected patients of different ages covering the range of lips in a free smile and natural teeth, with the maximum limitation of the visibility of other facial structures. The photos were numbered and presented anonymously to 228 study participants, assigned to 4 research groups: students of dentistry, dentists, people related to dental profession other than dentists and people unrelated to the dental profession. The respondents were asked to subjectively estimate the age and level of aesthetics on a scale 1-5.

Results

The study involved 228 participants: 54 dentists, 51 students of dentistry, 52 people related to dental profession and 71 people unrelated to dental profession. Most of the participants in all groups misestimated the age of patients with a tendency to underestimating. There is no correlation between groups in age and the esthetics estimating. Esthetics of the smile was estimated rather low (2-3) in all cases.

Conclusions

It is difficult to estimate age basing just on the smile appearance. The estimation of the smile appearance in Polish society is rather low. There is no correlation between age and a level of esthetics.

[1817] Comparison of System Requirements and Friendliness of User Interface in different Software for Guided Dental Implant Planning

Authors: Andrzej Sołtyk, Parham Motamedi, Marcel Mierzwiński, Aleksandra Orlańska

Affiliation: SKN przy Zakładzie Propedeutyki i Profilaktyki Stomatologicznej WUM

Trustee of the paper: Łukasz Zadrożny DDS PhD, Jaafar Abduo BDS PHD

Corresponding author: Andrzej Sołtyk (soltykandrzej@gmail.com)

Introduction

CAD/CAM technologies provide new possibilities in modern dentistry. Digital planning of different dental procedures improves diagnostics, however designing and 3D printing of templates which transfer virtual planning to the clinical conditions has even higher impact on the whole treatment. There are different software providing various possibilities which have different requirements for its application for dental implant surgery planning. That makes difficulties especially for young dentists to make a decision which software to choose to start planning and performing navigated surgeries.

Aim of the study

To evaluate hardware requirements of eight popular software. Additional goal was to evaluate user friendliness of one paid and one free available software by dental students without previous experience in using such a software.

Materials and methods

Eight implant planning software were found. Based on the information provided by manufacturers comparison of hardware requirements and pricing for each software were done. DentiqGuide (DG) and BlueSkyPlan (BSP) which offer free analysis of two cases were further used to be tested by 4 students. Presentation about planning and designing guided implant surgeries was given to the group. Then, data and instruction for planning implant procedure at the prepared training model were provided to the students. Task included data importing, virtual wax-up designing, positioning 5 implants and designing one temporary crown and surgical stent, then preparing planning report in both software. User friendliness of performing each step was evaluated using Likert scale from 1 to 10 and time of each step was measured. Data were analyzed statistically.

Results

Performed test has shown that paid software DG has lower system requirements than available for free BSP. Time used in the first one mentioned was much shorter and all users agreed that work with DG was easier and more user friendly than with BSP.

Conclusions

Analyzed software provides users similar possibilities in terms of crucial planning functions. Differences were found in the available components, range of virtual libraries, and user friendliness during operation. However, accessibility to some software is limited by its costs and hardware requirements. Then, when expensive software offers unlimited cases to be plan, on the other hand, free or cheaper ones may provide an available for young dentists option to start with modern surgical planning and using all benefits of navigated surgeries.

[1829] Prevalence of pulp stones in children

Authors: Anna Pogorzelska, Parham Motamedi

Affiliation: Medical University of Warswa/Oral and maxillofacial radiology of WUM

Trustee of the paper: Anna Pogorzelska

Corresponding author: Parham Motamedi (parham96motamedi@gmail.com)

Introduction

Pulp stones are common foci of calcification in the dental pulp. Pulp stones are more frequently encountered in dentin dysplasia, regional odontodysplasia, Ehlers-Danlos syndrome, caries, in heavily restored teeth, and after dental trauma.

Aim of the study

To determine the prevalence and distribution of pulp stones in the posterior teeth in the pediatric population.

Materials and methods

In this retrospective study, 100 panoramic radiographs of patients to the University Dental Center of the Medical University of Warsaw from January 2018 to March 2018 were reviewed. Presence or absence of pulp stones and their associations with sex, side, distribution in the dentition, and dental status were noted.

Results

Pulp stones were seen in 21% (21/100) of the examined patients, in 5.42% of examined teeth (112/2068). Pulp stones were found in 10.54% (33/313) of the primary teeth and 4.50% (79/1755) of the permanent teeth.

The first permanent molars represented 65.82% of all affected permanent teeth (46.43% of all primary and permanent teeth) and the second primary molars represented 63.64% of all affected primary teeth (18.75% of all primary and permanent teeth). The pulp stone prevalence in maxillary permanent teeth than in mandibular ones, and higher in the mandibular primary teeth than in the maxillary ones. Pulp stones occurred more often on the right side (52.67%). Fifty-three percent of the affected subjects had pulp stones in more than one tooth.

Conclusions

Pulp stones depending on their place and their size can block access to the canal openings and thus complicate root endodontic treatment. Knowledge of their prevalence in primary and secondary dentition may improve the quality of root canal treatments and prevents possible endodontic difficulties.

[1860] Influence of implant scan body installation torque on the accuracy of digital workflow for implant prostheses preparation.

Authors: Aleksandra Orlańska, Weronika Zaborowska, Wojciech Grodzki, Przemysław Zamojski

Affiliation: SKN przy Zakładzie Propedeutyki i Profilaktyki Stomatologicznej WUM, Wydział Mechaniczny Politechnika Białostocka

Trustee of the paper: dr n. med. Łukasz Zadrożny, dr inż. Rafał Molak

Corresponding author: Aleksandra Izabela Orlańska (s079141@student.wum.edu.pl)

Introduction

As intraoral scanning (iOS) use is gaining ground in modern dentistry, newer and more precise scanners appear on the market. Despite iOS precision growing, there are still problems with their accuracy, mainly in whole arch implant supported cases. In digital workflow, providing the laboratory with precise intraoral implant position requires the use of a scan body (SB) made of different materials and designs, which is secured onto the implant with a screw. Manufacturers recommend either hand-tightening the scan body onto the implant/implant's abutment or using torque ratchets or electronic drivers with 5 or 10 N/cm to control the torque, depending on the system. However, the literature says that torque applied by hand differs between clinicians and can reach up to 25 N/cm.

Aim of the study

The study set out to determine whether forces applied while fastening different SB cause their distortions, thereby leading to intraoral scans of lesser accuracy.

Materials and methods

10 samples (SB-implant) from 3 implant systems - Osstem (O), Thommen Medical (TM), MegaGen (MG) - were tightened with electronic torque driver (e-Driver). SBs differed in scan region shape, body size and base shape corresponding to the implant connection design. Connections were flat (TM) or conical 7 degrees (MG) and 11 degrees (O). The torque for securing analysed SB began at 5 and was increased by 5 N/cm reaching 25N/cm. Contactless measurement of SBs line distortions and surfaces' deformation fields were obtained with Digital Image Correlation (DIC) method using Aramis 3D 5M software.

Results

Initial testing showed onset of distortions to begin with implementation of a 25N/cm torque. Then, test with 25N/cm compared 3 groups (O, TM, MG) of 5 samples each. Difference between groups is implant/SB connection design. Absolute line distortion values of all samples were 0,0015-0,0059mm (TM), 0,0031-0,0119mm (MG) and 0,0011-0,0038mm (O). Samples of each system behaved notably differently, exhibiting mainly shortening (O) or first shortening followed by lengthening (MG). Deformation field map of scan bodies surface showed local deformations to be homogenous.

Conclusions

Initial testing showed onset of distortions to begin when 25N/cm torque was applied. Despite literature suggesting this force can be reached by clinicians during hand-tightening of SB, obtained distortions aren't significant enough to detrimentally affect scanning precision. There is need to further investigate potential reasons affecting accuracy of intraoral scanning.

Dermatology & Allergology

Date: 21st April 2023, 10:00 AM

Coordinators:
Anna Rapiejko
Malwina Wojtas

Patronage:

Konsultant krajowy ds. dermatologii i wenerologii:
prof. dr hab.n.med. Joanna Narbutt
Konsultant Krajowy ds. Alergologii : prof dr hab.n.med. Karina Jahnz-Różyk

[1665] The relationship between BMI, reaction severity and tryptase concentration in patients with allergy to hymenoptera venom.

Authors: Magdalena Czyczerska, Adam Kalinowski, Martyna Klimek, Anna Salamon, Aleksandra Śledziewska

Affiliation: Medical faculty, University of Opole

Trustee of the paper: Prof. Zenon Brzoza MD, Ph.D.; Łukasz Moos MD^[1]_[SEP]

Corresponding author: Aleksandra Maria Śledziewska (masledziewska@gmail.com)

Introduction

Allergy is an excessive, abnormal reaction of the immune system to foreign allergens. Insects whose venom cause allergic reactions in Central Europe usually come from the order of Hymenoptera. An anaphylactic reaction is a complex process. The risk of its development and severity of its course depend on various factors. Increased tryptase levels are among the risk factors for a severe allergic reaction. Literature studies indicate that elevated levels of tryptase may occur in people with BMI > 30.0, which could suggest a greater degree of reaction severity (SYS) following a hymenoptera sting in people with allergies.

Aim of the study

Assessment of the relationship between BMI and SYS values as well as tryptase concentration in patients allergic to Hymenoptera venom. The knowledge of risk factors for allergic reactions may allow to avoid severe systemic reactions in the future.

Materials and methods

Medical records of 72 patients with symptoms of hypersensitivity to the venom of hymenoptera referred to the Opole University Hospital from the 2018-2021 period were analyzed. The data from the history and the results of additional tests were obtained. The symptoms of hypersensitivity were classified according to the Mueller scale.

Results

Increased levels of tryptase were observed in the older age group of patients. There was no statistical difference between people with abnormal BMI values and those with normal BMI values in terms of the severity of the systemic reaction. There was no correlation between the tryptase concentration and the severity of symptoms following the sting.

Conclusions

In our research, no direct relationship between the BMI value, the severity of the reaction and the concentration of tryptase in patients allergic to Hymenoptera venom was found. It should be borne in mind that the role of overweight and obesity in the development of allergic diseases is still being investigated.

[1713] Importance of the ABCA4 gene in physiology and pathology of skin epithelial cells

Authors: Krzysztof Łuszczynski*, Marcin Radziszewski, Marta Soszyńska, Michał Komorowski, Aneta Ścieżyńska

Affiliation: Medical University of Warsaw, Department of Histology and Embryology, Chałubińskiego 5 street, 02-004 Warsaw

Trustee of the paper: dr n. med. Aneta Ścieżyńska

Corresponding author: Krzysztof Łuszczynski (krzysztof.luszczynski99@gmail.com)

Introduction

ABCA4 gene encodes an ATP-binding cassette transporter which translocates retinoid intermediates of the visual cycle. ABCA4 gene mutations are the cause of a spectrum of ABCA4 retinopathies, with the most common juvenile macular degeneration called Stargardt disease. ABCA4 has been regarded as photoreceptor-specific gene, but recent data revealed its expression also in other tissues i.e. skin and hair follicles cells.

Aim of the study

Main aim of this study is to investigate the possible role of the ABCA4 gene in physiology of skin epithelial cells.

Materials and methods

All experiments were performed on human keratinocytes isolated from skin explants. In cultured keratinocytes ABCA4 gene silencing was performed with use of double Ambion® Silencer Select SiRNA. Cell stimulations were performed with use of 10uM all-trans-Retinal and 1uM Retinoic acid solutions. Cell proliferation rate was measured directly with automatic fluorescent cell counter. Keratinocyte differentiation rate was evaluated with use of specific markers at mRNA and protein level via qRT-PCR or Western Blot, respectively. Cellular localisation of the ABCA4 gene was evaluated with use of the confocal microscopy. Lipofuscin was visualised during staining with Sudan Black.

Results

Cells stimulation with all-trans Retinal, but not Retinoic-acid, significantly enhance ABCA4 gene expression at mRNA and protein level. Proliferation rate of keratinocytes observed after stimulation with Retinoid Acid showed a slight decrease, on the other hand all-trans Retinal induced a great reduction of cellular proliferation. Both Retinoid Acid and all-trans Retinal influenced keratinocytes differentiation. ABCA4 gene silencing slightly decreased proliferation rate. Surprisingly after gene silencing all-trans Retinal impact on keratinocyte's proliferation and differentiation was lowered. ABCA4 gene silencing influenced differentiation rate of keratinocytes. Immunostaining revealed close localisation of the ABCA4 gene and the endoplasmic reticulum. Lipofuscin concentration slightly increased after Retinoic Acid stimulation and significantly after all-trans Retinal.

Conclusions

According to the acquired data, we show for the first time, involvement of the photoreceptor-specific ABCA4 gene in the physiology of the human skin cells. This study was supported by the National Science Centre, Poland grants no. 2016/23/N/NZ5/02588 and Medical University of Warsaw Grant no. 1M15/1/M/MBS/N/21/21 and 1M15/2/M/MG/N/21/21

[1975] Insight into antibiotic prescription tendencies for acute asthma exacerbations – results of the Polish part of the EAACI survey

Authors: Anna Rapiejko 1, Anne-Lotte Redel 2, Katarzyna Moliszewska 1, Paweł Kukielka 1, Gerdien Tramper-Stranders 2,3, Wojciech Feleszko 1, the EAACI Task Force on Conscious and Rational Use of Antibiotics in Allergic Diseases

Affiliation: 1. Dept of Pediatric Pneumonology and Allergy, Medical University of Warsaw, Warsaw, Poland; 2. Dept of Pediatrics, Franciscus Gasthuis & Vlietland, Rotterdam, the Netherlands; 3. Dept of Neonatology, Erasmus Medical Center-Sophia, Rotterdam, the Netherlands

Trustee of the paper: dr hab. n. med. Wojciech Feleszko

Corresponding author: Anna Agnieszka Rapiejko (ania.rapiejko@gmail.com)

Introduction

Acute asthma exacerbations (AAE) are treated with an intensity appropriate to their severity, including bronchodilators and systemic steroids. Little evidence supports the empirical use of antibiotics in AAE, as bacterial infections are estimated to be responsible for only a minority of exacerbations.

Aim of the study

The study, as a part of the international survey led by the European Academy of Allergy and Clinical Immunology, aimed to assess tendencies in prescribing antibiotics to patients with AAE in Poland.

Materials and methods

The online survey, designed by the EAACI Task Force at Castor EDC, included questions on health care provider demographics and questions to explore influencing factors and antibiotic prescription rates. The questionnaire, translated into Polish, was distributed by email and in person to physicians across the country in late 2022 and early 2023.

Results

The survey was completed by 93 physicians representing different specialisations; mainly paediatricians (30,1%), allergists (20,4%), pulmonologists (20,4%), general practitioners (19,4%). Ninety respondents made a diagnosis of AAE within a month before completing the survey. In 20% (median; IQR=0-46%) of cases antibiotics were prescribed, the international results indicated 18% (median; IQR=0-33%). Over half of participants (57%) believed they prescribe antibiotics in AAE less frequently than their colleagues. Indeed their prescription rates were lower (median 10%; IQR:0-33%). In the international results this declaration was at 73.2%. Physicians mostly prescribed macrolides (52%) and penicillins (41%), mainly for 7 days. Results for antibiotic classes resembled the international results. Among the symptoms leading to prescribing antibiotics, the most frequent were purulent sputum, reductions in lung sound or crackles, temperature >38,5°C, comorbidities. Before prescribing antibiotics in AAE, 77% of participants would perform additional diagnostic tests, mainly inflammatory blood parameters or X-ray. 89% of respondents are aware there is no strong, reliable evidence in the literature to support the use of antibiotics in AAE. 80% of them are convinced that there are no national guidelines for prescribing antibiotics to patients with AAE.

Conclusions

Physicians' antibiotic prescribing practices in AAE varied. Most participants are aware there is a lack of strong evidence for the beneficial effect of antibiotic treatment in AAE. They emphasize the lack of clear guidelines for a rational antibiotic prescribing policy for patients with AAE.

[1802] Erysipelas: A benign condition or a deadly threat? A case report study

Authors: Konrad Kaleta, Asst. Prof. Andrzej Jaworek

Affiliation: Jagiellonian University Medical College / Dermatology Clinic

Trustee of the paper: Asst. Prof. Andrzej Jaworek

Corresponding author: Konrad Kaleta (konrad.kaleta@student.uj.edu.pl)

Background

Infectious skin diseases pose a significant medical challenge, with approximately 300 million cases reported worldwide each year. One such disease, Erysipelas, caused mainly by *S. pyogenes*, is a common global health burden that primarily affects elderly people and patients with poor health status. Despite improvements in healthcare standards, Erysipelas remains a serious problem for modern medicine. Unfortunately, many medical professionals fail to recognize the severity of the disease. However, the potential for systemic complications during its course, coupled with the uncontrolled outbreak during the COVID-19 pandemic, serves as a reminder of its dangerous nature.

Case report

A 49-year-old female patient with class III obesity (BMI 40.62) was admitted to the Dermatology Clinic due to her second episode of bullous erysipelas on the lower right leg within one year. The patient had been undergoing Adalimumab therapy for ankylosing spondylitis at the time of admission. The patient's medical history included symptoms of 39-40 °C fever, chills, vomiting, excessive heat, and edema in the affected leg. Outpatient treatment comprised amoxicillin with clavulanic acid 2 times a day. In laboratory studies: procalcitonin 2.65 (N<0.5), CRP 261 mg/l (N<5.0), hemoglobin 11.9. Blood cultures that were checked 2 times during hospitalization were negative. The culture test from the skin lesion revealed *E. faecalis* species and dalbavancin treatment (1500 mg IV) was included. Initially the improvement in general status with alleviation of inflammatory parameters (CRP < 41.5 mg/l) was observed. On the 17th day of hospitalization, after reaching CRP below 10 mg/l, a sudden deterioration in general condition occurred including increase in the body temperature to 38 °C, shivering, rise in CRP (34.1 mg/l) and pain of the lower extremity. A positive result for SARS-CoV-2 was obtained. The therapy with several antibiotics was enriched by 2x100 mg of LMWH. A new culture test performed from the lesion on patient's foot revealed *P. Aeruginosa* and yeast-like fungi which resulted in gentamicin inclusion. On the 25th day of hospitalization the SpO2 decreased to 77% and patient died after transport to intensive care unit.

Conclusions

Recurrent erysipelas in this patient may have contributed to a fatal course of SARS-CoV-2 infection. The development of a *P. Aeruginosa* superinfection was critical in determining this outcome. Erysipelas in some circumstances may be fatal and should never be understated.

[1804] „12 cm squamous cell carcinoma skin tumor of the scalp”

Authors: Michał Zygarowicz

Affiliation: Students' Scientific Group of Multidisciplinary Oncology 'Onkosfera', Department of Soft Tissue/Bone Sarcoma and Melanoma, Maria Skłodowska-Curie National Research Institute of Oncology in Warsaw

Trustee of the paper: Prof. Anna Czarnecka MD, PhD

Corresponding author: Michał Zygarowicz (m.zygarowicz@o2.pl)

Background

Squamous cell carcinomas (SCC) of the skin comprise about 20% of all nonmelanoma skin cancers (NMSC) and are estimated to have an incidence of 700 000 new cases per year in the US. Cutaneous SCC is the more aggressive form of NMSC than basal cell carcinoma, however, 5-year survival after diagnosis is over 90%. Distant metastases are present in only 3-5% of cases, but they are related to poor prognosis. Diagnosis of SCC is based on the excisional biopsy when is possible or a partial biopsy in other cases. Treatment usually aims for surgical removal of the lesion and follow-up for recurrence, but other modalities such as immunotherapy and radiotherapy are also available.

Case report

A 76-year-old woman was diagnosed with a skin tumor of the scalp measuring 12 cm by 8 cm with ulceration, which had been growing dynamically for a year. The biopsy performed 26th May 2022 showed it to be SCC. Moreover, computed tomography imaging showed hypertrophy of the thyroid gland to the mediastinum, which displaced the trachea to the right side, no other abnormalities were found. She was offered treatment by excision of the skin tumor and plastic surgery with a skin graft from the groin. Despite the initial consent, she ultimately did not consent to the operation. In this situation, with no ability for radiotherapy, after consulting a clinical oncologist, she was qualified for treatment with anti-PD-1 drug - cemiplimab. From 28th July 2022 to 8th February 2023, she took 9 infusions of cemiplimab with one dose missed due to features of pneumonia, which later resolved before the next dose. From the fifth infusion, a gradual remission of the scalp tumor was observed, but the CT scan at the eighth infusion suggested an 8 mm nodule in the apex of the left lung. Hyperactive nodular goiter was treated with thyrostatic tiamazol with good tolerance and therapeutic effect.

Conclusions

This case shows how large an SCC skin tumor can grow when the patient reports to the doctor very late. Despite the “gold standard” of therapy, which is complete excision of the lesion, sometimes therapy must be limited to the administration of systemic therapy due to the patient's refusal to consent to the excision of the lesion.

[1835] Unusual manifestation of hematopoietic malignancy

Authors: Natalia Sak, Przemysław Hałasiński

Affiliation: Students' Scientific Association of Dermatology and Aesthetic Dermatology of the Department of Dermatology, Poznan University of Medical Science

Trustee of the paper: Katarzyna Waligóra MD

Corresponding author: Natalia Sak (natalia.sak@onet.pl)

Background

Purpura lesions occur as a result of erythrocytes penetrating the vascular walls into the dermis. They can be caused by hematological disorders, increased venous pressure or vascular damage due to inflammation. They occur five times more often in men than in women. A rare cause of their occurrence can also be cancers including multiple myeloma, in which there is an excessive proliferation and accumulation of plasma cells. It accounts for 1% of all malignancies. It occurs slightly more often in men, and the peak incidence is in the 7th decade of life. Typical symptoms are anemia and immune dysfunction, progressive renal failure, increased predisposition to thrombosis, gradual bone destruction.

Case report

A 72-year-old patient with suspected vasculitis was admitted to the Dermatology Department for treatment of skin lesions. The lesions were present on the lower extremities, upper extremities and trunk. In addition, petechial lesions were present in the throat. The patient had comorbidities: hypertension and mixed hypercholesterolemia. The patient had a radical prostatectomy and radiation therapy for prostate cancer in 2004. Upon admission, the patient was ordered consultations in rheumatology, otolaryngology, urology, tropical and parasitic diseases, hematology, dentistry, nephrology. Imaging examinations were performed: chest X-ray, abdominal ultrasound, ultrasound of neck lymph nodes, Doppler ultrasound of lower extremity veins, skull X-ray, ultrasound, thyroid. A skull X-ray revealed an osteolytic focus of 5 mm in size. Laboratory tests performed revealed the presence of monoclonal protein, IgG paraprotein lambda chains, in addition, free lambda chains present and elevated CRP. Due to the presence of monoclonal protein, a blood and marrow smear was performed for cytological evaluation. A flow cytometry study was performed, based on which the suspicion of plasmocytic myeloma was raised. The bone marrow preparation is undergoing histopathological evaluation.

Conclusions

Purpura is a common symptom seen in dermatology outpatient clinics. Purpura lesions present diagnostic difficulties due to the many possible etiologies of these lesions. Attention should be paid to interdisciplinary cooperation of specialists to make a correct diagnosis and determine an appropriate treatment regimen.

[1899] The case report of immune related toxicities during immunotherapy of melanoma

Authors: Maria Kleczkowska

Affiliation: Students' Scientific Group of Multidisciplinary Oncology 'Onkosfera', Department of Soft Tissue/Bone Sarcoma and Melanoma, Maria Skłodowska-Curie National Research Institute of Oncology in Warsaw

Trustee of the paper: Professor Anna Czarnecka

Corresponding author: Maria Magdalena Kleczkowska (marysia.kleczkowska1@wp.pl)

Background

Melanoma is a rapidly increasing worldwide skin cancer originating from melanocytes. The typical cause is the exposure of skin to ultraviolet light, however familiar history and genetic susceptibility also play a role. Immunotherapy is a revolutionary treatment in both the adjuvant and metastatic settings, but its use is often restricted by immune-related toxicity. The objective of this clinical case is to describe the early management of drug-induced toxicities using ASCO and ESMO guidelines as well as to emphasise the importance of early diagnosis and treatment of drug-induced complications.

Case report

A seventy-one-year old patient with BRAF-negative skin melanoma of epigastric region with unresectable metastases to the lungs, subcutaneous tissue and CNS (suspicion) started immunotherapy with nivolumab 240mg on 24.05.2021. After 2 courses of immunotherapy, he developed dyspnea and angina pectoris which significantly limited his exercise tolerance, suggesting exacerbation of existing coronary artery disease. This was followed by a non-ST segment elevation myocardial infarction, treated with marginal venous bypass angioplasty with DES stent implantation. Due to these events, immunotherapy treatment was discontinued for 8 weeks. It was later resumed and continued for 12 courses, during which there were incidences of thyroid dysfunction, hepatitis and colitis. The thyroid dysfunction was treated with Tiamazol between 21.06.2021 and 20.07.2021, being terminated due to the development of a hypoactivity phase of thyroiditis. The hepatitis, with AST/ALT values being graded in the ASCO guidelines as G2/3, was treated with Prednizone starting on 12.07.2021, with a dose reduction on 27.07.2021 and normalization of AST/ALT on 09.11.2021. The colitis was treated with Loperamide between 23.02.2022 and 05.12.2022. The development of those toxicities resulted in the termination of immunotherapy with Nivolumab on 30.05.2022 with the result of PD according to the RECIST scale.

Conclusions

This case highlights the necessity of multidisciplinary melanoma care as well as observing and dealing with early drug-induced complications, which enables the patient to continue therapy and might be crucial while preventing life-threatening situations.

[1929] **Dyskeratosis congenita: A rare congenital disease with diagnostic value of skin biopsy**

Authors: Carolyn Szwed

Affiliation: Department of Dermatology, Medical University of Warsaw

Trustee of the paper: Katarzyna Piszcz, MD, Joanna Czuwara, MD, PhD

Corresponding author: Carolyn Szwed (caroszwed@gmail.com)

Background

Dyskeratosis congenita (DC), also referred to as Zinsser-Engman-Cole syndrome, is a rare inherited disorder that mainly affects males. It is characterized by progressive bone marrow failure, predisposition to cancer and premature aging. Although the disease may produce a variety of symptoms due to its multisystem involvement, it often presents with the classic mucocutaneous triad of abnormal skin pigmentation, nail dystrophy and oral leukoplakia.

Case report

We present two patients diagnosed with DC. The first patient, a 9-month-old boy with hyperpigmentation on the face, trunk and extremities. The changes first appeared in the second month of life. Family history was positive for psoriasis. Laboratory tests showed eosinophilia and mild thrombocytopenia. Antinuclear antibody was negative. Skin prick tests were negative. No changes were observed in the oral cavity. Hydrocortisone and zinc ointments and emollients were used for skin dryness. The second patient, a 7-year-old boy with skin changes in the form of mottled hyperpigmentation on the neck, upper chest and extremities. He also presented nail dystrophy, oral leukoplakia and hyperhidrosis. Family history was unremarkable. Both patients presented hyperkeratosis of the palms and soles. Skin biopsies of both patients revealed subtle features of interface dermatitis and characteristic dyskeratosis.

Conclusions

Most patients present with signs and symptoms of DC before the age of 10 years. Clinicians should suspect DC when classic mucocutaneous triad features can be observed. However, not all features may be present. Awareness of the severity of this infrequent disorder and its possible sequelae is paramount. Prompt diagnosis, which requires laboratory, histopathological and genetic testing, is possible. The dermatologist plays a critical role in the diagnosis and interdisciplinary management of DC.

[1947] Details of pediatric cases of anaphylactic or allergic symptoms in Emergency Department - a single centre study

Authors: Dominika Mamcarz, Anna Złotnik

Affiliation: Medical University of Warsaw/Medical Department

Trustee of the paper: dr n. o zdr. Jan Stachurski

Corresponding author: Dominika Anna Mamcarz (dominikamamcarz@gmail.com)

Introduction

According to raising life standards and 'cleaner' upbringing the number of allergies in children increases every year. There are countless cases of young patients affected by sensitivity for potentially harmless substances in many hospitals worldwide, which can be sometimes a serious challenge for the medical staff.

Aim of the study

The aim of this study was to investigate the details of anaphylaxis and allergy cases in pediatric population, that was examined in the Emergency Department. It was supposed to show the most common characteristics of interventions such as age and sex of patients, their symptoms, implemented pharmacotherapy and date with time of the day(including day of the week) of their arrival to ED.

Materials and methods

In our retrospective study, we analyzed 380 cases, which met the criteria of diagnoses, according to the allergy-related ICD10 codes. We collected patients' history completed by pediatricians from Emergency Department in Pediatric Hospital in Warsaw throughout the calendar years 2020-2021. The medical records contained full informations about patients' condition and steps taken by health personnel. Moreover, complementary data from the pre-hospital actions taken by Emergency Medical Services or by patient's parents, was added.

Results

Months of the year were divided in 4 quarters - I with 107 patients(28%), II with 67(18%), III with 108(28%) and IV with 98(26%). When it comes to days of the week - higher percentage than 15% of arrivals of all week had three groups - 63 patients (16,58%) on Thursday, 64 (16,84%) on Friday and 61 (16,05%) on Saturday. Also, hours were divided in: Group A (before 5:59) with 23 kids, Group B (6:00-11:59) with 73, Group C (12:00-17:59) with 128 and Group D (after 18:00) with 155. 90% of patients came to the hospital by themselves compared to only 10% transported by Emergency Medical Services. In 69(18%) cases patients stayed in hospital. 207 patients took drugs at ED. 131(63%) patients got dexamethazon, 93(45%) Clemastine and 35(17%) Hydrocortisone. The suspicion of the cause of allergy had 137 patients. They were connected with food in 67(49%) cases and drugs in 46(34%) with significant 34 cases after amoxicillin were administered.

Conclusions

Most commonly patients were at the Emergency Department on Fridays, more frequent nightly and in the range of months: July, August and September. Majority of patients came by themselves and weren't hospitalized. The most suspected allergens were related to food and the drug of choice was dexamethazon.

[1958] BRAFi/MEKi rechallenge as efficient therapy of metastatic melanoma

Authors: Arkadiusz Moskwa

Affiliation: Students' Scientific Group of Multidisciplinary Oncology 'Onkosfera', Department of Soft Tissue/Bone Sarcoma and Melanoma, Maria Skłodowska-Curie National Research Institute of Oncology in Warsaw

Trustee of the paper: prof. Anna Małgorzata Czarnecka, MD, PhD

Corresponding author: Arkadiusz Jan Moskwa (amoskwa2001@gmail.com)

Background

Melanomas are relatively rare in Poland – approximately 3800 cases per year. Nevertheless, the incidence is increasing. Therefore, there is still a need to develop the most appropriate approach, especially as another line of treatment.

Case report

Forty-nine year old woman was diagnosed with an expansive BRAF+ melanoma of the right thigh and qualified to a radical surgery accompanied by sentinel node biopsy. In addition, the inguinal-iliac-obturator lymph node dissection was performed and radiotherapy was administered. Half a year later, metastases to the lungs and VIII rib were diagnosed. It was decided to start treatment with vemurafenib (BRAF inhibitor). Two years after the diagnosis, “in transit” metastatic lesions in the soft tissue of the thigh were diagnosed and excised. Due to progression of the disease she started ipilimumab (anti-CTLA-4) one year later and after subsequent progression - pembrolizumab (anti-PD-1). During the next three years, the disease was stable. As 4th line of treatment she was rechallenged with dabrafenib and trametinib (BRAF inhibitors). With this treatment, the patient achieved stable disease for 1.5 years. The patient did not agree to continue treatment, but almost 2 years later due to 20cm wide melanoma with persistent ulceration she started encorafenib and binimetinib (BRAF inhibitors) therapy and achieved partial response.

Conclusions

Rechallenge with BRAF and MEK inhibitors may result in objective response and should be offered to eligible patients.

[3009] Clinical case of oral allergic syndrome in a child with birch allergy

Authors: Daria Yasynovska

Affiliation: Department of pediatrics №2 Bogomolets National Medical University

Trustee of the paper: Assistant Professor Krivopustova Mariia

Corresponding author: Daria Yasynovska ()

Background

The prevalence of oral allergy syndrome in children varies considerably, depending on the geographical region, and ranges from 4.7% to more than 20% (Carlson, G., et al 2019). Pollen-food syndrome is an immunoglobulin E-mediated immediate allergic reaction that occurs after eating fruits, vegetables or nuts that cross-react with pollen in patients with seasonal allergic rhinitis (Jeon Y. H. 2020). An available etiologic method of treating birch pollen allergy is allergen-specific immunotherapy based on the administration of birch pollen extracts subcutaneously or sublingually to induce tolerance to Bet v1 and the homologous allergen Mal d 1 (Kong, N., et al 2019).

Case report

A 14-year-old boy complained of itching in the mouth, swelling of the lips when eating fresh apples, raw hazelnuts, which appeared 1 year ago (in March) and has not gone away since then. Child has symptoms of allergic rhinitis in spring. In younger childhood, he had manifestations of atopic dermatitis. The family allergic history is burdened - the mother has allergic rhinitis. Skin prick tests revealed a positive result with birch and alder allergens (+++). The boy underwent multicomponent molecular allergy diagnostics - ALEX² test (Macro Array Diagnostics GmbH, Austria): Bet v 1 birch-26.31 kUA/L, Aln g 1 alder-8.11 kUA/L, Cor a 1.0103 hazel-12.99 kUA/L, Mal d 1 apple-22.96 kUA/L, Cor a 1.0401 hazelnut-22.51 kUA/L, Dau c 1 carrot-11.10 kUA/L, Api g 1 celery-5.77 kUA/L, Gly m 4 soybean-16.85 kUA/L, Ara h 8 peanut-16.57 kUA/L. When eating carrots and peanuts, she does not notice any symptoms of oral allergic syndrome. The boy was prescribed a course of allergen-specific immunotherapy subcutaneously with a mixture of trees.

Conclusions

This clinical case emphasizes the relevance of the problem of pollen-fruit syndrome in children, emphasizes the need for its early diagnosis, careful and timely history taking, and the use of modern molecular allergy diagnostic capabilities. This allows for effective therapy using etiologic treatment, preventing more severe clinical manifestations of allergic rhinitis and oral allergic syndrome.

Endocrinology & Diabetes

Date: 21st April 2023, 10:00 AM

Coordinators:
Kinga Dziobiak
Zuzanna Kaczmarczyk

Patronage:

prof. dr hab. n. med. Krzysztof Strojek - Krajowy Konsultant Diabetologii

[1561] SPECT/CT parathyroid scintigraphy in primary hyperparathyroidism: minimizing the risk of negative results by biochemical parameters assessment.

Authors: Karolina Kucharczyk, Anna Drynda, Malgorzata Trofimiuk-Muldner, Alicja Hubalewska-Dydejczyk, Grzegorz Sokolowski

Affiliation: Jagiellonian University Medical College, Department of Endocrinology

Trustee of the paper: Malgorzata Trofimiuk-Muldner, MD PhD

Corresponding author: Karolina Agnieszka Kucharczyk (karolina.qcharczyk@gmail.com)

Introduction

Primary hyperparathyroidism (PHP) diagnosis in clinical practice is based on biochemical blood tests. Since a single parathyroid adenoma causes about 85% of cases, the treatment of choice is parathyroidectomy, preceded by imaging studies. Ultrasound and [99mTc] sestamibi scanning can enable adenoma localization. However, the latter method is of higher sensitivity, especially if combined with anatomical imaging. In some cases, the radiotracer uptake in adenoma tissue is insufficient, leading to negative imaging results.

Aim of the study

This study aimed to compare parathormone (PTH), calcium, and serum phosphate levels among patients diagnosed with PHP with positive and negative parathyroid nuclear hybrid imaging (SPECT/CT) and to evaluate biochemical parameters' ability to predict imaging results.

Materials and methods

563 patients with suspected primary hyperthyroidism (84% females, median age 62 years, IQR 19 years; 16% males, median age 59 years, IQR 25 years) who underwent [99mTc] sestamibi SPECT/CT imaging between 2010 and 2022, were included in this study. Concentrations of preoperative calcium, PTH and serum phosphate were noted.

Results

The imaging result was positive in 257 cases (46%). Patients with positive imaging were characterized by higher PTH (median 124.5 pg/mL vs 96.6 pg/mL; $p < 0.05$), higher calcium (median 2.76 mmol/L vs 2.67 mmol/L; $p < 0.05$), and lower serum phosphate concentrations (median 0.82 mmol/L vs 0.89 mmol/L; $p < 0.05$). Based on ROC analysis, the following threshold values for nuclear imaging were proposed for calcium, PTH, and serum phosphate concentrations, respectively: calcium ≥ 3.11 mmol/L (AUC 0.73; PPV 72%; sensitivity = 37%; specificity = 88%); phosphate ≤ 0.45 mmol/L (AUC 0.65; PPV 55%; sensitivity = 36%; specificity = 79%); PTH ≥ 260 pg/mL (AUC 0,70; PPV 78%; SENS = 33%; SPEC = 92%).

Conclusions

Before offering preoperative hybrid nuclear imaging to a patient with PHP, attention should be paid to the results of biochemical tests to limit unnecessary radiation exposure. Indeed, if calcium and parathormone concentrations are slightly above the upper reference values, the probability of a negative imaging result seems to be high.

[1645] Treatment features of complicated type 2 diabetes mellitus

Authors: Marija Hibner, Vaiva Kaktaitė

Affiliation: Faculty of Medicine, Medical Academy, Lithuanian University of Health Sciences, Kaunas, Lithuania

Trustee of the paper: Aurimas Rapalavičius

Corresponding author: Marija Hibner (marijahibner@gmail.com)

Introduction

Diabetes mellitus is one of the most frequent chronic diseases in the world. Accurately selected medicaments in diabetes aims to reduce the risk of major diabetic complications, including cardiovascular outcomes, retinopathy, nephropathy, neuropathy and overall mortality.

Aim of the study

To evaluate treatment features of complicated type 2 diabetes mellitus

Materials and methods

A retrospective analysis of patients, treated in the Department of Family medicine, Kaunas Lithuanian University of Health Sciences Hospital from 2017 to 2022 was performed. Study population of people who were diagnosed with type 2 diabetes mellitus (DM) with complications including ICD-10 diagnoses E11.0-E11.8 was selected. There were 203 cases analyzed. Statistical analysis was performed using Excel and IBM SPSS Statistics 29 software. Results with values of $p < 0.05$ considered statistically significant.

Results

For treatment of complicated type 2 DM either one, two or three medications were prescribed most often – 37.7 %, 36.3 % and 19.6 % respectively of all the patients. Metformin was used by more than a half of the patients in each different complication group with highest in DM with other specified complication group with 83.9 % usage. Patients prescribed with metformin were on average 10 years younger than the patient group without metformin use: 68.99 (SD = 10.57) and 76.49 (SD = 9.74) years ($p < 0.05$) respectively. Sulfonylureas were most popular in the groups of DM with other specified complication and diabetic polyneuropathy – 42.85 % and 42.55 % respectively. SGLT-2 inhibitors were most often prescribed to the patients with ophthalmic complications – 37.5 % of the cases in this group. GLP-1 inhibitors were used by 23.21 % of the patients with DM with other specified complication. Insulins were most often prescribed to 40 % of the patients with renal complications, 37.5 % with ophthalmic complications and 36 % with multiple complications. HbA1c levels varied in-between groups of patients with different diabetic complications ($p < 0.05$). Higher glycosylated hemoglobin counts were detected in cases where GLP-1 inhibitors, SGLT-2 inhibitors, sulfonylureas, insulins were prescribed ($p < 0.05$). The number of drugs used statistically significantly increases with higher HbA1c levels (correlation coefficient 0.606, $p < 0.05$).

Conclusions

Our study shows that the treatment of type 2 diabetes mellitus is complicated and often requires more than one medication, selected according to age, HbA1c, and complications.

[1653] Primary response in short stature treatment in patients with GHD as a predictor for long-term therapy effectiveness - a retrospective cohort study

Authors: Jan Maciej Kapala, Tomasz Maroszczyk

Affiliation: University of Warmia and Mazury in Olsztyn / Medical Department

Trustee of the paper: Dorota Charemska, MD

Corresponding author: Jan Maciej Kapala (jas.kapala@gmail.com)

Introduction

Short stature in growth hormone deficiency (GHD) can be treated with recombinant human growth hormone (rhGH), which is proven to be both safe and effective. However, a considerable number of patients does not achieve satisfying therapy outcomes.

Aim of the study

The purpose of the study is to evaluate the predictive effect of height increase in the first year of rhGH treatment on long-term therapy outcomes.

Materials and methods

165 short-stature children (mean age 10.72 ± 3.33 years; 63% males), diagnosed with isolated GHD, treated with rhGH for at least one year-long (mean follow-up 4.32 ± 1.80) were included in the study. The patients were divided into two groups according to the Δ height standard deviation score after the first year of rhGH treatment: good responders (GR) and poor responders (PR). Patient's sex, chronological age, bone age, height, weight, insulin-like growth factor 1, and rhGH dose were obtained up to ten years with one-year intervals.

Results

There were no significant differences between the patient characteristics ($p > 0.05$). In the GR group mean height velocity up to five years of observation was 1.19 ± 0.41 /year and in the PR group 0.59 ± 0.38 /year. The differences were significant ($p < 0.05$).

Conclusions

The primary response to the rhGH treatment in GHD children seems to be a good predictor for long-term therapy outcomes.

[1654] Do the rhGH therapy outcomes in GHD children depend on dose size and dosage adjustment? - retrospective cohort study

Authors: Jan Maciej Kapala, Tomasz Maroszczuk

Affiliation: University of Warmia and Mazury in Olsztyn / Medical Department

Trustee of the paper: Dorota Charemska, MD

Corresponding author: Jan Maciej Kapala (jas.kapala@gmail.com)

Introduction

Recombinant human growth hormone (rhGH) is a safe and effective medication for short stature treatment in growth hormone deficiency (GHD). However, the satisfactory rhGH dosing strategy remains a source of controversy.

Aim of the study

Evaluation of the effect of the dose of rhGH and the dosage adjustment on the therapy effectiveness in children with GHD with a long-term follow-up.

Materials and methods

The inclusion criteria gathered 165 short-statured children diagnosed with isolated GHD and treated with rhGH for at least one year-long. Patients were separated into two groups based on the rhGH dose: low dose (LD) and high dose (HD) (cut-off point 0.2 mg/kg/week) and into two additional groups based on the dosage adjustment. Sex, chronological age, bone age, height, weight, insulin-like growth factor level, and rhGH dosage of the patient were all determined at one-year intervals.

Results

Changes between dose groups were significant at almost every stage of follow-up in favor of the HD group ($p < 0.1$). However, there was no significant difference in mean height velocity between the LD (0.44 ± 0.28 /year) and HD (0.44 ± 0.23 /year) groups ($p > 0.1$). For dose adjustment, only the difference between the first and second year was significant, where dose adjustment resulted in increased height (0.34 vs. 0.47) ($p < 0.1$). Subsequent years revealed no significant changes ($p > 0.1$).

Conclusions

Considering the entire period of therapy, high doses of rhGH do not provide any benefit to children with GHD. Controversies regarding dosing strategies in the treatment of short stature need to be assessed.

[1674] Sex-dependant impact of body position on oral glucose tolerance test results in healthy, young subjects

Authors: Maciej Bara, Katarzyna Poreda

Affiliation: Medical University of Warsaw / Department of Internal Medicine, Hypertension and Vascular Diseases

Trustee of the paper: Piotr Abramczyk, MD PhD

Corresponding author: Katarzyna Poreda (poreda.katarzyna@gmail.com)

Introduction

Oral glucose tolerance test (OGTT) is frequently performed during diagnosis of diabetes mellitus (DM) and impaired glucose tolerance in ambulatory and hospital conditions in patients with risk factors. Official guidelines suggest that patient undergoing OGTT should be rested during exam. However, it is not specified whether the patient should remain in sitting or supine position. Blood glucose level and regulation of insulin secretion are under rigid control of sympathetic nervous system, which activity depends on body position and sex. Supine position significantly outbalances sitting position during OGTT in hospitals which could have a great impact on test results and thus lead to misdiagnosis of DM.

Aim of the study

To investigate sex-related blood glucose levels response to the body position in young, healthy adults during OGTT.

Materials and methods

Study was approved by Bioethical Commission. 16 healthy volunteers (age 18-25, males: 8) were enrolled into the study. Each of them underwent OGTT in supine and sitting position with 4 weeks interval in between. First position was selected randomly. Tests were performed in the morning after fasting for at least 12 hours. After 5 minutes of rest in selected position first blood sample was drawn. Afterwards, 75 g of glucose in 300 ml of water was administered orally and another blood samples were drawn in 30th, 60th and 120th minute of OGTT. The blood samples were tested for insulin and glucose concentration.

Results

Glucose tolerance was significantly impaired in supine position in 30th minute in men and in 60th and 120th minute in women. Data is presented as differences between values of glucose or insulin concentration in respectively 30th, 60th, 120th minute and baseline during OGTT in both positions. First value of each pairs means sitting and second supine position. Data is expressed as mean \pm SD. Glucose [mg/dl]: men (28.8 \pm 27.77 vs 41.1 \pm 18.66, p <0.05; 22.0 \pm 28.34 vs 19.4 \pm 9.30, ns; -1.8 \pm 21.61 vs 4.0 \pm 23.13, ns) and women (45.7 \pm 25.53 vs 46.8 \pm 17.33, ns; 17.8 \pm 26.83 vs 33.5 \pm 30.10, p <0.01; 0.8 \pm 20.04 vs 17.6 \pm 29.16, p <0.03). Insulin [mIU/l]: men (41.7 \pm 16.09 vs 47.7 \pm 17.65, ns; 49.8 \pm 32.94 vs 33.1 \pm 19.79, ns; 27.8 \pm 16.62 vs 21.0 \pm 12.82, ns) and women (77.3 \pm 26.08 vs 46.9 \pm 16.05, p <0.02; 56.8 \pm 25.80 vs 40.4 \pm 16.74, ns; 36.0 \pm 14.77 vs 34.3 \pm 14.00, ns).

Conclusions

Impaired glucose tolerance in women in supine position may be related to delay of insulin excretion. Conditions of performing of OGTT especially in women may yield to overdiagnosis of DM.

[1772] Investigation of thyroid involvement in patients treated with primary Raynaud's phenomenon

Authors: Mihály Székely; Gábor Papp; Zoltán Csiki

Affiliation: University of Debrecen, Faculty of Medicine, Department of Internal Medicine

Trustee of the paper: Mihály Székely

Corresponding author: Mihály Székely (mihaly.szekely2@gmail.com)

Introduction

Raynaud's phenomenon (RP) is characterized by the vasospasm of the fingers in response to cold or psychological stress, leading to a characteristic discoloration of the skin color of the fingers. It is caused by an imbalance between vasoconstrictor and vasodilator factors. A distinction is made between primary and secondary forms, the latter associated with various underlying diseases, including autoimmune conditions. As the development of Raynaud's phenomenon may be one of the first clinical signs of a systemic autoimmune disease, early detection and detailed investigation of patients is crucial.

Aim of the study

Our retrospective study focused on analyzing laboratory markers measured in patients suspected of having Raynaud's syndrome and then were followed up.

Materials and methods

Among the patients examined and monitored for suspected primary Raynaud's phenomenon in our department between 2012 and 2022, 216 female (mean age 43.25 ± 15.71 years) patients with known sTSH and vitamin D levels were included in our study after the exclusion of systemic autoimmune disease.

Results

Among the patients studied, 59.26% had a confirmed thyroid involvement (e.g., hypothyroidism, goiter, carcinoma) or an abnormal sTSH level within a mean of 4.72 ± 1.89 years from the date of the first Raynaud's attack. It should be noted that 31.25% of affected patients did not have a history of thyroid disease diagnosed before the first Raynaud's phenomenon. Plasma or serum vitamin D3 levels were below the reference range in a significant proportion of subjects (83.33%).

Conclusions

In the case of RP, detailed thyroid disease screening is essential, as a large proportion of patients have thyroid involvement at first presentation. In addition, the increased risk of developing thyroid disease should be considered during follow-ups. Furthermore, our results suggest that testing of vitamin D3 levels should always be considered in patients with suspected primary Raynaud's phenomenon, and regular oral supplementation is recommended in case of deficiency.

Supported by: NTP-HHTDK-22-0051

[1820] Schmidt's syndrome – Case report

Authors: Lelde Loreta Freidenberga, Kristians Hscanovics

Affiliation: Riga Stradins University, Department of Internal Diseases

Trustee of the paper: Ingvars Rasa

Corresponding author: Lelde Loreta Freidenberga (lfreidenberga@gmail.com)

Background

Polyglandular autoimmune syndrome type 2 (PAS 2) or Schmidt's syndrome is an autoimmune disease inherited by multiple genes. When first discovered, PAS-2 was considered only to entail Addison's disease and autoimmune or Hashimoto's thyroiditis. More research has revealed that the disorder includes other failing endocrine organs such as the gonads, the pancreas, parathyroid glands, and non-endocrine organs, e.g., rheumatologic diseases.

Case report

A 38-year-old man presented to the emergency department in January 2015 with two episodes of unprovoked syncope. After MRI, Holter monitoring, and an EEG, he was diagnosed with orthostatic hypotension and autoimmune thyroiditis with normal thyroid function. TSH 2.21 μ IU/ml (range:0.4-4.0), anti-TPO 63.31 μ IU/ml (range:0-50) In August 2015, he presented to the endocrinology department and was diagnosed with primary adrenal insufficiency when glucocorticoid and mineral corticosteroid therapy were started. He went to regular checkups with his endocrinologist. Still, in February 2017, he was admitted to the hospital with complaints of heart palpitations over the last six months regardless of physical exercise or time of day and shortness of breath, which worsened with activity. His ACTH level was 78.9 pg/ml (range:7.2-63.3) and TSH 1.31 μ IU/ml. He was diagnosed with chronic primary adrenal insufficiency and symptomatic sinus tachycardia. Over the next year, he visited his endocrinologist in the outpatient clinic every three months. In July 2022, his free testosterone was 0.048 ng/ml (range:0.09-0.3), and total testosterone was 1.69 ng/ml (range:0.025-7.78), which demonstrated hypogonadotropic hypogonadism, and testosterone replacement therapy was initiated. In his latest blood work (January of 2023), he has high levels of prolactin – 1129 μ IU/ml (range:53-360) due to using antidepressant medication from the SSRI group. All other blood tests are within normal range. He leads a normal life - with a family of two children and a career.

Conclusions

This case report has proved the importance of early recognition of possible acute endocrine disorders and their prompt diagnosis. It has also shown that doctors must remain vigilant and examine their patients for all probable causes of their symptoms, as it can be two or three diseases simultaneously.

[1836] Multiple endocrine problems in patient with ACTH-secreting bronchial carcinoid

Authors: Agata Król (1), Magdalena Kochman MD PhD (2), Alicja Szatko MD (2), Mirella Iwanowska MD (2), Dorota Leszczyńska MD (2), Professor Wojciech Zgliczyński MD PhD (2)

Affiliation: (1) Students' Scientific Group affiliated to the Department of Endocrinology, Centre of Postgraduate Medical Education, Warsaw, Poland; (2) Department of Endocrinology, Centre of Postgraduate Medical Education, Warsaw, Poland

Trustee of the paper: Magdalena Kochman MD PhD

Corresponding author: Agata Król (agatakrol517@gmail.com)

Background

Bronchopulmonary neuroendocrine tumours (BP-NETs) are rare neoplasms, mostly with indolent clinical behaviour. Because of heterogeneous pathological features, we distinguish low-grade typical carcinoid, intermediate atypical carcinoid to high-grade neuroendocrine carcinoma. Nearly all are sporadic, however, they can rarely occur in patients with multiple endocrine neoplasia type 1 (MEN1). In few cases, ectopic hormone secretion, such as adrenocorticotrophic hormone (ACTH), leading to Cushing syndrome (CS) has been reported.

Case report

A 65-year-old woman with multifocal bronchial carcinoid and primary hyperparathyroidism was admitted to the hospital with suspicion of MEN1. The patient reported facial plethora and fullness, hirsutism and muscle weakness. Her medical history was remarkable for recurrent nephrolithiasis, hypertension, impaired fasting glucose and hyperlipidemia.

Endogenous hypercortisolemia was confirmed, elevated ACTH concentration was measured, no cortisol suppression was observed in high-dose dexamethasone test, not significant ACTH and cortisol rise in corticotropin-releasing hormone test was observed: confirming the ectopic ACTH syndrome in patient with bronchial carcinoid. In 18F-FDG PET/CT multiple pulmonary lesions with increased radiotracer uptake were identified. Somatostatin analogue therapy was initiated.

Laboratory tests confirmed the diagnosis of primary hyperparathyroidism. Pathologically enlarged right upper parathyroid was localized using MIBI SPECT/CT scintigraphy and ultrasonography, confirmed by PTH measurement in the fine-needle aspirate washout. To reduce the potential risk of complications related to surgery in patient with hypercortisolemia the laser thermal ablation of pathological parathyroid was scheduled instead of parathyroidectomy.

No other typical for MEN1 syndrome pathologies were found.

Conclusions

Synchronic multiple endocrine neoplasms pose a significant challenge for clinicians, especially when it is associated with ectopic ACTH-producing tumours. Hypercortisolemia often leads to life-threatening complications. It increases bone resorption and impairs bone formation, therefore, in a patient with coexisting primary hyperparathyroidism, may contribute to hypercalcemia, hypercalciuria, nephrolithiasis and bone loss. The management needs to be individualized, novel therapeutic approaches including laser thermal ablation of pathological parathyroid may be advantageous.

[1882] **Complex Autoimmune Polyendocrine Syndromes: Importance of Extended Diagnostics in Type 1 Diabetes- a case report**

Authors: Adam Surma, Zuzanna Roszkowska

Affiliation: Medical University of Warsaw/ Students Scientific Society Internal Med 7th Floor

Trustee of the paper: Paweł Kuca MD, PhD

Corresponding author: Adam Surma (s082727@student.wum.edu.pl)

Background

The prevalence of autoimmune diseases has been on the rise, with a current estimated incidence of 3-5% in the general population. Autoimmune endocrinopathies make up a sizable proportion of these cases. Autoimmune polyendocrine syndromes (APS) are rare and complex disorders. Type 3 APS involves autoimmune thyroid disease, type 1 diabetes, and various other autoimmune conditions, excluding Addison's disease and hypoparathyroidism.

Case report

A 23-year-old female with a longstanding history of type 1 diabetes and chronic autoimmune thyroiditis (increased ATPO and ATG titers) was admitted to the Endocrinology Department of the Mazowiecki Szpital Brodnowski due to weakness, fatigue, polydipsia, and polyuria that were not associated with glycemic control and had been present for the past year. The patient had previously received thyrostatics for hyperthyroidism symptoms, which were discontinued due to hypothyroidism (TSH of 51.9 IU/ul). Imaging and Laboratory tests revealed Hashitoxicosis, and a water deprivation test confirmed central diabetes insipidus, along with an MRI showing asymmetry of the pituitary stalk. Desmopressin at a dose of 2x60µg effectively treated the symptoms and normalized laboratory test results. However, the patient was readmitted due to the recurrence of symptoms in the form of polydipsia with polyuria and vomiting unrelated to meals. Further evaluation revealed secondary adrenal insufficiency, and the patient was started on substitution treatment with hydrocortisone. The dose of desmopressin was increased by 60µg/day. After treatment modification, significant clinical and laboratory improvement was achieved.

Conclusions

This case report highlights the significance of monitoring patients with autoimmune diseases that can occur in APS syndromes and conducting additional diagnostics, such as water deprivation tests, for patients with type 1 diabetes who experience polydipsia and polyuria despite adequate glycemic control. It emphasizes the complexity of autoimmune polyendocrine syndromes and the need for personalized treatment strategies.

[1884] Ectopic ACTH Syndrome in a Patient with ACTH- secreting Lung Cancer- Treatment Difficulties: a case report

Authors: Zuzanna Roszkowska, Adam Surma

Affiliation: Medical University of Warsaw/ Students Scientific Society "Internal Med 7th Floor"

Trustee of the paper: Pawel Kuca MD, PhD

Corresponding author: Zuzanna Roszkowska (s082681@student.wum.edu.pl)

Background

Cushing syndrome (CS) is a composite of disease symptoms caused by hypercortisolemia. Ectopic CS is a paraneoplastic disorder with the exogenous secretion of adrenocorticotropic hormone (ACTH), which may be associated with small-cell lung cancer.

Case report

A 59-year-old woman with arterial hypertension and pre-diabetes was admitted to the Endocrinology Department due to severe hypokalemia (1,2 mmol/l). On referral, she reported insomnia and rapid unintentional weight loss. Routine abdominal ultrasonography revealed suspicious liver lesions with possible metastatic characteristics. CT of the chest, abdomen, and pelvis was performed and revealed a solid tumor (from the aortic arch level to the eighth thoracic vertebrae level) in the mediastinum and nodes in the liver. Potassium supplementation was implemented both intravenously and by oral route. Due to difficulties with the normalization of electrolytes disorder, the hormonal evaluation was performed and confirmed ACTH- dependent hypercortisolemia. MRI did not visualize a lesion compatible with a pituitary adenoma. Corticotropin-releasing hormone (CRH) stimulation test was negative. In histopathological examination samples from the liver, small-cell lung cancer cells were found. Based on hormonal and radiological findings, ectopic Cushing syndrome was diagnosed. Due to persistent hypercortisolemia and difficulty in normalizing hypokalemia, pharmacological treatment was implemented. Etomidate in constant infusion (steroidogenesis inhibitor) was started in monotherapy and then continued with osilodrostat (nonsteroidal corticosteroid biosynthesis inhibitor), which led to eucortisolemia, adequate control of blood pressure. After normalizing cortisol concentrations, osilodrostat in monotherapy was continued in doses adjusted to hormonal assessments. The patient was classified for further oncological treatment.

Conclusions

Digital imaging results should be interpreted carefully, along with the findings of hormonal evaluations. Neuroendocrine tumors should be considered a source of ACTH. Sometimes, it is challenging to achieve hormonal normalization with monotherapy treatment, especially in cases of severe hypercortisolemia, so the combinative treatment should be considered. Proper management of hypercortisolemia can decelerate the progression of complications, making the role of rapid implementation of treatment crucial.

[1955] How a suspected lymphoma turned out to be an adrenocortical carcinoma- diagnostic issues with a hormone-secreting tumours

Authors: Paulina Kalman, Paweł Szajewski

Affiliation: Student's Scientific Society „Thyroldea” of Department of Oncological Endocrinology and Nuclear Medicine, Maria Skłodowska-Curie National Research Institute of Oncology

Trustee of the paper: Agnieszka Żyłka MD, PhD

Corresponding author: Paulina Kalman (paulina.kalman@wp.pl)

Background

Adrenocortical carcinoma (ACC) is a rare neoplasm with a variable clinical course. It occurs in about 0,2% of malignancies in adult population. In most cases the disease is recognized in an advanced stage because it is asymptomatic for a long time and can be confused with other diseases.

Case report

A 44-year-old woman complained of abdominal pain, general weakness, and menstrual irregularities for three months. The patient has gained 10kg in the last eight months. Physical examination revealed lower extremity oedema, a palpable mid-abdominal mass, and excessive hairiness of the sacrum and chin. Hypertension, elevated fasting glucose and hyperthyroidism were all diagnosed three months ago. An ultrasound scan revealed a mass in the left mid-abdomen. Due to hyperthyroidism, an outpatient non-contrast computed tomography (CT) scan was performed, which showed periaortic lymphadenopathy. Lymph node material was taken under ultrasound guidance for cytometric and cytogenetic examination, which ruled out lymphoma. Thyroid hormone and TSH levels were found to be lower in the absence of thiamazole supplementation. A contrast-enhanced CT scan was performed which revealed multiple lymph node packages in the neck, mediastinum, and retroperitoneal space in the lumbar region. A polycyclic mass near the left adrenal gland, numerous pathological lymph nodes, and a focal lesion in the pancreatic head region were discovered using positron emission tomography (PET-CT) imaging. A biopsy of the supraclavicular lymph nodes revealed that it is a metastatic adrenocortical carcinoma (ACC). Laboratory studies have found elevated cortisol levels and an abnormal circadian rate of its release, as well as elevated levels of adrenal androgens and hypothyroidism. ACC metastasized to the lymph nodes, causing Cushing syndrome and virilization was diagnosed. The patient was eligible for surgical treatment, but the tumour was determined to be unresectable after an exploratory laparotomy. The decision was made to begin mitotane treatment and possibly chemotherapy. Depending on the concentration of mitotane, experimental treatment will be considered.

Conclusions

In conclusion, rapid diagnosis and surgical resection are associated with the best treatment response in ACC but many of the tumours are non-operative and revealed in the metastatic stage. Hormone-secreting tumours can complicate diagnosis even further by affecting the hormonal activity of other axes and thus hiding behind the mask of other diseases.

[1990] Papillary thyroid carcinoma with elevated thyroglobulin level: a case report

Authors: Gabriela Pabian

Affiliation: Uniwersytet Jagielloński Collegium Medicum medical department

Trustee of the paper: Dr. n. med. Małgorzata Trofimiuk-Muldner

Corresponding author: Gabriela Maria Pabian (gabi.pabian@student.uj.edu.pl)

Background

Most patients with papillary carcinoma receive thyroidectomy with ablative radioactive iodine therapy. Thyroid ultrasound and serial serum thyroglobulin assessment were followed in such patients. This case report presents a middle-aged woman after total thyroidectomy with unexplained elevated level of thyroglobulin.

Case report

The 39-year-old woman was referred to the hospital in June 2021 for complementary ablative radioactive iodine therapy, after total thyroidectomy due to papillary thyroid carcinoma (PT3aN1Mx). In computer tomography of the neck before surgery, the nodular thyroid occupies both lobes and the isthmus. The tumor measured 58x45x46mm. Thyroid resection was performed with resection of the lymph groups - II, III, IV, VI. The histopathological examination showed a limited infiltration of papillary carcinoma to the parenchyma. Two lymph nodes on the left side of the neck showed cancer metastasis without transgressing the node capsule. The tests performed during hospitalization showed an increased level of thyroglobulin -204.4 ng/ml with a low level of anti-thyroglobulin antibodies -11,1 U/ml. After rhTSH stimulation, the level of thyroglobulin was 206.4 ng/ml. To find the source of high levels of thyroglobulin, positron emission tomography/computed tomography of the head, neck, chest and mediastinum was performed where no pathology was detected. Abdominal ultrasonography showed no signs of structural disease. Thyroglobulin tests were repeated - the results were consistently elevated. Bone scintigraphy with WBS AP+PA did not reveal osteoblastic typical metastasis changes. Therefore, the thyroglobulin level was measured in a laboratories that use a different analyzers from the one used in the hospital. The results received on another analyzer were within limits. During hospitalization in June 2022 patient received 148M of radioiodine 131-I. A day later, a whole-body scintigraphy was performed - no findings of distant metastases were recognized. The level of thyroglobulin in the hospital was determined by the ECLIA method on the COBAS 8000 analyzer.

Conclusions

High TG values determined in the COBAS system are the result of a laboratory error. This case illustrates that the type of medical analyzer may have a significant diagnostic impact and draws attention to the problem of early changing a method of verification or confrontation incorrect laboratory test results.

[1998] Minimally invasive method to exclude the pituitary origin of Cushing syndrome in the evaluation of the central-peripheral ACTH gradient.

Authors: Natalia Kukuła, Ewelina Kustra

Affiliation: Department of Descriptive and Clinical Anatomy Medical University of Warsaw, Chałubińskiego 5, 02-004 Warsaw, Poland

Trustee of the paper: Bartosz Sadownik, M.D.

Corresponding author: Natalia Kukuła (Natalia3kukula@gmail.com)

Background

Cushing's syndrome is caused by overexposure to elevated blood cortisol levels or long-term corticosteroid use. The most common mechanism, called Cushing's disease, is caused by an overproduction of ACTH by the pituitary gland (80% of cases pituitary adenoma present). Sometimes ACTH can be produced ectopic, which can be difficult to identify the location of secretion. Typical symptoms include weight gain, significant weakness, moon-shaped face, ease of bruising, menstrual disorders in women and erectile dysfunction in men. Also osteopenia, weakness of the limbs, or hirsutism. Cognitive dysfunction and depression are common. It can be accompanied by diabetes, or hypertension. It has a high morbidity and mortality rate, and if untreated, leads to death from cardiovascular and psychiatric complications in most patients.

Case report

A 58-year-old female patient with sacredly recognised diabetes mellitus and grade III obesity was transferred to the University Clinical Centre MUW with suspected ACTH-dependent Cushing's disease. Investigations showed high levels of daily urinary cortisol (500 ug/day) and ACTH (142 pg/day). The patient showed myopathy and hypokalemia indicative of a rapidly progressive disease. Swelling of the lower extremities and a moon-shaped face are present. Prior to transfer, a bilateral inferior petrosal sinus sampling (BIPSS) with desmopressin stimulation test was performed at Invasive Radiology Lab with access through the femoral vein. A test result was negative - no gradient was detected; however, MRI showed a small lesion that may be a microadenoma. In cases of very high values of cortisol in the blood, the BIPSS may come out falsely negative. With the patient's consent, it was decided to repeat assessment of central/peripheral ACTH gradient. This time the puncture was done at the level of the C7 vertebra (12cm french mid-line)]. After administration of methopirone, which inhibits cortisol synthesis, bilateral internal jugular vein cannulation was performed by 12cm 3F catheter, at the level of the C7 vertebra in the cephalad direction. Peripheral venous cannulation was also done and 30 blood samples were taken at two-minute intervals.

Conclusions

Due to the use of a non-standard, minimally invasive approach in bilateral internal jugular vein bulb cannulation and repeated assessment of the central and peripheral ACTH gradient with methopirone administration neurosurgical resection of a pituitary adenoma was avoided.

Infectious Diseases

Date: 21st April 2023, 10:00 AM

Coordinators:
Klaudia Zielonka
Kamil Tkacz

Patronage:

prof. dr hab. n. med. Andrzej Horban
Konsultant Krajowy w dziedzinie Chorób Zakaźnych, główny doradca Prezesa Rady
Ministrów do spraw COVID-19, przewodniczący Rady Medycznej

[1550] Parents' Attitudes Towards Vaccinations Regarding the Ukrainian Migration to Poland in 2022.

Authors: Martyna Cholewik, Maciej Stępień

Affiliation: Student Scientific Circle at the Department of Children's Infectious Diseases, Medical University of Warsaw, Wolska 37, 01-201 Warsaw, Poland

Trustee of the paper: Carlo Bieńkowski, MD

Corresponding author: Martyna Iga Cholewik (martynacholewik@gmail.com)

Introduction

Russia's aggression against Ukraine in early 2022 resulted in a large migration of refugees to many countries, including Poland. Vaccination coverage for some infectious diseases in Ukraine is lower than in Poland, and consequently, the infectious diseases incidence is higher including: measles, poliomyelitis, tuberculosis, and COVID-19.

Aim of the study

The aim of the study was to investigate whether the migration of Ukrainians had influenced parents' decisions on having their children vaccinated, and to examine their attitude towards vaccinations.

Materials and methods

A cross-sectional survey study was designed. The study population was divided into two subgroups for further analysis. Stratification was performed according to the declared impact of Ukrainian migration on participants' decisions on whether they would vaccinate their children. The Mann–Whitney U test and the chi² were used for comparison of continuous, and categorical variables, respectively. A p-value of < 0.05 was considered significant.

Results

A total of 568 questionnaires were collected, of which 21 did not meet the criteria for being included in the analysis (respondents were not parents). The Ukrainian immigrants' influx had affected 54 (9.87%) participants in their decision of having their children vaccinated. Respondents in this group were more likely to have a positive attitude toward recommended vaccinations ($p=0.0428$), have their children vaccinated with recommended vaccinations ($p=0.0063$), believed the vaccination coverage with mandatory vaccinations was higher in Poland than in Ukraine ($p=0.0014$), the incidence of diseases covered by mandatory ($p=0.0472$), and recommended ($p=0.0097$) vaccinations was higher in Ukraine. In addition, respondents who declared that the migration had affected their decision regarding their children's vaccinations, had more often been vaccinated due to the influx of Ukrainian immigrants ($p<0.00001$), and were more likely to be aware of the impact on the current epidemiological situation in Poland ($p=0.0021$). Moreover, the survey more often made these participants think about getting additional vaccinations for themselves ($p<0.0001$), and their children ($p<0.0001$)

Conclusions

To sum up, the Ukrainian immigrants' influx affected 9.87 % of surveyed parents in their decision of having their children vaccinated. This group was more aware of the differences in infectious diseases' epidemiology in Poland and Ukraine. In addition, they also had more positive attitude toward vaccinations.

[1551] Risk Factors for *Toxoplasma gondii* Infection among Pregnant Women Living in Rural Areas in Poland

Authors: Martyna Cholewik, Maciej Stępień

Affiliation: Student Scientific Circle at the Department of Children's Infectious Diseases, Medical University of Warsaw, Wolska 37, 01-201 Warsaw, Poland

Trustee of the paper: Carlo Bieńkowski, MD

Corresponding author: Martyna Iga Cholewik (martynacholewik@gmail.com)

Introduction

Toxoplasma gondii is a parasitic protozoon. The infection is usually asymptomatic in humans, however, it may pose a threat to the developing fetus in pregnant women. The felids as the final host are the carriers for the oocysts, which when excreted with their feces may be contagious. Potential risk factors for acquiring the protozoon include: eating unwashed vegetables, gardening without gloves, eating raw meat and taking care of cats.

Aim of the study

The aim of this study was to compare the prevalence of risk factors for toxoplasmosis between pregnant women living in rural areas and those living in urban areas.

Materials and methods

It was a retrospective observational study, data from the medical records of all pregnant women with suspected toxoplasmosis, that were consecutively consulted in the Hospital for Infectious Diseases in Warsaw between 1st September 2019 and 14th March 2020 were analyzed. Patients' demographics and data on risk factors for toxoplasmosis were included in the analysis. The presumptive diagnosis of primary toxoplasmosis was verified by serological assessment of immunoglobulins M and G titers, and immunoglobulin G affinity tests by VIDAS® (bioMérieux, Lyon, France) assay.

Results

In total, 273 women were included in the analysis with a median age of 30 years [IQR: 26-33 years]. Women living in rural areas were less likely to have good socioeconomic status ($p=0.0064$), and were less likely to have toxoplasmosis infection excluded ($p=0.0023$). Compared to women living in urban areas, pregnant women from rural areas were more likely to have confirmed primary toxoplasmosis ($p=0.0164$), more likely to work in the garden without gloves ($p<0.0001$), ate unwashed vegetables ($p=0.0025$), ate raw meat during pregnancy ($p=0.0008$), and were also more likely to care for cats during pregnancy ($p=0.0002$), before pregnancy ($p=0.0069$), and feral cats ($p<0.0001$).

Conclusions

Pregnant women living in rural areas were significantly more likely to be exposed to seven risk factors for toxoplasmosis. This can be considered as a reason for the rural residents in this study to have the higher percentage of primary infections during pregnancy and lower rate of excluded infections.

[1564] Similarities and differences between patients who interrupted ART and those who presented late with HIV

Authors: Wiktoria Gajek-Flanczewska, Sebastian Flanczewski

Affiliation: Department of Infectious and Tropical Diseases and Hepatology, Medical University of Warsaw, Poland, Student's Scientific Society, Department of Infectious and Tropical Diseases and Hepatology, Medical University of Warsaw, Poland

Trustee of the paper: MD Dagny Krankowska, MD Mariusz Sapuła, Md PhD Aneta Cybula, MD, PhD, Prof A Wiercińska-Drapało

Corresponding author: Wiktoria Stefania Gajek-Flanczewska (wiktoria.gajek@icloud.com)

Introduction

About 50% of newly diagnosed patients with HIV in Europe are diagnosed late. An equally important topic to late presentation is antiretroviral treatment (ART) discontinuation.

Aim of the study

The purpose of this study was to analyze ART discontinuation in the context of late HIV presentation and to see what the risk factors for ART interruption are.

Materials and methods

This is a retrospective analysis of patients with HIV hospitalized in one of the HIV services in Poland between January 2020 and December 2021. Two sub-analyses were carried out: a comparison of patients who came to the hospital to restart antiretroviral therapy after treatment interruption with patients who were diagnosed late, and another one comparing those who have interrupted antiretroviral treatment to those who were adherent to ART.

Results

Two hundred fifteen patients were included in this study and divided into 3 groups: 47 patients admitted for re-initiation of ART ("Group A"), 53 patients newly diagnosed late HIV presenters ("Group B"), 115 patients living with HIV (PLWH) on stable antiretroviral treatment ("Group C"). Those who discontinued ART more often had history of addictions ($p=0.001$) in comparison to late presenters. Women ($p=0.026$), younger people ($p=0.007$) and those who actively use drugs ($p<0.001$) more often discontinued ART in comparison to the control group.

Conclusions

ART discontinuation is a topic that cannot be omitted while analyzing late presenters. Women living with HIV and people using drugs have a higher risk of ART interruption and thus adequate interventions should be made to retain them in medical care.

[1590] **Clinical and epidemiological features of Lyme neuroborreliosis in adults in Lithuania: a retrospective study**

Authors: Emilija Damazeckaite

Affiliation: Vilnius University, 5th year MD student.

Trustee of the paper: Daiva Radzisauskiene, MD, VULSK Center of Infectious Diseases.

Corresponding author: Emilija Damazeckaite (emilija.damazeckaite@mf.stud.vu.lt)

Introduction

Lyme borreliosis (LB) is a tickborne disease, predominantly caused by bacteria *Borrelia afzelii* or *Borrelia garinii* in Europe. Reported incidence has been increasing, and the clinical manifestations of Lyme borreliosis are diverse. Current estimates suggest that in Europe around 85 000 people contract LB every year.[1] Since 1991, till 2018, 48 236 cases of LB have been documented in Lithuania. Acute Lyme neuroborreliosis (LNB) is the second most frequent clinical manifestation after erythema migrans. Neurological symptoms are present in 61% of LB patients in Lithuania.

Aim of the study

To overview clinical and epidemiological features of Lyme neuroborreliosis patients that were hospitalized in 2010-2021 in Vilnius University Hospital Santaros Klinikos in Lithuania.

Materials and methods

A retrospective study was carried out to analyze the clinical and epidemiological features of neuroborreliosis in hospitalized adults. The study took place in the Center of Infectious diseases and the Center of Neurology of Vilnius University Hospital Santaros Klinikos in 2010 – 2021. Cases were defined based on precisely documented clinical characteristics, imaging tests and laboratory results. Definite LNB was diagnosed if all the following three criteria were fulfilled: neurological symptoms suggestive of LNB (with other causes excluded), cerebrospinal fluid (CSF) pleocytosis and intrathecally produced *B. burgdorferi* antibodies. Early LNB was defined if neurological symptoms and signs lasted for <6 months. Late LNB was diagnosed if they persisted for >6 months.

Results

Out of all 103 LNB patients, 100 (97,09%) had early LNB. Division between male and female patients was similar. Mean age was 58 years. Most popular regions for contracting the disease were Vilnius city and Vilnius County. Most hospitalizations occurred in August (21, 20,39%). July was the most prominent month for tick bites (32,5%) and onset of symptoms (24,32%). Only 38,8% of the patients recalled getting bit by a tick. Radiculitis was the leading first neurological symptom, as it manifested in 70 (69%) patients. It was also the most common symptom overall in early LNB (75, 75%). 56 (67%) of the subjects had no residual symptoms.

Conclusions

Summer is the most popular season for contracting and showing symptoms of LNB. Radiculitis is the leading first and overall symptom of LNB. Two thirds of LNB patients are bound to full recovery.

[1617] The Attitude of Pregnant or Breastfeeding Polish Women Towards COVID-19 Vaccinations: a Cross-sectional Survey Study

Authors: Hanna Dancewicz, Anita Kwiatkowska, Joanna Gębarowska

Affiliation: Student's Scientific Society of the Department of Pediatric Infectious Diseases of Medical University of Warsaw

Trustee of the paper: Carlo Bieńkowski, MD

Corresponding author: Hanna Dancewicz (hania@dancewicz.pl)

Introduction

Pregnant women are at higher risk of severe course of COVID-19. According to the recommendations of the Polish Society of Gynecologists and Obstetricians the vaccine against COVID-19 is recommended in pregnant and/or breastfeeding women.

Aim of the study

The aim of the study was to assess the attitude towards vaccination against COVID-19 among Polish pregnant and/or breastfeeding women.

Materials and methods

A cross-sectional survey study was performed from April 20th 2021 to October 23rd 2021 using an online questionnaire distributed via social media. In total 679 questionnaires met the inclusion criteria. Willingness to be vaccinated was defined by giving correct answers to both questions including: "Would you get vaccinated against COVID-19 during pregnancy?", and "Would you get vaccinated against COVID-19 during breastfeeding?". The statistical analysis was performed using: Quick Statistics Calculators Programme (online).

Results

Willingness to be vaccinated was expressed in 235/679 (34.61%) of the surveyed women. Women that were healthcare workers were more likely to be vaccinated according to the recommendations (43/90, 47.78% vs 192/589, 32.60%, $p=0.005$). Women with higher education were more prone to be vaccinated with recommended vaccines than women who finished primary, grammar, vocational or high school (216/569, 37.96% vs 19/110, 17.27%, $p=0.00003$). Women who trusted their doctors showed higher interest in being vaccinated against COVID-19 according to the guidelines than those who didn't (96/204, 47.06% vs 5/28, 17.86%, $p=0.0038$). Moreover, women who thought COVID-19 vaccine was effective were more likely to get vaccinated with recommended vaccines compared to women with other opinion (199/322, 61.80% vs 36/357, 10.08%, $p<0.00001$). In addition, women that were afraid of COVID-19 were more prone to be vaccinated with recommended vaccines than women who weren't afraid of the disease (197/416, 47.36% vs 38/263, 14.45%, $p <0.00001$).

Conclusions

The study showed that 34.61% of the surveyed women wanted to be vaccinated against COVID-19. In addition, women working in the medical field, with higher education, who trusted their doctors, thought that vaccines against COVID-19 were effective, and those afraid of COVID-19 were more prone to be vaccinated against COVID-19 with recommended vaccines. Therefore, educational role of healthcare workers might be crucial for increasing the COVID-19 vaccine coverage in pregnant and breastfeeding women.

[1655] Prevalence and subtyping of *Blastocystis* sp. in pet rodents in Warsaw

Authors: Paweł Bochomulski, Filip Jakubczak, Bartosz Cieślak, Łukasz Nowotka, Ruslan Salamatin, Adam Kaczmarek

Affiliation: Department of Microbiology and Parasitology, Faculty of Medicine. Collegium Medicum, Cardinal Stefan Wyszyński University in Warsaw, Wóycickiego 1/3, 01-938 Warsaw, Poland

Trustee of the paper: Adam Kaczmarek

Corresponding author: Filip Jakubczak (jakubczak.filip@gmail.com)

Introduction

Blastocystis sp. is a protozoan parasite that can be found worldwide in the human and animal intestine. Infection may be asymptomatic or accompanied by symptoms such as diarrhea and abdominal pain. By analyzing the small subunit ribosomal RNA gene, different subtypes of *Blastocystis* sp. can be identified, with subtypes 1-9 and 12 being detectable in humans. Some of these subtypes have been found in small rodents, which is important in understanding the zoonotic potential of the parasite.

Aim of the study

Identification the subtypes of *Blastocystis* sp. present in the feces of domestic rodents and rabbits from pet stores in Warsaw.

Materials and methods

Study sample consisted of 480 rodents and 52 rabbits residing in 244 cages within 23 pet stores. Due to multiple animals being kept in the same cage, testing was conducted on pooled fecal samples, and the prevalence of *Blastocystis* sp. was determined by the presence of the parasite in culture or a positive Real-time PCR result for each cage. Feces were placed in a modified Jones medium containing 10% horse serum, followed by a 48-hour culture to detect the parasite via light microscopy. For boxes with positive results in the microscopic examination, DNA was isolated and Real-time PCR was conducted to detect a specific fragment of SSU rDNA. The PCR products were sequenced and analyzed.

Results

Among the 11 rodent species tested, *Blastocystis* sp. was detected in 4 species in 9 boxes (4.1 %) using culture, while none of the rabbits were infected. Specifically, the parasite was present in 4 (10.3 %) rat boxes, 3 (6.1 %) Djungarian hamster boxes, 1 (33.3 %) Cairo spiny mouse box, and 1 (4.0 %) house mouse box. Prevalence of *Blastocystis* sp. detected by Real-time PCR was lower than that detected by culture. Only 4 (1.8 %) of all the rodent boxes tested positive for the parasite, with the prevalence being highest in rats (5.1 %), followed by a single positive result each in Cairo spiny mouse (2.0 %) – the first documented case - and Djungarian hamster (33.3 %), respectively. The mouse sample tested negative for the parasite. Sequencing identified ST1 and ST3 in two rats and ST17 in one Djungarian hamster and Cairo spiny mouse.

Conclusions

The low prevalence of the parasite indicates good sanitary conditions in Polish pet stores. A small number of infected individuals creates a low chance of infecting animal keepers. However, the subtypes found in rats have also been detected in humans. Their zoonotic and anthroponotic potential can be considered.

[1656] Knowledge of risk factors for *Toxoplasma gondii* infection in Polish women in regard of their pregnancy status

Authors: Aleksandra Ciesielska, Joanna Ciepiewska, Edyta Dusza, Piotr Gaworek

Affiliation: Students' Scientific Group at the Department of Children's Infectious Diseases, Medical University of Warsaw

Trustee of the paper: Carlo Bieńkowski, MD

Corresponding author: Aleksandra Weronika Ciesielska (aleksandra.ciesielska99@gmail.com)

Introduction

Toxoplasmosis is an infection caused by a parasitic protozoon *Toxoplasma gondii*. Major routes of infection include: fecal-oral and transplacental transmission. The prevalence of congenital infection in the Polish population is estimated at 1-4/1000 newborns. Consequences of congenital toxoplasmosis may be severe, including: intrauterine fetal death, intracerebral calcifications and vision loss.

Aim of the study

The aim of the study was to evaluate knowledge of risk factors for *Toxoplasma gondii* infection in Polish women in regard of their pregnancy status.

Materials and methods

A cross-sectional survey study was designed. The inclusion criterion was being a female above or at the age of 18. The survey was prepared in Google Forms and was distributed via social media between December 2022 and January 2023. Questions about infection symptoms, clinical management, preventive screening and plausible consequences for the developing fetus were included.

The survey included 4 demographic questions, followed by knowledge-checking questions about toxoplasmosis. A maximum of 14 points were possible to obtain. A point for a multiple-choice question was received when the respondent marked 60% of the correct distractors without choosing any false answers.

Results

In total 229 women were included in the analysis with median age of 30 years (IQR: 23–36 years). In our cohort 55.5% of women had been pregnant or were currently expecting, the remaining 44.5% had never been pregnant. Women not working in the medical profession accounted for 84.7%. Having higher education applied to 65.9%, and none of the respondents declared primary education. Women who had been pregnant or were expecting obtained significantly higher results in the knowledge assessment section than women who had never been pregnant (66/127, 51.97% vs. 38/102, 37.25%, $p=0.026$).

Conclusions

Women who have been pregnant or were expecting had received significantly higher results in the survey. Hence, physicians' educational role is crucial for women's awareness on potential risk factors for *Toxoplasma gondii* infection during pregnancy and may be beneficial for congenital toxoplasmosis prevention.

[1784] The effects of Non-Pharmaceutical Interventions (NPIs) on the epidemiology of notifiable infectious diseases in Poland, 2015-2022, a cross-sectional study

Authors: Abdulla Hourani, Abdelrahman Abdelsalam

Affiliation: Department VII of the Provincial Infectious Hospital, Medical University of Warsaw, Poland

Trustee of the paper: Agnieszka Bednarska, Dominik Bursa

Corresponding author: Abdulla Hourani (hourani03@gmail.com)

Introduction

The COVID-19 pandemic has led governments to apply restrictions on various levels to curb the drastic rise of cases. Non-Pharmaceutical Interventions (NPIs) have been shown to be effective in reducing not only the spread of COVID-19 but also the number of reported cases of most notifiable infectious diseases.

Aim of the study

The study was conducted to statistically analyse the effects of NPIs on the epidemiology of notifiable infectious diseases in Poland.

Materials and methods

In this analytical cross-sectional study, we utilized data from the National Institute of Health to investigate biweekly reported cases of 31 notifiable infectious diseases from Jan 1, 2015, to Dec 31, 2022, with the criterion of an average of >200 cases per year between 2015 and 2019. We conducted non-parametric analyses based on stringency which was denoted 0 and 1 when <2 NPIs and >2 NPIs were applied, respectively, and based on the number of NPIs applied simultaneously (0-4). The studied NPIs were face covering, school closure, travel ban, and restrictions on public gathering, data of which were collected from Oxford Covid Government Response Tracker.

Results

With the exception of *C. Difficile*, statistical analysis revealed a significant reduction of cases in all selected diseases upon implementation of at least two NPIs ($p=0.00001$). The analysis based on the number of applied NPIs has shown that the number of cases decreased proportionally as more NPIs were enacted ($p=0.00001$). Diseases transmitted with respiratory droplets (from Scarlet Fever 82% to Influenza 53%) and vaccine-preventable diseases (from Whooping cough 80% to severe Mumps 68%) exhibited the steepest trend of decrease when stringency was 1. In contrast, diseases transmitted through the oral-fecal route (from Hepatitis A 88% to *C. Difficile* 24%) and wound-borne diseases (*Erysipelas* 57%) showed the least trend of decrease.

Conclusions

Our study findings suggest that NPIs are effective in reducing the incidence of most infectious diseases, and increasing the number of NPIs implemented results in a proportional reduction of cases. However, *C. Difficile* infections didn't significantly decrease, possibly because hospitalization rates have not declined during the pandemic. The reduction in vaccine-preventable diseases incidence suggests that a combination of vaccines and NPIs is the most effective approach for mitigating the spread of infectious diseases.

[1800] Prevalence and antimicrobial susceptibility of *Bacteroides* spp. – isolation from peritoneal fluid in pediatric units

Authors: Alicja Danieluk, Jan Kownacki

Affiliation: (1) Chair and Department of Medical Microbiology, Medical University of Warsaw, (2) Microbiology Laboratory UCML UCK WUM, Warsaw, Poland

Trustee of the paper: Marta Kierzkowska PhD, Anna Midak-Siewirska PhD

Corresponding author: Alicja Danieluk (adanieluk@gmail.com)

Introduction

Bacteroides species are obligate anaerobic, Gram-negative, rod-shaped bacteria that play a significant role in the human gastrointestinal microflora. However, despite being important commensals, they are also the most prevalent anaerobic bacteria causing abdominal infections when they escape the colonic environment. This can occur as a result of abdominal surgeries, penetrating injuries or inflammatory processes such as appendicitis, especially common in pediatric patients. The most commonly used antibiotic in perioperative prophylaxis is cefazolin, and adding metronidazole is indicated specifically for procedures involving the large intestine. Similarly, for intra-abdominal infections, combination therapy with metronidazole plus cefazolin or monotherapy with piperacillin-tazobactam or carbapenems is used. Recently, an increase in resistance to beta-lactams (including carbapenems) and clindamycin has been observed in the *Bacteroides* group.

Aim of the study

The aim of the study was to determine the prevalence and antimicrobial susceptibility of *Bacteroides* species in peritoneal fluid from pediatric patients.

Materials and methods

109 samples of peritoneal fluid were plated on microbiological media and incubated under aerobic and anaerobic conditions. Samples were collected from 105 pediatric patients hospitalized in various departments of a teaching hospital in Warsaw in 2022. Anaerobic bacteria were cultured on Schaedler Agar in 37°C for 48 hours under anaerobic conditions. *Bacteroides* strains were identified using the mass spectrometry technique MALDI TOF (Bruker Biotyper). The antimicrobial susceptibility of the *Bacteroides* strains to metronidazole, piperacillin-tazobactam, clindamycin and meropenem was determined using the disk diffuse method on FAA agar, according to EUCAST breakpoints.

Results

Out of all 109 peritoneal fluid samples tested, *Bacteroides* strains were isolated from 39 samples (35.8%). In total, 50 non-duplicate strains of *Bacteroides* were isolated, including: *B. fragilis* (62%), *B. thetaiotaomicron* (18%), *B. ovatus* (10%), *B. vulgatus* (4%), *B. caccae* (2%), *B. uniformis* (2%) and *P. merdae* (2%). All *Bacteroides* strains were susceptible to metronidazole and meropenem. 41.46% of the strains were resistant to clindamycin and 4.76%, both *B. thetaiotaomicron*, were resistant to piperacillin-tazobactam.

Conclusions

The results of susceptibility testing, which showed 100% susceptibility to metronidazole and meropenem, indicate their role as first-line antimicrobial prophylaxis in intra-abdominal surgeries.

[1838] Susceptibility profile of *Bacteroides* spp. among the surgical patients

Authors: Jan Kownacki, Alicja Danieluk

Affiliation: 1) Chair and Department of Medical Microbiology, Medical University of Warsaw, (2) Microbiology Laboratory UCML UCK WUM, Warsaw, Poland

Trustee of the paper: Marta Kierzkowska PhD, Anna Midak-Siewirska PhD

Corresponding author: Jan Kownacki (Jajaneckow@gmail.com)

Introduction

Bacteroides is a genus of obligate anaerobic bacteria that is also important part of the human gastrointestinal microbiota. However, during surgical procedures, it can spread to surrounding tissues and body fluids, causing serious endogenous infections. The treatment of such cases poses a challenge, due to the tendency of *Bacteroides* to create abscesses, which impedes drug penetration. Another predicament arises from high resistance to a wide variety of antibiotics, especially those used in surgical prophylaxis. Clindamycin resistance is increasingly common. Therefore, it is essential to determine the susceptibility of bacteria in each case individually in order to perform effective targeted therapy.

Aim of the study

The aim of the study was to investigate the drug susceptibility of *Bacteroides* strains isolated from various types of samples obtained from patients in the surgical wards of teaching hospital.

Materials and methods

35 cultures of different *Bacteroides* were isolated from 29 types of surgical materials (peritoneal fluid, surgical wounds, abscesses, bile). The specimens were collected from surgical wards including general surgery, urology, orthopedic and intensive surgical care units. The samples were grown on the Schaedler Agar under anaerobic conditions, and then tested for susceptibility to four antibiotics (piperacillin with tazobactam, clindamycin, meropenem, and metronidazole) using the disk diffusion method on FAA agar, based on EUCAST recommendations. All specimens were identified using the mass spectrometry technique MALDI TOF MS of Bruker System.

Results

From all the samples, 35 isolates of *Bacteroides* were obtained, including 8 different species. Most of them were *B. fragilis* (n=19). The rest were *B. thetaiotaomicron* (n=5), *B. uniformis* (n=4), *P. distasonis* (n=3), *B. xylanisolvens* (n=1), *B. ovatus* (n=1), *B. pyogenes* (n=1) and *P. vulgatus* (n=1). All of them were susceptible to metronidazole, and 90.3% were susceptible to piperacillin with tazobactam. 55.9% of them presented no resistance to clindamycin. One of them was resistant to meropenem.

Conclusions

To conclude, all results confirm that monitoring the susceptibility of *Bacteroides* is crucial in light of the high risk of resistance to therapy. Metronidazole still covers the whole spectrum of *Bacteroides* and remains the most efficient therapy. The fact of obtaining the strain resistant to carbapenems is very disturbing. Conducting monotherapy based on clindamycin seems risky in regards to the high resistance of *Bacteroides* to this antibiotic.

[1936] Changes of ACE-2 related-miR-200b-3p expression over time is a predictive factor of long hospitalization for COVID-19: in silico, machine learning and validation analysis

Authors: Zofia Wicik, Ceren Eyileten, Anna Nowak, Disha Keshwani, Mikolaj Marszalek, Sérgio N. Simões, David C. Martins, Jr.2, Jolanta M. Siller-Matula, Marek Postula

Affiliation: Department of Experimental and Clinical Pharmacology, Medical University of Warsaw, Center for Preclinical Research and Technology CEPT, 02-091 Warsaw, Poland

Trustee of the paper: Ceren Eyileten

Corresponding author: Disha Keshwani (dishkeswani@gmail.com)

Introduction

Coronavirus disease 2019 (COVID-19) is associated with an increased risk of mortality and adverse cardiovascular (CV) occurrences. SARS-CoV-2 virus enters cells through angiotensin converting enzyme 2 (ACE2) cell membrane enzymes, leading to the downregulation in the ACE2-related pathways.

Aim of the study

In this study we aimed to analyse the diagnostic and predictive utility of ACE2-related miRNAs, which were identified in our previous in silico analysis (miR-10b-5p, miR-124-3p, miR-200b-3p, miR-26b-5p, miR-302c-5p) in patients with COVID-19. We also aimed to unravel the functions of analyzed miRNAs, by using machine learning based tools.

Materials and methods

Blood samples and clinical data of 79 COVID-19 patients were collected at three different time points, including the day of admission, 7-days and 21-days after admission, as well as one time-point of 32 healthy volunteers. The composite endpoint was hospitalisation length of stay (>21 days) and/or death in follow-up.

Results

Delta low miR-200b-3p expression (after 7-days of admission) presents predictive utility in assessment of the hospital length of stay and/or death in ROC curve analysis (AUC:0.730, $p=0.002$) (Fig. 1). Delta low miR-200b-3p expression, together with diabetes mellitus (DM) are independent predictors of increased hospital length of stay and/or death (OR= 5.775; CI= 1.572- 21.214; $p= 0.008$, OR= 4,888; CI= 1.001- 23.858; $p= 0.050$, respectively). The expression levels of miR-26b-5p and miR-10b-5p in COVID-19 patients were found lower at the baseline, 7 and 21-days after admission compared to the healthy controls ($p<0.0001$ for all time points).

SHAP analysis indicated levels of miR 200b-3p (day 7th), miR-302c-5p (day 7th), CRP (day 7th), neutrophils (day 0), and D-Dimer (day 0) as the most promising predictors of long hospitalisation for the COVID-19 patients.

Pathway enrichment analysis showed that among top shared pathways between targets of analyzed miRNAs were Interleukin-2 signaling pathway, and Pathways in cancer. Bioinformatics analysis pointed out the role of those miRNAs in multiple CVDs phenotypes associated with COVID-19 disease.

Conclusions

In this study we characterised and validated miRNAs which could serve as novel, predictive biomarkers of the long term COVID-19 hospitalisation and thus can be used for early stratification of patients and prediction of severity of infection development in an individual.

[1966] **Comprehensive longitudinal analysis of lung function tests in patients after acute COVID-19**

Authors: Wiktoria Maria Izdebska, Katarzyna Anna Pietranis, prof. Marcin Moniuszko, prof. Anna Kuryliszyn-Moskal

Affiliation: Department of Allergology and Internal Medicine; Department of Rehabilitation, Medical University of Białystok, Poland

Trustee of the paper: prof. Marcin Moniuszko

Corresponding author: Wiktoria Maria Izdebska (izdebskawiktoria@gmail.com)

Introduction

Symptoms of long lasting COVID-19 including shortness of breath and chronic fatigue can significantly impact the functioning of the convalescents. They may present with a restrictive pulmonary pattern and impaired diffusion capacity which leads to significant impairment of quality of life. To date, the time and the extent of improvement of the lung function parameters during post-COVID-19 recovery has not been assessed in sufficient detail.

Aim of the study

The aim of the study was to assess the dynamics of changes of parameters of spirometry, bodyplethysmography and diffusion lung capacity for carbon monoxide (DLCO) parameters in patients who recovered from COVID-19.

Materials and methods

We performed spirometry, bodyplethysmography and DLCO at 3 and 6 months after acute COVID-19. We analyzed the dynamic changes of selected parameters including FEV₁, FEV₁/FVC, FEV₁/VC max, FEV₁,VC max, FVC, TLC, RV, DLCO at months 3 and 6 with the use of Wilcoxon tests in GraphPad programme.

Results

All analyzed lung function parameters increased at month 6 as compared to month 3 after the acute COVID-19. The median FEV₁ values raised from 2,425L to 3,87L (p=0,0001); FEV₁/FVC values raised from 70.86% to 88,51% (p=0,0001); FEV₁/VCmax values raised from 67.64% to 87.94% (p=0.0001); VCmax values increased from 1,46L to 5,34L (p=0.0001). FVC values raised from 1.4L to 5.34L (p= 0,0001). The TLC values raised from 3 to 7,24 (p=0,0001). The RV raised from 0,87 to 3,16 (p=0,0001). The DLCO values raised 2,36 to 7,65 ml/min/mmHg (p=0,0001). We also found statistically significant correlations between: FEV₁ and MEF50, PEF, DLCO, TLC, IC, FRCpl, ERV; VC max and PEF, DLCO, TLC, IC, FRCpl, ERV, RV; DLCO and FEV₁, VC max, PEF, VA, TLC, IC, FRCpl after 3 months from the infection.

Conclusions

Our data indicate that lung function impairment associated with COVID-19 can be at least partly reversed throughout next couple of months.

[3001] **Multisystem inflammatory syndrome associated with SARS-CoV-2 infection in children**

Authors: Luiza Shcherbakova

Affiliation: Department of Children's infectious diseases, Bogomolets National Medical University

Trustee of the paper: Candidate of Medical Sciences (Ph.D.), docent Oleksandra Buts

Corresponding author: Luiza Shcherbakova (shcherbakovaluiza@gmail.com)

Introduction

First, the Coronavirus disease 2019 was reported in Asia. Initial investigations suggested that children have only mild symptoms compared to adults. As the pandemic progress, there have been increased reports of complications associated with severe acute respiratory syndrome coronavirus 2 (SARS-CoV-2) infection. This condition was described as Multisystem inflammatory syndrome in children (MIS-C). Similar cases of the disease have been registered in Ukraine, particularly among children admitted to hospitals in Kyiv.

Aim of the study

Our study aimed to analyze and compare the main clinical manifestations, laboratory features, and management in children with the multisystem inflammatory syndrome in the "Kyiv City Children's Clinical Hospital №2".

Materials and methods

We examined 20 children (aged 4–16 years) between November 2020 and April 2021, with suspected MIS-C associated with SARS-CoV-2 infection. The diagnosis was made according to the Centers for Disease Control and Prevention (CDC). We performed the Mann–Whitney U-Test or Student's t-test to compare the laboratory parameters between the two groups. $P < 0.05$ was considered statistically significant. Data were analyzed with the Statistical software EZR v. 1.54.

Results

According to symptoms and pathological conditions, we divided patients into 2 phenotypes. Group I included 8 children with clinical signs that met the Kawasaki disease (KD) criteria. They were classified as patients with an MIS-C phenotype overlapping with KD. The median age of this group was less than in the second (7 years vs 10.5). Children have spent fewer days in the hospital (11 days vs 15 in group II). Additionally, this group is characterized by the occurrence of coronary artery dilatation or aneurysm (37.5%). Group II (MIS-C phenotype without overlapping with Kawasaki disease) included 12 patients. They had a higher number of involved organ systems. Patients with that phenotype had a significantly higher prevalence of abdominal pain (83.3% vs 50.0% in group I). Shock (25.0%) and peritonitis (16.7%) occurred only in this group. The median of leukocytes and neutrophils was found to be higher than in patients with a Kawasaki-like phenotype ($p=0.043$; $p=0.047$). Almost all patients in group II (84.6%) received intravenous immunoglobulin, in contrast to the group I (62.5%).

Conclusions

Our results suggest that MIS-C is characterized by a wide range of clinical features. Dividing patients into two phenotypes will allow doctors to diagnose MIS-C faster and treat it more effectively.

Internal Medicine

Date: 21st April 2023, 15:00 PM

Coordinators:

Ada Piwko

Weronika Stachera

Patronage:

Polskie Towarzystwo Nadciśnienia Tętniczego

Polskie Towarzystwo Farmakologiczne

Towarzystwo Internistów Polskich

[1529] **AngioScore: artificial intelligence for determination of SYNTAX Score**

Authors: Jakub Michal Zimodro, Ewelina Blazejowska, Adam Brzeski, Tomasz Dziubich, Jaroslaw Parzuchowski, Radoslaw Targonski, Aleksandra Gasecka

Affiliation: 1st Chair and Department of Cardiology, Medical University of Warsaw; Gdansk University of Technology; University Clinical Centre, Medical University of Gdansk

Trustee of the paper: Aleksandra Gasecka MD, PhD

Corresponding author: Jakub Michal Zimodro (zimodro.jakub@gmail.com)

Introduction

SYNTAX Score evaluates the severity of a coronary artery disease (CAD) and calculates the risk associated with invasive treatment of CAD based on a coronary artery lesion characteristic. Determination of SYNTAX Score with online calculators is subjective, depends on the experience of a medical professional and requires manual input of all assessed parameters.

Aim of the study

We aimed to create artificial intelligence-based tool for objective and efficient determination of SYNTAX Score. A prototype of online application AngioScore was developed and trained to independently assess coronary angiograms in terms of nine parameters necessary to determine SYNTAX Score (diseased segment, total occlusion, bifurcation, trifurcation, aorto-ostial lesion, severe tortuosity, length >20mm, heavy calcification, thrombus).

Materials and methods

Two medical students independently evaluated 100 randomly selected coronary artery lesions with AngioScore. First, student marked the lesion on an angiogram. Then, AngioScore determined initial SYNTAX Score. Subsequently, student identified parameters requiring manual correction and recorded their number. Statistical analysis was performed in Microsoft Excel spreadsheet.

Results

A total of 900 parameters were assessed with 83.7% accuracy. Parameters of coronary artery lesions located in the right coronary artery were assessed with 82.1% accuracy, in the left anterior descending artery with 85.7% accuracy and in the circumflex branch of the left coronary artery with 82.5% accuracy. 19% of coronary artery lesions were assessed fully correctly. In 34% of coronary artery lesions, 8 of 9 parameters were assessed correctly, in 31% - 7 parameters, in 16% - 6 or less parameters. Parameters that most often required corrections were: diseased segment (55%), bifurcation (33%), severe tortuosity (23%).

Conclusions

A prototype of AngioScore showed promising results regarding accuracy of SYNTAX Score determination. Thus, further development of our tool may lead to faster and more objective way to assess coronary artery lesions.

[1632] Correlation between conduction disturbances and noncompacted versus compacted myocardial layer of the left ventricle among patients at Pauls Stradins Clinical University Hospital

Authors: Nikola Serge

Affiliation: Riga Stradins University

Trustee of the paper: Prof. Oskars Kalejs, Dr. Ligita Zvaigzne

Corresponding author: Nikola Gabriela Serge (nikolaserge@gmail.com)

Introduction

Usually referred to as an isolated condition, left ventricular noncompaction is a structural defect of the left ventricle that can occasionally be linked to other structural cardiac diseases. It is yet to be determined whether a distinct noncompaction in particular segments of the left ventricle correspond to specific abnormalities in ECGs.

Aim of the study

The aim of this study was to assess conduction disturbances in patients with noncompaction cardiomyopathy at Pauls Stradins Clinical University Hospital.

Materials and methods

Retrospective single-center study included adult patients who had cardiac MRI performed at Pauls Stradins Clinical University Hospital in the timespan from January 1, 2018, to October 1, 2022. In order to assess the compacted and noncompacted layers of the myocardium, syngo.CT Cardiac Function software was used. Mathematical data processing was performed using descriptive statistics.

Results

Out of 1465 cardiac MRIs that were performed in the respective period of time, noncompaction cardiomyopathy was detected in 6,5% (n=95) of the cases. Out of these 95 patients, 37 had an ECG available for assessment. 49% of these patients (n=18) were women and 51% (n=19) were men. In 16% (n=6) of the cases, patients presented with atrial fibrillation, 35% (n=13) with ventricular extrasystoles, 24% (n=9) with left bundle branch block, 3% (n=1) showed sinoatrial node block, 3% (n=1) nonspecific ST-T segment changes, and 3% (n=1) presented with intraatrial conduction disturbances. In 16% (n=6) of the ECGs there were no abnormal findings.

Atrial fibrillation was more frequent in patients with a high ratio of noncompact to compact layer in segments 1, 6, 12; left bundle branch block was more common in patients with a high ratio in segments 5, 13, 14, 17; ventricular extrasystoles more pronounced with a high ratio in segments 6, 12, 15, 16; non-specific ST-T changes – with high ratio in segment 1; intraatrial conduction disturbances – in segment 5; SA blockade episodes – in segment 16.

Conclusions

It was concluded that most of the conduction disturbances presented in patients who had the highest noncompacted versus compacted myocardial layer ratio in segments 1, 5, 6, 12, and 16.

In our study, most of the conduction disturbances were observed in patients who displayed the highest noncompacted versus compacted layer ratio in the lateral portion of the left ventricle.

[1667] The type of SIBO is not associated with selected anthropometric parameters

Authors: Justyna Paulina Wielgosz-Grochowska¹, Małgorzata Ewa Drywień² and Nicole Domanski^{3,*}

Affiliation: 1, 2 Department of Human Nutrition, Institute of Human Nutrition Sciences, Warsaw University of Life Sciences, 02-776 Warsaw, Poland 3 Faculty of Pharmaceutical Sciences, University of British Columbia, Vancouver, BC, Canada: *

Trustee of the paper: Justyna Paulina Wielgosz-Grochowska

Corresponding author: Justyna Paulina Wielgosz- Grochowska (wielgosz.dietetyka@gmail.com)

Introduction

Recent observations have shown that Small Intestinal Bacterial Overgrowth (SIBO) affect the host through various mechanisms. The excessive bacterial carbohydrate fermentation may lead to impaired digestion and malabsorption of essential nutrients, as well as increased permeability, intestinal inflammation and possible weight loss. Obesity has been linked to SIBO as well, due to changes in the microbiome. In obese individuals, less diversity of gut microbiota and increased methanogenic Archaea has been observed in comparison with healthy subjects. While both weight loss and obesity have been reported in the SIBO population due to alterations in the gut microbiome, very little is known about the influence of SIBO type on body composition.

Aim of the study

This study aimed to evaluate whether there is an association between the three types of SIBO (methane dominant (M), hydrogen-dominant (H) and methane-hydrogen dominant (M+H)) and specific anthropometric parameter.

Materials and methods

This observational study included fifty-six participants (W=46, M=10) with gastrointestinal symptoms who underwent lactulose hydrogen-methane breath tests (LHMBTs) using the QuinTron device. Participants who fulfilled the study's eligibility criteria underwent a body composition assessment by Bioelectrical Impedance Analysis (BIA) using the InBody Analyzer. Non-parametric tests were used to determine associations between the types of SIBO and selected anthropometric parameters.

Results

SIBO type did not correlate with age, height, body weight, percent body fat, BMI, visceral fat, visceral to subcutaneous fat ratio (V/S), lean body mass (LBM) (kg, %) or waist-hip ratio (WHR). In patients with M+H, BMI ($p=0,0032$) and body fat in kg ($p=0.0011$) and body fat in % ($p=0.0050$) and visceral fat were inversely associated with increased H₂ concentration on the exhaled breath. In addition, when including only women, the correlation was stronger. Higher concentrations of exhaled methane, and hydrogen and methane together, were not associated with changes in BMI, V/S, body fat (kg, %), WHR, visceral fat or LBM.

Conclusions

Further research is needed to determine whether the type of SIBO is associated with specific anthropometric parameters. This will include a larger group of subjects and utilize methane and hydrogen breath tests for diagnosing SIBO.

[1682] The significance of interplay between serotonin reuptake transporter and brain-derived neurotrophic factor in inflammatory bowel disease

Authors: Sochal M.1, Gabryelska A.1, Binienda A.2, Ditmer M.1, Białasiewicz P.1, Fichna J.2, Talar-Wojnarowska R.3, Małecka-Wojcieszko E.3

Affiliation: 1 Department of Sleep Medicine and Metabolic Disorders, Medical University of Lodz, Poland 2 Department of Biochemistry, Medical University of Lodz, Poland 3 Department of Digestive Tract Diseases, Medical University of Lodz, Poland

Trustee of the paper: Marta Ditmer

Corresponding author: Marta Ditmer (marta.insmk@gmail.com)

Introduction

Serotonergic signaling and neurotrophins, brain-derived neurotrophic factor (BDNF) in particular, could partake in the pathophysiological mechanisms behind inflammatory bowel diseases (IBD). The interplay between BDNF and the serotonin signaling pathway has been thoroughly researched only within the central nervous system (CNS), there are limited data on processes occurring outside of this compartment. The intensity of signal transmission is regulated by the serotonin reuptake transporter (SERT) which returns the neurochemical back to the vesicles. The relation between SERT and BDNF on the periphery remains unclear.

Aim of the study

The study aimed to evaluate the expression of SERT and BDNF mRNA in IBD and healthy controls (HC) as well as assess interactions between the two.

Materials and methods

The study group comprised 68 IBD patients (27 UC- ulcerative colitis, 41 CD - Crohn's disease) and 27 HC. Harvey-Bradshaw index and partial Mayo score were used for disease activity assessment in CD and UC, correspondingly. Peripheral blood samples were collected. RNA isolation from peripheral blood mononuclear cells was performed using the Trizol method. cDNA was synthesized with a reverse transcription kit according to the instructions. mRNA expression level was determined with qRT-PCR (reference gene: β -actin). Relative expression was calculated using the Livak formula. The study has been financed by National Science Centre, Poland-2018/31/N/NZ5/03715.

Results

IBD group had an elevated expression of SERT and BDNF mRNA compared to HC ($p=0.023$, $p=0.015$). IBD women have higher SERT mRNA expression than IBD men ($p=0.019$). SERT mRNA expression positively correlated with BDNF mRNA ($r=0.24$, $p=0.044$). IBD type, disease activity, and concomitant chronic diseases (i.e. asthma, diabetes, etc.) did not affect gene expression ($p>0.05$).

Conclusions

SERT and BDNF may be relevant to the pathophysiology of IBD. They exert their influence regardless of disease activity, comorbidities, or IBD type. Future research on interactions between neurotrophins and serotonergic transmission in IBD could broaden the knowledge on the pathophysiology of this condition as well as may constitute a basis for innovations in clinical approach.

[1718] Longitudinal Assessment of the Association Between Electrolyte Imbalances and Mortality Among Intensive Care COVID-19 Patients

Authors: Ivan Szergyuk, Mohammed F. Abosamak, Maria Helena Santos de Oliveira, Sara Mathkar Almutairi, Jawza Salem Alharbi, Stefanie W. Benoit, Giuseppe Lippi, Marianna Tovt-Korshynska, Brandon Michael Henry

Affiliation: Faculty of Medicine, Jagiellonian University Medical College, Krakow, Poland

Trustee of the paper: Dr. Brandon Michael Henry MD

Corresponding author: Ivan Szergyuk (serdyuk.ivan@gmail.com)

Introduction

According to a substantial body of research, electrolyte abnormalities are a common manifestation in coronavirus disease 2019 (COVID-19) patients. Given their many important physiologic roles, such as immune function, cardiac function, and protection against oxidative stress, disturbances in electrolyte balance may worsen outcome of COVID-19 illness.

Aim of the study

To investigate electrolyte imbalances in COVID-19 patients and assess their relation to mortality.

Materials and methods

Adult COVID-19 patients hospitalized in the Security Forces Hospital in Saudi Arabia from June 8th till August 18th, 2020 were enrolled in this retrospective observational study. We examined baseline characteristics, comorbidities, acute organ injuries, medications, and electrolyte levels including sodium, potassium, chloride, calcium, bicarbonate, phosphate, and magnesium on ICU admission, as well as every following day of ICU stay, until death or discharge. Patients were stratified according to survival, and differences in variables between groups were compared using Mann-Whitney's U test or Fisher's exact test. Longitudinal electrolyte profiles were modeled using random intercept linear regression models.

Results

A total of 60 COVID-19 patients were enrolled. Compared to survivors, non-survivors had significantly higher sodium and phosphate on admission and death, higher potassium and magnesium at death, and significantly lower calcium at death. Abnormalities in admission levels of chloride and bicarbonate were also more frequently observed in non-survivors. Furthermore, in the deceased group, we observed a daily increase in potassium and phosphate levels, and a daily decrease in sodium and chloride. Finally, calcium increased in non-survivors over time, however, not as significantly as in the survivor group. The exact mechanisms of electrolyte imbalance are uncertain, however, among the comorbid conditions and medications analyzed, only acute cardiac injury, heart failure, and antiplatelet use during hospitalization might explain some of the observed differences as these were more prevalent in non-survivors.

Conclusions

Admission levels of electrolytes as well as subsequent daily changes over the course of ICU stay appear to be associated with mortality in COVID-19 patients. Our findings regarding disruption of electrolyte homeostasis in COVID-19 and associated survival outcomes offer not only insight into the pathophysiology of SARS-CoV-2 infection, but also suggest potential therapeutic options for minimizing disease severity.

[1776] “Blood pressure control in regular patients of Hypertension Outpatient Clinic during the pandemic years.”

Authors: Julia Sternicka 1, Anna Nieckarz 1, Anna Panfil 1, Aleksandra Białas 1, Łukasz Jędrzejewski 1, Michał Hoffmann 1, Anna Szyndler 1, Aleksander Prejbisz 2, Michel Burnier 3, Krzysztof Narkiewicz 1, Jacek Wolf 1.

Affiliation: Department of Hypertension and Diabetology, Medical University of Gdańsk; (2) Department of Epidemiology, Cardiovascular Prevention of the National Institute of Cardiology, Warsaw; (3) University of Lausanne, Lausanne.

Trustee of the paper: dr hab. med. Jacek Wolf

Corresponding author: Julia Sternicka (julia.sternicka@gumed.edu.pl)

Introduction

Cardiovascular risk factors distribution during the pandemic suggests worsening of the cardiovascular risk profile of hypertensive patients. At the same time, data on the quality of hypertension control during the COVID-19 pandemic are scarce, in Poland.

Aim of the study

The aim of the study was to analyze the quality of blood pressure control in a group of patients who require regular control in tertiary care.

Materials and methods

The study included 220 patients who required tertiary care for hypertension. Patients were regularly monitored in Gdańsk Hypertension Center for at least 4 years with at least 2 visits a year prior to the analysis. The size of the group was calculated based on the original data of 50 consecutive patients (power of 90%). Records were retrospectively analyzed with respect to office blood pressure (oBP) control. Additionally, within-visit blood pressure variability was calculated (difference of maximum and minimum BP from 3 measurements); body weight, age, sex, duration of hypertension, number of visits per year, seasonal BP variability, use of telemedical services, comorbidities and blood-lowering treatment were recorded.

Results

The values of systolic blood pressure (sBP) before and after the break in the whole group were 135.8 ± 17.1 mm Hg vs. 137.9 ± 19.5 mmHg; $P=0.08$, and a diastolic blood pressure (dBP) of 80.3 ± 11.4 mmHg vs. 82.6 ± 12.2 mmHg; $P=0.001$.

After adjusting for seasonal variation of blood pressure, the respective differences were: sBP: 134.8 ± 16.5 vs. 138.0 ± 19.4 ; $P=0.03$, and dBP: 79.4 ± 10.9 vs. 82.2 ± 11.9 ; $P=0.004$.

Before 2020, 61.4% of patients were controlled as BP <140/90 mmHg, whereas after the break in regular visits 55.5% ($P=0.21$).

Conclusions

Blood pressure control deteriorated during the COVID-19 pandemic in a group of patients requiring tertiary care for hypertension.

[1798] Proenkephalin level and its determinants in patients with end-stage kidney disease treated with hemodialysis and peritoneal dialysis

Authors: Wiktoria Grycuk, Zuzanna Jakubowska, MD

Affiliation: Department of Nephrology, Dialysis and Internal Medicine, Medical University of Warsaw

Trustee of the paper: Prof. Jolanta Małyszko, MD, PhD

Corresponding author: Wiktoria Grycuk (wiktoriagrycuk@gmail.com)

Introduction

Proenkephalin (PENK) has been recently shown to reflect glomerular dysfunction and predict new-onset acute kidney injury and heart failure. While previous studies investigated PENK utility as a biomarker in individuals with preserved renal function, PENK concentration in patients with end-stage kidney disease (ESKD) remains to be established.

Aim of the study

The aim of the study was to assess plasma PENK concentration in patients with end-stage kidney disease treated with hemodialysis (HD) and peritoneal dialysis (PD) and to investigate its correlation with renal function and heart failure. Additionally, we aimed to determine whether PENK is removed during hemodialysis session.

Materials and methods

88 patients with ESKD (41 females, 47%; median age 65 years [51-72]) undergoing HD (n=66, 75%) and PD (n=22, 25%) were enrolled in this cross-sectional study. Blood samples for PENK determination were collected before and at the end of the hemodialysis session in HD patients and at a single time point in PD patients. Plasma proenkephalin concentration was assessed using a sandwich ELISA immunoassay. Samples for measurement of creatinine, urea and NT-proBNP were drawn simultaneously. Renal function and cardiac status were determined based on the estimated glomerular filtration rate (eGFR) and ejection fraction (EF). Demographic and clinical variables were collected from patients' records. XLSLAT 2022 and STATA software were used for statistical analyses.

Results

The median (IQR) plasma PENK concentration in the overall population was 1.492 ng/ml (1.071-4.380). Both median eGFR (5 mL/min/1.73 m² [4-7] vs. 5 mL/min/1.73 m² [4-8], p=0.856) and plasma PENK levels (1.368 ng/ml [1.068-4.030] vs. 1.706 ng/ml [1.211-5.858], p=0.305) did not differ significantly between HD and PD patients. In HD patients, median PENK concentration was significantly higher before than after hemodialysis (1.368 vs. 2.06, p=0.003). No correlation was found between PENK level and urea (p=0.192), eGFR (p=0.922), duration of dialysis (p=0.637) and residual urine output (p=0.784). Heart failure (p=0.961), EF (p=0.361) and NT-proBNP (p=0.949) were not associated with increased PENK concentration.

Conclusions

Our results indicate that PENK is not removed during hemodialysis session. PENK concentration does not reflect renal function and cardiac status in patients with ESKD. Further research is required to establish the clinical utility of the new biomarker in patients with impaired kidney function.

[1815] FibroScan and FIB-4 calculator – how do they talk to each other?

Authors: Anna Olejarz, Mirela Hendel, Krzysztof Irluk

Affiliation: Department of Internal Medicine, Diabetology and Nephrology, Faculty of Medical Sciences in Zabrze, Medical University of Silesia, Katowice

Trustee of the paper: Dr hab.n.med. Katarzyna Nabrdalik, prof. SUM

Corresponding author: Anna Olejarz (anna.olejarz11@gmail.com)

Introduction

Determining the degree of fibrosis is essential for evaluating patients with liver steatosis because it is closely related to disease prognosis. Whereas the gold standard in the assessment of liver fibrosis remains liver biopsy, non-invasive methods like FibroScan or FIB-4 calculator are of great importance in everyday clinical practice.

Aim of the study

The aim of this study was to determine the cohesion between fibrosis assessment via FibroScan (a modified ultrasound examination of the liver) and the use of fibrosis index based on four factors (FIB-4), which is a calculator determining the probability of fibrosis on the basis of age, aminotransferases and platelet count.

Materials and methods

190 patients (with diabetes mellitus or obese ones without carbohydrates disorders) with liver steatosis underwent a FibroScan assessment and FIB-4 calculation. The stage of fibrosis in FibroScan is categorized as F0 (none) to F4 (advanced) whereas FIB-4 score is expressed as “advanced fibrosis excluded”, “further investigation” and “advanced fibrosis likely”.

Results

On the basis of FIB-4 calculator, 144 patients were categorized as “advanced fibrosis excluded”, which corresponded to the low stage of fibrosis in FibroScan, and amounted to 1 (1-2) (median and interquartile range 25-75%). “Further investigation” according to FIB-4 was advised for 36 patients, whose median and interquartile range 25-75% stage of fibrosis was 1 (1-2) based on FibroScan. Ten patients were assessed by FIB-4 as “advanced fibrosis likely” which corresponds with median and interquartile range 25-75% stage of fibrosis 2.5 (1.75-3.25) on the basis of FibroScan.

Conclusions

FIB-4 seems to be a valuable tool in everyday practice allowing for a good prediction of liver fibrosis especially in less advanced stages of fibrosis. Identification of patients with advanced liver fibrosis using FIB-4 calculator in our study seems to be less precise due to higher interquartile range. However interpretation of this data should be done with cautions because of a small sample of patients with “advanced fibrosis likely” identified by FIB-4. Further studies are needed on a larger group of patients.

[1865] Analysis of factors associated with frailty syndrome in patients with heart failure

Authors: Wiktoria Niegowska, Julia Szydlik, Marcelina Barszczewska, Olga Grodzka, Piotr Czapski, Katarzyna Januszewska

Affiliation: Klinika Chorób Wewnętrznych i Gerontokardiologii, Samodzielny Publiczny Szpital Kliniczny im. prof. W. Orłowskiego

Trustee of the paper: prof. dr hab. n. med. Piotr Jankowski, lek. Ada Sawicka

Corresponding author: Wiktoria Monika Niegowska (niegowskawiktoria@gmail.com)

Introduction

Frailty syndrome (FS) is a state present in elderly patients characterized by the body's inability to compensate stress factors.

Aim of the study

The purpose of this study was to determine factors associated with frailty syndrome in patients with diagnosed heart failure (HF).

Materials and methods

Patients hospitalized in the department were assessed for the presence of frailty syndrome using L. Fried criteria, Edmonton Frail Scale and Tilburg Frailty Indicator. Presence of arterial hypertension, diabetes, obesity, chronic obstructive pulmonary disorder (COPD), heart failure was included. Patients were assessed for the presence of depression using Beck's Depression Inventory (BDI). Physical capacity was assessed using NYHA classification.

Results

87 patients (mean age 81.4 ± 6.7 ; 57 women, 11 HF_rEF, mean NYHA 2.88 ± 0.99 ; 11 HF_mrEF, mean NYHA 2.3 ± 1.06 ; 65 HF_pEF mean NYHA 2.0 ± 1.10) were included in the final analysis. Multiple regression analysis showed significant relationship between FS assessed using Edmonton Frail Scale and age ($\beta=0.31$, SE=0.08; $p=0.000168$), presence of arterial hypertension ($\beta=-0.22$, SE=0.08; $p=0.00854$), COPD ($\beta=0.21$, SE=0.08; $p=0.0115$) and depression intensity ($\beta=0.61$, SE=0.08; $p=0.0000$). Significant relationship was also found between age ($\beta=0.39$, SE=0.09; $p=0.000058$), NYHA classification ($\beta=0.32$, SE=0.09; $p=0.000762$) and depression intensity ($\beta=0.35$, SE=0.09; $p=0.000259$) and FS assessed using L. Fried criteria and age ($\beta=0.23$, SE=0.10; $p=0.0222$) and depression intensity ($\beta=0.39$, SE=0.1; $p=0.000219$) and FS assessed using Tilburg Frailty Indicator. In multiple regression analysis heart failure phenotype was not significantly related to FS.

Conclusions

Age and depression intensity assessed using BDI are related to frailty syndrome in patients with heart failure. Presence of arterial hypertension and COPD are linked to FS assessed using Edmonton Frail Scale, whereas NYHA classification is linked to FS assessed with L. Fried criteria. We did not find an independent relationship between FS and HF phenotype.

[3005] Assessment of vascular age in patients with chronic kidney disease

Authors: Kateryna Gurska, Aleksandra Kaplina

Affiliation: Department of Propedeutics of internal medicine #2, Bogomolets National Medical University, Kyiv, Ukraine

Trustee of the paper: PhD Candidate, Associate Professor Olena Karpenko

Corresponding author: Kateryna Gurska (katarzynagurski@gmail.com, alexakaplina@gmail.com)

Introduction

Recently there is a tendency to increase the number of patients with chronic kidney disease (CKD), which requires the use of renal replacement therapy (RRT), namely hemodialysis. It needs permanent vascular access and depends on the structural and functional state of the vascular wall. This can be assessed by calculating vascular age (VA).

Aim of the study

Assessment of VA in patients with CKD, specifically end-stage renal disease (ESRD) and assessment of frequency of cardiovascular risk factors (CVR) in patients with ESRD.

Materials and methods

We used a two-part questionnaire for patients with ESRD on hemodialysis without severe comorbidities. The first part corresponded to the Framingham Risk Score for calculating the "Age of the heart/vessels". The second part concerned data on patients' CKD.

Results

The age of patients in the study ranged from 32 to 69 years, with an average of 54 years. Smoking was observed in 16.7% of examined. Most patients (80%) deny that they have diabetes mellitus (DM). Among 20% of patients with diabetes, 16.7% had II type, and 3.3% - I type of the disease. The maximum systolic blood pressure (SBP) in the majority (90% of patients) was above 160 mm Hg. But with the use of antihypertensive drugs, SBP significantly decreased - 50% reached the SBP of 140 mm Hg and less. Dyslipidemia was determined in 70%. The VA was significantly higher than the passport age (PA), reaching the maximum value (more than 80 years) in 73.3% of the examined. The average delta between VA and PA was +22 years. The maximum delta was +39 years. Duration of the disease from diagnosis to the time of the survey was 9.3 years. The average length of stay on hemodialysis at the time of the survey was 3.6 years. Glomerulonephritis (GN) was the most common nosology - 46.7% of patients. It should be clarified that 16.7% had combined forms. 6 patients (20%) had a history of previous difficulties with AVF functioning (thrombosis), which led to the need for repeated surgical interventions. In patients who had complications establishing a vascular access, the delta between VA and PA ranged from +28 to +33 years, which is much larger than the average delta in our sample.

Conclusions

High incidence of discrepancy between the vascular and passport ages (76 vs. 54 app.) of patients with end-stage renal disease. High frequency of risk factors in patients with ESRD (dyslipidemia - 70%, smoking - 16.7%, DM - 20%). Dependence between existing complications with vascular access and VA-PA delta. Need of further research and development of methods for angioprotection for patients who require hemodialysis.

Laboratory Medicine

Date: 22nd April 2023, 9:00 AM

Coordinators:
Julia Wiśniewska
Szczepan Wąsik

Patronage:

PTDL Oddział Warszawa
STDŁ Oddział Warszawa
Dziekan Wydziału Farmaceutycznego

[1675] NCAM-1/sCD56 concentration in serum of COVID-19 convalescents

Authors: Michalina Lulek, Agata Skwarek, Paweł Kozłowski, Marcin Śmiarowski, Olga Ciepiela

Affiliation: Students Scientific Group of Laboratory Medicine, Department of Laboratory Medicine, Medical University of Warsaw

Trustee of the paper: Olga Ciepiela

Corresponding author: Michalina Lulek (michalina.lulek@onet.pl)

Introduction

COVID-19 causes not only acute infection manifested mainly by respiratory symptoms, but various long-term complications, the mechanisms of which are still not fully understood. During the course of the disease a decrease in the natural killers (NK) cells can be observed. They are responsible for cytotoxicity and cytokine production during innate immunity response. Based on their clusters of differentiation – CD16 and CD56 – specific subpopulations can be distinguished using flow cytometry. Neural cell adhesion molecule 1 (NCAM-1), a glycoprotein expressed on the surface of neurons, glia, monocytes and NK cells as CD56, may appear in serum and indicate abnormalities in the number of NK cells.

Aim of the study

The aim of the study was to determine whether there are differences in the concentration of NCAM-1 in the serum of patients without reported COVID-19 in the past and in convalescents.

Materials and methods

Levels of NCAM-1 were established in the sera of 176 healthy adult blood donors registered at Regional Blood Donation Center in Warsaw, aged 18-65, without acute or chronic diseases neither under any medical treatment. Among them 90 reported COVID-19 infection in the past, and 86 did not declare previous SARS-CoV-2 positivity. After performing anti-nucleocapsid anti-SARS-CoV-2 IgG antibodies tests by Roche Diagnostics (Switzerland) 33 of 86 non-infected were assigned to the convalescents. In all subjects NCAM-1 concentrations were measured using enzyme-linked immunosorbent assay by Boster Bio (USA).

Results

During the statistical analysis, 4 outliers were discarded with the Grubbs test. The median NCAM-1 concentration in the convalescent group was 2496 pg/ml (379,3 ; 12618), and in the healthy group 2929 pg/ml (862,1 ; 16077). The Mann-Whitney test for non-parametric data showed that NCAM-1 levels were higher in the non-infected than in the patients who had COVID-19, with p value=0,0364. That indicates statistically significant differences between the groups.

Conclusions

According to the results, serum concentration of soluble NCAM-1 appears to be a marker of NK cells depletion as well as abnormal CD56 expression seen during COVID-19.

[1715] Endogenous cannabinoids in children and adolescents with Crohn's Disease

Authors: Michał Bochenek, Jan Tomasiak

Affiliation: Students' Research Society of Clinical Biochemistry, Jagiellonian University Medical College, Kraków, Poland

Trustee of the paper: prof. dr hab. Przemysław Tomasiak

Corresponding author: Michał Sebastian Bochenek (michalbochenek22@gmail.com)

Introduction

Crohn's Disease (CD) is one of the Inflammatory Bowel Diseases (IBD), affecting an increasing number of people. Recent research suggests that the endogenous cannabinoid system plays an important role in IBD, as CB-1 and CB-2 receptors are expressed on immune cells. Because of that, the main ligands activating said receptors, anandamide (AEA) and 2-arachidonoylglycerol (2-AG), are thought to intermediate the inflammatory activity, that lies at the bottom of CD. In particular, CD-2 activation seems to promote macrophage transformation toward the M2 form. Furthermore, CD-1 ligands regulate emesis and pain processing.

Aim of the study

Little is known about the secretion of endogenous cannabinoids in the course of IBD. Therefore, this study aimed to assess 2-arachidonoylglycerol (2-AG) and anandamide (AEA) concentration in children who suffered from IBD.

Materials and methods

We studied 20 children with CD, mean age of 12.8 ys \pm 2.9. The blood was collected three times – in an active phase of the disease (during admission to the hospital, before treatment), 2-4 weeks later during the consolidation of medical treatment, and month to 6 months later during remission. 20 age-matched healthy children served as a control group. In all cases, fasting samples were taken in the morning. The 2AG and AEA were measured in the serum using EIA kits (respectively ELK; Wuhan, China, and BT Lab; Shanghai, China).

Results

2-AG mean concentration in the study group was stable - acute phase 1019.7 \pm 804.3 pg/ml, during treatment 987 \pm 792.3 pg/ml; remission 1036.2 \pm 696.1 pg/ml and similar to the values observed in control group 1081.1 \pm 768.2 pg/ml. There were not any significant differences between all study groups and versus controls ($p > 0.61$ in all cases).

In the study group before treatment median concentration of AEA was 2.60 \pm 0.61 ng/ml, and similar during the treatment 2.63 \pm 0.62 ng/ml, and in the remission - 2.44 \pm 0.61 ng/ml. All these values were lower as compared to values observed in the control group – 3.2 \pm 0.61 ng/ml ($p = 0.047$, $p < 0.056$, $p < 0.043$ respectively).

Conclusions

2-AG levels weren't disturbed in children with IBD. Interventions aiming to increase AEA-related signaling, such as the administration of its analogs or fatty acid amide hydrolase inhibitors may alleviate symptoms related to Crohn's Disease in children.

[1877] What is the frequency of electrolyte disturbances in hospitalized patients?

Authors: Aleksandra Wiśniewska, Magdalena Modliborska, Juliusz Łukasik, Milena Małecka-Giełdowska

Affiliation: Medical University of Warsaw/Students Scientific Group of Laboratory Medicine

Trustee of the paper: Milena Małecka-Giełdowska

Corresponding author: Aleksandra Wiśniewska (wisniewska_aleksandra@o2.pl)

Introduction

Evaluation of electrolyte concentration is an important element of monitoring hospitalized patients. The balance of the body's potassium economy is determined by its absorption and excretion. The kidneys, digestive tract and transmembrane transport are responsible for keeping the correct K⁺ concentration. Disturbances in the Na⁺ and K⁺ balance are among the most common disorders in hospitalized patients.

Aim of the study

To analyse the frequency of electrolyte disturbances in hospitalized patients.

Materials and methods

A retrospective study assessed the electrolyte parameters in a group of 121827 patients hospitalized in 2019-2023 at the University Clinical Center of the Medical University of Warsaw. We examined electrolytes concentration in patients' serum using a potentiometric method and measuring the electromotive force with ion-selective electrodes, on Siemens Dimension EXL and Roche Cobas c501.

Results

The serum Ca²⁺ concentration was tested in 75621 patients (57% men, 43% women, median Ca²⁺ level 2.53mmol/L (2.34;2.64). There were 38% patients with hypocalcemia (median 2.18mmol/L (2.01;2.41) for men (47%), 2.09mmol/L (1.99;2.20) for women (53%), p<0.001), 41% with normocalcemia (45% men, 55% women, median Ca²⁺ level 2.38 mmol/L (2.21;2.53) and 23% with hypercalcemia (median 2.79mmol/L (2.75;2;82) for men (48%), 2.88mmol/L (2.79;2.98) for women (52%), p=0.0032). The serum Na⁺ concentration was tested in 121827 patients (51% men, 49% women, median Na⁺ level 141mmol/L (138;144). There were 40% patients with hyponatremia (median 131mmol/L (128;133) for women (57%), 128mmol/L (126;130) for men (43%), p<0.01), 38% with normonatremia (43% men, 57% women, median Na⁺ level 143mmol/L (140;146) and 22% with hypernatremia (median 151mmol/L (148;154) for men (52%), 148mmol/L (145;152) for women (48%), p=0.0400). The serum K⁺ concentration was tested in 121827 patients (49% men, 51% women, median K⁺ level 3.71mmol/L (3.42;3.82). There were 38% patients with hypokalemia (median 3.01mmol/L (2.89;3.20) for women (51%), 3.12mmol/L (3.05;3.24) for men (49%), p<0.002), 34% with normokalemia (34% men, 66% women, median K⁺ level 4.03mmol/L (3.92;4.18) and 28% with hyperkalemia (median 5.19mmol/L (5.07;5;31) for men (62%), 5.51mmol/L (5.34;5.64) for women (38%), p=0.0001).

Conclusions

We can conclude that among hospitalized patients Ca²⁺, Na⁺ and K⁺ metabolism might significantly change and differ among genders. Electrolyte changes in older age mostly occur due to renal or heart diseases, drug intake and lower water percentage.

[1908] Mutational profile in unresectable soft tissue sarcomas

Authors: K. Bobak, A. Tysarowski, K. Seliga, M. J. Spalek, A. Szumera-Ciećkiewicz, K. Sokół, M. Wągrodzki, H. Kosela-Paterczyk, P. Rutkowski and A. M. Czarnecka

Affiliation: Maria Skłodowska-Curie National Research Institute of Oncology, Department of Soft Tissue/Bone Sarcoma and Melanoma, Warsaw, Poland

Trustee of the paper: Anna M. Czarnecka

Corresponding author: Klaudia Małgorzata Bobak (klaudia.bobak@pib-nio.pl)

Introduction

Locally advanced unresectable soft tissue sarcomas (STS) require intensive preoperative treatment before limb-sparing or conservative surgery. Unresectable sarcomas remain, therefore, a treatment challenge for clinicians due to the lack of standard treatment. Identification of a molecular biomarker of the pathological response (PR) would aid in the diagnosis and treatment of this group of patients. However, molecular profile of STS are still poorly understood.

Aim of the study

The study aimed to identify a diagnostic or predictive biomarker in STS.

Materials and methods

We analysed preoperative core biopsy samples of 19 patients who participated in the phase II clinical trial (NCT03651375). Enrolled patients included 10 patients with undifferentiated pleomorphic sarcoma (UPS), 5 patients with myxofibrosarcoma (MFS), 1 patient with leiomyosarcoma (LMS), 1 patient with pleomorphic liposarcoma (PLPS), 1 patient with dedifferentiated liposarcoma (DDLPS), and 1 patient with malignant peripheral nerve sheath tumor (MPNST). Patients were treated 5×5 Gy radiotherapy combined with 3 cycles of doxorubicin-ifosfamide chemotherapy. The PR was assessed using the European Organization for Research and Treatment of Cancer-Soft Tissue and Bone Sarcoma Group (EORTC-STBSG) recommendations. For Next-Generation Sequencing (NGS) Illumina NGS TruSight Oncology 500 kit was used. For pathological prediction the VarSome genome browser was used.

Results

In the analysed group, a good PR to neoadjuvant chemoradiotherapy were reported in five cases (grades A = 1, B = 1, C = 3, D = 9, E = 5). In four UPS and MFS cases with favourable response to therapy, we identified the KDR gene missense mutation (p.Q472H c.1416A>T) with a benign pathogenic prediction. In UPS patients with significant PR duplication of the SH2B3 gene and PALB2 gene deletion (p.Q60Rfs*7 c.172_175delTTGT) causing frameshift and STOP codon were detected. In two different cases (PLPS, DDLPS), two different missense mutations of POLE gene were identified. Additionally, in one UPS case with poor response to treatment, a mutation of the TERT promoter gene was detected.

Conclusions

The missense mutations of POLE gene may be potential candidates for diagnostic biomarker for liposarcomas. However, more research is needed on a larger group of patients.

[1909] **Mutational signatures of chondrosarcoma using next-generation sequencing**

Authors: Agnieszka E. Zajac, Jakub Piątkowski, Paweł Golik, Anna Szumera-Ciećkiewicz, Paweł Teterycz, Andrzej Tysarowski, Anna M. Czarnecka, Piotr Rutkowski

Affiliation: Maria Skłodowska-Curie National Research Institute of Oncology, Department of Soft Tissue/Bone Sarcoma and Melanoma

Trustee of the paper: Piotr Rutkowski

Corresponding author: Agnieszka Ewa Zajac (agnieszka.zajac@pib-nio.pl)

Introduction

Chondrosarcoma (ChS) is the second most common primary bone tumor which belongs to the group of bone sarcomas. Genetics and roles of particular mutations in ChS progression are still poorly understood, due to its rarity of occurrence and heterogeneity. The most common genetic changes include IDH1/IDH2, TP53, COL2A1, EXT/EXT2, MDM2, and CDKN2A mutations. Treatment of these tumors is limited only to surgery and there is a lack of other therapeutic options, due to their resistance to chemo- and radiotherapy.

Aim of the study

The aim of this study was to identify potentially pathogenic mutations in different subtypes of ChS, which may contribute to development of this tumor.

Materials and methods

In the study 62 patients with primary ChS were enrolled (female/male ratio: 1/1.38, median age: 47.5 with range 21-91 years; subtypes: 22 G1, 25 G2, 10 G3, 4 dedifferentiated, 1 mesenchymal; diagnosed between 2011-2019). All patients were radically treated by surgery, with the exception of mesenchymal case (treated additionally with adjuvant radiotherapy). DNA was isolated from formalin-fixed paraffin-embedded (FFPE) tissue from primary tumor. Mutational profile and tumor mutational burden (TMB) were analyzed by Next Generation Sequencing (NGS) using a targeted panel of 409 genes (OncoPrint™ Tumor Mutation Load Assay). Microsatellite instability (MSI) was analyzed by Idylla™ MSI Test.

Results

The average TMB of all patients was low (3.91 mutations/Mb) and none of them had MSI. IDH1/IDH2, genes related to chromatin remodelling (i.e. ATRX, ARID1A, KDM5C, SETD2), genes related to cell proliferation and differentiation signaling pathways (i.e. GPR124, LRP1B), and cell cycle controlling genes (i.e. TP53, ATR) were the most frequently mutated. IDH1/2 mutations were found in 32% of patients in all subtypes of ChS, beside mesenchymal. TP53 and RB1 suppressor genes were observed in 14% of patients and only in high grades ChS (G2, G3 and dedifferentiated). Other genes, related to Hedgehog pathway, PTCH1 and SUFU were observed in 8% of cases (low and high grade ChS, beside mesenchymal ChS). Moreover, in high grade subtypes (G2, G3 and dedifferentiated) amplifications in genes related to tumor growth and cell proliferation pathways were observed (e.g. AKT2/3, PIK3R2, MAP2K2, FGFR1, JAK3).

Conclusions

Mutational status analysis suggests that p53 signaling pathway and PI3K-AKT-mTOR, MAPK/ERK and JAK/STAT pathways may play role in ChS progression and pathogenesis of high grade ChS.

[1951] Is there a relationship between IGF-1, GH, and parameters of lipid metabolism?

Authors: Ilona Zembrzuska-Kaska, Paulina Kludkiewicz, Wiktoria Klus

Affiliation: Students Scientific Group of Laboratory Medicine, Medical University of Warsaw, Warsaw, Poland

Trustee of the paper: mgr Milena Małeczka-Giełdowska 1.Department of Laboratory Medicine, Medical University of Warsaw, Warsaw, Poland; 2.Central Laboratory, Central Teaching Hospital of University Clinical Center of Medical University of Warsaw, Warsaw, Poland

Corresponding author: Ilona Zembrzuska-Kaska (ilona.z.kaska@gmail.com)

Introduction

Growth hormone (GH) release is inhibited by somatostatin, glucose, glucocorticoids, fatty acids, L-dopa, and beta-blockers, and later is regulated by the concentration of circulating GH and IGF-1 on a negative basis feedback. Insulin-like growth factor 1 (IGF-1) is a small molecule, similar to the proinsulin molecule. It is produced by the liver as a result of the action of growth hormone on the liver cells, and its role is to regulate the growth of the body. The concentration of IGF-1 depends on age and sex- the lowest concentration occurs immediately after birth, and the highest during the period of intensive growth and maturation, and remains at such a high level until the age of 40 and then gradually decreases.

Aim of the study

The aim of the study was to assess the correlation between IGF-1, GH and lipid parameters serum concentrations.

Materials and methods

The method used for the determination of GH was the ECLIA electrochemiluminescence method, using the Cobas e602 analyzer. IGF-1 concentrations were marked in blood serum on the LIAISON XL analyzer with the CLIA method, the one-stage, chemiluminescent immunoassay test. In the study we also assessed the concentration of C-peptide, insulin and glucose in the group of patients included in the study. The first study group consisted of 1073 adult patients without lipid metabolism disorders, while the second group consisted of 1013 patients with lipid metabolism disorders.

Results

The retrospective analysis provided the following results: in the first group, the median IGF-1 concentration in adult patients was 91.0 ng/ml (78.0;101), while in the second group, it was 165 ng/ml ($p=0.001$). Statistically significant difference was found for cholesterol concentration 215mg/dl (190;228) for the first group and 279 mg/dl (249;299) for the second group, $p=0.0251$.

In the study, statistically significant differences were also observed in GH, triglycerides and glucose concentration. Concentration of GH was 25 μ g/l (20;31) in the first group and 15 μ g/l (11;19) in the second, $p=0.0350$. Triglyceride concentrations medians in the first group was 195 mg/dl and second group 249 mg/dl ($p<0.0001$). Glucose concentration was 101mg/dl (95;108) in the first group and 165mg/dl in the second group, $p=0.010$.

Conclusions

Dyslipidemia is associated with increased IGF-1 and low GH concentration. Thus, it can be concluded that lipids disorders influence metabolic action of endocrine system.

[2001] Is thrombocytopenia more common in patients hospitalized in the emergency room or intensive care unit?

Authors: Aleksandra Kumorek 3, Aleksandra Kijak 3 , Małeczka-Giełdowska Milena 1,2

Affiliation: 1.Department of Laboratory Medicine, Medical University of Warsaw, Poland, 2.Central Laboratory, University Clinical Center of Medical University of Warsaw, Poland, 3.Students Scientific Group of Laboratory Medicine, Medical University of Warsaw, Poland

Trustee of the paper: Małeczka-Giełdowska Milena

Corresponding author: Aleksandra Kumorek (aleksandra.kumorek@gmail.com)

Introduction

Thrombocytopenia due to reduced platelet production occurs in bone marrow aplasia, non-effective thrombopoiesis and dysfunctions in the regulatory mechanisms of platelet production. The characteristic symptom of thrombocytopenia is the presence of petechiae on the skin and mucosa.

Aim of the study

The study aimed to show whether there are differences between the number of platelets and platelet parameters in patients from the hospital emergency room (ER) and patients hospitalized in the intensive care unit (ICU).

Materials and methods

Platelets count (PLT) and platelet parameters were determined using an automated hematology analyzer Sysmex XN2000. In the study results of 1114 patient from ICU, including 621 women aged 57 ± 4 years old and 493 men aged 51 ± 5 y.o. and 1191 patients from ER, including 581 women aged 54 ± 3 y.o. and 610 men aged 52 ± 6 y.o., were enrolled.

Results

The mean PLT count in women from ICU was $96\times 10^3/\mu\text{l} \pm 19.1$, and in men from ICU $111\times 10^3/\mu\text{l} \pm 9.7$. The mean PLT count in women from ER was $143\times 10^3/\mu\text{l} \pm 11.3$ and in men from ER $133\times 10^3/\mu\text{l} \pm 14.5$. The mean immature platelet fraction (IPF) for the ICU group of women was $5.71\pm 0.33\%$ and for men $4.71\pm 0.48\%$, while for ER women group it was $3.22\pm 0.19\%$ and for ER men group $4.35\pm 0.13\%$. PLT and IPF differed significantly between women hospitalized in ICU and women from ER, $p<0.001$ and $p=0.007$, respectively. Difference in the number of platelets in ICU and ER men was statistically significant, $p=0.001$.

Conclusions

Our study shows that in patients hospitalized in the ICU, platelet production in the marrow is more strongly stimulated despite the patients' thrombocytopenia.

Laryngology, Audiology & Phoniatrics

Date: 21st April 2023, 10:00 AM

Coordinators:
Julia Śladowska
Zosia Jedral

[1599] Analysis of mastoid portion of facial nerve course in temporal bone using computed tomography

Authors: Paulina Szot, Iga Płachta, Emilia Nagórska, Eliza Brożek-Mądry

Affiliation: Department of Otorhinolaryngology, Faculty of Dentistry, Medical University of Warsaw, Warsaw, Poland

Trustee of the paper: Eliza Brożek-Mądry

Corresponding author: Paulina Maria Szot (paulinaszotszkolny@gmail.com)

Introduction

The facial nerve (FN) follows a complex route in the temporal bone. Successful temporal bone surgery requires knowledge of its course which can be achieved using imaging methods such as computed tomography.

Aim of the study

This investigation aims to analyze the FN course in its mastoid portion and second genu and the frequency of its atypical course.

Materials and methods

This is a retrospective study that enrolled 104 CT scans of temporal bones of patients followed up in the outpatient clinic of the Otorhinolaryngology Department of Dentistry Faculty of the Medical University of Warsaw between 2020 and 2022. FN courses were classified as straight, bulging, or letter "S" like. Other parameters estimated:

- position of the second genu according to the prominence of the lateral semicircular canal (classified as lateral, medial, or middle) and its distance from a line adjacent to the lateral semicircular canal was measured.
- the distance between the short process of the incus and the outermost point of the second genu.
- the course of the mastoid portion of the FN and the location of SG in comparison to the tympanic portion of n. VII. The course was later classified as lateral, medial, or middle.

Results

Among the 104 assessed temporal bones, the course of the mastoid portion of the FN was classified as bulging in 47 cases (45.2%). Straight and letter "S"-like courses were present in 41 (39.4%) and 16 (15.4%) cases, respectively. Deviation of the second genu according to the prominence of the lateral semicircular canal was medial in 86 cases (82.7%), and middle in 4 cases (3.8%). In the rest, second genu was paramedian to the prominence of the later circular canal. The mean distance between the short process of incus and the outermost point of SG was 4.9 mm (± 0.73 mm). The mastoid portion was located laterally, medially and in the middle of the tympanic portion plane in respectfully 4.8%, 83.7%, and 11.5%. The second genu was located laterally, medially and in the middle of the tympanic portion plane in respectfully 1.9%, 73.1%, and 25%. In conclusion, seven temporal bones (6.7%) of five patients presented with a lateral displacement of the FN in relation to established anatomical landmarks.

Conclusions

Although the atypical course of the FN, including the lateral displacement of the mastoid portion, is rare, screening for it is crucial before surgical exploration.

[1761] Colour analysis of endoscopic images for objective diagnosis of nasal mucosal diseases

Authors: A.K.Krievina, E.Eliasa-Vigante, S.Konuhova, K.Peksis, U.Rubins, J.Spigulis

Affiliation: (1) University of Latvia Faculty of Medicine, (2) ENT clinic "Headline", (3) Institute of Atomic Physics and Spectroscopy, Biophotonics Laboratory, University of Latvia

Trustee of the paper: A.K.Krievina

Corresponding author: Agate Kristena Krievina (agate.krievina@gmail.com)

Introduction

Pathological processes cause the nasal mucosa to change its structure and composition, the presence of different cells, changes in chemical composition, dilation or constriction of blood vessels - all these change the colour of the mucosa. The otorhinolaryngologist makes a subjective diagnosis by examining the patient with an anterior rhinoscopy. Diseases of the nasal mucosa are common in ENT practice, with an average of one in three patients presenting to a specialist with a complaint of a disease of the nasal mucosa or symptoms caused by it. Colour vision varies between people, so some non-invasive method of objective examination is needed to clarify the diagnosis.

Aim of the study

To determine whether spectroscopy can be used to quantify changes in the nasal mucosa from images and videos obtained during nasal endoscopy on the surface of the inferior nasal turbinates in different diseases of the nasal mucosa: acute rhinosinusitis, chronic inflammation (vasomotor or other cause), chronic hyperplastic and allergic nasal mucosa.

Materials and methods

The study participants (66 in total, 36 healthy or control group, 10 chronic hyperplastic, 9 chronic inflammatory, 10 acute rhinosinusitis, 5 allergic) underwent anterior nasal endoscopy, prepared and stored the material in video format. The Karl Storz TP 200 endoscope system with a video camera was used to acquire the material. The videos were then analysed on a computer using Matlab software. The analysis algorithm consists of manually selecting the region of interest (inferior nasal turbinate), segmenting the image, and then averaging the pixels in [RGB] and [L*a*b] colour scales.

Results

Generally positive values of [a, b] depend largely on the degree of inflammation of the nasal mucosa. The results of the study showed that [a] values were higher in chronic inflammatory and acute rhinosinusitis (35+/-3), while [a] values were slightly lower in chronic hyperplastic nasal mucosa (24+/-3), compared to the control group (27+/-4).

Conclusions

There is a large statistical spread in the control group. Spectroscopic analysis can distinguish between healthy and inflamed nasal mucosa. Chronic inflammation and acute rhinosinusitis have higher [a] values. Chronic hyperplastic nasal mucosa has lower [a] values. Slightly higher [b] values for allergic mucosa, but the number of participants in this group was too small for the group results to be considered conclusive. This study is a pilot study which is planned to be continued.

[1839] Elastography as a complement method to ultrasound diagnostics of salivary gland pathology.

Authors: Marta Mękarska [1], Maria Molga - Magusiak MD [2]; Przemysław Krawczyk MD [2]; Anna Rzepakowska PhD, DSc, [2];

Affiliation: [1] Students Scientific Research Group, Otorhinolaryngology Department, Head and Neck Surgery, MUW, ul. Banacha 1a, 02-097, Warsaw, Poland. [2] Department of Otorhinolaryngology, Head and Neck Surgery, MUW, ul. Banacha 1a, 02-097, Poland

Trustee of the paper: Anna Rzepakowska PhD, DSc

Corresponding author: Marta Zofia Mękarska (marta.mekarska@gmail.com)

Introduction

Salivary gland tumors are responsible for 3 to 6% of all head and neck tumors, accounting for 0.2% of all cancers. 80% of them are located in the parotid gland in its superficial part; 80% of parotid tumors are benign. The WHO classification from 2017 distinguishes 11 benign and 22 malignant histological types of salivary gland tumors. Such diversity may cause problems in making an accurate diagnosis. The gold standard in the treatment of salivary gland tumors is their surgical resection. When performing the parotid excision special attention should be paid to the course of the facial nerve due to the risk of its postoperative paralysis. Ultrasound (US) examination is the basis for the diagnosis of inflammatory and neoplastic lesions of the salivary glands. Elastography is a modern option performed as a supplement to classic ultrasound imaging. There are two types of elastography: strain elastography and shear wave elastography (SWE). Currently, SWE is considered the more objective and reliable method.

Aim of the study

The aim of this study is to determine the usefulness of SWE in the diagnosis of salivary glands pathologies. So far, there are only a few literature reports on this subject. The introduction of this method to the routine assessment of inflammatory and neoplastic lesions of the salivary glands may contribute to the increase in the sensitivity and specificity of US.

Materials and methods

Patients with different changes in the salivary gland pathology underwent ultrasound and SWE test. The diagnosis was confirmed by postoperative histopathological examination. All of the ultrasound data were evaluated and analyzed.

Results

In salivary glands lesions, the stiffer areas were more extensive in malignant tumors than in benign one. In chronic inflammation of the salivary glands, tissue stiffness was also increased but not as high as for malignant pathologies.

Conclusions

The usefulness of SWE test has been proven in the assessment of many types of tumors, primarily in the liver and breast, as well as in the examination of the thyroid and prostate gland. Differences in parenchyma stiffness in lesions within the salivary gland and differences in the results of SWE examination may in the future help in the preoperative assessment of the lesion. This may affect the method of further treatment and the choice of surgical technique.

[1856] The impact of tumor stroma factors in advanced laryngeal cancer

Authors: Joanna Olędzka [1], Łukasz Fus MD, PhD [2], Michał Żurek MD [3], Anna Rzepakowska PhD, DSc [3]

Affiliation: [1] Students Scientific Research Group, Department of Otorhinolaryngology, Head and Neck Surgery, Medical University of Warsaw; [2] Department of Pathology, MUW; [3] Department of Otorhinolaryngology, Head and Neck Surgery, MUW

Trustee of the paper: Anna Rzepakowska PhD, DSc

Corresponding author: Joanna Olędzka (jo.oledzka@gmail.com)

Introduction

Tumor stroma plays a significant role in growth and spread of cancer cells, therefore it became a research target both for prognostic and predictive factors. Clinical correlation of histopathological features as tumor budding, small cell nests size at the core and the front tumor area and high amount of stroma, especially fibroblastic type, with patients' survival and treatment outcomes, has been confirmed significant in the colorectal carcinoma. The initial reports suggest the essential role of these parameters in the laryngeal cancer as well.

Aim of the study

The aim of the study was to explore the prognostic and predictive role of selected tumor stroma factors in advanced laryngeal squamous cell cancer.

Materials and methods

This retrospective study included results of histopathological examinations of 65 patients (9 women and 56 men) at the age ranged from 43 to 91, with laryngeal cancer (supraglottic, glottic, subglottic, transglottic; stage III or IVa), treated with total laryngectomy. The following parameters were evaluated: tumor budding activity (BA), tumor-stroma ratio (TSR), cell nests size (CNS), stroma type and lymphocytic host response. They were correlated with clinical data: overall survival (OS), disease free survival (DFS), primary tumor size and nodal status (T and N from TNM staging classification).

Results

Tumor budding occurred in 17 patients with T3 and 6 with T4 ($p=0.447$), 16 with N0, 7 with N+ ($p=0.913$). $TSR \geq 50\%$ (stroma-rich) was observed in 28 with T3 and 7 with T4 ($p=0.831$), 26 with N0 and 9 with N+ ($p=0.412$). Fibroblastic stroma was noted in 25 patients with T3 and 7 with T4 ($p=0.856$), 22 with N0 and 10 with N+ ($p=0.778$). Intense lymphocytic reaction was found in 9 with T3 and 3 with T4 ($p=0.656$), 9 with N0 and 3 with N2 ($p=0.262$). There was revealed no statistically significant correlation between histological tumor features and TNM staging, overall survival or disease free survival.

Conclusions

Histopathological parameters of laryngeal tumor stroma require further research on a larger group of patients to specify with certainty their prognostic and predictive value.

[1887] The usefulness of selected olfactory tests in diagnostics of young Polish children

Authors: Anna Bohdziewicz, Julia Wiśniewska, Rafał Jowik, Karolina Dżaman

Affiliation: Department of Otolaryngology, The Medical Centre of Postgraduate Education, 01-813 Warsaw, Poland

Trustee of the paper: PhD, prof. Education Karolina Dżaman

Corresponding author: Anna Bohdziewicz (bohdziewicz99@gmail.com)

Introduction

The ability to perceive odors is important for humans, as it serves as a protective mechanism against danger and can affect quality of life, even in children. Olfactory function can be modulated by repeated exposure to odors, presenting challenges in olfactory testing, especially for children with less exposure to smells. There is considerable variability in odor recognition in different age groups of children and geography regions. Many olfactory tests are available, including the 'Sniffin' Sticks' test and the children's version, 'Sniffin' Kids', which uses 14 smells instead of 16 odors. A recent study in Poland developed a simple 6-odors test.

Aim of the study

This study aimed to assess the utility of three olfactory tests - 'Sniffin' Sticks', 'Sniffin' Kids', and the 6-odors test in the group of 4-7-year-old Polish children.

Materials and methods

The present study enrolled a group of 70 healthy Polish children - 35 girls and 35 boys, aged between 4 and 7 years. Participants were subjected to three olfactory tests. The statistical analysis was conducted using the Statistica 6.0 software.

Results

Normosmia, defined as 70% correct answers in each test, was confirmed in 8.6% of the children based on 'Sniffin' Kids' and 'Sniffin' Sticks' test results, and in 78.57% of kids diagnosed with the 6-odors test. Those results were statistically different. The average time needed to perform both Sniffin tests was 15 minutes, and 5 minutes were needed for the 6-odors test.

Conclusions

The 6-odors test is more suitable than 'Sniffin' Kids' and 'Sniffin' Sticks' test as a screening olfactory method in young Polish children, because includes fragrances that are more recognizable for Polish children and is easier and quicker to administer. Both Sniffin tests, performed in Polish children aged 4-7 years, provided an overdiagnosis of olfactory disorders, probably caused by unfamiliarity with the used fragrances.

[1895] Hearing screening of school children from the Silesian Voivodeship

Authors: Mędrek E.1, Świerniak W.2, Skarzynski P.H.1,2

Affiliation: 1. Students' Scientific Association of Otolaryngology, WM.CM Faculty of Medicine, Cardinal Stefan Wyszyński University, Warsaw, Poland, 2. Department of Teleaudiology and Screening, Institute of Physiology and Pathology of Hearing, Warsaw, Poland

Trustee of the paper: Skarzynski P.H.

Corresponding author: Eliza Weronika Mędrek (e.medrek@student.uksw.edu.pl)

Introduction

Hearing screening in children is important in detecting hearing disorders. Early detection of the disorder is crucial for implementation of therapy and the child's subsequent normal development. Children with hearing disorders can suffer from delayed speech and cognitive disabilities.

Aim of the study

Early detection of hearing disorders in school-aged children in the Silesian Voivodeship and increasing public awareness of hearing disorders.

Materials and methods

In the study included 2364 children (1208 girls and 1156 boys) aged 6 to 9 from 238 schools in the Silesian province. An audiometric examination and audiological questionnaire were performed on each child. Screening pure-tone audiometry examination were performed for air conduction in the frequency range of 0.5-8kHz using the Platform for Sensory Organs Examination. Results of audiometric hearing tests were automatically collected in a central database „SZOK”®. An audiometric screening result was considered abnormal if the hearing threshold was above 20 dB HL at one or more frequencies in at least one ear.

Results

A normal result of the hearing screening test was obtained by 1970 children (83.3%). Abnormal results were obtained by 394 children (16.7%). No significant gender difference was found in this aspect. Children who had an abnormal hearing screening result were more likely to experience tinnitus. The percentage of children with tinnitus in the group with an abnormal hearing screening result was 16.7%, which was significantly higher than in the group of children with a normal hearing screening result (12.6%).

Conclusions

This study presents estimated data on screening pure-tone audiometry school-aged children from the province of Silesia. It is shown that hearing problems are common in this population. Early therapeutic, diagnostic and rehabilitative management is essential for the proper development of a child with hearing disorders. Therefore, there is a need for systematic monitoring of children's hearing.

[1957] **Plasmacytoma of the larynx - single-centre experience and literature review.**

Authors: Arkadiusz Moskwa

Affiliation: Students' Scientific Group at the Department of Otorhinolaryngology, Head and Neck Surgery, Medical University of Warsaw, Poland

Trustee of the paper: Elżbieta Szczepanek MD; prof. Kazimierz Niemczyk, MD, PhD; Anna Rzepakowska, MD, PhD; prof. Krzysztof Jamroziak, MD, PhD

Corresponding author: Arkadiusz Jan Moskwa (amoskwa2001@gmail.com)

Introduction

Plasma Cell Myeloma (PCM) usually occurs as an infiltration of the bone marrow. The systemic disease may be diagnosed with laryngeal involvement (PCM-L) or just as a single manifestation of an extraosseous lesion, called a single extramedullary plasmacytoma (sEMP).

Aim of the study

The aim of this study was to perform retrospective single-centre analysis of patients diagnosed with plasmacytoma of the larynx (both solitary and in the course of bone marrow disease). The second aim was to demonstrate literature review in this topic.

Materials and methods

A retrospective single-centre analysis of cases of sEMP-L or PCM-L was performed. Then PubMed/Medline search for case reports or case series with PCM manifesting in the larynx was conducted.

Results

Six patients (two sEMP-L and four PCM-L) were identified in our Centre from 2009 to 2021. The literature search was performed for papers released until April 2022. We compared demographic and clinical data between the groups of patients with sEMP-L and PCM-L in the combined cohort of patient cases identified through our single-centre analysis and PubMed/Medline literature review. The median age of patients from the sEMP-L group was 56.0 years, while patients with secondary involvement of the larynx (PCM-L) had a median age of 64.0 years ($p < 0.001$). Patients with sEMP-L had supraglottis, glottis, or both localisations involved in 75.4% of cases, while in those with PCM-L, these localisations were involved in 48.7% ($p = 0.0027$). The cartilages of the larynx were not involved in 97.8% of patients with sEMP-L, but such involvement was relatively common (30.8%) in patients with PCM-L ($p < 0.001$). We compared the OS between patients with sEMP-L and PCM-L. As expected, the patients with PCM-L had less favourable prognosis than cases with sEMP-L with 5-year OS of 55% (95% CI, 40–74%) vs. 86% (95% CI, 79–94%) and 10-year of 55% (95% CI, 40–74%) vs. 81% (95% CI, 72–90%), respectively.

Conclusions

PCM with laryngeal involvement is rare. Secondary involvement of the larynx during PCM might be more common than sEMP-L and is associated with reduced survival. The involvement of cartilage adversely influences the outcome of sEMP-L.

[1539] Chronic otorrhoea after ventilation drainage. Complicated association of otorhinolaryngological diseases based on the case of a 3-year-old patient.

Authors: Wiktoria Baczewska

Affiliation: Student Scientific Audiological and Phoniatic Club, Department of Otolaryngology, Pediatric Hospital of Medical University of Warsaw

Trustee of the paper: Dr Tomasz Lis, Dr hab. n. med. Lidia Zawadzka-Głós

Corresponding author: Wiktoria Baczewska (wiki1601@o2.pl)

Background

Chronic otitis media with effusion (OMS) is a disease in which obstruction of the eustachian tube causes fluid to accumulate in the tympanic cavity. Ventilation drainage is the most effective procedure. Submucosal cleft palate (SMCP) is a congenital craniofacial defect whose etiology is associated with the time of fetal palate formation. This type of cleft is difficult to recognize, which often results in a late diagnosis.

Case report

The patient was referred to the Department of Pediatric Otorhinolaryngology with a diagnosis of bilateral OMS. It was decided to perform a ventilation drainage procedure. Less than 2 months, the patient was admitted to the hospital with persistent bilateral leak. The diagnosis: chronic, purulent and unspecified otitis media. Swab results showed an increase in unusual pathogens, including the alarm pathogen MRSA [*Staphylococcus aureus*]. During the phoniatic consultation claimed palatine-pharyngeal occlusion and SCMP. In resulted it was the qualification for pharyngoplasty surgery.

Conclusions

The patient is under the constant care of otorhinolaryngologists, phoniaticists, (neuro)speech therapists and surgeons. As a result of the pharyngoplasty procedure, the quality of life improved. The healing processes have not been fully completed but the patient is constantly rehabilitating.

[1554] **Diagnosis and treatment of schwannoma of the parapharyngeal space on the example of a 14-year-old male patient**

Authors: Julia Dwornik

Affiliation: Student Scientific Audiological and Phoniatic Club, Department of Otolaryngology, Pediatric Hospital of Medical University of Warsaw, Poland

Trustee of the paper: lek. Magdalena Frąckiewicz, dr hab. n. med. Lidia Zawadzka-Głós

Corresponding author: Julia Anna Dwornik (juliaromeo@vp.pl)

Background

Tumors of the parapharyngeal space are just 0,5% of head and neck cancers, and only 30% of them are neurogenic tumors such as schwannoma, also called neurilemoma. Schwannoma is a benign tumor that arises from the Schwann cells of the myelin sheaths of nerves. If the tumor is in the parapharyngeal space, it may cause a sensation of a foreign body in the throat, dysphagia, and also inarticulate speech.

Case report

A male patient was diagnosed with a schwannoma in the right parapharyngeal space. The patient had a history of frequent nosebleeds and a feeling of discomfort in the throat for several months. The physical examination revealed asymmetry of the palatal arches and anisocoria. MRI was performed, and the patient was qualified for surgery to remove the tumor. He underwent it successfully. One day after the operation, the patient was diagnosed with symptoms of Horner's syndrome, which, according to the mother, had been present even before the surgery. Neurological and ophthalmological consultation was performed, and a genetic consultation was recommended.

Conclusions

The most common method of treating schwannoma of the parapharyngeal space is a radical surgery, which, due to the complex location of the parapharyngeal space, is not a simple procedure. Possible complications of it include e.g. hematomas and damage to numerous cranial nerves. It was possible to avoid serious difficulties in the described case and significantly improve the patient's quality of life. The follow-up examinations showed no recurrence of the disease.

[1585] **Audiological and otolaryngological issues in Goldenhar's syndrome**

Authors: Dr n. med. Monika Jabłońska- Jesionowska, Dr hab. n. med. Lidia Zawadzka-Głós, Bartosz Rigall, Magdalena Dziedzic

Affiliation: Student Scientific Audiological and Phoniatic Club, Department of Otolaryngology, Pediatric Hospital of Medical University of Warsaw, Poland

Trustee of the paper: Dr n. med. Monika Jabłońska- Jesionowska, Dr hab. n. med. Lidia Zawadzka-Głós

Corresponding author: Magdalena Dziedzic (mm.dziedzicc@gmail.com)

Background

Goldenhar's syndrome is a complex set of congenital abnormalities with unknown etiology. It may feature: craniofacial microsomia, eyes anomalies, skeletal alterations, cleft palate or diverse ear abnormalities. In a GHS, characteristic clinical findings include: dysfunction of cardiovascular, respiratory, genitourinary system. The most common diagnostic procedures in GHS are: head CT and MRI of the head and spine. Ophthalmoscopy and ABR are also in use.

Case report

This work depicts two cases of GHS. Two women, aged 1 and 9, present characteristic symptoms of this syndrome. The first patient was diagnosed with hypoplasia of the right temporal bone, atresia and microtia of the right ear. An ABR test was performed. Examination of the left ear shows preauricular tags. A cleft at the corner of the mouth, a shortened lingual frenulum, retrognathia was also observed. After consultation with laryngologist, it was decided to undercut the frenulum. The second patient was diagnosed with microtia and underdevelopment of the inner and middle ear of the left side. Examination of the right ear showed no abnormalities. Hypertrophy of the palatine and pharyngeal tonsils was found. The patient was diagnosed with chronic respiratory insufficiency. After an otolaryngological consultation, patient underwent a tracheostomy.

Conclusions

Patients are under doctor's observation. Due to the diagnostics and treatments, quality of life is improved. Based on presented work, the need for further diagnostics should be taken into account in order to diversify the cases, and their audiological and ENT problems in Goldenhar syndrome.

[1598] Case Report of Late Recurrence of Rare Middle Ear Neuroendocrine Tumor with Intracranial Extension to Temporal Fossa

Authors: Lukas Kvaščevičius

Affiliation: Faculty of Medicine, Vilnius University

Trustee of the paper: Inga Šatinskienė, MD

Corresponding author: Lukas Kvaščevičius (lukas.kvascevicus@gmail.com)

Background

We report a clinical case of an extremely rare neuroendocrine tumor in the right middle ear (MeNET) which relapsed after 13 years postoperatively and locally extended into the right temporal fossa. To our knowledge, there are around 150 cases of MeNETs in the present medical literature and even fewer cases with follow-up for more than 10 years, recurrence, and tumor intracranial progression.

Case report

In 2009, a 35-year-old woman presented to the Department of Otorhinolaryngology with reduced hearing in her right ear that worsened over the past year. The otoscopy revealed a hard, rough, inert, painless, and non-bleeding mass in the frontal part of the eardrum. Tympanogram AD/AS showed B/A type curves, respectively. Rinne and Weber tests indicated conductive hearing loss on the affected side. The pure tone audiogram in the right ear showed mixed hearing loss. Middle ear computed tomography (CT) showed masses in the epitympanum, opacification of the mastoid air cells, ossicles embedded by the tumor, and dehiscence of bone tissue. At that time differential diagnosis included mainly pus and cholesteatoma. A canal wall up mastoidectomy of the right ear using the retroauricular approach was performed and the tumor was removed. Tumor masses were histologically and immunohistochemically verified as grade 1 MeNET. In 2011, a canal wall down mastoidectomy and complete resection of residual tumor in the same location together with the ossicular chain reconstruction was done. In 2022, the patient presented to the outpatient clinic complaining of non-specific wet discharge from her right ear that worsened over the last four months. Head magnetic resonance imaging (MRI) revealed heterogenic tumor masses infiltrating the middle cerebral fossa with protein-like fluid content and contrast-enhancing zones. Compared with previous regular MRIs tumor recurrence and progression were confirmed. The patient was admitted to the Department of Neurosurgery where transcranial re-mastoidectomy, tumor resection, and duroplasty were performed. Postoperatively, right facial nerve paresis developed which was treated with dexamethasone. The patient's symptoms resolved, and she has been closely monitored since then.

Conclusions

We have presented a case of MeNET that recurred 13 years after a successful surgical removal and extended into the dura mater of the temporal fossa, suggesting its uncertain clinical behavior and a need for regular follow-up.

[1602] SECONDARY BENIGN PAROXYSMAL POSITIONAL VERTIGO AFTER VESTIBULAR NEURITIS: A CASE REPORT AND REVIEW OF THE LITERATURE

Authors: Domas Turcinas, Aiste Paskoniene

Affiliation: Clinic of Ear, Nose, Throat, and Eye Diseases, Institute of Clinical Medicine, Faculty of Medicine, Vilnius University, Vilnius, Lithuania

Trustee of the paper: Aiste Paskoniene MD

Corresponding author: Domas Turcinas (domas.turcinas@gmail.com)

Background

Benign paroxysmal positional vertigo (BPPV) is one of the most common causes of dizziness and recurrent peripheral vertigo, with paroxysmal, spontaneous-resolving episodes of vertigo, which are triggered by specific head positions. The peak incidence of primary or idiopathic BPPV is greatest among middle-aged women. One of the causes of secondary BPPV is vestibular neuritis (VN). Secondary BPPV after VN is observed in younger patients and is often associated with treatment-resistant forms, with persisting symptoms of posterior semicircular canalolithiasis. We present a case of a male patient with treatment-resistant secondary BPPV after VN.

Case report

A 21-year-old patient presented to a general physician complaining of a sudden attack of prolonged continuous vertigo while lying in bed, and imbalance during walking. The patient was diagnosed with vestibular neuritis and received treatment with prednisolone, betahistine, and B vitamins. After a few months a positive supine roll test and Dix-Hallpike maneuver, with both provoking right peripheral nystagmus, confirmed the diagnosis of secondary posterior and horizontal benign paroxysmal positional vertigo. Repositional maneuvers proved to be beneficial for a short period of time, afterwards the symptoms deteriorated. The patient experienced brief vertigo attacks and issues in focusing the eyes, with a slight left nystagmus a rotary component. MRI of the head showed no pathological findings. Due to the vestibular dysfunction, issues in focusing the eyes, and recurring BPPV, the treatment was initiated by administering tab. Cinnarizinum et. Dimenhydrinatum. Additionally, modified repositional maneuvers and vestibular rehabilitation were continuously applied for 12 months. Due to the long-term treatment, the symptoms have improved but have not gone away completely.

Conclusions

In this case report we present a young patient with a treatment-resistant secondary benign paroxysmal positional vertigo after vestibular neuritis. Due to the possibility of BPPV after vestibular neuritis, we suggest a thorough examination of patients after being diagnosed with VN to prevent a late diagnosis.

[1662] Clinical manifestation and spreading directions of jugular foramen paragangliomas - case series

Authors: Aleksandra Borowy, Wiktoria Suchcicka, Tomasz Antczak

Affiliation: Department of Otorhinolaryngology, Head and Neck Surgery, Medical University of Warsaw

Trustee of the paper: Prof. dr hab. n. med. Kazimierz Niemczyk

Corresponding author: Aleksandra Borowy (aborowy0311@gmail.com)

Background

Paragangliomas are rare, hypervascular, neuroendocrine tumors. Most frequently located at the carotid body, jugular foramen, and vagal nerve, but can spread in different directions. Although paraganglioma is slow-growing and generally benign, this tumor can cause significant complications due to the associated mass effect and compression or even erosion of the local structures. The management of these lesions includes surgical excision, embolization and radiotherapy.

Case report

The study aimed to analyze the spreading directions and the correlation with the clinical characteristics of jugular foramen paragangliomas in six cases.

Our study group consisted of four women and two men, mean age was 57,3, ranging from 36 to 76 years, who underwent surgery in November 2022 in the Clinic of Otorhinolaryngology at the Medical University of Warsaw.

Four of the six patients developed hearing loss. Three suffered from vertigo and pulsatile tinnitus. Two exhibited headaches, and one presented with dysphagia. Moreover, one had recurrent syncope.

The average time from the onset of symptoms was 6.8 years, ranging from 2 to 20 years. One patient had a tumor of the bulb of the jugular vein spreading to the parapharyngeal space.

In two patients, the tumor occupied the tympanic cavity. In one patient, it grew into the posterior cranial fossa. Sigmoid sinus involvement was found in two cases. In the most advanced case, the tumor involved the artery, internal jugular vein, sigmoid sinus, and posterior cranial fossa. In five patients, the tumor involved the bulb of the internal jugular vein in different parts.

The most common postoperative complication was facial nerve palsy (3/6), followed by dysphagia (2/6).

Conclusions

The clinical manifestation of the described patients shows the diversity of paragangliomas development. Nonspecific manifestations and a broad spectrum of symptoms cause difficulty in diagnosis. Surgical resection is an effective treatment, but it is challenging due to the variety of structure involvement and hypervascular features. The direction of tumor growth may result from the paraganglionic body's primary location relative to the jugular foramen's structures, but this requires further research. Determining and predicting the growth direction of paragangliomas can be essential in planning surgical treatment.

[1705] “The first case of non-responsive to standard treatment, rare type of sinonasal tumor in a young girl”

Authors: Natalia Kwiatkowska, Alicja Kamińska

Affiliation: Department of Pediatric Oncology, Hematology, and Transplantology, Institute of Pediatrics, Poznan University of Medical Sciences, 60-355 Poznan, Poland.

Trustee of the paper: Magdalena Samborska MD PhD, Prof. Katarzyna Derwich, MD PhD

Corresponding author: Natalia Maria Kwiatkowska (natalia.maria.kwiatkowska@gmail.com)

Background

Biphenotypic Sinonasal Sarcoma (BSNS) represents a rare type of mesenchymal tumor, usually presented in women in their fifth decade. The treatment of choice is a surgical procedure. Despite radical removal, locoregional recurrences are common, reaching up to 50 %. So far, no distant metastases have been observed in patients diagnosed with BSNS. The overall prognosis remains good. Here we report a rare case of a teenager with no-responsive to treatment BSNS.

Case report

A 15-year-old patient was admitted to the Otolaryngology Department with an obstructed nasal cavity and watery nasal discharge for about a year. MR revealed an irregular mass in the middle turbinate of the right nasal meatus and total obstruction of the ostiomeatal complex. Endoscopic examination showed a mass that obstructed the patient's posterior nostrils. Histopathologic results confirmed a biphasic sinonasal sarcoma diagnosis. The patient was qualified for surgical treatment. Five months later, MRI confirmed the recurrence of the disease in the nasal cavity and penetration into the anterior cranial fossa. Due to recurrence, the patient was qualified to receive chemotherapy. After seven weeks of unsuccessful treatment, the patient was treated with second-line chemotherapy with no response. After 4 weeks, radiotherapy was applied to the patient as a fourth line of treatment.

Conclusions

To our knowledge, it is the first case of metastatic Biphenotypic Sinonasal Sarcoma, which was diagnosed in adolescence and did not respond to the multiple lines of treatment. The overall reported prognosis for the patients was good. Up to this date, only three cases of death were reported due to intracranial extension of the tumor, conversely to our patient, who received multiple lines of treatment. Analyzing available literature on other cases of Biphenotypic Sinonasal Sarcoma, the therapeutic approach is not yet established, making its management even more difficult.

[1778] Two Adjacent Frontal Sinus Pseudomucoceles in a 13-year-old boy: A Pediatric Case Report

Authors: Razan Nossier, Piotr Kwast, Jia Jia Teo, Lidia Zawadzka-Głós

Affiliation: Pediatric Otolaryngology Department of the Medical University of Warsaw

Trustee of the paper: dr hab. n. med. Lidia Zawadzka-Głós

Corresponding author: Razan Ahmed Nossier (r.nossier01@gmail.com)

Background

A sinus pseudomucocele is defined as the dilation of a sinus due to a compromised outflow of mucus. It is rare to find such a pathology in children due to the underdevelopment of their paranasal sinuses. The frontal sinus is absent upon birth and begins to develop later during childhood. Ethmoid sinuses are the most common location of paranasal sinus mucoceles in the pediatric population. The anatomy of the frontal sinus is very complex and different from one person to another, so thorough individualized pre-surgical planning using the right tools is crucial. The current literature focuses more on paranasal sinus mucoceles in adults, and few papers report their incidence in children. We report a rare and interesting pediatric case of two adjacent pseudomucoceles of the right frontal sinus, and we focus on the best diagnostic tools and surgical approach that give optimal results.

Case report

A 13-year-old boy presented with the chief complaint of persistent unilateral headache on the right side over the past 6 months. An MRI was previously performed, and the report indicated that polycystic lesions of the frontal sinus were observed. A CT scan was performed in our department, and it revealed over-pneumatization of the sinuses especially in the true frontal sinus and frontal septal cell. In these cells, there was also marked opacification and complete obstruction of the frontal sinus drainage pathway. The patient underwent an endoscopic intranasal surgery intraoperative computed tomography navigation. Thus, the frontal sinus was successfully opened and drained. The patient healed well and did not have headaches after surgery. In the follow up after 6 weeks, the patient did not report any headaches, and there were no complications observed.

Conclusions

Although the incidence of pseudomucoceles of the frontal sinus in children is very uncommon, it can still happen and it should be considered in the differential diagnosis of headaches by pediatricians and otolaryngologists. The anatomy of the frontal sinuses is complex and highly variable, and it can be well developed even in a 13-year old boy. CT is a key radiological study in the diagnosis of pseudomucoceles as it helps surgeons see intricate details of the bone anatomy which is crucial for surgical planning. The golden standard treatment is endoscopic endonasal surgery. The use of intraoperative CT navigation within its limitations will effectively help ENT surgeons navigate their way during surgery.

[1840] Intracranial abscess as a complication of acute rhinosinusitis - a report of two cases

Authors: Marta Mękarska [1], Maria Molga-Magusiak MD [2], Tomasz Gotlib PhD, DSc [2], Emilia Wnuk MD [3], Kazimierz Niemczyk Prof [2]

Affiliation: [1] Students Scientific Research Group, Otorhinolaryngology Department, Head and Neck Surgery, MUW, Warsaw, Poland. [2] Department of Otorhinolaryngology, Head and Neck Surgery, MUW, Warsaw, Poland [3] II Department of Radiology, MUW, Warsaw, Poland

Trustee of the paper: Tomasz Gotlib PhD, DSc

Corresponding author: Marta Zofia Mękarska (marta.mekarska@gmail.com)

Background

Acute rhinosinusitis (ARS) is defined as the sudden onset of two or more symptoms, one of which should be either: nasal blockage/obstruction/congestion or nasal discharge (anterior/posterior nasal drip). ARS lasts less than 12 weeks. Acute bacterial rhinosinusitis (ABRS) is defined as the presence of at least three out of five symptoms, which are: discolored mucus, severe local pain, fever above 38°C, raised CRP/ESR, and "double" sickening. The complications of ABRS are still a significant clinical problem, despite the widespread use of antibiotics and glucocorticoids. ABRS complications are divided into orbital, intracranial and osseous. There are three ways of transmission of inflammation from the paranasal sinuses to the intracranial space: through diploic veins, bone defects in the walls of the sinuses or osteomyelitis. It is also possible to spread complications through the bloodstream. A frontal lobe abscess may be a diagnostic problem due to the lack of specific symptoms in some patients. Magnetic resonance imaging (MRI) is considered the "gold standard" when complications of ABRS are suspected and should be the imaging modality of choice. Pathogens usually responsible for the development of ABRS are anaerobic and mixed aerobic-anaerobic bacteria.

Case report

In this paper, two patients (26- and 74-year-old men) were presented. The patients developed intracranial complications of ABRS - abscesses of the frontal lobe. The abscesses were most likely caused by a disruption of the posterior wall of the frontal sinus. Surgical treatment and Intravenous antibiotic therapy were implemented in both cases. A 26-year-old patient developed ABRS, most likely odontogenic, spreading first to the maxillary sinus and then to the other paranasal sinuses. The 74-year-old patient was infected with *Aspergillus* fungi.

Conclusions

The prognosis of patients with intracranial complications of ABRS depends on the severity of neurological symptoms, the time of diagnosis and treatment. This is the reason why a frontal lobe abscess as a complication of acute frontal sinusitis often requires intervention, apart from an otolaryngologist, also of a neurosurgeon and an infectious disease specialist is often necessary. Endoscopic or open drainage to remove the abscess and long-term intravenous antibiotics therapy are required for successful treatment of the patient.

Lifestyle Medicine & Public Health

Date: 21st April 2023, 15:00 PM

Coordinators:
Magdalena Kędrak
Zuzanna Warzywoda

Patronage:

Polskie Towarzystwo Medycyny Stylu Życia

[1506] Transforming the perceptions of undergraduate medical students towards autism spectrum disorder: an interventional study

Authors: Akanksha Mahajan

Affiliation: MBBS student, Government medical college Amritsar, Baba Farid University of Health Sciences

Trustee of the paper: -

Corresponding author: Akanksha Mahajan (akankshamahajan5@gmail.com)

Introduction

According to WHO, presently 1–2% of the world population is affected by autism spectrum disorder. However, various international studies (Eseigbe et al. 2015; Kumar et al. 2015; Moyle et al., 2010; Rahbar et al. 2011; Shaukat et al. 2014), involving medical doctors and medical students indicate that there is a critical lack of medical training in ASD, particularly in the developing countries. Therefore, sensitisation amongst the medical students regarding the same is the need of the hour, who are the future of medicine.

Aim of the study

To find ways to transform the perceptions of undergraduate medical students towards autism spectrum disorder in a positive direction

Materials and methods

A convenience sample of 100 MBBS students was taken from Government Medical College, Amritsar, 1st year students were excluded as they had no clinical exposure at all, the participants were all asked to fill in 3 questionnaires -SATA (Societal Attitudes towards Autism), KCAHW (knowledge about childhood autism spectrum disorder among healthcare workers), a case-based questionnaire (formulated with the help of a special educator and a psychiatrist; the questionnaires were supposed to be filled before and after a workshop conducted by a special educator who was experienced in working with children with autism spectrum disorder).

Results

An aggregated mean score of 2.74 was obtained before the workshop on a five-point Likert Scale, which increased to 3.85 after the workshop. The percentage of increase in score was found to be strongly related with gender, and was greater in females ($p < 0.002$).

Conclusions

The study highlighted the importance of provision to include an additional training for medical students towards being inclusive practitioners in the contemporary medical curriculum.

[1657] Frequency of vitamin D3 deficiency in the adult population of the Warsaw University Hospital

Authors: Kaja Tyszkiewicz, Barbara Buchalska, Agata Gawęł, Julia Hanke, Aleksandra Żuk

Affiliation: Department of Orthopaedic Surgery and Traumatology, Medical University of Warsaw

Trustee of the paper: Grzegorz Szczęsny, MD, PhD

Corresponding author: Kaja Tyszkiewicz (kajatyszkiewicz@wp.pl)

Introduction

Vitamin D3 deficiency (VDD) occurs worldwide, and is associated with a wide range of health disturbances affecting musculoskeletal, cardiovascular, mental, and immune systems.

Aim of the study

The study aimed to assess the frequency of VDD in the blood serum, as well as to validate the impact of the Covid-19 pandemic on its frequency of it.

Materials and methods

We based on the hospital's laboratory data of the vitamin D3 concentrations in blood serum obtained from patients treated in the University Hospital in Warsaw between 2011 and 2022. For analysis a total number of 13520 patients were included (7972 females and 5548 males), defining deficiency as vitamin D concentration below 30 ng/mL. For more precise analysis groups of patients presenting critical (<10 ng/mL), severe (10-19 ng/mL), and mild (20-29 ng/mL) deficiencies were distinguished considering values 30-50 ng/mL as recommended ones..

Results

Collected data showed the decreasing frequency of VDD from 92,2% in 2011 to 62,8% of patients in 2017 (mean value 72,2%), including critical from 18,6% to 3,0%, severe from 40,2% to 26,7%, and the least stable frequency of mild deficiency occurring in 30,7-33,3% of patients. In 2022, during the Covid-19 pandemic, VDD showed 46,8% of patients, including 5,7% critical, 16,5% severe, and 24,5% mild deficiencies. VDD was more frequent in men than women and in patients above 55 years old than younger.

Conclusions

Our study shows that despite the fact that the frequency of VD deficiency in the polish population gradually decreases, most probably due to supplementation, it remains significant. The most endangered are women above 55 years. Thus, much more effort has to be paid to the propagation of VD supplementation, especially among elder men, with a possible re-evaluation of recommended doses and principles of application. The Covid-19 pandemic allowed us to reduce the frequency of VDD, most probably due to increased interest in a healthy way of life and methods supporting the immune system.

[1670] Pain as Risk Factor for Frailty Among Older Adults: A Cross-sectional Study using the Indonesian Family Life Survey

Authors: Dewangga Yudisthira

Affiliation: Medical Faculty Of Brawijaya University

Trustee of the paper: (1) Asri Maharani, MD., P.hD; (2) Holipah, MD., P.hD.

Corresponding author: Dewangga Yudisthira (dewanggay369@gmail.com)

Introduction

Pain is a global problem causing difficulties and barriers to activities, especially among older people. Frailty is defined as a clinically recognisable state of increased vulnerability related to the ageing process, and pain has been identified as its risk factor in high-income countries. However, little is known about the relationship between pain and frailty in Lower Middle-Income Countries (LMICs).

Aim of the study

This study aims to investigate the association between pain status and frailty index (FI) among older people in Indonesia.

Materials and methods

A cross-sectional study design was used for data from the Indonesian Family Life Survey (IFLS) wave 5 in 2014. The FI was constructed for adults aged 60 and older from 60 variables or deficits representing conditions that a) accumulate with age and b) are associated with adverse outcomes. Pain status was classified into five categories, i.e., (1) no pain; (2) a little; (3) somewhat; (4) quite a bit; and (5) severe pain. Multivariate linear regression models were used to analyse associations between pain and FI, adjusted by age, sex, and education. Statistical analysis was performed using STATA version 14

Results

This study included 2,967 participants, with a mean age of 69.52 ± 7.95 years. Individuals who reported having severe ($\beta = 0.137$; 95% confidence intervals (CIs) = 0.123, 0.151), quite a bit ($\beta = 0.087$; 95% CIs = 0.073, 0.100), somewhat ($\beta = 0.042$; 95% CIs = 0.026, 0.058), and a little pain ($\beta = 0.016$; 95% CIs = 0.005, 0.026) had higher FI than those with no pain. Those results remained significant when we included age, gender, and education attainment in the analysis. Being older ($\beta = 0.006$; 95% CIs = 0.005, 0.007) and female ($\beta = 0.030$; 95% CIs = 0.021, 0.038) were linked to a higher FI. Education attainment had no significant association with the FI.

Conclusions

The pain status increases vulnerability, as measured using the fFI, among older adults, which hinders daily activities. Therefore, practitioners in LMICs may consider to give more consent to pain among older adults and improve the care, including developing guidance for pain management, to reduce risk for frailty.

[1673] Analysis of the awareness of pharmacy specialists about breast cancer

Authors: Rafalska Yaroslava, Kosyachenko Konstantin.

Affiliation: Bogomolets National Medical University / Department of Organization and Economics in Pharmacy

Trustee of the paper: Rafalska Yaroslava

Corresponding author: Yaroslava Rafalska (yaroslava.gavrylyuk@gmail.com)

Introduction

The most common oncological disease among the female population in the world is breast cancer, which is associated with a significant risk of their mortality. The level of the frequency of screening for breast cancer remains quite low, despite the constant efforts of the state and various charitable organizations to increase the awareness of the population about breast cancer with the help of various social companies and public screening programs. In this regard, it is necessary to transmit and spread information about the prevention and screening of this disease not only by medical, but also by pharmaceutical workers, because more often at the first symptoms of various diseases, people visit a pharmacy, and not their family doctor.

Aim of the study

To analyze the results of a survey of pharmacists in Ukraine on the actual state of aspects of work on improving the literacy of the female population on breast cancer issues.

Materials and methods

80 respondents' questionnaires were analyzed. Such methods as sociological survey, mathematical and statistical analysis and generalization of results were used.

Results

The study revealed that 73.6% of respondents have a high and medium level of interest in consulting pharmacy visitors on issues related to breast cancer. When analyzing the frequency of providing consultations to pharmacy visitors, it was shown that most pharmacists never provided information about breast cancer, and only a few did so only once a month. Respondents were also asked whether they were familiar with the term "medical literacy". The majority answered positively to this question (61.3%) and only 38.7% were not familiar with this term. Next, the responses to the question of pharmacists' interest in advanced training in breast cancer issues were investigated. Half of the respondents (50.0%) showed a high level of interest, 37.5% - medium, and only 12.5% - low.

Conclusions

The results of the study showed insufficient participation of pharmaceutical workers in breast cancer health promotion, which may indicate insufficient awareness of visitors about this disease and its prevention. It is also necessary to implement at the state level training programs for pharmaceutical specialists in the field of breast cancer.

[1677] Cardiovascular Diseases as the Mediator between Inflammation and Frailty Among Older Adults: A Path Analysis using Generalised Structural Equation Modeling (GSEM)

Authors: (1) Alfatea Pintari Rahmi, (2) Dewangga Yudisthira

Affiliation: Medical Faculty, Universitas Brawijaya

Trustee of the paper: (1) Asri Maharani, MD, PhD; (2) Holipah, MD, PhD

Corresponding author: Alfatea Pintari Rahmi (alfatea.rahmi@gmail.com)

Introduction

Frailty has been described as a distinctive health state related to the ageing process, in which multiple body systems gradually lose their in-built reserves. Despite well-established literature showing inflammaging as a key component for the development of frailty in older individuals, the mechanism of the relationship is still unknown.

Aim of the study

This study aims to investigate the link between chronic inflammation and frailty among older adults in Indonesia and whether cardiovascular diseases (CVDs) mediate that association.

Materials and methods

Data were drawn from the nationally-representative Indonesian Family Life Survey waves 4 (2007) and 5 (2014). We included participants aged 60 years and older. Frailty was defined using a frailty index (FI) comprised of 60 health deficits. Inflammatory biomarker data in the form of C-reactive protein (CRP) level was obtained from IFLS-4, while the diagnosis of CVDs and FI were taken from IFLS-5. Participants with CRP levels higher than 10 mg/dL were excluded from the analysis as these values were likely to represent acute inflammation. CVDs variables were based on self-reported doctor-diagnosed heart attack, coronary heart disease, angina, or other heart problems. A Generalised Structural Equation Modeling (GSEM) approach was performed to analyse CRP's direct and indirect effects on FI among older adults using STATA version 14. All analyses were adjusted by age and gender.

Results

This study included 1.547 participants (mean age= 69.2 ± 7.7). GSEM analysis shows that CRP level in 2007 was associated with a higher FI seven years later ($\beta = 0.003$; 95% CI = 0.000, 0.006), and the occurrence of CVDs mediated that relationship. CRP level predicted CVDs in seven years ($\beta = 0.006$; 95% CI = 0.001, 0.012), and the CVDs are related to a higher FI ($\beta = 0.057$; 95% CI = 0.031, 0.084). Being older is related to a higher FI ($\beta = 0.006$; 95% CI = 0.005, 0.007).

Conclusions

This study concluded that older adults with chronic inflammation are at higher risk of being frail seven years later, partly mediated by the occurrence of CVDs. Further studies are required to know whether controlling inflammation prevents the incidence of CVDs and frailty in LMICs.

[1717] Risk factors associated with falls among patients hospitalized for COVID-19

Authors: Ivan Szergyuk, Marcin Mikos, Błażej Szydło, Maria Helena Santos de Oliveira, Michał Kuboń, Brandon Michael Henry

Affiliation: Faculty of Medicine, Jagiellonian University Medical College, Krakow, Poland

Trustee of the paper: Dr. Brandon Michael Henry MD

Corresponding author: Ivan Szergyuk (serdyuk.ivan@gmail.com)

Introduction

Falls are a significant public health issue, given the high rate of hospitalizations and fatalities, as well as the costs to the patient and the healthcare system incurred by the falls. During the current coronavirus disease 2019 (COVID-19) pandemic, falls have been identified as a potential presenting symptom in patients infected with severe acute respiratory syndrome coronavirus 2 (SARS-CoV-2), however, data on factors increasing fall risk in this patient population is limited.

Aim of the study

This study aimed to examine the factors that may predispose hospitalized COVID-19 patients to falls.

Materials and methods

In this retrospective observational study, hospitalized COVID-19 patients were examined for fall incidence, as well as demographics, comorbidities, clinical and laboratory data. Patients were stratified according to their fall status and their characteristics were compared using Fisher's exact test or Mann-Whitney's U test.

Results

A total of 312 hospitalized COVID-19 patients were enrolled (median age, 75 years; males, 51.3%), of whom 11 (3.5%) fell. There was a greater prevalence of falls among patients that experienced arrhythmias than those that did not (28.6% vs 1.7%; $p < 0.001$). Additionally, a significantly greater proportion of those that were discharged to the internal ward and to the intensive care unit fell (10.3% and 10.0%) compared to those that were discharged home (1.6%) [$p = 0.008$]. Thyroid stimulating hormone (TSH) was significantly elevated in patients that fell (5.3 vs 0.97 $\mu\text{U/mL}$, $p = 0.013$), while alanine aminotransferase (ALT) was significantly lower in fallers (17.1 vs 33.5 IU/L, $p = 0.041$).

Conclusions

In conclusion, COVID-19 patients that experience arrhythmias may be at increased risk for falls and fall prevention strategies should be aimed at this vulnerable patient population to reduce fall-related injuries and the associated costs. A holistic approach involving both hospital staff training and patient education, with a focus on screening for multiple potential risk factors should be effective in helping minimize fall risk. To the best of our knowledge, this study is one of the first to study falls in COVID-19 patients, and hence should be followed with studies with larger cohort size and analyzing for association to further validate our findings.

[1766] What do young Poles actually know about sex?

Authors: Paweł Bochomulski¹, Maria Bendykowska¹, Marcin Chrzanowski², Aneta Zwierzchowska¹, Ewa Barcz¹

Affiliation: 1. Chair and Clinic of Gynecology and Obstetrics, Faculty of Medicine, Collegium Medicum, Cardinal Stefan Wyszyński University in Warsaw, Warsaw, Poland 2. Biology Teaching Laboratory, Faculty of Biology, University of Warsaw, Warsaw, Poland

Trustee of the paper: Aneta Zwierzchowska

Corresponding author: Maria Bendykowska (marysiia.bendykowska@gmail.com)

Introduction

Sex education is recognized as a key component of public and reproductive health. Medical professionals have been emphasizing the society's lack of knowledge concerning human sexuality for a long time and the issue remains controversial.

Aim of the study

The goal of the current study was to investigate the understanding of high school and university students in the field of sexuality. Students' knowledge depending on the educational stage, source of knowledge that they use as well as the effectiveness of teaching sex education in secondary schools were evaluated.

Materials and methods

The data was collected based on the authors' self-composed questionnaire, consisting of 40 questions divided into four equal categories: reproductive biology, sexual health of women and men, and sexually transmitted diseases. The study group comprised 3016 participants- 635 students of the first grade of high school and 1866 students of the first and 515 of the fifth year of university studies.

Results

Female participants proved to have a better knowledge of human sexuality than males at the same educational level. High school students scored lower than college students. Within a given sex, the results between the students of the first and the fifth year did not differ statistically significantly. Questions concerning sexually transmitted diseases were answered least accurately, whereas those regarding sexuality of one's gender were most frequently answered correctly. Students who declared using at least one scientific source answered better than those who used only non-scientific sources. No relationship between attending sex education classes and the correctness of the answers was observed, even in those who declared that the classes were valuable.

Conclusions

The period of high school is crucial for the development of sexual awareness of young Poles. It is of utmost importance to shape the habit of using scientific sources in search for information. Due to its ineffectiveness, the teaching of sex education in schools should be thoroughly reformed.

[1871] Evaluation of patients' workability level in primary health care institution

Authors: Alvita Steponavičiūtė¹, Gintarė Gedvilaitė¹, Erika Fabijonavičė², Kristina Ziuteliienė²

Affiliation: 1Lithuanian University of Health Sciences, Academy of Medicine, Faculty of Medicine, 2Lithuanian University of Health Sciences, Academy of Medicine, Faculty of Medicine, Department of Family Medicine

Trustee of the paper: Kristina Ziuteliienė

Corresponding author: Alvita Steponavičiūtė (alvita.step@gmail.com)

Introduction

Workability research was started in Finland in 1980, as significant labor force aging and early retirement were observed in many European countries. It was found that the employment rate of older workers aged ≥ 55 years was below 40%. Research shows that the Work Ability Index (WAI) questionnaire can detect a declining level of workability. By taking preventive measures, the WAI score increases, which means that retirement is postponed.

Aim of the study

To evaluate patients' workability level in Lithuania's primary healthcare.

Materials and methods

A prospective study was performed at LUHS Kaunas Clinics, Department of Family Medicine in 2022 – 2023. A total of 84 patients were included in the study. Workability level was evaluated with WAI questionnaire based on WAI score. Workability by WAI score is divided into 4 categories (excellent, good, moderate, poor) and shows which action should be done (maintain, support, improve, restore). Pearson χ^2 criterion was used in statistical analysis based on IBM SPSS Statistics program. Results were statistically significant if $p < 0,05$.

Results

76,2 % of women and 23,8 % of men participated in the study. Mean of age was 46,98 (21-70). 44,0 % of participants were health care workers and 56,0 % were other specialties workers. 28,6 % of patients' workability level was excellent and should be maintained. 57,1 % of patients' workability level was good and should be supported. 13,1 % was moderate and should be improved. 1,2 % was poor and should be restored. There was no significant difference between age, gender, education, profession and WAI score. Patients with no disease had highest WAI score ($p < 0,001$). Patients with the lowest WAI scores had the highest number of days off work because of illness during the last 12 months ($p = 0,017$).

Conclusions

Most of the patients in Lithuania's primary healthcare had good workability level which should be supported. Poor workability was found in minority of patients. Workability is highly related with illnesses. It is important to manage chronic diseases to improve workability.

[1875] **The Emotional Intelligence in Polish undergraduate students and high school graduates: a cross-sectional survey study.**

Authors: Zuzanna Danielecka, Julia M. Smyk

Affiliation: Department of Medical Communication, Medical University of Warsaw

Trustee of the paper: Antonina Doroszevska, PhD

Corresponding author: Zuzanna Danielecka (z.danielecka@gmail.com)

Introduction

Emotional intelligence (EI) is a set of cognitive abilities enabling the processing of emotional information. Several studies have shown elevated EI levels in various professional groups. Thus, we decided to investigate if the level of EI influences the choices of career path.

Aim of the study

The study aimed to assess and compare the level of EI in undergraduate students and high school graduates regarding their studied or just chosen field of education. It seems to be important to investigate the level of EI in young adults since it has an impact on their mental health, professional career and interpersonal relations.

Materials and methods

A cross-sectional survey study was conducted obtaining responses from 777 Polish undergraduate students and 449 Polish high school graduates. Undergraduate students were divided into 10 subgroups based on The International Standard Classification of Education. To assess the level of EI (TIE total) and abilities: Perception (P), Assimilation (A), Understanding (U) and Management (Mn) the Test of Emotional Intelligence was used.

Results

Among high school graduates, females achieved higher scores than males in TIE total, U, A and Mn. Among undergraduate students females scored higher than males in TIE total, P, U, A, Mn. Among fifth-year undergraduate students in the subgroup called Engineering, manufacturing and construction TIE total, P and U scores were higher than among first year students in this subgroup. In the subgroup of Social sciences, journalism and information fifth-year students also scored higher in TIE total, P, A, Mn.

Conclusions

It is worth trying to develop EI through studying and training. It would be advisable to perform tests assessing EI on high school graduates at career counseling centers and to offer them opportunities for EI development.

[1915] Diseases and health incidents among the homeless in Krakow - the role of health in exiting homelessness

Authors: Marcin Wojnarski

Affiliation: Jagiellonian University Medical College, Medicine; Cracow University of Economics, Economy and Public Administration

Trustee of the paper: Jacek Klich associate professor at Cracow University of Economics

Corresponding author: Marcin Wojnarski (marcin-wojnarski@wp.pl)

Introduction

Homelessness is a vital social problem affecting about 30,000 inhabitants in Poland. People experiencing homelessness are particularly prone to health issues, due to the lifestyle, addictions and living conditions. Also, they do not always qualify for publicly funded healthcare. Health is an important resource, the lack of which limits one's ability to work and one's motivation, thus makes it difficult to exit homelessness.

Aim of the study

The aim of the study was to assess the prevalence of various diseases and health incidents among homeless people. It also examined how important a health problem is in entering and exiting homelessness. A side aim of the study was to assess the boldness of homeless people to talk about their health and general awareness of their health.

Materials and methods

Author's own survey questionnaire was used as a research tool. People experiencing homelessness residing in Krakow were included in the study. From 175 responses 75 were obtained by a direct interview with the author of the study and the remaining 100 by filling out the survey questionnaire by respondents on their own. The survey period ran from December 2021 to May 2022.

Results

Of the 175 participants, 108 (61,7%) declared that they currently suffer from some kind of illness. In this group an average of 2.3 diseases (median=2, SD=1.3) was reported. The most frequently declared diseases were hypertension (59), chronic pain (39), depression (36), diabetes (23) and COPD (18). Lower extremity ulcers (currently or in the past) were reported by 54 participants. Moreover, 29 individuals declared that they had experienced a serious injury, 22 an accident, 14 a heart attack and 7 a stroke. Health problems were the second most frequently stated barrier to exiting homelessness, reported by 74 (42,3%) respondents. Some qualitative data has been also obtained.

Conclusions

Most people experiencing homelessness have some sort of health problems. Their health history often includes serious incidents resulting in deterioration and disability. Respondents mention numerous difficulties associated with getting sick and point out that health problems are a very serious barrier in exiting homelessness. Homeless people mostly have the courage to talk about their health. At the same time, they show low awareness of their health and low motivation to treat themselves. To improve the homeless' health situation, cooperation of local authorities, NGOs and medical institutions is needed, as well as legislative changes.

[1982] The Future of the Polish Primary Care – projection of the demand and the number of family doctors till 2045

Authors: Anna Krawczyk

Affiliation: Warsaw School of Economics, Institute of Statistics and Demography

Trustee of the paper: dr hab. Wiktoria Wróblewska

Corresponding author: Anna Krawczyk (aniakk2142@gmail.com)

Introduction

Family doctors are a key link in the Polish healthcare system, especially in the terms of primary care. In 2020, the number of family doctors satisfied only 64.4% of the needs defined by the National Consultant for Family Medicine. The average age among family doctors was 55.23 years, while for all physicians (excluding physicians with no specialization) the average age was 54.97 years. People of retirement age (65+) accounted for 19.82% of all professionally active family doctors. Insufficient number of physicians combined with a high average age is not promising.

Aim of the study

The aim of the study was to project the demand and the number of family doctors in Poland until 2045. Moreover, detailed analysis of the current state was performed. This study can be used as an assessment of current staffing strategy in primary care.

Materials and methods

The analysis was based on the data from Baza Analiz Systemowych i Wdrożeniowych (BASIW) of the Ministry of Health. The projection model was developed using Microsoft Excel, including specially prepared life tables as the base of the model. The following groups of supply factors were taken into the analysis: the inflow of family doctors to the labor market, the outflow of family doctors from the profession, and as a demand factor - the demand for family doctors according to Polish population.

Results

Values projected with the model, demonstrate a persistent future shortage of family medicine specialists in Poland. In 2020 there was a shortage of 6,029 family doctors, which resulted in only 64.40% of needs being met. Over the next 25 years, this percentage will only increase to 78.25%, lacking 3352 specialists.

The projected deficit will gradually decrease over time due to the increasing number of doctors and the falling demand for them due to the expected decline in the Polish population. Apart from the number, the age structure of family doctors will also change from regressive to progressive.

Conclusions

The results of the study argue for the current strategy not being effective long term in improving the healthcare system in the matter of primary care and family medicine. Unsatisfactory prediction yields call for an alternate systemic approach, one targeted more towards the system fundamentals – primary care physicians.

[1994] Prevalence and Knowledge of cardiovascular risk factors among students of non-medical faculties in Poland.

Authors: Patryk Pindlowski, Maria Boszko, Alicja Skrobucha, Łukasz Sęczyk, Kaja Balcerowska, Adrianna Zabłotnia, Bartosz Krzowski MD

Affiliation: 1st Chair and Department of Cardiology, Medical University of Warsaw, Warsaw, Poland

Trustee of the paper: Bartosz Krzowski, MD

Corresponding author: Patryk Pindlowski (ppindlowski@gmail.com)

Introduction

Cardiovascular diseases (CVD) are the leading cause of mortality in Poland. Sedentary lifestyle and unhealthy dietary habits increase the risk of cardiovascular events in young individuals, leading to increased healthcare costs, decreased quality of life and worse prognosis. The data on the prevalence and knowledge of CVD risk factors in non-medical students is limited.

Aim of the study

The goal of this study was to determine the prevalence of CVD risk factors among Polish students at nonmedical faculties and evaluate knowledge of the individuals regarding healthy lifestyle.

Materials and methods

A dedicated questionnaire survey was conducted among 4036 of Polish non-medical faculty students at the age over 18. Data were collected from 07.2022 to 11.2022 using social media and internal e-mails of selected universities. Questionnaire consisted of 49 questions divided into 2 sections (31 prevalence, 18 knowledge). Questions and answers were prepared based on "2021 ESC Guidelines on cardiovascular disease prevention in clinical practice". The data were analyzed using T-test, ANOVA test, Shapiro-Wilk test.

Results

Population of 4036 students with an average age (22,5 years old) and BMI (23,1) was analyzed. The average BMI was significantly higher in men than in women (24,1 vs. 22,6, $p < 0.0001$). Respondents scored an average of 6.9 +/- 2,9 points of 17 possible (the last question was not scored, the question was multiple choice and checks sources of knowledge about health) in the knowledge part of survey. Women obtained a significantly higher mean score than men (7,3 vs 6,2, $p < 0,0001$). The score correlated significantly with age ($R = 0,12$, $p < 0,05$). Interestingly, the score differed significantly between students in different voivodeships ($p < 0.0001$) from 6,35 points in Subcarpathia to 7,74 points in Pomerania. There were also differences in the results by the faculty ($p < 0,0001$). The highest score was obtained by students of agricultural, forestry and veterinary studies (8.43 points), while the lowest score was obtained by students of humanities (6.46 points).

Conclusions

The knowledge regarding CVD risk factors in non-medical faculties in Poland is unsatisfactory. Women and older responders scored higher in the questionnaire. Lack of awareness regarding preventive measures can have long-term fatal consequences for both individuals and health care systems. There is a need for educational campaigns with aim of limiting dangerous cardiac events in the future.

[1996] Position of women in medicine. How high is the glass ceiling at Polish medical universities?

Authors: Aleksandra Gładys, Małgorzata Osmola, Justyna Danel, Paulina Kukła, Paulina Kumięga

Affiliation: Medical University of Warsaw

Trustee of the paper: Agata Malenda

Corresponding author: Paulina Kumięga (paulinakumiega@gmail.com)

Introduction

Medicine is one of the oldest arts and sciences known to humans. Throughout the centuries women's position in medicine has been changing. Despite innumerable hindrances and restrictions, women persistently pursued the education and career in the discipline. With merely 15,7% of women among medical graduates in Poland in 1945, the percentage of female graduates swiftly grew to reach as high as 71,1% in 1973. A new regulation introduced in 1985 was to further discriminate women in healthcare, allowing only 50% of women and 50% of men to be accepted to universities to study medicine. The regulation was recognised as discriminatory and was withdrawn in 1987. Nowadays, with the majority of medical students being female, it is still men who dominate in management positions and who more often bear the highest academic rank.

Aim of the study

The study assessed the percentage of female students, doctoral students, academic teachers, and professors at eleven Polish medical universities throughout the years 2017-2021 in order to determine the existence of barriers to academic advancement. Gaining an understanding of the stage at which the divergence of female academics out of academia may help support women in science.

Materials and methods

The data was collected from two sources: the Central Statistical Office (pol. Główny Urząd Statystyczny) and directly from the databases of the 11 Polish universities. It included information from years 2017-2021 about the number of females and males at: 9 distinct undergraduate and graduate degree courses, doctorate degrees, at academic teaching positions, and with the professor rank.

Results

Among undergraduate and graduate degrees women were the majority of students in 8 out of 9 courses. In total, women accounted for roughly 75% of all students. The highest percentage of females was observed in midwifery: about 99%. The percentages of women among doctoral students and academic teachers were approximately 10 percentage points lower compared to the primary stage of the academic education. In 2021 the percentage of female professors was as low as 44,39% compared to 73,76% of female students.

Conclusions

Changes in the percentage of female academics at the starting point and at the top of the academic career show a distinct and steady decline in the percentage of women. Identifying the causes of the trend gives a possibility to women to gain greater self-agency in their career.

[3003] Risk management of the use of antidepressants in the treatment of post-traumatic stress disorder

Authors: Daria Turchak

Affiliation: Dep. of Clinical pharmacology and clinical pharmacy, Faculty of Pharmacy, Bogomolets National Medical University, Kyiv, Ukraine

Trustee of the paper:

Corresponding author: Daria Turchak (turchak.dasha@gmail.com)

Introduction

Post-traumatic stress disorder (PTSD) refers to anxiety disorders and is noted in 5-10% of the population, more often in women. Treatment of PTSD includes psychotherapy (mainly trauma-focused cognitive-behavioral therapy) and pharmacotherapy (mainly antidepressants). The sale of antidepressants has increased significantly, driven by increased levels of anxiety and depression amid the COVID-19 pandemic and full-scale war, as well as the permission to family physicians of to prescribe antidepressants. At the same time, the sales leaders are escitalopram, amitriptyline, fluoxetine, sertraline and paroxetine. In 5.1% of patients during treatment with antidepressants, the level of transaminases increases, in 2.8% of patients movement disorders appear.

Aim of the study

To study the main risks of using antidepressants in PTSD and to carry out risk management.

Materials and methods

31 healthcare professionals with experience in prescribing antidepressants were anonymously surveyed, including 7 psychiatrists, 6 neurologists, 6 pediatricians, 6 family doctors, 2 pharmacists, 1 endocrinologist, 1 anesthesiologist, 1 therapist, and 1 dentist. 23 specialists had more than 7 years of experience, 2-7 years - 7 specialists, less than 2 years - 1 specialist.

Results

48.4% of respondents noted that sexual dysfunction was most often noted in patients who used antidepressants, 41.9% of respondents marked dry mouth, headache, weight gain; 29% - nausea and abdominal pain, 19.4% - accommodation disorders; 9.7% - rapid heartbeat, 6.5% - tremor. 54.8% of respondents noted that escitalopram and amitriptyline are prescribed more often, 38.7% - fluoxetine, 32.3% - paroxetine; 22.6% - sertraline and mirtazapine. 45.2 respondents mistakenly believe that it is safe to combine antidepressants with beta-blockers, 29% - with statins, 22.6% - with hypoglycemic sulfonylurea derivatives, 19.4% - calcium channel blockers, angiotensin II receptor blockers. Only 25.8% of doctors recommend patients when prescribed antidepressants to consult a dentist.

Conclusions

The majority of health care professionals point to frequent adverse reactions when using antidepressants, while they are not sufficiently focused on the risks of drug interaction and do not take measures to prevent adverse reactions, which we have paid attention when developing the risk management algorithm.

[3008] **Assessment of the risk of developing cardiovascular complaints among Ukrainian students and situational anxiety level during the martial law**

Authors: Anastasiia Shkvarok

Affiliation: Bogomolets National Medical University

Trustee of the paper: Associate Professor at the Department of General practice (Family medicine), Candidate of Medical Sciences (Ph.D.) Yaroslava Korost

Corresponding author: Anastasiia Shkvarok (shkvarok.anastasiia@gmail.com)

Introduction

Since the beginning of hostilities in Ukraine, the population has been under prolonged stress. Young people are considered the most resilient and enduring category of the population, but they also suffer from physical and psychological exhaustion. Human body responds to the exhaustion, somatic illnesses and complaints from the cardiovascular system appear.

Aim of the study

The aim of the study was to assess the risk of developing complaints from the cardiovascular system among students during the martial law with the background of increased situational anxiety level.

Materials and methods

Anamnestic, computational and statistical methods were used. The questionnaire contained 20 statements from the Spielberger-Hanin test, according to which students assessed their condition by choosing a number from 1 to 4. After determining the level of anxiety according to the test, characteristics such as the appearance of complaints from the cardiovascular system or exacerbation of previously existing conditions after 24.02.22 were analyzed, as well as the subjective evaluation of the respondents regarding the connection between their own condition worsening and hostilities in Ukraine.

Results

According to the results of the Spielberger-Hanin test, in 27% of the 123 surveyed students low level of reactive anxiety was revealed, moderate level – in 32%, high level – in 41%. Two groups were formed: 1 – students whose level of anxiety remained within the low range; 2 – students whose anxiety level was elevated. Both groups included students who reported cardiovascular complaints during the state of emergency and those who did not. The odds ratio was 5.08, indicating an increased risk of experiencing the mentioned complaints under the influence of the elevated level of anxiety. The most common complaints were palpitation, tachycardia, feeling cold in the extremities due to stress, chest pain, shortness of breath, pain in the heart region, episodes of hypertension and hypotension. 87% of students who reported the appearance or exacerbation of cardiovascular complaints subjectively attribute changes in their health to the state of war in the country.

Conclusions

There is an increased risk of cardiovascular complaints in individuals exposed to a high level of anxiety. 87% of surveyed students who reported manifestation cardiovascular complaints or exacerbation of existing ones after February 24th, 2022, attribute these changes in their health to the state of emergency in the country.

Neonatology

Date: 22nd April 2023, 9:00 AM

Coordinators:
Mateusz Kopczyński
Kacper Majczak

[1528] “Assessment of the frequency and severity of bronchopulmonary dysplasia in pre-premature neonates, maturity below 28 weeks of pregnancy, when following the 2020 ESPGHAN Nutrition Guidelines”

Authors: Konstancja Ustymowicz, Maria Orzeł, Dariusz Madajczak

Affiliation: Medical University of Warsaw

Trustee of the paper: Konstancja Ustymowicz

Corresponding author: Konstancja Ustymowicz (konstancja108123@gmail.com)

Introduction

Bronchopulmonary dysplasia (BPD) is the most common lung disease diagnosed in children who are born extremely preterm. BPD pathophysiology assumes that malnutrition in the early postpartum period results in insufficient energy for the growth of epithelial and ciliated cells. The supply of fluids, energy, nutrients, and the methods of their administration - parenteral or enteral - have a direct impact on the composition of lung tissue.

Aim of the study

For this reason, we decided to assess the incidence and severity of BPD depending on nutritional management - the amount of planned and administered fluids in parenteral nutrition in the first 14 days of life in the extremely preterm infants born below and in the 28th GA. The obtained data can be used to create a predictive model for assessing the risk of BPD in future patients of Neonatal Intensive Care Units.

Materials and methods

We conducted a retrospective pilot study in which we collected data on newborns (n = 41) born below and at 28 weeks of gestation (from 2021). Newborns who had been transferred to another hospital or died (before the 36th week of corrected age was completed) were excluded from the evaluation, leaving us with 29 patients, including 17 female and 12 male newborns. The median gestational age was 26 weeks and two days, and the median body weight was 755 g.

Results

The planned amount of fluids on the first day of life 60 – 100 ml/kg/day (median 81 ml/kg/day), was statistically significantly lower compared to the fluids obtained: 60 – 195 ml/kg/day (median 108.5 ml/kg/day).

Similar disproportions were observed in the amount of fluids on the 3rd, 7th and 14th day of life. Despite the observed statistically significant differences, the increased fluid intake did not significantly affect the frequency or severity of bronchopulmonary dysplasia.

Conclusions

Because of the above, and in view of the ambiguous conclusions of clinical trials and meta-analyses, a prospective study was planned to assess the effect of the amount of fluids and nutrients received on the incidence of BPD.

[1581] Comparison of selected indicators of perinatal care in Poland and Zimbabwe with special focus on maternal mental health and neo-nate's birth status.

Authors: Adrianna Perzanowska, Anna Korczak

Affiliation: Department of Neonatology and Rare Diseases, Children's Clinical Hospital of Józef Polikarp Brudziński in Warsaw

Trustee of the paper: Karol Taradaj MD MSc, Tomasz Ginda MD

Corresponding author: Adrianna Maria Perzanowska (adrianna.perzanowska@gmail.com)

Introduction

Postpartum depression is a common and serious mental health problem that is associated with maternal distress and negative consequences for the offspring. Scientific studies conducted to date have confirmed the existence of significant differences in the prevalence of postnatal depression in different social groups. Maternal and neonatal care also has a major impact on the health of the newborn, which varies between the countries compared.

Aim of the study

The aim of this study was to compare the intensity of depressive symptoms in Poland and Zimbabwe and to identify the risk factors present in both populations. We have also compared neonatal biometric parameters and perinatal strategies in Poland and Zimbabwe.

Materials and methods

The study was conducted from 25.01 to 9.12.22. We used Apgar Scale and the Edinburgh Postnatal Depression Rating Scale. We have collected 451 questionnaires from patients at the Department of Neonatology and Rare Diseases (MUW, Poland) and 500 from the Clinic at Binga District Hospital (Zimbabwe). Outcome analyses were performed using Mann-Whitney test ($p < 0,05$). Cronbach's alpha was used to assess the internal consistency of EPDS in both samples.

Results

Significant differences were found between the two groups in the level of depressive symptoms ($p < 0,001$) (the Welch test was used due to the violation of the variance equality assumption). Research indicated statistically relevant differences in the percentage of women with increased risk of postnatal depression (16.23% in Warsaw vs 36.7% in Zimbabwe, $p < 0,001$). The size of the effect was medium (Hedges $g = 0,394$). In the neonatal population, the most significant differences were revealed in mean Apgar score in the first minute of life (Warsaw 9.52 vs Zimbabwe 7.37 $p < 0,05$) and mean birth weight in grams (Warsaw 3311.95 vs Zimbabwe 3092.39 $p < 0,05$).

Conclusions

The standards of perinatal care in Poland and Zimbabwe are different which may have implications for both the well-being and future development of the child and the psychological state of the mother. There is a need for more research comparing neonatal, obstetric and psychological care in developing and highly developed countries. The results can contribute to the development of new guidelines that can be implemented after considering the organizational resources, means and needs of developing countries. Aforementioned new standards could help to improve the somatic and mental health of mothers and newborns.

[1623] Is an analgesic dosage of paracetamol sufficient in patent ductus arteriosus closure in preterm infants?

Authors: Marianna Mycroft, Małgorzata Bednarczyk, Klaudia Baran, Magdalena Zarlenga, Bożena Kociszewska-Najman

Affiliation: Student Scientific Association ProNeo at the Department of Neonatology and Rare Diseases of the Warsaw Medical University, Poland; Head of Department: prof. Bożena Kociszewska-Najman

Trustee of the paper: Dr Magdalena Zarlenga

Corresponding author: Marianna Victoria Mycroft (marysia.mycroft@gmail.com)

Introduction

Usually, functional patent ductus arteriosus (PDA) closes itself within 72 hours after birth. However, it is not the case in preterm neonates, as they have a higher threshold of response to oxygen as well as they are more sensitive to prostaglandin E2 (PGE2) and nitric oxide (NO), which are the reasons for PDA's delayed closure. Presence of ductus Botalli can lead to multiple neonatal morbidities, either due to steal phenomenon that diminishes the systemic perfusion or left-to-right shunt being the direct cause of pulmonary hypertension. Generally, when PDA fails to close itself infants require medical or surgical intervention. Closure can be achieved with either Ibuprofen or Paracetamol.

Aim of the study

Analysis whether the analgesic dosage of paracetamol can be sufficient in the closure of patent ductus arteriosus in preterm infants.

Materials and methods

A retrospective investigation included 47 preterm neonates from 23 to 32 weeks of gestation (WG) admitted to the Department of Neonatology and Rare Diseases of the tertiary centre of the Medical University of Warsaw, Poland, from January 1st 2020 to January 2nd 2023. All inborn neonates were receiving Paracetamol at a dosage of < 10 mg/kg intravenously as an analgesic from the 1st day of life and during their first week. Later on, the postnatal echocardiography detected either the PDA closure or the need for its treatment. The therapy for PDA was Paracetamol at a dose 15 mg/kg x4/daily i.v. or Ibuprofen at a dose 20-30 mg/kg/day i.v.

Results

The median WG and birth weight of the 47 included infants were 27 weeks and 1080 grams. 51% (24/47) of mothers received at least 1 dose of steroids before labour, among which 88% (21/24) received a full course. Overall, ductal closure was confirmed with postnatal echocardiography in 91,5% (43/47) of neonates. However, 8,5% (4/47) required additional intervention for PDA closure. Amidst which, 25% (1/4) of them were treated with ibuprofen and 75% (3/4) with Paracetamol.

Conclusions

The analgesic use of Paracetamol in smaller doses than recommended (15 mg/kg) in premature infants can promote the closure of the ductus arteriosus. Treatment with smaller doses can help to avoid adverse effects that come with using Paracetamol.

[1641] Renal replacement therapy in critically ill newborns

Authors: Julia Śladowska, Olga Błażowska

Affiliation: Student Scientific Association ProNeo at the Department of Neonatology and Rare Diseases of the Warsaw Medical University, Poland; Head of the Department: prof Bożena Kociszewska-Najman

Trustee of the paper: Ewa Wilkos

Corresponding author: Julia Śladowska (j.sladowska1@gmail.com)

Introduction

Renal replacement therapy (RRT) is a rare and challenging life-saving intervention in Neonatal Intensive Care Units (NICUs). It includes peritoneal dialysis (PD), hemodialysis (HD) and continuous RRT (CRRT). CRRT (hemofiltration, hemodiafiltration etc.) and traditional HD, despite providing more efficient clearance than PD, encounter limitations in neonates. In this group of patients, unlike older children, the modality of choice is PD. Although we observe a progress in neonatal renal pathophysiology, there is still a lack of studies regarding RRT.

Aim of the study

The aim of this retrospective study is to evaluate indications, efficacy and complications of RRT in critically ill neonates.

Materials and methods

We retrospectively reviewed medical charts of infants who underwent RRT in the Department of Neonatology and Rare Diseases between January 2020 and January 2023. We analyzed perinatal medical records, RRT indications, age at the beginning of RRT (in days), RRT duration (in days), complications and laboratory results with clinical characteristics at the beginning and after therapy.

Results

We identified 5 patients who underwent RRT. Among them 4 underwent PD and 1 received hemofiltration. All were delivered by cesarean section (CC). Indications for planned CC (n=4) included birth asphyxia (n=3) and preeclampsia (n=1). The median gestational age at birth was 32 weeks (30 - 37 weeks). The birth weight ranged from 1885 to 3640 g. All except 1 patient had at least 2 clinical manifestations indicating for RRT (acute kidney injury (n=3), hydrops fetalis (n=2), peripheral edema (n=2), anuria (n=2) and renal ciliopathy (n=1)). At the beginning of RRT the average patients' age was 6 ± 3.16 days (2-10 days) and RRT duration ranged from 2 to 25 days. 2 neonates suffered from RRT-related complications. The laboratory results at the beginning of RRT showed mean urea 91.74 ± 63.40 mg/dl (31.7 - 182 mg/dl) and mean creatinine 1.88 ± 1.23 mg/dl (0.32 - 3.98 mg/dl). During the period of RRT implementation, only 1 patient who received PD, died. Consequently, the mean laboratory values at discharge were assessed in only 4 neonates - urea 29.65 ± 15.98 mg/dl (11.9 - 51 mg/dl), creatinine 1.01 ± 1.17 mg/dl (0.3 - 3.04 mg/dl).

Conclusions

RRT is an appropriate and irreplaceable treatment for critically ill neonates, nevertheless, the recommendations for modality of RRT, complications and its efficacy in low birth weight (<2500 g) neonates must be verified in further studies.

[1646] **Assessment of the effect of immunosuppression on antibiotic resistance of intestinal microbiota in children born by mothers with liver or kidney transplant medical history**

Authors: Martyna Berej

Affiliation: Student Scientific Association ProNeo at the Department of Neonatology and Rare Diseases of the Warsaw Medical University, Poland Head of Department: prof. dr hab. n.med.
Bożena Kociszewska-Najman

Trustee of the paper: Oliver Jendro

Corresponding author: Martyna Ewa Berej (martyna.berej1@gmail.com)

Introduction

In recent years, the number of transplantations of parenchymal organs, also among women of childbearing age, has been increasing. The influence of chronic immunosuppressive therapy during pregnancy on the body of the developing foetus, then the newborn taking immunosuppressants or their metabolites with breast milk remains an unresolved issue. Chronic intrauterine exposure of the foetus to immunosuppressive drugs is believed to affect the structure of intestinal microbiota, including the emergence of antibiotic-resistant strains in the postnatal period. Such a change may result in an increased risk of chronic diseases, including cardiovascular diseases, allergies, inflammatory bowel diseases, and even a higher incidence of cancer.

Aim of the study

The aim of the project is to determine the presence of antibiotic resistance genes in children's gut microbiota of mothers who received chronic immunosuppression during pregnancy.

Materials and methods

The study used faeces samples from 30 children who were exposed to immunosuppressants during foetal life and during breast-feeding. The resistance of intestinal microbiota to antibiotics such as aminoglycosides, macrolides, sulphonamides, colistin and tigecycline was examined on the basis of the presence of specific resistance genes. From the sample of fresh faeces of children delivered to the laboratory, the total DNA material was isolated using the commercial Fast DNA Spin Kit for Faeces according to the original manufacturer protocol. Using the obtained genetic material, the nucleotide sequences from which the corresponding resistance genes were then read out are listed.

Results

Among the 30 samples tested, 28 reliable results were obtained. In 26 samples, the presence of the tetX gene determining resistance to tigecycline was demonstrated. In addition, 6 of these samples contained a sul2 gene for sulphonamide resistance. The result of one sample indicated resistance to both tigecycline and colistin. The mother of each subject was given prednisone and azathioprine during pregnancy. The difference factor was the third immunosuppressive drug: tacrolimus or ciclosporin.

Conclusions

Based on the conducted studies, it is not possible to clearly determine how much exposure of the foetus and child to immunosuppression or its metabolites affects the antibiotic resistance of intestinal microbiota. This suggests the need to interest the medical community in this topic and to carry out further research in this direction

[1688] Life-saving actions in extremely preterm infants on the verge of survival: A retrospective study- 2004-2022

Authors: Oliwia Bolek, Julia Kuszewska, Dominika Paw MD, Marta Szymaska MD, Joanna Puskarz-Gąsowska MD, PhD

Affiliation: Department of Neonatology and Neonatal Intensive Care, Medical University of Warsaw

Trustee of the paper: Joanna Puskarz-Gąsowska MD, PhD

Corresponding author: Oliwia Magdalena Bolek (oliwia.bolek99@gmail.com)

Introduction

An extremely preterm infant is defined as born at or before 28 weeks of pregnancy. Prematurity is a significant cause of infant morbidity and mortality. It is a group of newborns with high disease incidence and risk of future developmental disorders occurrence. Globally, prematurity is the leading cause of death in children under the age of 5 years. In many countries including Poland, the minimal age for undertaking resuscitation in a delivery room is 22-24 weeks of pregnancy.

Aim of the study

The paper is an attempt to present the statistics of extremely preterm childbirth, undertaking resuscitation and survival rate among newborns born at 22+0/7 weeks' to 23+6/7 weeks' gestational age in the Department of Neonatology and Neonatal Intensive Care, the Medical University of Warsaw through the years 2004-2022.

Materials and methods

A retrospective study of 167 infants born at 22+0/7 weeks' to 23+6/7 weeks' gestational age, birth weight of 230 g to 1060 g in the Department of Neonatology and Neonatal Intensive Care between 2004-2022.

Results

71,20% (119) newborns dead, 28,7% (48) newborns survived, including 30 (62,5%) girls and 18 (37,5%) boys. Among the whole group, 41 (24,5%) preemies were in palliative care from the beginning, meaning that resuscitation was performed on 126 newborns. The procedure was successful in 38% of cases, however, children who survived, developed significant impairments connected with prematurity: 21 (43,75%) intraventricular hemorrhage – 3 (14, 3%) of them were III/IV grade; 15 (31,25%) retinopathy of prematurity – 7 (46,7%) of which were treated with laser therapy and 3 (20%) with ranibizumab; 5 necrotizing enterocolitis and 18 (37,5%) bronchopulmonary dysplasia.

Conclusions

Extremely premature infants with incredibly low birth weight remain at high risk for death. Rates of survival for infants born on the verge of life are still very low. Survivability has not improved through the years, which is a result of both resuscitation guidelines and limits of the therapeutic options for such immature organisms. This report could be useful in explaining to the parents our decision-making in obstetric and neonatology departments. We plan to further analyze these children's development.

[1730] **The impact of childbirth on lactation.**

Authors: Klaudia Janiak, Marta Szumska, Anna Kwiatkowska, Klara Wojciechowska

Affiliation: Medical University of Warsaw/ Department of Neonatal Intensive Care

Trustee of the paper: Dariusz Madajczak PhD

Corresponding author: Klara Wojciechowska (wojciechowska.klara@gmail.com)

Introduction

Exclusive breastfeeding in the first six months of life is recommended by WHO due to its beneficial effects on the infants' development. It should be continued up to and beyond two years of age. Breast milk is biologically active, moderates a baby's immune system and has a long-term beneficial effect on reducing the risk of civilization diseases or improving mental development observed not only in infancy, but even in adulthood. Recent studies indicate that cesarean delivery negatively affects the maintenance of exclusive breastfeeding for the first week after birth. The use of natural products containing beta-glucan, barley malt, choline and B vitamins is one way to improve it, in addition to the lactation counseling.

Aim of the study

The aim of this observational, prospective study was to assess the percentage of delayed oversupply of breast milk and problems with maintaining lactation in women after cesarean section in comparison to the natural birth. Additionally, in those groups the percentage of women requiring the use of a food supplement containing beta-glucan, barley malt, choline and B vitamins plus was assessed.

Materials and methods

This was a prospective observational study on the impact of the type of childbirth on the development of lactation at its early stage. The study was based on conducting questionnaire interviews with eighty women in the early postnatal period. The questionnaire assessed information on the development of lactation, the way of feeding the newborn, possible use of natural products containing barley malt and the newborn's daily weight gain. Inclusion criteria: single pregnancy, birth on term with no SGA or LGA. Experimental group consisted of forty women after the cesarean section. Control group included forty women who gave birth vaginally.

Results

In the experimental group, issues such as delayed milk oversupply, lower weight gain of the newborn, and a higher need of lactation counseling. Use of barley malt preparations were significantly more frequently observed. Furthermore, satisfactory lactation occurred more frequently in women from this group only after using the barley malt products.

Conclusions

Based on the survey results, it can be concluded that the mode of delivery significantly affects the effectiveness of lactation in the early postnatal period. Additionally, barley malt-containing mixtures have a positive impact on initiating and maintaining lactation.

[1744] Characteristics and clinical outcomes of the extremely preterm infants hospitalized in the Department of Neonatal Diseases of Pomeranian Medical University in Szczecin.

Authors: dr hab. n. med. Beata Łoniewska, Ksenia Mazur, Aleksandra Łysiak, Karolina Koniarska

Affiliation: Department of Neonatology and Neonatal Intensive Care at Pomeranian Medical University in Szczecin

Trustee of the paper: dr hab. n. med. Beata Łoniewska

Corresponding author: Ksenia Weronika Mazur (ksenia1016@gmail.com)

Introduction

Extremely preterm infants (less than 28 weeks of gestation) are at risk of many complications and severe health conditions which can affect their development, future quality of life and morbidity.

Aim of the study

To analyze hospitalization course of the extremely preterm infants born between 2018 and 2021 at the Department of Neonatal Diseases at Pomeranian Medical University in Szczecin

Materials and methods

A single-center retrospective study included 57 extremely premature infants of both sexes. There were analyzed anthropometric parameters at birth and at hospital discharge, nutrition mode, complications of prematurity: necrotizing enterocolitis (NEC), retinopathy (ROP), bronchopulmonary dysplasia (BPD), severe intraventricular hemorrhage (IVH) and mortality.

Results

At the Department were born 57 extremely preterm infants. Mean gestational age was $25,8 \pm 1,83$ Hbd and mean birthweight was $836,4 \pm 217,64$ g. 20 infants (35,09%) died before hospital discharge and were not included in the further analysis. 17 deaths occurred up to day 6 of life. 1 (2,63%) of the neonates was born in a good, 27 (71,05%) in a medium and 10 (26,32%) in a severe condition. 29 (76,32%) preterm neonates needed invasive and 9 (23,68%) noninvasive mechanical ventilation. Mean duration of respiratory support was $53,4 \pm 30,62$ days. 30 (78,95%) of all babies were born with congenital infections including meningitis 5 (13,16%) and sepsis 3 (7,89%). 33 (86,84%) of infants had acquired infections. 100% of the patients experienced complications of prematurity. The most common complications were: BPD 28 (73,68%), ROP 20 (52,63%) and PDA 20 (52,63%) of infants. There were 5 (13,16%) infants with NEC and 6 (15,79%) with severe IVH. 36 (94,74%) of all extremely preterm infants were breastfed at the Department with mean time duration of breastfeeding $55,7 \pm 34,78$ days and 26 (68%) of them continued breastfeeding at the hospital discharge. Median time of introduction completely enteral nutrition was 14 days (range 7-39). Mean time of hospitalization was $85,5 \pm 26,52$ days. Mean weight at hospital discharge was $2811,3 \pm 638,4$ g. 10 (26,32%) babies had weight at hospital discharge below the 10th percentile.

Conclusions

Hospitalization of the extremely preterm infants is associated with high risk of complications and death. The most common complications are infections and diseases typical for age. Many of newborns don't gain weight properly. Continuous improvement in the management, prevention, and treatment of extremely preterm infants are warranted.

[1773] Comparison of two methods of surfactant delivery (INSURE and LISA) in preterm infants

Authors: Aleksandra Barabasz, Julia Śladowska, Marta Sasin

Affiliation: Student Scientific Association ProNeo at the Department of Neonatology and Rare Diseases of the Warsaw Medical University, Poland Head of Department: prof Bożena Kociszewska-Najman

Trustee of the paper: Natalia Czaplińska

Corresponding author: Aleksandra Barabasz (ola.barabasz@gmail.com)

Introduction

Respiratory distress syndrome (RDS) in preterm infants is caused by lung immaturity and surfactant deficiency. The basic treatment is endotracheal supply of exogenous surfactant and breathing support. Surfactant administration is often associated with mechanical ventilation. There are alternative methods, i.e. administration of surfactant during short-term intubation (INSURE) or by thin catheter while infant is breathing spontaneously with support (LISA). LISA has proven to reduce mortality and incidence of BPD.

Aim of the study

The aim of this study was to compare the effectiveness of surfactant administration by LISA and INSURE methods.

Materials and methods

We retrospectively reviewed 48 neonates with RDS treated in the Department of Neonatology and Rare Diseases at the Pediatric Hospital of Medical University of Warsaw in the years 2018-2022. The neonates were divided into 2 groups: the LISA group and the INSURE group. The groups were analyzed for the effectiveness of therapy, especially the need for the next dose of surfactant, the use of mechanical ventilation and its duration, the total number of days of respiratory support and the incidence of BPD.

Results

There were 48 newborns included to the study - 30 in the INSURE group and 18 in the LISA group. Average gestational age in the INSURE group was 31.4 weeks and in the LISA group 30.5 weeks. The average body weight in the LISA group was 1604g, and in the INSURE group it was 1814g. In the LISA group, 55.6% of children required a second dose of surfactant, two (11%) of whom received 2 additional doses. In the INSURE group, 10% of babies received one additional dose of surfactant. The average number of days of respiratory support in the LISA group was 19.9 days and 13.6 days in the INSURE group. In the LISA group 66.7% of children required mechanical ventilation while in the INSURE group 36.7%. The average period of mechanical ventilation among patients who required it, was 5.3 days in the LISA group and 6.6 days in the INSURE group. In the LISA group, 4 infants (22.2%) developed BPD, and in the INSURE group – 3 (10%). One extremely preterm infant in the LISA group died on day 4 of life.

Conclusions

Newborns in the LISA group more often needed another dose of surfactant, required mechanical ventilation and had longer period of respiratory support.

This group also had higher incidence of BPD.

Further observations are required on a bigger group, considering other factors.

[1633] Suspected Perlman syndrome in a neonate. A case report

Authors: Paulina Biernacka, Łukasz Blochel, Idalia Błażejczyk

Affiliation: Students' Scientific Society at the Department of Intensive Care and Neonatal Pathology, Medical University of Silesia in Katowice

Trustee of the paper: Anna Suchojad, MD

Corresponding author: Paulina Katarzyna Biernacka (p_biernacka@wp.pl)

Background

Perlman syndrome is a rare disorder characterized by macrosomia, distinctive facial appearance, renal dysplasia, nephroblastomatosis and a predisposition to Wilms' tumor; often associated with a high neonatal mortality rate.

Case report

35 weeks gestational age male newborn was born with a body weight of 4260 grams and congenital anomalies to an underage mother. He presented severe refractory hypoglycemia, congenital heart defect and dysmorphism. Coarctation of the aorta with hypoplasia of the aortic arch was surgically corrected, but needed a stent implantation due to re-coarctation in the course of hospitalization. Hyperinsulinemia was diagnosed with C-peptide concentration above the quantifiable threshold and decreased IGF concentration. The neonatal period was complicated by numerous infections (increased inflammatory markers), gastro-intestinal perforation and significant weight gain; macrosomia, hepatosplenomegaly and generalized tissue edema were observed. Throughout the hospitalization, the infant's respiratory function remained insufficient; he presented convulsive activity and anxiety despite continuous anticonvulsant and analgosedative therapy. Applied treatment failed to cause clinical improvement with subsequent myocardial hypertrophy and narrowing of the outflow tract from the right and left ventricles followed by metabolic acidosis, oliguria and multiple organ failure leading to death on the 57th day of life. The lack of histopathological examination of the kidney did not allow for confirmation of the diagnosis.

Conclusions

The clinical picture and the review of reported cases suggest the probability of Perlman's syndrome in our patient. Complete clinical diagnosis including autopsy in fatal cases should be introduced in rare clinical syndromes. Family cooperation is crucial but not always implementable.

[1639] Neonate patient with tuberous sclerosis complex and syndrome of infant of a mother with gestational diabetes: a case report

Authors: Jakub Góra, Aleksandra Barabasz

Affiliation: Student Scientific Association ProNeo at the Department of Neonatology and Rare Diseases of the Warsaw Medical University, Poland Head of Department: prof. dr hab. n.med. Bożena Kociszewska-Najman

Trustee of the paper: Dr Agnieszka Turzańska

Corresponding author: Jakub Góra (jakub.gra7@gmail.com)

Background

Tuberous sclerosis complex is a multisystemic genetic condition with autosomal dominant inheritance, characterized by a mutation in tumour suppressor genes TSC1 and TSC2 which lead to the development of hamartomas in kidneys, lungs, heart, central nervous system cutis, and eyes. Clinical manifestations of this disease emerge from tissue changes described above organs. The disease affects one in 10 000 newborns.

Case report

Male neonate born in 39th week of pregnancy in generally good condition. Pregnancy was complicated, the mother suffers from undiagnosed gestational diabetes. Family history reveals father with tuberous sclerosis complex. During the physical examination, heart murmurs were found. A heart echo scan exhibits multiple rhabdomyoma in heart chambers. Electrocardiography showed a disorder of repolarization. Presence of sinus tachycardia. Right ventricle overgrowth within the physiological norm. Ultrasonography of the other organs shows no pathological changes. Child don't need treatment. Nephrology, Cardiology, and Neurology consultations in the future were recommended.

Conclusions

Heart echo scan and family health history are crucial in properly diagnosing cardiac manifestation of tuberous sclerosis complex. Disorders of heart functionality result most likely not from rhabdomyomas, but from pregnancy complications, however, they don't affect it to the degree that could be dangerous for the child. Further observation of the patient is necessary due to the dynamic nature of TSC.

[1642] Can pneumothorax save a life? – A case report of an infant with congenital neuroblastoma

Authors: Paulina Woźniak

Affiliation: Department of Neonatology and Neonatal Intensive Care, Medical University of Warsaw

Trustee of the paper: Joanna Puskarz-Gąsowska PhD

Corresponding author: Paulina Woźniak (paulinawoz777@gmail.com)

Background

Neuroblastoma is a tumour that derive from the cells of sympathetic nervous system. It is the most common extracranial paediatric malignancy. Numerous locations of neuroblastoma result in huge polymorphism of symptoms, including asymptomatic tumours. I would like to present a case of an infant boy with asymptomatic, congenital, thoracic neuroblastoma.

Case report

The patient was a male twin born to a healthy mother (gravida 3, para 3) after a gestation of 35 weeks, delivered via a caesarean section, estimated 10 points in Apgar score and weighed 2840 grams. His twin brother was prenatally diagnosed with omphalocele and transported to the Department of Surgery within the first day of life. Due to increasing respiratory distress the patient was treated with nasal continuous positive airway pressure with FiO₂ 0.21, still after a few hours his condition deteriorated. A chest X-ray and lung ultrasound revealed right-sided pneumothorax, which was treated with an insertion of a chest tube and suction drainage. Lung ultrasound additionally showed a well-circumscribed mass in posterior mediastinum with internal vascularity and calcification, about 32x26mm large, which was penetrating to intervertebral foramina – Th5 to Th7 as CT later confirmed. In blood testing NSE was slightly elevated. With a histopathology report a diagnosis of neuroblastoma, stage L2 was made. There were no metastases in bone marrow and MYCN was negative for amplification in FISH method. In 123I-MIBG scintigraphy abnormal marker uptake was recorded only in the tumour projection.

With the combination of age <18 months, no MYCN amplification and stage L2 the patient had a very good prognosis. He was qualified for low-risk chemotherapy and received four cycles. In a follow-up visit 123I-MIBG scintigraphy showed no abnormal marker uptake, catecholamine levels in 24-hour urine collection were normal and CT scan revealed a residual, shrinking mass with no spine penetration. Currently the boy is under the care of the Department of Paediatrics and Oncology and he is in full remission.

Conclusions

About 50% of neuroblastomas are diagnosed in stage M. Early diagnosis may contribute to reducing the percentage of disease advancement and improve treatment outcomes as staging and age are important factors for prognosis. This case highlights the importance of oncological vigilance in as soon as in perinatal period.

[1647] Diagnostic difficulties related to the lack of AFP standards for premature babies

Authors: Martyna Berej, Joanna Końska

Affiliation: Student Scientific Association ProNeo at the Department of Neonatology and Rare Diseases of the Warsaw Medical University, Poland Head of Department: prof. dr hab. n.med.
Bożena Kociszewska-Najman

Trustee of the paper: Beata Borek-Dzięcioł

Corresponding author: Martyna Ewa Berej (martyna.berej1@gmail.com)

Background

Alpha 1-fetoprotein (AFP) is a glycoprotein synthesized by the liver . Although its biological function is not entirely known, AFP is often used as an oncological marker. High or increasing levels of AFP may indicate the onset of germ cell tumours, hepatocellular carcinoma or hepatoblastoma. However, prematurity is also a reason why elevated levels of alpha 1- fetoprotein may be observed. Reference ranges for preterm infants are not precisely specified but some studies suggest that the AFP level should not be higher than $134,734 \mp 42.444$ ng/ml. It is supposed to gradually decline as infants mature.

Case report

The authors present the case of a male infant born in 25 + 5/7 HBD with a birth weight of 800g. The boy had a full oncological diagnostic due to the detection of a change in the liver (in the 24th day of the baby's life) in the abdominal ultrasound examination significantly. The AFP concentration (>430 000 ng/ml) increased significantly as well. In the next days of the child's life, the level of AFP gradually decreased, and the suspected change in the liver was not seen (in the 59th day of the baby's life) either in the ultrasound examination of the abdomen or in the MRI. Based on the conducted examination and test results the authors conclude that the only explanation of extremely high AFP level was its being premature and its treatment.

Conclusions

The extremely high level of cancer marker, such as AFP can be helpful in diagnosis, but is not synonymous with the occurrence of cancer in the patient. An additional diagnostic challenge in the use of AFP levels in premature infants is the lack of a well-defined reference range for this patient group. This indicates the need for studies to establish standards for premature babies.

[1648] The significance of preliminary and differential diagnosis based on trisomy 13 and focal dermal hypoplasia

Authors: Martyna Berej

Affiliation: Student Scientific Association ProNeo at the Department of Neonatology and Rare Diseases of the Warsaw Medical University, Poland Head of Department: prof. dr hab. n.med.
Bożena Kociszewska-Najman

Trustee of the paper: Barbara Saniewska

Corresponding author: Martyna Ewa Berej (martyna.berej1@gmail.com)

Background

Patau syndrome is a genetic disease caused by chromosome 13 trisomy, occurring at a frequency of 1:10 000 live births. It is associated with a 95% risk of miscarriage and more than 90% of live born children die in the first year of life. The syndrome is characterized by, among others, defects of the organ of sight, cleft lip and palate, polydactyly, heart defects, microcephaly. Diagnosis is based on clinical manifestation and cytogenetic study. Due to the lethality of the disease, the treatment is limited to palliative care. Many of these symptoms also occur in patients with Goltz syndrome, called FDH (focal dermal hypoplasia) - a rare disease caused by mutation in the PORCN gene on the X chromosome. The prognosis in this case is definitely more advantageous.

Case report

The authors present the case of a male new born, in which Patau syndrome was suspected based on dysmorphic features and malformations. In the child, among others, residual eyeballs, loss of scalp, polydactyly of the hands and a defect in the heart (aortic coarctation, atrial septal defect, patent ductus arteriosus, dextrocardia) were observed. After consultation with the clinical geneticist, a preliminary diagnosis of Goltz syndrome was made and the boy was qualified for an urgent cardiac surgery (cardiorespiratory failure, cardiac arrhythmias). Eventually, the procedure was abandoned when the results of cytogenetic tests confirmed Patau syndrome in the boy. Palliative treatment was administered.

Conclusions

Despite the many common features of both genetic syndromes, the therapeutic approach is extremely different. It involves palliative care in the case of Patau syndrome, while in the case of Goltz syndrome, the procedure is focused on symptomatic treatment and prevention of secondary complications. The presented case shows how the planning, treatment and prognosis in a child changes depending on the initial diagnosis.

[1689] Congenital esophageal and tracheal malformations: a case report

Authors: Ugnė Šilkūnė, Ieva Apanavičiūtė, Rasa Brinkis

Affiliation: Lithuanian university of health sciences, Faculty of medicine, Kaunas, Lithuania;
Lithuanian university of health sciences, Department of neonatology.

Trustee of the paper: Rasa Brinkis

Corresponding author: Ugnė Šilkūnė (ugne.peciukaiyte@gmail.com)

Background

The esophagus and trachea develop very early in the fetus as the foregut tube divides. Failure of development can cause tracheoesophageal fistula and esophageal atresia. These congenital malformations of the trachea and esophagus include a wide assembly of anomalies with a broad spectrum of symptoms such as respiratory distress, choking, and failure to pass a nasogastric or endotracheal tube. Early diagnosis and treatment require interprofessional teamwork.

Case report

A preterm male infant was born to a healthy mother gravida 1 para 1 born via spontaneous vaginal delivery at 31 weeks of gestation, with a birth weight of 1470 grams. Esophageal atresia was suspected antenatally. The Apgar score was of 1– 1 at 1 and 5 minutes, respectively. The infant was born unresponsive and not breathing, the resuscitation was started.

Positive pressure ventilation with a T-piece resuscitator was started at a rate of 60 breaths per minute, however, there were no chest wall movements and no breathing sounds were heard on auscultation. During laryngoscopy there was a visible obstacle beyond the vocal cords, the neonatologists were unable to insert an endotracheal tube of 2.5 and 3 cm diameter deeper than 6 cm into mouth. Tracheal obstacle made pulmonary ventilation impossible. Chest compressions were continued as long as neonatologists were sure that the airway was closed and there was no way to restore breathing. After 20 minutes of resuscitation, the infant died.

The autopsy was performed. During the morphological examination, there was determined that the newborn had multiple congenital malformations including esophageal atresia with tracheoesophageal fistula, severe laryngeal stenosis, and horseshoe kidney.

Conclusions

This case report demonstrates that congenital tracheal and esophageal malformations may cause airway obstruction and may be a fatal condition in neonates.

[1777] The case of a newborn with Transient Abnormal Myelopoiesis and no signs of Down Syndrome.

Authors: Natalia Zamorska

Affiliation: SKN of Pediatrician Oncology and Hematology

Trustee of the paper: Małgorzata Czogała MD

Corresponding author: Natalia Zamorska (natizamo@wp.pl)

Background

Transient abnormal myelopoiesis (TAM) is a remarkable hematologic abnormality that usually co-occurs with Down syndrome (DS) or mosaic trisomy 21 in children. Furthermore the GATA1 mutation is representative and correlated with this disorder. In the clinical picture it can manifest as many different phenotypes - it may be detected incidentally or during a rapid course with a fatal result. Importantly TAM should always be differentiated with congenital leukemia (CL), which contrary to TAM can reveal as an extremely critical prognosis.

Case report

We would like to present the case of a newborn girl with anemia, leukocytosis, thrombocytosis and presence of blasts in peripheral blood smear whose condition and test results could have given a suspicion of AML M7. Nevertheless, examination findings – appearance of non-typical anomalies at that age in morphological and blood smear tests - got specialist's attention and could have suggested TAM. Interestingly enough, 21 trisomy and GATA 1 mutation were detected in genetic testing but only in the blast cells, moreover there were no phenotypic signs of DS. Because of increasing hepatomegaly and dyspnea four-day cytorductive therapy was used. Afterwards gradual normalization of complete blood count was observed.

Conclusions

In diagnostics, it is incredibly important to identify which entity we deal with in the particular case. Moreover, for this reason, making an early diagnosis is rather difficult and challenging so far. Lastly, prompt GATA1 testing of blasts before self-resolution can establish a definitive diagnosis, allowing for the effective counseling of families on both immediate and long-term management and screening.

[1914] A 7-day-old patient with encephalitis caused by human parechovirus infection - a case report

Authors: Patrycja Bzdziuch, Jakub Buziak, Katarzyna Cencelewicz, Joanna Chajec

Affiliation: Medical University of Lublin / Department of Neonate and Infant Pathology

Trustee of the paper: MD PhD Agata Tarkowska

Corresponding author: Patrycja Bzdziuch (patrycja.bzdziuch@op.pl)

Background

Human parechovirus (HPEV) belonging to the family Picornaviridae is non-enveloped, positive-sense, single-stranded RNA virus. It can cause severe illness and be very dangerous to children, especially younger than three months. HPEV has multiple types which cause various clinical symptoms like irritability, fever, rash, seizures, lethargy, diarrhea or feeding difficulties. More serious consequences are meningitis, sepsis, encephalitis. Central nervous system manifestations are associated with genotype 3 of HPEV.

Case report

A 7-day-old full-term male neonate was admitted to the Department of Neonate and Infant Pathology with otitis media of the right ear. Examination revealed a failure to thrive, signs of dehydration, neonatal jaundice, erythematous papular rash, small hydroceles. Laboratory tests did not show high level of CRP and PCT or any significant abnormalities. The patient was hydrated and treated with Paracetamol and Ampicillin. Several hours after admission irritability persisted and fever and tachycardia appeared. The next day of the hospitalization two episodes of hemiclonic seizures occurred. Antiepileptic treatment with phenobarbital was applied. Follow-up laboratory tests without CRP or PCT increase. Due to the symptoms suggestive of CNS involvement, a lumbar puncture was performed. Based on cerebrospinal fluid analysis with the rapid test for 14 pathogens - Biofire, human parechovirus, which caused encephalitis, was identified. Head MRI was performed and showed diffuse inflammatory lesions in white matter and periventricularly. Following the diagnosis, antibiotic doses were reduced from meningeal doses to those used for the otitis and immunoglobulin infusions were administered. During hospitalization, the patient's health was gradually improving. After 10 days, the patient was discharged from the hospital in a good condition and follow-up visit in 3 weeks was advised.

Conclusions

Despite most people don't show symptoms of the HPEV infection, infants and neonates are exposed to the increased risk of severe course of the disease and required hospitalization. This case suggests that appropriate diagnostics and symptomatic treatment can improve patient's condition and avoid complications.

Neurology & Neurosurgery

Date: 21st April 2023, 15:00 PM

Coordinators:
Weronika Zając
Aleksandra Kulczyk

Sponsor:

Novartis



Patronage:

Krajowy Konsultant w dziedzinie Neurochirurgii prof. dr hab. Tomasz
Trojanowski Krajowy Konsultant w dziedzinie Neurologii prof. dr hab. Agnieszka
Słowik Neurologia Praktyczna

[1508] Transient global amnesia - hippocampal lesions in magnetic resonance imaging

Authors: Aleksandra Golenia (MD, PhD), Antoni Ferens (MD, PhD), Anna Kolasa (MD), Aleksandra Ignatiuk (MD) and Anna Kostera-Pruszczyk (MD, PhD, Professor)

Affiliation: Department of Neurology, Medical University of Warsaw

Trustee of the paper: Piotr Olejnik (MD student)

Corresponding author: Piotr Olejnik (piotrek.olejnik2001@gmail.com)

Introduction

Transient global amnesia is a benign syndrome characterised by a sudden onset loss of anterograde amnesia without other accompanying focal neurological symptoms, lasting less than 24 hours. There is no long-term sequela. Diagnosis is based on the clinical picture. Pathophysiologic mechanism is still not fully understood, but it appears that transient dysfunction of the hippocampus might play the main role.

Aim of the study

Aim of the study was analysis of presence of hippocampal lesions in MRI DWI in patients with TGA and possible influence of additional factors on their appearance.

Materials and methods

Single-center, retrospective, observational study included 38 patients presenting with TGA. All patients were examined by a neurologist and diagnosis was based on the Caplan's criteria revised by Hodges and Warlow. The criteria include 1) presence of anterograde amnesia witnessed by the observer, 2) no clouding of consciousness or loss of personal identity, 3) cognitive impairments limited to short-term memory loss, 4) no focal neurologic or epileptic signs, 5) no recent history of head injuries or seizures, 6) resolution of symptoms within 24 hours. Demographic data, details of the episode (duration, triggers, onset time), and previous medical history (hypertension, dyslipidemia, atrial fibrillation, diabetes mellitus, migraine) were collected. MRI DWI was performed in all patients who did not have a contradiction. The study technique included an optimized diffusion sequence.

Results

A total of 38 patients with TGA were included for analysis (17 men, 21 women). Complete recovery was 4.08 (SD 3.87, range 0.5-18) hours. 13% patients had recurrent amnesia. Precipitating events such as stress and moderate to vigorous exercise preceded the onset of amnesia in 13% and 16% patients, respectively. There was no higher incidence of migraine in TGA patients (13%). All patients had normal electroencephalogram. There was also no correlation between symptoms duration, analyzed variables, and age. Thirty-six of the patients underwent an MRI DWI within the first days of hospitalization (except 2 patients). In 47% patients isolated, dot-like, hyperintense hippocampal MRI DWI lesions with a mean diameter of 2 mm were detected.

Conclusions

Various conditions might lead to the hippocampal MRI-DWI lesions, and these lesions are not pathognomonic for TGA. Overall, nearly 50% of individuals with TGA had hippocampal MRI DWI lesions. There was a preference for left-sided hippocampal lesions which requires further investigation.

[1510] How should the catheter in VP shunt be placed? Influence of placement on malfunction.

Authors: Karolina Markusiewicz

Affiliation: Medical University of Warsaw

Trustee of the paper: Emilia Sołtan, MD, PhD

Corresponding author: Karolina Alicja Markusiewicz (karolinamarkusiewicz@gmail.com)

Introduction

Ventriculoperitoneal shunt (VP) insertion is the gold standard procedure to manage hydrocephalus (HCP). VP drains the excess of the cerebrospinal fluid (CSF) from the ventricular system into the peritoneal cavity. Ventricular catheter blockage is the most common cause of VP malfunction.

The ventricular catheter may be placed into the anterior horn of the lateral ventricle through the Kocher's point or through the parieto-occipital approach (Keen's point) into the trigone of the lateral ventricle.

Aim of the study

The aim of this study was to assess the safety and efficacy of VP placement and determine the risk of shunt malfunction depending on the place of the insertion of the ventricular catheter.

Materials and methods

The retrospective analysis was based on the data of 176 patients under the age of 10 months (39% female, 61% male), collected over a period of 6 years (2017-2022). 145 patients (n=145), who had undergone VP placement using either frontal (n₁ = 91) or parieto-occipital (n₂ = 54) approach, were involved. From the frontal horn group, 24,2% of patients required a replacement of the catheter, and from the parieto-occipital group – 40,7%. A null hypothesis (H₀: p₁ - p₂ = 0), which stated that there was no difference in the outcome in two corresponding groups, was established and tested against an opposite one (H₁: p₁ - p₂ ≠ 0). The z-test $((p_1 - p_2) / \sqrt{SE_{pooled}(p_1 - p_2)})$ was performed to conclude whether to reject or confirm the null hypothesis. All the requirements for the study to be eligible for the z-test were met. During the study, the Standard Error, Z-test, and p-value were calculated.

Results

The value of the calculated Z-test was -2.0975, hence the p-value of the results was 0.03572 which led us to reject the null hypothesis at a significance level of 0.05. There was enough evidence to conclude that there is a statistically significant difference between the outcomes in those two populations.

Conclusions

The patients that had a placement of ventriculoperitoneal shunt performed through a parieto-occipital approach to the ventricular system were more likely to need a replacement of the catheter later in the future because of the ventricular catheter blockage. Based on the results of the study, it should be advised to choose the frontal approach to the ventricular system, when possible.

[1538] Analysis of influence of prenatal exposition to testosterone and serum testosterone level in patients with multiple sclerosis treated with natalizumab and fingolimod.

Authors: Dominika Świerczewska, Karolina Pendrasik, Kacper Mazurkiewicz, Michalina Wiwatowska-Ligęza

Affiliation: Department of Neurology, University Hospital No 1, Medical University of Lodz.

Trustee of the paper: Bartosz Bielecki MD, PhD

Corresponding author: Dominika Świerczewska (domi.swierczewska@gmail.com)

Introduction

Multiple sclerosis (MS) is a chronic inflammatory demyelinating disease of the central nervous system (CNS). Many studies show a role of androgens in pathogenesis of MS. Women are more often affected by MS than men. Exposition to low levels of testosterone (T) during prenatal period as well as hypogonadism represent risk factors for developing MS. Whereas high serum testosterone levels in adult patients can be a protective factor in terms of MS. Androgens are known modulators of peripheral immune response but T plays also a role in formation and repair of myelin in the CNS suggesting its neuroprotective role.

Aim of the study

In this work we studied a link between prenatal exposition to T, serum T levels and clinical progression of patients treated for relapsing-remitting form of MS (RRMS).

Materials and methods

We enrolled 33 patients with RRMS treated with natalizumab (NTZ) and fingolimod (FDG). Digit ratio (DR) was measured using a digital scanner. Serum T concentration was measured with electrochemiluminescence. Neurological outcome was determined using standard Expanded Disability Status Scale (EDSS). For assessment of cognitive functions we used Symbol Digit Modalities Test (SDMT), Montreal Cognitive Assessment (MoCA), Fatigue Scale for Motor and Cognitive Function (FSMC) and Modified Fatigue Impact Scale (MFIS). Since patients suffering from MS frequently cope with depressive disorders we measured its severity with Beck Depression Inventory (BDI).

Results

We found a correlation in female patients treated with FNG between serum T level and progression in MFIS psychosocial and also a correlation in female patients treated with NTZ between DR and FSMC cognitive. In male patients treated with NTZ we observed an association between serum T level and progression in SDMT and also between T and progression in MFIS cognitive. There is also a relation in all male patients between DR and progression in BDI. The obtained results reached statistical significance.

Conclusions

Our observations indicate an existing link between prenatal exposition to T, serum T level and outcome of patients with RRMS treated with NTZ and FDG. The data may provide useful information for the use of DR and serum T level as a marker for response to different MS therapies.

[1573] Endoscopic Endonasal Repair of Transsphenoidal/Transethmoidal Meningoencephalocele and Meningocele - Surgical Outcomes and Complications Analysis

Authors: Jia Jia Teo, Barbara Buchalska, Pawel Poppe, Jacek Kunicki

Affiliation: Department of Neurosurgery, Marie Curie National Research Institute of Oncology, Warsaw

Trustee of the paper: Dr n. med. Jacek Kunicki, MD PhD

Corresponding author: Jia Jia Teo (angela.teojajia2508@gmail.com)

Introduction

Transsphenoidal/transethmoidal meningoencephalocele (or meningocele) are rare entities most commonly presenting as spontaneous CSF leaks. The defects of the lateral wall of the sphenoidal sinus for meningoencephalocele are considered congenital lesions, but some factors (increased ICP) may lead to acquired secondary skull base defects.

Aim of the study

The purpose of the study was to analyse the surgical outcomes, incidence and evolution of complications in cases of endoscopic endonasal repair (EEN) of Meningoencephalocele/ meningocele of the sphenoid sinus.

Materials and methods

The study is a retrospective clinical case series analysis. Eleven consecutive cases of meningoencephalocele and meningocele of the sphenoid sinus operated on using an endoscopic endonasal approach from 2011 to 2022 at the National Research Institute of Oncology in Warsaw, Poland, were reviewed. All patients have undergone reconstructions of skull base defects through extended transnasal transsphenoidal/ transpterygoid endoscopic approaches.

Results

The series includes 11 patients (3 men, 8 women). All patients in this series presented with CSF rhinorrhea and it was associated with meningitis in 3 cases. There were no severe complications associated with surgery. There was no CSF leak postoperatively. Two patients complained of transitional hypoaesthesia of the V2 dermatome of the face, and there were three cases with sinusitis and one case of prolonged intranasal crusting.

Conclusions

Endoscopic endonasal surgery is a safe and effective approach for meningocele and meningoencephalocele of the sphenoid sinus. This minimally invasive method allows the resection of the meningeal hernia and repair of the skull base defect with favourable clinical outcomes and a low number of complications.

[1620] Visual disturbances in patients with Parkinson's disease and treated with oral medications or with deep brain stimulation.

Authors: Jakub Rusinek

Affiliation: Jagiellonian University Medical College - SSG of Neurology at the Department of Neurology UJ CM

Trustee of the paper: Małgorzata Dec-Ćwiek MD, PhD; Karolina Porębska MD, PhD

Corresponding author: Jakub Mikołaj Rusinek (kuba.rusinek22@gmail.com)

Introduction

Parkinson's disease (PD) is the second most frequent neurodegenerative disorder, simultaneously being the most frequent movement disorder. It might be treated with medications or deep brain stimulation (DBS). Ophthalmological symptoms are common in patients with PD. Visual Impairment in Parkinson's Disease Questionnaire (VIPD-Q) is a recently developed questionnaire assessing ophthalmological symptoms in PD which consist of 17 questions divided into 4 domains (ocular surface, intraocular, oculomotor and optic nerve).

Aim of the study

The aim of this study was to assess the prevalence of and the severity of ophthalmological symptoms depending on the type of treatment used – pharmacological or DBS.

Materials and methods

It was a cross-sectional study. The data was gathered by VIPD-Q completed during the visit in an outpatient clinic and from medical records. 79 patients suffering from PD were included. Then the 2 groups were identified. The allocation was based on the type of treatment – pharmacological (39 patients) or DBS (40 patients).

Results

There were no statistically significant differences between the groups concerning general characteristics apart from median disease duration – 7.0 (5.0 – 11.0) years in the pharmacological group and 14.0 (11.5 – 19.5) years in the DBS group ($p < 0.001$). 72 (91.1%) patients experienced at least one ophthalmologic symptom occurring at least once a week – 37 (94.9%) in the pharmacological group and 35 (87.5%) in the DBS group ($p = 0.432$). There were no significant differences between the groups regarding VIPD-Q domains or total score. The prevalence of 3 symptoms differed significantly between the groups. Burning sensation or gritty feelings in the eyes occurred in 6 (15.4%) patients in the pharmacological group and in 16 (40.0%) patients in the DBS group ($p = 0.015$). The inability to read plain text on a colored or grey background was present in 15 (38.5%) patients in the pharmacological group and in 6 (15.0%) patients in the DBS group ($p = 0.018$). Problems with rapid changes of light intensity occurred in 11 (28.2%) patients in the pharmacological group and in 4 (10.0%) patients in the DBS group ($p = 0.039$).

Conclusions

The study confirmed the high prevalence of ophthalmological symptoms in patients with PD. However, there are only small differences in the prevalence of those symptoms in patients treated pharmacologically or with DBS. It cannot be established which method is better for relieving ophthalmological symptoms.

[1678] The influence of different levodopa equivalent daily doses on heart rate and mean arterial pressure in patients with Parkinson's disease

Authors: Barbara Buchalska

Affiliation: Neuromodulation Section, Students Scientific Group, Department of Neurology, Faculty of Health Science, Medical University of Warsaw

Trustee of the paper: Stanislaw Szlufik, MD, PhD

Corresponding author: Barbara Anna Buchalska (buchalskabara@gmail.com)

Introduction

Parkinson's disease (PD) is one of the most commonly diagnosed movement disorder. Patients with PD are treated mainly with levodopa to restore dopamine levels in the body. It was shown levodopa may reduce arterial blood pressure but has no effect on heart rate. The DBS STN procedure (Deep Brain Stimulation of the Subthalamic Nucleus) is an effective treatment of PD, and it allows for a reduction in levodopa doses taken by the patients.

Aim of the study

The study was conducted to assess if high and low levodopa equivalent daily doses (LEDD) differ in their influences on heart rate (HR) and mean arterial pressure (MAP) in patients with PD.

Materials and methods

We recruited 33 patients who were hospitalized in Department of Neurology. 18 patients were assigned to the control group, did not undergo DBS STN procedure and had mean LEDD value of 1229 mg, 15 patients were assigned to the study group, underwent DBS STN procedure, and had mean LEDD value of 744 mg. During hospitalization all patients had Holter monitoring of MAP and HR for 24 hours. The Holter device measured these values every hour.

Results

The patients with DBS STN implantation and lower LEDD value had the mean HR value decreased by 5,6% (from nearly 61,4 beats per minute to 58,62, $p=0,14$) compared to control group. The mean MAP value decreased non-significantly by 2% (from approximately 80,41 mmHg to 78,91, $p=0,6$).

Conclusions

There were no significant differences in MAP and HR values in patients with high and low levodopa doses. Although DBS STN allows for a reduction in LEDD it does not increase heart rate or arterial blood pressure.

[1704] IMPACT OF BILATERAL SUBTHALAMIC NUCLEUS DEEP BRAIN STIMULATION ON COGNITIVE FUNCTIONS IN PARKINSON'S DISEASE PATIENTS.

Authors: Aleksandra Ćwiklińska

Affiliation: Neuromodulation Section, Students Scientific Group, Department of Neurology, Faculty of Health Science, Medical University of Warsaw, Head of Department: Dariusz Kozirowski, MD, PhD

Trustee of the paper: Stanislaw Szlufik, MD, PhD

Corresponding author: Aleksandra Ćwiklińska (ola.cwiklinska412@gmail.com)

Introduction

Parkinson's disease (PD) is one of the most common neurodegenerative movement disorders. Deficit of dopamine causes the characteristic triad of motor symptoms: bradykinesia, rigidity and tremor. The first stage of medical treatment is pharmacotherapy but due to the fact of disease progression, complications of pharmacological treatment occur - the majority of PD patients (>90%) after 10 years suffer from motor fluctuations and drug-induced dyskinesia. Recent guidelines for advanced PD patients allow qualification to bilateral subthalamic deep brain stimulation (STN-DBS) only in cases without dementia. Besides to the strict qualification to STN-DBS, the cognitive functions in PD patients can deteriorate.

Aim of the study

The aim of our study was to assess the progression of cognitive impairment among patients with PD after bilateral STN-DBS in PD patients.

Materials and methods

Twenty patients (10 females and 10 males) with idiopathic PD were psychologically examined before the surgical procedure (V0) and three times after bilateral STN-DBS (V1, V2, V3) in the time intervals of 12±4 months. The cognitive tests were performed by neuropsychologists who assessed general cognitive functions (Mini-Mental State Examination, MMSE) and then fully the executive functions (verbal fluency tests), memory (CVLT), language (WAIS-R similarities), working memory and attention (Trial Making Test, WAIS-R digit span). Patients were also examined using Beck Depression Inventory in order to exclude depressive disorders.

Results

The study showed, that executive functions, language, working memory and attention have deteriorated significantly ($p < 0.05$), but not in first postoperative evaluation (V1/V0 not statistically significant), but during longer time of post-operational observation (V2, V3). Interestingly, MMSE results improved during first post-operational evaluation (but non-significant). Depressive disorders have improved significantly after STN-DBS ($p < 0.05$). Results in particular series of neuropsychological examinations were compared by Wilcoxon's test.

Conclusions

Bilateral STN-DBS stimulation can impact the cognitive function and mood in PD patients without the cognitive impairment before the surgery. Therefore the deterioration of cognitive functions should be always taken into consideration during pre-operative qualification of PD patients.

[1710] Infusion pump therapy after STN DBS surgery as a new therapeutic option in advanced Parkinson's disease patients.

Authors: Karolina Jaros

Affiliation: Neuromodulation Section, Students Scientific Group, Department of Neurology, Faculty of Health Science, Medical University of Warsaw

Trustee of the paper: Stanislaw Szlufik, MD, PhD

Corresponding author: Karolina Jaros (karolinajaros99@gmail.com)

Introduction

Deep brain stimulation (DBS) and infusion pumps with apomorphine or duodopa are possible treatment methods for patients with advanced Parkinson's disease. DBS is known for its high success rates and rare side effects. However, some of the patients need more restorative therapy due to PD progression and continuing motor disability. In such cases, implementation of infusion pumps (apomorphine, duodopa) may give significant improvement in motor and nonmotor disabilities.

Aim of the study

The study aimed to evaluate the impact of additive infusion pump therapy to bilateral DBS STN therapy in PD patients.

Materials and methods

We enrolled 4 patients with idiopathic PD (3 females, 1 male, mean age: 52,5; mean age of onset: 52,5), who underwent bilateral DBS STN surgery following infusion pump therapy (mean time between procedures: 7,5 years). The effects of each therapeutic option (pharmacotherapy, STN DBS, infusion therapy) were assessed with the use of motor examination in on and off phase (UPDRS III scale), Hauser's diaries and QoL scales.

Results

There is a significant difference in LEDD (1505,9 pts, $p < 0,05$) and UPDRS III OFF (44,3 pts, $p < 0,05$), UPDRS III ON (11,4 pts, $p < 0,05$) between DBS and pharmacotherapy and a combination of pharmacotherapy, DBS and infusion pump. Patients require higher doses of pharmacotherapy and their UPDRS scores are higher after implementation of the infusion pump. Performed QoL scales showed a significant difference in patients' answers: PDQ 39 (59,0 pts, $p < 0,05$), EQ VAS (60,1 pts, $p < 0,05$), EQ 5D mobility (1,3 pts, $p < 0,05$) and EQ 5D usual activities (1,0 pts, $p < 0,05$). And non-significant difference in EQ 5D self-care (0,3 pts, $p = 0,21$), EQ 5D pain/discomfort (0,4 pts, $p = 0,24$) and EQ 5D anxiety/depression (0 pts, $p = 1$). Results indicate improvement in the overall quality of patients' life. Significant reduction in sleepiness was achieved according to PDSS-1 (105,8 pts, $p < 0,05$) and Epworth sleepiness scale (6,58 pts, $p < 0,05$)

Conclusions

Initially, patients with advanced PD have satisfactory results after DBS. However, they may gradually re-experience symptoms of the disease. Implementation of Infusion pumps may be a therapeutic option that enables once again the management of symptoms.

[1731] Early changes of cognitive function after temporal lobe epilepsy surgery

Authors: Saulius Ročka

Affiliation: Vilnius University, Faculty of Medicine

Trustee of the paper: Prof. Saulius Ročka PhD, MD

Corresponding author: Saulius Ročka (rocka.saulius@gmail.com)

Introduction

With estimated prevalence of approximately 1%, epilepsy remains one of the most frequent disorders of the central nervous system with temporal lobe epilepsy (TLE) being the most common form of focal epilepsy among adults. To this date, TLE is regarded to be drug resistant, therefore resection of the epileptogenic brain tissue remains the only effective treatment method. Typically, TLE originates in the structure of the limbic system called hippocampus (Ammon's horn), eventually leading to hippocampal sclerosis. Ammon's horn has a major role in memory, learning and spatial navigation, thus lesioned hippocampus is often associated with cognitive dysfunction. Confirmed cognitive function improvement after temporal lobe epilepsy surgery could be of a potential prognostic value for neurosurgeons not only treating drug resistant epilepsy but also achieving enhanced cognitive performance.

Aim of the study

Evaluate early changes of cognitive function before and after the temporal lobe epilepsy surgery.

Materials and methods

A total of 14 patients (8 males, 6 females) assigned for temporal lobe epilepsy surgery were included in the prospective study over the course of three years from 2020 to 2023. Mini-Mental State Examination (MMSE) was administered one day before and five days after the surgical intervention as a measure to evaluate changes of early cognitive function.

Results

A mean score of Mini-Mental State Examination before surgery was 26.79 (18; 30). Five days after the temporal lobe epilepsy surgery mean score of MMSE increased to 27.93 (24; 30), indicating the average score increase of 1.14. Elimination of three patients without cognitive dysfunction even before surgery (MMSE=30) decreased the mean score to 25.50 (18; 29) one day before surgery and improved the post-surgical mean MMSE score to 27.10 (24; 30). On average, 1.60 higher MMSE score was achieved after TLE surgery compared with the result one day before surgery in patients with cognitive dysfunction. There were no statistically significant differences in measurement results between hemispheres or genders.

Conclusions

The study showed that early cognitive function slightly increases after temporal lobe epilepsy surgery based on Mini-Mental State Examination score.

[1743] Treatment of chronic subdural hematoma with embolization of middle meningeal artery

Authors: Sandra Pilawska, Aleksandra Bodzioch, Adriana Nudga, Paweł Mizera

Affiliation: Student Scientific Group at Department of Neurosurgery and Neurotraumatology, Jagiellonian University Medical College, Krakow, Poland

Trustee of the paper: Roger Krzyżewski MD, PhD, Jarosław Pola MD, PhD

Corresponding author: Adriana Nudga (nudga.adriana@gmail.com)

Introduction

Chronic subdural hematoma is a neurosurgical pathology with one of the highest recurrence rates. Due to its complicated physiology, outcomes are hard to predict. Recently embolization of the middle meningeal artery has been introduced as a first line treatment or an adjuvant therapy.

Aim of the study

In this study we explore the clinical course and outcome of patients with embolized middle meningeal artery in chronic subdural hematoma.

Materials and methods

We prospectively analyzed data of 60 patients undergoing embolization of the middle meningeal artery. We recorded clinical risk factors, results of treatment and the possible complications.

Results

Embolization of MMA was used as the first line treatment in 15% of cases. The patients who received embolization as first line treatment were statistically older as well as had fewer symptoms (77.87 vs 68.12 years; $p=0.01$). Intracranial complications occurred in 5.33% of cases; 2 cases of peripheral facial nerve palsy, 1 case of partial blindness in ipsilateral eye, 1 case of vertigo and 1 case of increased headache. 75% of the patients were discharged home. The Mean time of hospitalization for all patients was $2,3 \pm 1,1$ days.

Conclusions

Embolization of MMA seems safe and effective both for first line treatment and adjuvant therapy for chronic subdural hematoma. Serious neurological complications occurs in less than 5% of procedures. Most patients return home within three days after admission.

[1861] **Surgical anatomy of the tuberculum sellae complex and its relations with the tuberculum recess of the sphenoid sinus.**

Authors: Jakub Skiba

Affiliation: Department of Neurosurgery, National Research Institute of Oncology Warsaw

Trustee of the paper: MD, PhD Jacek Kunicki

Corresponding author: Jakub Łukasz Skiba (theskiib@gmail.com)

Introduction

Development of transsphenoidal endoscopic approaches revitalized surgical anatomy of the sellae and sphenoid sinus. The tuberculum recess is defined as the indentation corresponding to the tuberculum sellae complex.

Aim of the study

The aim of the study was to describe morphological variability of the tuberculum recess and show their intraoperative use.

Materials and methods

The authors performed anatomical study on 114 middle skull base blocks without any pathologies. The specimens were scanned using Toshiba Astelion 16 row CT. The morphometrical analysis of the tuberculum sellae complex were performed in CT scans and specimens. The simulation of the endoscopic trans-tubercular transsphenoidal approach in 15 scanned blocks to correlate with CT measurements and observations.

Results

Based on the CT measurements, the tuberculum complex was divided into type I - defined (62.28%) and type II - ill-defined (37.72%). Type 1 was then subdivided into subtype A tuberculum recess angle $<122^\circ$ (33.8%), subtype B $>122^\circ$ (52.1%) and subtype C "C" - like recess (14.1%). Type 2 has been categorized based on the cause of the difficulty in defining a recess. Subtype A distended recess (48.84%) and subtype B no pneumatization of the recess or its ossification (51.16%). The authors then compared the operative observations and correlated them with the selected types.

Conclusions

The pneumatization of the sphenoid sinus correlates with morphological variability of the tuberculum recess. We believe our classification has potential to help preoperative planning and allowing for better estimation of exposure range during transtubercular approaches.

[1862] Clinicopathological analysis and outcomes of thyrotrophe pituitary neuroendocrine tumors (TSH immunopositive adenomas).

Authors: Jakub Skiba

Affiliation: Department of Neurosurgery, The Maria Skłodowska-Curie National Research Institute of Oncology, Warsaw, Poland

Trustee of the paper: MD, PhD Jacek Kunicki

Corresponding author: Jakub Łukasz Skiba (theskiib@gmail.com)

Introduction

TSH pituitary neuroendocrine tumors (PitNET)s, are a rare type of tumor (1 - 3%), derived from Pit1 transcription factor line.

Aim of the study

The aim of the study was to analyze the results of surgical treatment, invasive character and the clinical and pathological characteristics of new various types of PitNETs that can secrete TSH.

Materials and methods

The study is a retrospective analysis of patients diagnosed with thyrotrophe pituitary neuroendocrine tumors(TSH-secreting adenomas) . TSH Pitnet were defined as those with immunohistochemical staining for TSH, even if they also stained for other hormones. During 2005-2022, 39 patients were treated with transsphenoidal endoscopic surgery at the Department of Neurosurgery, Those patients accounted for 1.55% of the operated andenoma cases.

Results

Our group consisted of 39 cases (26 women and 13 men) The mean age at diagnosis was 48 aged (range 19 to 47) . There were 33 macroadenomas, 4 giant adenomas and 2 microadenomas. The most frequently reported symptoms were headache (56%) and visual disturbances (31%). Central hyperthyroidism was diagnosed in 10 (26%) patients. Twenty seven tumors (69%) stained for other hormones, 8 of which were classified as immature Pit1-lineage PitNETs and 13 mature plurihormonal PIT1-lineage PitNETs. There were 33 macroadenomas, 4 giant adenoma and 2 microadenomas. Invasive character (suprasellar invasion, Knosp III and IV) was observed in 6 (75%) immature Pit1 PitNETs, 6 (46%) mature plurihormonal PIT1 PitNETs and 7 (39%) thyrotroph tumors. Surgical results : 33 patients (85%) achieved complete resection confirmed by MR examination. There were no serious complications or deaths: transient diabetes insipidus - 4, cerebrospinal fluid leakage - 2, SIADH – 1, paresis of the oculomotor nerve - 1.

Conclusions

Thyrotrophe pituitary neuroendocrine tumors are rare tumors that typically present as macroadenomas, in majority not presenting with primary hyperthyroidism . Surgical treatment of immunopositive TSH PitNETs by transsphenoidal endoscopic methods is a safe and highly effective method. The factors limiting the effectiveness of surgical treatment are the invasive growth and the multi-hormonal nature of the tumor.

[1896] The efficacy of Deep Brain Stimulation of the subthalamic nucleus in the treatment of Parkinson's disease

Authors: Barbara Buchalska, Karolina Jaros, Agata Marszałek

Affiliation: Neuromodulation Section, Students Scientific Group, Department of Neurology, Faculty of Health Science, Medical University of Warsaw

Trustee of the paper: Stanislaw Szlufik, MD, PhD

Corresponding author: Agata Marszałek (agata19x@gmail.com)

Introduction

Parkinson's disease (PD) is one of the most commonly diagnosed movement disorder. Patients with PD experience many disturbing physical symptoms such as rest tremor, rigidity and slowness of movement. They also have emotional disorders like anxiety, depression or apathy. Deep Brain Stimulation of the subthalamic nucleus (DBS STN) is a gold standard surgical therapy, which may reduce many motor and non-motor symptoms of PD.

Aim of the study

The study was conducted to assess the efficacy of DBS STN in the treatment of non-motor symptoms in PD patients.

Materials and methods

The study group consisted of 29 patients (8 women and 21 men, mean age 58.4 ± 10 years), with idiopathic PD, who underwent the DBS STN implantation procedure. The scales assessing quality of life (PDQ8, PDQ-39) and non-motor symptoms of PD (PDSS, Epworth, TAS-20, HADS, AES, SRMI) were evaluated two times in each case (before and 24 months after DBS STN surgery).

Results

After the DBS STN implantation, the patients' mean PDQ-39 score decreased by 41% (from nearly 56 points to 33 points, $p=0,002$). The mean PDQ-8 score decreased by 33% (from approximately 12 to 8 points, $p=0,01$) and the mean PDSS score increased by 12% (from nearly 91 to 108 points, $p=0,02$). The remaining non-motor scales were not significantly altered ($p>0,05$).

Conclusions

DBS STN implantation may significantly improve PD patients' quality of life and such non-motor functions like sleepiness, but tends not to severely impact on mania, apathy and emotional problems in this group of patients.

[1935] Circulating plasma microrna profiling for both diagnostic and predictive potential in patients with ischemic stroke

Authors: Ceren Eyileten, Anna Nowak, Disha Keshwani, Zofia Wicik, Piotr Szwed, Michael Chong, Salvatore De Rosa, Guillaume Pare, Marek Postula

Affiliation: Department of Experimental and Clinical Pharmacology, Centre for Preclinical Research and Technology (CePT), Medical University of Warsaw, Warsaw, Poland

Trustee of the paper: Ceren Eyileten

Corresponding author: Disha Keshwani (dishkeswani@gmail.com)

Introduction

We aimed to identify and validate circulating miRNAs, modulated in ischemic stroke (IS) patients in order to distinguish the most specific as biomarkers to facilitate diagnosis and prognosis.

Aim of the study

Two microarray miRNA profilings were done and validated by RT-qPCR to explore (i) diagnostic miRNAs (29 acute IS patients vs 30 controls), and (ii) predictive miRNAs (24 patients with single stroke vs 24 patients with multiple stroke or TIA-NAVIGATE-ESUS cohort (ClinicalTrials.gov, NCT02313909)).

Materials and methods

2 microarray miRNA profilings performed, validated (RT-qPCR) to explore; diagnostic miRNAs (29 acute IS patients vs 30 controls), predictive miRNAs.

Results

Microarray data identified 146 up- and 258 downregulated miRs. Target prediction of those miRNAs showed 67 up- and 125 downregulated miRNAs. Upregulated top miRNAs were associated with BDNF, IL-2 signaling pathway, FSH regulation of apoptosis, Axon guidance, TGF-beta regulation of EC matrix. Downregulated miRNAs were most associated with Neuronal Signaling by NGF. ANKRD52, AGO1 were targeted by all types of DE miRNAs. Most susceptible to regulation by upregulated miRNAs: ANKRD12 and HIF1A and downregulated miRNAs: GNAI2 and GRIN1. Diagnostic: miR-18a5p was higher in IS patients at day1/day7 compared to cntrl($p=0.001, p=0.009, res$). MiR-199a5p was higher in acute IS, and stayed upregulated at day7 ($p<0.001, p=0.002, res$). MiR-4467 was lower in the IS patients at day1 compared to cntrl ($p<0.001$). MiR-3135b was downregulated in IS patients at day1/day7 compared to cntrl ($p<0.001, p<0.001, res$). ROC showed diagnostic value for all studied miRNAs for acute IS ($p<0.01$). Predictive: MiR-4786(AUC=0.88; $p=0.008$), miR-1288(AUC=0.93; $p=0.027$), miR-548ar3p (AUC=0.85; $p=0.009$), Let-7e5p(AUC=0.52; $p=0.005$) and miR-125a5p(AUC=0.52; $p=0.008$) were upregulated, whereas miR-4676(AUC=0.91; $p=0.003$) was downregulated, in patients with events. qPCR confirmed the microarray results for all studied miRNAs($p<0.0001$), which showed predictive value for risk of events in ROC($p<0.0001$). Enrichment analysis: IL-2, lipid metabolism, BDNF/MAPK signaling are significantly related to stroke.

Conclusions

None of the identified miRNAs were studied in stroke before. All studied miRNAs have diagnostic value for acute IS. Results show predictive significance for the risk of a second stroke. Found miRNAs and pathways have potential diagnostic, prognostic utility in neurovascular diseases.

[3010] PECULIARITIES OF DIAGNOSIS AND TREATMENT OF MYELOMA WITH SKULL BONE LESIONS ON THE EXAMPLE OF TWO CLINICAL CASES

Authors: Nataliia Kolomiets

Affiliation: Department of Neurosurgery, Bogomolets National Medical University, Kyiv, Ukraine

Trustee of the paper: PhD, assistant of the department Molotkovets V.Y.

Corresponding author: Nataliia Kolomiets (koliminata@gmail.com)

Introduction

Solitary bone plasmacytoma is a rare type of myeloma that can exclusively affect the skull, therefore, in the absence of signs of systemic myelomatosis, manifests as local brain compression

Aim of the study

The aim is to improve the diagnosis and treatment of cranial solitary plasmacytomas by describing and analyzing two clinical cases of this pathology.

Materials and methods

Clinical cases were selected from the observation cohort at the Romodanov Institute of Neurosurgery of the NAMS of Ukraine. Diagnostics was performed with the use of general clinical, neurological and ophthalmological examinations, as well as magnetic resonance imaging (MRI) and multispiral computed tomography (MSCT) of the head, osteoscintigraphy, histopathology, and a number of laboratory tests.

Results

Patient Y., 38 years old, complained of a headache, periorbital edema, and right-sided exophthalmos. The disease duration at the time of the examination was 2 months. MRI of the head showed signs of a cranioorbital tumor of the right frontal region with a heterogeneous structure, calcifications, clear uneven border, and uneven accumulation of contrast. At MSCT of the head, the tumor extended into the orbit and the upper parts of the ethmoidal labyrinth, causing defects in the frontal bone, compression, and left-sided displacement of the median brain structures. Surgery included total removal of the tumor, plastic surgery of defects in the dura mater and bones of the cranial vault. The diagnosis was confirmed histologically.

Conclusions

Obstetrics, Gynecology & Perinatology

Date: 21st April 2023, 10:00 AM

Coordinators:
Julia Sieńczyk
Natalia Rosót

[1593] Cesarean birth on patient request

Authors: Aistė Buitvidaitė

Affiliation: Faculty of Medicine, Medical Academy, Lithuanian University of Health Sciences, Kaunas, Lithuania

Trustee of the paper: Justina Kačerauskienė MD, Lithuanian University of Health Sciences, Department of Obstetrics and Gynaecology, Kaunas, Lithuania

Corresponding author: Aistė Buitvidaitė (abuitvidaite@gmail.com)

Introduction

Cesarean birth on patient request is a surgery performed in the absence of standard medical or obstetric indications due to the mother's request. Rates of cesarean delivery on maternal request (CDMR) might vary from 4 to 18 percent worldwide, but because CDMR is still not a well-recognized clinical entity there is little trust in the validity of these values. It is principal to evaluate how many women would want to request a cesarean section surgery as CDMR might contribute to the increase in cesarean section rates countrywide.

Aim of the study

To assess how many Lithuanian women would agree to an indication "maternal request" for cesarean section surgery.

Materials and methods

A questionnaire survey was conducted, which was placed on the website www.apklausa.lt from 2022 June 14th to 2022 August 31st. Only 18 – 45 years old women who were pregnant during the research period or gave birth at least once were included in the study. IBM SPSS software was used for data processing. Results with values of $p < 0.05$ were considered statistically significant.

Results

A total of 405 women answered a questionnaire. A vast majority of Lithuanian women (63,7 %) think they should be able to choose the delivery method independently. 18 – 25 and 36 – 45 years old women were more likely to agree to the ability to choose the delivery method on their own as opposed to women 26 – 35 years old, $p = 0,001$. 60,9% of respondents think that CDMR should be legalized. 18 – 25 and 36 – 45 years old women tended to agree more with the legalization of CDMR in comparison to 26 – 35 years old women, $p = 0,001$. The fundamental cause why women would request cesarean section surgery was fear of childbirth pain (51,4%). Women who agreed with the legalization of CDMR thought that society (funded by compulsory health insurance) should pay for these surgeries, $p < 0,001$. Most women who opposed the legalization of CDMR thought that women themselves should pay for these surgeries, $p < 0,001$.

Conclusions

Most Lithuanian women would want to choose the delivery method (natural or operative) independently and would agree with the legalization of "maternal request" as an indication for cesarean section surgery.

[1594] BREASTFEEDING KNOWLEDGE AND PRACTICE AMONG THE SELECTION OF LATVIAN WOMEN

Authors: Katrīna Demčenko

Affiliation: Rīga Stradiņš University (Latvia) / Faculty of Medicine, 5th year

Trustee of the paper: Asst. (acting) Olga Boka-Veide; Rīga Stradiņš University / Department of Obstetrics and Gynaecology

Corresponding author: Katrīna Demčenko (demcenkok@gmail.com)

Introduction

Breast milk provides the best nutrition for an infant, however, breastfeeding (hereafter BF) has both early and late health benefits for the mother's health. WHO recommends starting BF within the first hour after birth and continuing exclusive BF during the first 6 months, although only 44% of infants worldwide receive exclusive BF for 6 months.

Aim of the study

The present study aims to determine the number of women who BF, assess the level of knowledge, and factors associated with BF, and evaluate the early benefits of BF on mothers' postpartum period.

Materials and methods

Data were obtained through a self-made questionnaire aimed at Latvian women, who gave birth from 2017 to 2022. The questionnaire consisted of 4 sections – basic information, information about pregnancy/childbirth, BF, and the woman's awareness of BF. As a result, 854 responses were collected. Qualitative data were described as counts and percentages. Data were analysed using quantitative methods – Pearson's chi-squared test; Fisher's exact test. Organized in MS Excel, and analysed using IBM SPSS Statistics 28.0 program.

Results

The respondents were divided into 2 groups – BF 817 (95,7%) and non-BF 37 (4,3%). Out of BF respondents, 468 (54,8%) exclusively BF for ≥ 6 months. The most common reason for not BF was insufficient milk supply (32,4%).

67,8% of BF and 40,5% of non-BF women rated their knowledge of BF as sufficient. There is a statistically significant association between BF and adequate awareness ($p < 0,001$). 33,6% of respondents referred to medical personnel as a source of information. 60,1% of BF mothers attended childbirth preparation classes and only 32,4% of non-BF. Thus, there is a significant association between BF and attending preparation courses ($p < 0,001$). 35,1% of non-BF respondents sought help from a lactation consultant.

The most frequently noted advantages of BF for the mother were convenience and financial benefits; emotional and physical bond with the child; better recovery after birth; weight loss. In addition, BF women had fewer postpartum complications compared to non-BF.

Conclusions

Mothers' awareness of the positive effects of BF on a child's health is one of the main factors that increase the number of BF women. On the other hand, women who lack knowledge of BF are more likely to not initiate or stop BF sooner.

To underline the importance of BF, public education and the involvement of specialists should be promoted to provide the best support to mothers in solving BF-related problems.

[1709] Why women choose to pursue labiaplasty

Authors: Rasa Dalibagaitė, Emilija Dedelytė, Snieguolė Martinkienė

Affiliation: Faculty of Medicine, Medical Academy, Lithuanian University of Health Sciences, Kaunas, Lithuania

Trustee of the paper: Snieguolė Martinkienė

Corresponding author: Rasa Dalibagaitė (dalibagaite@gmail.com)

Introduction

Labiaplasty is a cosmetic genital surgery that reduces excess labia. The demand for labiaplasty procedures has been significantly increasing during the recent years. There is a present assumption that the main influencing factor to request the surgery is genital aesthetics, however there is insufficient information about the other motivators.

Aim of the study

The study was conducted in order to explore womens' decision to undergo labiaplasty, to assess whether functional or esthetic factors were the main motivators to pursue surgery and to evaluate relation with body self-image.

Materials and methods

The study group consisted of 40 women who underwent labiaplasty surgery in 2022. Data was collected through a questionnaire form consisting of 18 questions. The survey included demographic information, symptoms and complaints before and after surgery, body dysmorphia related questions and outcome satisfaction.

Results

The vast majority of patients (97,5 %) claimed they felt functional discomfort before surgery, most commonly discomfort during physical excersize and sexual intercourse, 67,5% and 50 % respectively. Only 5% of respondents were happy with labial appearance before surgery. There wasn't a correlation between the importance of either aesthetic or functional factors and age ($p=0.219$). Womens' sexual partners did not have any significant influence on making the decision. The results indicate that 20% of the women had body dysmorphic disorder symptoms and this respondent group had significantly more plastic surgeries of other kind (56%) and cosmetic procedures (89%) ($p<0.001$). 95% of women were satisfied with the surgery outcome. 10% of women still feel discomfort during physical activity and 12,5% were unhappy with labial appearance postoperatively.

Conclusions

The decision to seek genital plastic surgery has a significant incidence rate of both functional and appearance related reasons. High postoperative outcome satisfaction indicates that labiaplasty has a significant positive effect on symptoms of discomfort and labial appearance perception.

[1745] CURRENT OPINION OF POLISH WOMEN ABOUT THE OPTIMUM MODE OF DELIVERY AND SHARED-DECISION MAKING

Authors: Anna Różańska-Wałędziak MD, PhD¹, Marek Misiak², Małgorzata Wyszomirska², Maciej Wałędziak MD, PhD³

Affiliation: 1 Department of Human Physiology and Pathophysiology, Faculty of Medicine, Collegium Medicum, Cardinal Stefan Wyszyński University in Warsaw; aniaroza@tlen.pl (A.R.-W.)

Trustee of the paper: Anna Różańska-Wałędziak MD, PhD¹ aniaroza@tlen.pl

Corresponding author: Marek Misiak (misiak.m2022@gmail.com)

Introduction

The rate of cesarean sections (CS) has dramatically increased over the last decade, both worldwide and in Poland.

Aim of the study

Our aim was to assess the factors influencing women's preference for the mode of the delivery.

Materials and methods

The study was designed as an online survey that included questions about women's knowledge, opinion and preference for different modes of delivery and the decision-making. Data was collected in 2020 from 1033 women.

Results

56.0% of women declared CS as their preferred mode of delivery. 34.9% thought that choosing the mode of delivery should be their autonomic decision, 44.4% preferred decision-sharing with their obstetrician and 19.4% thought that CS should be performed for medical indications only. A significant increase of proportion of women who preferred vaginal delivery (VD) was in correlation with the educational level, with the lowest rate in the group with primary education - 33.3% and highest in the group with medical education - 69.3% ($p < 0.05$). A history of VD significantly reduced the preference for having a CS - only 8.9% compared to 56.0% of the total group of respondents ($p < 0.05$). No significant correlation was found between a history of delivery and the preference for the decision-making process or acceptance of paid cesarean delivery on maternal request.

Conclusions

As we observed a significantly lower rate of women who preferred CS after VD, lack of proper knowledge about the course of VD and its advantages for the mother and the child may be the main reason for the increasing trend for cesarean deliveries. Patient's preference and conception about the delivery should always be discussed with their obstetrician and education implemented, as adequate education about advantages and disadvantages of different modes of delivery might allow to reduce the augmented rate of CS.

[1803] „Annexin A2 in plasma and peritoneal fluid of women with endometriosis”

Authors: Michał Zygarowicz

Affiliation: Department of Obstetrics, Gynecology and Gynecological Oncology, Medical University of Warsaw, Poland

Trustee of the paper: Prof. Piotr Ludański MD, PhD

Corresponding author: Michał Zygarowicz (m.zygarowicz@o2.pl)

Introduction

Endometriosis is an inflammatory-related reproductive age disease characterized by the presence of endometrial cells outside the uterine cavity. Current laboratory practice does not provide specific markers for detecting and assessing the advancement of endometriosis in either plasma or peritoneal fluid. The severity of disease is assessed by stages from I to IV. The protein annexin A2 (ANXA2) has been reported to be associated with inflammatory processes, so it may also be elevated in women with endometriosis and play a role in its pathogenesis.

Aim of the study

The study aimed to investigate and compare ANXA2 protein concentration in plasma and peritoneal fluid in a group of women with endometriosis compared to controls.

Materials and methods

The ANXA2 study was carried out by the ELISA method using funds from the student "mini-grant" of the Medical University of Warsaw (project number 46/M/MG/N/21). Samples were collected during laparoscopy from 53 women with and 40 women without endometriosis. The patients were grouped by endometriosis stage and infertility status, and then compared between groups using statistical tests.

Results

Women with endometriosis had significantly elevated plasma ANXA2 levels compared to women without endometriosis ($p=0.01$). There was no such difference in the peritoneal fluid samples ($p=0.06$). Plasma concentrations in patients with stage III and IV endometriosis were significantly different compared to patients without endometriosis ($p=0.03$). There was no such difference observed in plasma when comparing stages I, II vs III and IV, and stages I, II vs controls ($p=0.72$ and $p=0.12$, respectively). In addition, there were no significant differences in the peritoneal fluid concentrations in the group comparisons mentioned above ($p=0.07$, $p=0.35$, and $p=0.32$, respectively). Comparison of samples for patients with or without infertility, primary or secondary infertility, endometriosis with or without infertility, and non-endometriosis with or without infertility showed neither significant differences in the plasma nor in the peritoneal fluid.

Conclusions

ANXA2 can possibly be involved in the pathogenesis of endometriosis especially in advanced stages but, due to the rather limited group of tested samples, further studies are needed to confirm its role.

[1850] Evaluation of the clinical examination in the determination of early-stage cervical cancer.

Authors: Ewelina Bornio, Karolina Karoń, Natalia Szmigielska, Krzysztof Piątkowski

Affiliation: Kazimierz Pułaski University of Technology and Humanities in Radom

Trustee of the paper: Szymon Piątek, M.D. Ph.D

Corresponding author: Ewelina Elżbieta Bornio (efelajna66@gmail.com)

Introduction

Advanced cervical cancer requires radiochemotherapy as the only effective treatment, while surgery is preferred in early disease. However, in some cases postoperative histopathology reveals parametrial involvement, lymph node metastasis, or non-radical surgical margins, which are indications for adjuvant radiotherapy. Consequently, these patients receive two treatments (surgery + radiotherapy), which significantly increases the risk of serious side effects (e.g., ureterovaginal and bowel-vaginal fistulas). This leads to a reduced quality of life. Therefore, determining clinical staging is crucial in choosing the appropriate therapeutic management.

Aim of the study

The aim is to assess the accuracy of the clinical examination concerning histopathology in the determination of stage cervical cancer.

Materials and methods

This retrospective study includes a group of patients who underwent surgery for cervical cancer at the Maria Skłodowska-Curie National Research Institute of Oncology in Warsaw between 2010 and 2022. Preoperative FIGO 2018 staging was compared to histopathological report after the surgery. Patients were classified into 3 groups based on the degree of discrepancy (correctly staged, under-staged and over-staged). The chi-squared test was performed to assess statistical significance.

Results

90 eligible patients were included. 77 patients were diagnosed with squamous cell cervical cancer and 13 patients with adenocarcinoma cervical cancer. Of all patients included in the study, 23 (25.6%) were correctly staged, 24 (26.7%) were clinically over-staged, and 43 (47.8%) were clinically under-staged. Angioinvasion occurred with higher frequency in under-staged patients than among those who were accurately or clinically over-staged (58.1% vs. 26.1% vs. 16.7%), as did the presence of lymph node metastases (32.6% vs. 13.0% vs. 16.7%). The difference was statistically significant for both parameters ($P < 0.01$).

Conclusions

A significant difference has been found between clinical staging and histopathological findings in early-stage cervical cancer. As clinical assessment is insufficient, imaging studies (MRI, PET CT) should be performed to properly determine the stage of the disease.

[1857] **Obstetric outcomes after gestational choriocarcinoma: single center study.**

Authors: Natalia Szmigielska, Karolina Karoń, Ewelina Bornio, Krzysztof Piątkowski

Affiliation: Kazimierz Pułaski University of Technology and Humanities in Radom

Trustee of the paper: Szymon Piątek, M.D. Ph.D

Corresponding author: Natalia Izabela Szmigielska (natalas20@gmail.com)

Introduction

Gestational choriocarcinoma (GC) occurs extremely rare with an incidence of 1 in 40,000 pregnancies in Europe. It has an unfavorable prognosis and requires aggressive treatment. Management of GC mainly is based on multidrug chemotherapy, however, some patients also need a hysterectomy. Although survival is the primary goal, fertility remains an issue for patients, who achieved complete remission.

Aim of the study

This study aims to evaluate obstetric outcomes in patients after the treatment of choriocarcinoma.

Materials and methods

This retrospective study included patients treated in the Department of Gynecologic Oncology at the Maria Skłodowska-Curie National Institute of Oncology in Warsaw between 2000 and 2020. All patients underwent chemotherapy. Eligibility criteria for the study were: age < 40 years, diagnosis of choriocarcinoma, and systemic treatment with chemotherapy. Patients after the hysterectomy were excluded. Factors analyzed that may affect fertility include age, having children before the disease, number of all abdominal surgeries, chemotherapy regimen, number of chemotherapy courses, age of first menstruation, FIGO score, and staging.

Results

18 patients met the eligibility criteria for the study. The median age was 30 (24-39) years old. Multidrug chemotherapy was administered in 11 patients, and methotrexate in 7 patients. 4 patients successfully became pregnant and gave birth, for a total of 6 children. One patient died due to disease progression. The median follow-up time after treatment was 59 months, and the average was 68 months.

Conclusions

Treatment of GC is complex and impairs patients' fertility. Despite the gonadotoxicity of chemotherapy used in GC management, childbearing is possible. Decisions about hysterectomies should be discussed with patients case by case.

[1928] Exploring the Clinical Profile of Endometrial Cancer Patients Treated Amidst the COVID-19 Pandemic.

Authors: Karolina Karoń, Natalia Szmigielska, Ewelina Bornio, Krzysztof Piątkowski

Affiliation: Kazimierz Pułaski University of Technology and Humanities in Radom

Trustee of the paper: Szymon Piątek, M.D. Ph.D

Corresponding author: Krzysztof Piątkowski (krzysztof.piatkowski98@gmail.com)

Introduction

The COVID-19 pandemic has had a profound impact on healthcare systems worldwide, causing delays in cancer diagnosis and treatment. In Poland, the pandemic has led to a significant decrease in the number of newly diagnosed cancer cases. However, endometrial cancer remains the most common gynecological malignancy diagnosed in women.

Aim of the study

This study aims to characterize the group of patients treated for endometrial cancer during the COVID-19 pandemic at Maria Skłodowska-Curie National Institute of Oncology and compare it to the pre-pandemic data.

Materials and methods

The study analyzed data from a database of 180 patients treated for endometrial cancer between 2020 and 2022 at Maria Skłodowska-Curie National Institute of Oncology. All patients underwent surgical treatment and adjuvant therapy if needed. The data collected included the patient's age, comorbidities, and pathological assessment (tumor histology, grading, staging, and angioinvasion). Survival analysis was performed using Kaplan-Meier curves.

Results

The mean age was 64,7 (26 - 89) and the mean BMI was 29.5 (17.6 - 53.5). Endometrioid histology was found in 163 (90.55%), serous in 5 patients (2.77%) Tumors intermediate grade (G2) was found to be the most common by 83 (46.11%), followed by 42 (23.33%) patients classified as G1 and 41 (22.77%) patients classified as G3.

Staging according to FIGO classification was: IA (47.22%), II (21.11%), IB (17.78%), IIIB (5%), IIIA and IVB (3.33%), IIIC (1.11%). Adjuvant brachytherapy was administered in 49 patients, external beam radiotherapy in 37, and teletherapy in 13 patients. The mean follow-up was 327.88 days (20 - 2779).

Conclusions

During the COVID-19 pandemic, the most commonly diagnosed type of endometrial cancer was FIGO IA, G2, which had a favorable prognosis. Advanced endometrial cancers constitute the minority (staging III and IV). Longer follow-up is needed to observe changes in patients' survival.

Oncology & Hematology

Date: 21st April 2023, 15:00 PM

Coordinators:
Mateusz Ziomek
Michał Cholewiński

Sponsor:

Novartis



[1586] The role of the sentinel lymph node biopsy in melanoma patients: A retrospective single center analysis

Authors: Maiboroda Natalja, Eglītis Jānis, Rubins Silvestrs, Zavorins Aleksejs

Affiliation: Faculty of Medicine, University of Latvia, Riga, Latvia Riga East University Hospital, Latvian Oncology Center, Riga, Latvia University of Latvia, Department of Dermatology and Venereology, Riga, Latvia

Trustee of the paper: Jānis Eglītis

Corresponding author: Natalja Maiboroda (natalja-maiboroda@inbox.lv)

Introduction

Sentinel lymph node biopsy (SLNB) is a sensitive, minimally invasive operative method for lymph node evaluation and staging in patients with melanoma without clinical and radiological lymph node findings. Precise SLNB identification is crucial for accurate diagnosis of micro-metastasis at an early stage of melanoma progression and treatment initiation.

Aim of the study

A retrospective single center study was performed to compare and analyze the patients who have undergone sentinel lymph node biopsy vs observation.

Materials and methods

The retrospective study was conducted at the Latvian Oncology Center. 134 patients with histologically confirmed melanoma in the 2015, were involved in the study. Patient data: diagnosis, age, sex, histological parameters, stage, treatment tactics, disease progression were collected. A Kaplan-Meier analysis was performed to compare patients who have undergone SLNB vs observation. The observation time was 7 years. Progression-free survival curves were created by R-studio program.

Results

Patients who have undergone SLNB had shown improving progression-free survival comparing to an observational group. The significance given by Fisher's test is $P=0,05$, which is on the edge. There was 22% (N=30) of patients who have undergone SLNB and 78% (N=104) patients who have undergone observation only. In SLNB group there was 7% (N=2) SLNB of metastases positive patients and 93 % (N=28) metastases negative patients. There were 11 % (N=11) of patients who didn't undergo SLNB due to technical reasons.

Conclusions

Data analyses revealed that in necessary cases SLNB was not taken accordingly to NCCN recommendations and there may be several reasons for that. In Latvia Pembrolizumab was included in the list of compensable medications only from 2018 and we suppose that there was no need to perform SLNB, because the treatment was not available. That is why SLNB plays crucial role in cases without clinical and radiological lymph node findings in melanoma patients, therefore we recommend SLNB in this group for making alterations to disease staging and change of treatment strategy. Another possible reason is that Latvian Oncology center's dermato-oncology unit got established in 2019 only.

[1587] The importance of histopathological reporting in melanoma patients.

Authors: Maiboroda Natalja , Eglītis Jānis, Rubins Silvestrs

Affiliation: Faculty of Medicine, University of Latvia, Riga, Latvia Riga East University Hospital, Latvian Oncology Center, Riga, Latvia University of Latvia, Department of Dermatology and Venereology, Riga, Latvia

Trustee of the paper: Jānis Eglītis

Corresponding author: Natalja Maiboroda (natalja-maiboroda@inbox.lv)

Introduction

NCCN and CAP guideline principles of pathology include recommendations about the essential and additionally recommended parameters, that should be reported to the histological protocol. The reporting of additional parameters can play a crucial role in melanoma patient staging and treatment tactics.

Aim of the study

To determine the percentage of patients having no complete histological information with minimally recommended parameters and to analyze the description frequency of each additional parameter.

Materials and methods

134 histopathological reports of year 2015 were analyzed during one center retrospective study. The following patient data was collected: diagnosis, age, sex, stage, Breslow thickness, Clark level, ulceration, mitotic rate, margin status, location, lymphovascular and perineural invasion, regression, tumor-infiltrating lymphocytes (TIL), vertical growth phase (VGP), histologic subtype, desmoplasia, disease progression. This data was analyzed with descriptive statistics method using R-studio software.

Results

Complete histological information with minimally recommended parameters was not found in 5% (N=7) of investigated patients. In seven cases the ulceration was not described. The most frequent additionally recommended parameter of histological protocol was location of melanoma found in 99 % (N=133) of patients. While, tumor mitotic rate was described in 32% (N=43), lymphovascular and perineural invasion in 45% (N=60), tumor-infiltrating lymphocytes (TIL) 56% (N=75), cutaneous melanoma subtype 43% (N=57), cell type 78% (N=104) and desmoplasia 2% (N=3). Regression and vertical growth phase (VGP) have not been described in any case.

Conclusions

A correct melanoma staging and change of treatment strategy depend on complete and properly performed histopathological protocol and that is why we want to emphasize the importance of additionally recommended parameters. Lymphovascular and perineural invasion, tumor mitotic rate, regression can play crucial role for making a decision about sentinel lymph node biopsy in thin (<1 mm) melanoma cases.

[1684] Evaluating the effectiveness of nivolumab neoadjuvant treatment in patients with locally advanced melanoma

Authors: Anna Terlecka

Affiliation: Students' Scientific Group of Multidisciplinary Oncology 'Onkosfera', Department of Soft Tissue/Bone Sarcoma and Melanoma, Maria Skłodowska-Curie National Research Institute of Oncology in Warsaw

Trustee of the paper: Prof. Anna M. Czarnecka MD PhD, Krzysztof Ostaszewski MD, Prof. Piotr Rutkowski MD PhD

Corresponding author: Anna Magdalena Terlecka (amterlecka@gmail.com)

Introduction

The role of neoadjuvant treatment in locally advanced melanoma is becoming increasingly notable. Phase II trials' results from the past four years demonstrate that preoperative immunotherapy with anti-PD-1 agents, such as nivolumab, or with BRAF/MEK inhibitors (when BRAF mutation is present), facilitate obtaining an objective response in a considerable number of patients and likely prolong their overall survival. However, large scale phase III/IV trials and real-world data are yet to be published to further ratify the use of neoadjuvant immunotherapy as a viable treatment option.

Aim of the study

The study aims to assess the effectiveness of neoadjuvant treatment with nivolumab in patients with locally advanced melanoma.

Materials and methods

Patients who underwent nivolumab neoadjuvant treatment (starting between 2016-08-16 and 2021-08-05) and subsequent surgery were enrolled into analysis. Preoperative treatment was administered for at least 8 weeks and diagnostic imaging was performed every 3 months.

Results

20 patients (median age 64 years, 6 BRAF V600 mutated) with locally advanced melanoma received nivolumab. R0 resections were achieved in 70% of the patients, and 90% of the patients had no remaining tumour in the operated area, as confirmed radiologically. Among the 3 patients with R1 resection, local recurrence occurred in only one of them; however, the remaining 2 patients progressed into metastatic disease. The 1-year OS rate was 95%, and the 2-year OS rate was 85%, with the PFS of respectively 75% and 53%. The prevalence of complications in the perioperative period was minor, as only one patient experienced delayed wound healing.

Conclusions

In routine clinical practice, when treating patients with locally advanced melanoma, it is crucial to refer them to reference centres to include them in prospective neoadjuvant clinical trials.

[1737] Salvage re-irradiation in non-melanoma skin cancers: preliminary results

Authors: Maria Stec, Agata Suleja, Szymon Sobel, Aleksandra Nasiek, Konrad Kaminiow

Affiliation: Śląski Uniwersytet Medyczny w Katowicach; Narodowy Instytut Onkologii im. Marii Skłodowskiej-Curie, Państwowy Instytut Badawczy, Oddział w Gliwicach

Trustee of the paper: Marcin Miszczyk, MD PhD

Corresponding author: Maria Stec (mariaannastec@gmail.com)

Introduction

Non-melanoma skin cancers (nMSC), comprising of basal cell carcinoma (BCC) and squamous cell carcinoma (SCC), are the most common skin malignancies. The treatment is usually surgical, but radiotherapy (RT) presents an alternative in some patients. However, there is almost no data on the outcomes of re-irradiation in the case of post-RT recurrences.

Aim of the study

To estimate the local control and safety of salvage re-irradiation in radio-recurrent nMSC.

Materials and methods

We included patients treated with high-dose-rate brachytherapy (HDR-BT) at a tertiary institution between 2016 and 2022 for BCC or SCC recurrence following primary definitive RT. Patients treated with palliative intent were excluded from the analysis. The treatment toxicity was assessed using CTCAE v5.0. Kaplan-Meier method was used to estimate local control (LC).

Results

The study included 31 patients at a median age of 77,7 years (IQR 67,8-86,3), and median follow-up of 20,4 months (IQR 8-38,8) treated with salvage HDR BT to a median dose of 45 Gy in 9 fraction doses. 87,1% of the lesions were BCC, 3,2% were SCC and 9,7% were other nMSC types. 38,7% of patients were primarily treated with surgery. The lesions were in majority located in the nasal area (38,7%) and the median dimension was 20 mm (IQR 15-30). The median period between 1 RT and re-RT was 16,46 months (IQR 12-23).

LC was maintained in 70% of patients within 1 year, in 45% within 2 years and in 22% within 3 years. There were 6,4% G3+ adverse events and 16,12% G1 reactions - mainly telangiectasias. Other adverse effects were facial pain, ear pain, skin ulceration and impaired hearing.

Conclusions

Salvage RT is associated with a low rate of G3+ adverse effects, but there are numerous local recurrences, and therefore should only be considered as patient-tailored compassionate treatment in selected cases. However more data and further studies are needed.

[1759] **The efficacy of rechallenge with BRAF-targeted therapy in metastatic melanoma**

Authors: Iga Płachta, Paweł Rogala, Aneta Borkowska, Krzysztof Ostaszewski, Anna Czarnecka

Affiliation: Medical University of Warsaw; Department of Soft Tissue/Bone Sarcoma and Melanoma, Maria Skłodowska-Curie National Research Institute of Oncology in Warsaw

Trustee of the paper: Prof. Anna Czarnecka MD, PhD

Corresponding author: Iga Płachta (iplachta@outlook.com)

Introduction

The prognosis of BRAF-mutant advanced melanoma has improved significantly following the introduction of molecularly targeted therapy. Nevertheless, the majority of the patients treated with BRAF and MEK inhibitors (BRAFi and MEKi) experience a disease progression due to acquired resistance. However, some evidence suggests that the re-sensitization to BRAFi/MEKi may be possible after drug discontinuation and therefore the rechallenge with targeted therapy could be effective.

Aim of the study

The retrospective assessment of the outcomes for patients retreated with BRAF-directed therapy (BRAFi or BRAFi+MEKi).

Materials and methods

The retrospective analysis included clinical data of patients treated between 2012 and 2022 in the Maria Skłodowska-Curie National Research Institute of Oncology in Warsaw, who progressed on BRAFi-based therapy and, after the immune checkpoint inhibitors treatment, were rechallenged with BRAFi±MEKi. Overall survival rate (OSR), progression-free survival (PFS), overall response rate (ORR), disease-control rate (DCR) and treatment duration for overall treatment (three lines) and rechallenge treatment (third line) were calculated.

Results

Forty-four patients (21 females, 23 males), with median age of 50 years (range: 20-81) were enrolled into study. Most patients were treated primarily with BRAFi+MEKi combination and nine patients (20.5%) with only BRAFi, whereas only one patient (2.3%) received single-agent BRAFi treatment as rechallenge therapy. Median duration of treatment was 14.8 months for first BRAFi±MEKi treatment and median time from first-line regimen cessation to rechallenge was 9.1 months. For almost all patients (43 of 44, 97.7%), first-line treatment was discontinued due to disease progression. One-year and two-year OSR from the start of the first-line treatment and from rechallenge BRAFi±MEKi therapy were 93.2% and 43.2%, and 70.5% and 19.8%, respectively, whereas one-year PFS rate were 45.5% and 29.5%, respectively. A response rate to treatment was higher for the first-line BRAFi±MEKi treatment as compared with the BRAFi±MEKi rechallenge, ORR were 34.1% and 11.4%, respectively; DCR were 86.4% and 56.8%, respectively.

Conclusions

Rechallenge with BRAFi±MEKi provides clinically significant benefit and should be considered for selected patients.

[1790] Toxicity of anti-PD 1 as first-line treatment in patients with advanced melanoma.

Authors: Magdalena Zielińska, Piotr Błoński, Krzysztof Ostaszewski, Anna M. Czarnecka

Affiliation: Students' Scientific Group of Multidisciplinary Oncology 'Onkosfera', Department of Soft Tissue/Bone Sarcoma and Melanoma, Maria Skłodowska-Curie National Research Institute of Oncology in Warsaw

Trustee of the paper: Dr Krzysztof Ostaszewski, prof. dr hab. n. med. Anna M. Czarnecka, prof. dr hab. n. med. Piotr Rutkowski, Head of Department of Soft Tissue/Bone Sarcoma and Melanoma

Corresponding author: Magdalena Zielińska (magda.zielinska20@gmail.com)

Introduction

Immune checkpoint inhibitors such as anti-PD-1 agents: nivolumab and pembrolizumab were approved by EMA and FDA in 2015. They have revolutionized the management of many cancers and significantly improved survival outcomes, particularly in patients with advanced melanomas. However, these therapies may induce immune-related adverse events (irAEs) affecting various organs.

Aim of the study

The study aimed to determine the occurrence of specific adverse effects and how frequently they result in termination of therapy or death in patients with advanced melanoma treated with either pembrolizumab or nivolumab as a first-line treatment.

Materials and methods

The data was collected by analyzing medical documentation of patients treated with anti-PD 1 agents, between July 2016 and February 2023, at the Maria Skłodowska-Curie National Research Institute of Oncology in Warsaw. We evaluated the severity of each adverse event using Common Terminology Criteria for Adverse Events (CTCAE) version 5.0.

Results

328 patients (173 males, 155 females) with a median age of 55 at the start of therapy were included. 170 (51.8%) patients were treated with pembrolizumab and 158 (48.2%) with nivolumab. 280 (85.4%) patients had at least one adverse event. The most frequent were irAEs affecting the endocrine system. Thyroid toxicity occurred in 147 (44.8%) patients and 2 patients experienced pituitary toxicity. Hepatotoxicity was the second most common irAE, affecting 135 (41.2%) patients, followed by the toxicity of the skin (23.8%), lungs (15.2%), pancreas (9.5%) and colon (9.5%). Rheumatic, cardiac and allergic complications were much less frequent. 53 (16.2%) patients experienced grade 3 or 4 irAEs and 4 experienced grade 5 toxicity resulting in death. The toxicity resulted in the termination of the therapy in 47 (14.3%) patients with pneumonitis being the most frequent cause (27.7%), followed by colitis (23.4%) and hepatotoxicity (17%). Cardiotoxicity led to treatment termination in 7 patients (14.9%), resulting in death in 2 of them. Thrombocytopenia (2 patients), skin toxicity (2), neurotoxicity (2) and immune-related gastritis (1) led to termination less frequently. Other immunotherapy-related deaths occurred due to renal toxicity (1 death) and neurotoxicity (1 death).

Conclusions

Although effective in the treatment of advanced melanoma, pembrolizumab and nivolumab may result in serious adverse events that can even lead to death. Regular assessments should be performed, particularly evaluating the thyroid, liver, skin and lungs.

[1791] A rare case of FPI melanoma with cardiac metastasis- difficulty in diagnosing antemortem. A case report.

Authors: Magdalena Zielińska

Affiliation: Students' Scientific Group of Multidisciplinary Oncology 'Onkosfera', Department of Soft Tissue/Bone Sarcoma and Melanoma, Maria Skłodowska-Curie National Research Institute of Oncology in Warsaw

Trustee of the paper: Dr Krzysztof Ostaszewski, prof. dr hab. n. med. Anna M. Czarnecka, prof. dr hab. n. med. Piotr Rutkowski, Head of Department of Soft Tissue/Bone Sarcoma and Melanoma

Corresponding author: Magdalena Zielińska (magda.zielinska20@gmail.com)

Background

Melanoma is a highly aggressive cancer with a predilection for early metastasis that can occur even from thin, primary tumors. Evidence suggests that most frequently diagnosed metastases occur in the skin, lung, brain, liver, bone and intestine. Cardiac metastases are rare and most often diagnosed postmortem due to the lack of symptoms in majority of patients. Diagnosing melanoma by first identifying a cardiac metastasis is even more rare, causing difficulty in distinguishing from more common malignant cardiac tumors such as myxomas and sarcomas.

Case Report

A 66-year-old woman reported chest pain and deterioration in exercise capacity resulting in the discovery of 50 mm left ventricular tumor, which was then resected. Initial histopathological analysis suggested sarcoma synoviale as diagnosis. 2 weeks later PET CT confirmed 20 mm local recurrence, without metastases to other tissues, not eligible for reoperation. Extended histopathological testing excluded initial diagnosis as well as the following possibilities: intimal sarcoma, sarcoma synoviale, clear cell sarcoma and myoepithelial carcinoma. Melanoma BRAF (-) metastasis and high grade malignant peripheral nerve sheath tumours (MPNST) were considered as likely diagnoses, impossible to clearly distinguish between with suggestion of melanoma. Decision to start treatment based on the diagnosis of melanoma of unknown primary was made after multidisciplinary team (MDT) consultation. Treatment with pembrolizumab 200 mg every 3 weeks was started and after 3 cycles, complete remission (CR) of the lesion in the heart was achieved. The remission persisted, after 27 cycles of pembrolizumab, with pauses due to grade 2 toxicities affecting skin, liver, pancreas and lungs, patient started "treatment holiday". The last CT scan was performed more than 13 months after starting "treatment holiday" and it showed no signs of progression. The patient is currently awaiting another follow-up visit (as of February 28, 2023).

Conclusions

Clinicians should be aware of to the possibility of cardiac metastasis in patients with both diagnosed and unknown primary melanomas. Due to diagnostic difficulties and rare occurrence of cardiac metastases of melanoma, treatment decisions should be made during multidisciplinary team (MDT) meetings.

[1805] Palliative management of melanoma

Authors: Michał Zygarowicz

Affiliation: Students' Scientific Group of Multidisciplinary Oncology 'Onkosfera', Department of Soft Tissue/Bone Sarcoma and Melanoma, Maria Skłodowska-Curie National Research Institute of Oncology in Warsaw

Trustee of the paper: Prof. Anna Czarnecka MD, PhD

Corresponding author: Michał Zygarowicz (m.zygarowicz@o2.pl)

Background

Melanoma is a skin cancer originating from melanocytes and usually treated primarily by surgical excision. Even after long periods of complete remission, metastases are relatively common and seemingly independent from the characteristics of primary lesion. In patients with surgically resected high-risk stage melanoma, palliative immunotherapy (e.g. pembrolizumab) is one of the best therapeutic strategies. In some cases, however, the aforementioned therapy results in adverse effects, such as immunological disorders, which determine the course of further therapy.

Case report

The 47 year old patient was originally diagnosed 3rd July 2006 with skin melanoma localized on the right shin. The lesion, infiltrating the skin for approximately 2 millimeters, was surgically excised. A biopsy of relevant sentinel lymph nodes revealed no metastases. After 11 years of complete remission, a local relapse was diagnosed, with distant metastases also being suspected. The patient's condition subsequently worsened over the course of the following months, with "in transit" metastases, treated with regional chemotherapy. Thereafter, the patient was qualified for treatment with pembrolizumab, which allowed for inhibition of the disease progression for 24 courses of 200 or 400 mg pembrolizumab. In spite of this initial therapeutic success, treatment had to be discontinued 21st August 2021 due to adverse effects, namely colitis, and haemorrhage. Afterward electrochemotherapy was administered on 28th October 2021, and Encorafenib combined with Binimetinib therapy from 23rd June 2022 which is continued until today with partial remission.

Conclusions

Even after a long period of remission, complete recovery in melanoma remains unsure. Therefore, it is of utmost importance to diagnose the primary cancer as early as possible what may allow for durable or long-term control. This particular patient's case shows that 11 years of supposed full recovery does not guarantee the full and unequivocal success of the treatment and underlines the importance of regular dermoscopy as a primary opportunity for an early diagnosis.

[1841] Lynch Syndrome screening among patients with endometrial cancer: a single center study.

Authors: Karolina Karoń, Natalia Szmigielska, Ewelina Bornio, Krzysztof Piątekowski

Affiliation: Kazimierz Pułaski University of Technology and Humanities in Radom

Trustee of the paper: Szymon Piątek, M.D. Ph.D

Corresponding author: Karolina Anna Karoń (kkaron045@gmail.com)

Introduction

Lynch syndrome is an inherited condition caused by mutations in DNA mismatch repair (MMR) genes, which increases the risk of developing various types of cancer, including endometrial cancer. The prevalence of Lynch syndrome varies among different populations, but it is estimated to be around 1-3% in individuals with colorectal cancer. Early identification of individuals with Lynch syndrome is crucial for cancer prevention and management.

Aim of the study

This study aims to evaluate the prevalence of MMR gene mutations among patients with endometrial cancer as screening for Lynch syndrome.

Materials and methods

Retrospective analysis of 120 patients with endometrial cancer treated at the Maria Skłodowska-Curie National Research Institute of Oncology in Warsaw between July 2020 to December 2022 was done. All patients underwent hysterectomy with bilateral salpingo-oophorectomy. The immunohistochemical expression of MMR proteins (MLH1, MSH2, MSH6, and PMS2) was assessed in the tumor tissue sample in patients with endometrioid endometrial cancer. Clinical (BMI, age, comorbidities, family history of cancer incidence) and pathological (grading, staging, LVSI, myometrial invasion, tumor size, lymph nodes involvement) data were analysed in relation to MMR expression.

Results

We found that 37.5% (45/120) of patients had mutations in one or more of the MMR genes. Of those with mutations, 80% (36/45) had mutations in PMS2 and MLH1, 6.7% (3/45) had mutations only in MLH1, 6.7% (3/45) had mutations in MSH6, 4.4% (2/45) had mutations in MSH2 and MSH6, and 2.2% (1/45) had mutations in PMS2, MSH6 and MLH1. The remaining 77 patients (64.2%) did not have any mutations. Among the patients with MMR mutations, 5 (11.1%) had a possible family history of Lynch-associated cancers.

Conclusions

One third of patients diagnosed with endometrial cancer had alterations in MMR proteins and needed genetic counseling. Each one of this patient may had higher risk of developing the Lynch syndrome and other malignancies. Early identification of individuals with Lynch may help in early diagnosis of colorectal cancer. Moreover, it improves management strategies for families and children of these patients. Screening for Lynch syndrome is reasonable and should be considered in patients with endometrial cancer.

[1961] Systemic therapy outcomes in patients with advanced melanoma: a real-world study

Authors: Piotr Błoński, Magdalena Zielińska, Gustaw Laskowski, Krzysztof Ostaszewski

Affiliation: Students' Scientific Group of Multidisciplinary Oncology 'Onkosfera', Department of Soft Tissue/Bone Sarcoma and Melanoma, Maria Skłodowska-Curie National Research Institute of Oncology in Warsaw

Trustee of the paper: prof. Anna Czarnecka MD, PhD, Dsc; prof. Piotr Rutkowski MD, PhD, Dsc

Corresponding author: Piotr Jan Błoński (pb.pol1560@gmail.com)

Introduction

The real-world data are valuable sources of information, especially about groups of patients who are rarely enrolled in clinical trials due to more advanced disease or poorer performance than acceptable within a trial.

Aim of the study

The study was conducted to evaluate the effectiveness of systemic therapies preferable in routine clinical practice for patients with advanced melanoma, especially for those underrepresented in clinical trials.

Materials and methods

In this study electronic medical records were retrospectively reviewed and a total number of 593 patients met the inclusion criteria. Patients treated for advanced cutaneous or mucosal melanoma, who started their treatment between October 2015 and December 2021, were enrolled. The follow-up is ongoing and the last revision took place on the 25th February 2023. The first-line treatment of all patients was: Anti-PD-1 immunotherapy (nivolumab or pembrolizumab) or BRAF/MEK inhibitors. Patients receiving adjuvant therapy, enrolled in clinical trials or previously treated with other systemic therapies were excluded from the analysis. Data analysis was performed with Kaplan-Meier estimator, log-rank test and Cox proportional hazards regression model.

Results

Out of 593 patients, 315 (53%) had BRAF-positive mutational status. Within this group 77 (24% of BRAF-positive) patients were treated with first-line Anti-PD-1 immunotherapy and their median overall survival was 26.4 months. The other 238 (76%) BRAF-positive patients started their systemic treatment with BRAF/MEK inhibitors and in this subgroup median overall survival was 12.4 months. For the entire group of 279 BRAF-negative patients (47% of all enrolled in the study) first-line systemic treatment was Anti-PD-1 immunotherapy and the median overall survival was 26.3 months. BRAF-positive patients had shorter median overall survival than the BRAF-negative patients: 14.5 months and 26.3 months – respectively ($p = 0.0001$). For the entire analysed population median overall survival was 16.8 months and median progression free survival – 8.5 months.

Conclusions

This real-world data analysis has proven clinical benefits of both Anti-PD-1 immunotherapy and BRAF/MEK inhibitors in the first line of systemic treatment of patients with advanced melanoma. Although the overall survival was worse than in clinical trials, it corresponded to other real-world data analyses for patients with advanced melanoma.

[2002] Thyroid lobectomy and its role in the diagnosis and treatment of thyroid neoplasms

Authors: Paulina Filipowicz, Paulina Kalman, Paweł Szajewski

Affiliation: Faculty of Medicine, Medical University of Warsaw; Department of Oncological Endocrinology and Nuclear Medicine, Maria Skłodowska-Curie National Research Institute of Oncology, Warsaw.

Trustee of the paper: prof. dr hab. n. med. Marek Dedecjus

Corresponding author: Paulina Filipowicz (paulinafilipowicz7@gmail.com)

Introduction

Choosing the best therapeutic strategy for patients with thyroid neoplasms can be challenging due to the distinct characteristics of the lesions. Polish recommendations are based on guidelines created by American and European societies, however, they present a specific approach adapted to the Polish conditions. Thus, there is a need to address clinical issues in thyroid cancer management with national data to provide a better perspective.

Aim of the study

We aimed to analyze the characteristics of patients with thyroid nodules treated by lobectomy and assess the association between preoperative factors, risk of malignancy and requirement of completion thyroidectomy.

Materials and methods

Clinical and pathological data of consecutive patients with aspiration biopsy results of the Bethesda II-VI category treated by thyroid lobectomy in the Maria Skłodowska-Curie National Research Institute of Oncology in Warsaw between 2018 and 2021 were used for retrospective analyses. Mann-Whitney U test, Shapiro-Wilk test and chi-square test were used for statistical analyses.

Results

492 patients (405 females, 87 males), with a median age of 43 years (range: 17-86) at the time of the primary lobectomy were included in the study. The majority of patients qualified for the surgery had fine-needle aspiration biopsy results of the Bethesda V or IV category in 47.6% and 25.1% of cases, respectively. Cancer was found in 73% of all specimens (n=358) with papillary thyroid carcinoma (PTC) as the most prevalent histotype (n=217, 60.6%). No significant association was noted between preoperative factors: age, sex, BMI, tumor diameter, Tg, TgAb, TPOAb, TSH concentrations and diagnosis of cancer in Bethesda category IV lesions ($p>0.05$). Patients with category V and VI lesions outside of the low-risk group were qualified for completion thyroidectomy, mostly due to tumor diameter >1 cm (40.6%) and multifocality (29.7%). According to the new Polish recommendations 2022, 20 patients (12%) who previously underwent completion thyroidectomy could be qualified for observation. However, in 4 cases pathological examination revealed malignancies in the second lobe and 2 patients were diagnosed with lymph node metastases.

Conclusions

Qualifying patients for lobectomy and completion thyroidectomy requires considerations of multiple factors. There is still a need for further research on this issue.

[1557] Tisa-cel CAR-T for relapsed/refractory diffuse large B-cell lymphoma, one therapy – two different clinical presentations. An urgent need to design adverse event predictors

Authors: Jaromir Tomasik, Joanna Drozd-Sokołowska, Piotr Kacprzyk, Agnieszka Tomaszewska, Rafał Machowicz, Elżbieta Urbanowska, Samanta Witkowska, Grzegorz W. Basak

Affiliation: Department of Hematology, Transplantation and Internal Medicine, Medical University of Warsaw, Warsaw, Poland

Trustee of the paper: Professor Grzegorz W. Basak

Corresponding author: Jaromir Tomasik (s080290@student.wum.edu.pl)

Background

CAR T-cell therapy for diffuse large B-cell lymphoma (DLBCL) has revolutionized treatment outcomes and posed new challenges to clinicians. Herein we present and compare the first two cases of patients treated with tisa-cel at the Department of Hematology, the Medical University of Warsaw. Both patients developed diverse clinical presentations after CAR-T infusion, constituting a valuable example of variable systemic responses to tisa-cel.

Case report

Initially, both patients were diagnosed with DLBCL not otherwise specified, Patient#1 had a stage IV, whereas stage IIE was diagnosed in Patient#2. Both patients were females with no comorbidities. Following the diagnosis, Patient#1 received 6 cycles of R-CHOP (rituximab/cyclophosphamide/adriamycin/vincristine/prednisone) chemoimmunotherapy and irradiation of the involved areas. Due to progressive disease (PD), the patient received R-DHAP (rituximab/dexamethasone/cytarabine/cisplatin) salvage therapy with prophylactic methotrexate/dexamethasone. After one R-DHAP cycle, the treatment was continued with R-ICE (rituximab/ifosfamide/carboplatin/etoposide) due to a lack of response to the former. The R-ICE therapy resulted in remission before CAR-T infusion. Patient#2 received pre-phase treatment with cyclophosphamide/glucocorticoids followed by 4 cycles of CHOP, 4 cycles of R-CHOP and irradiation. Then, 4 cycles of R-ICE were administered resulting in PD and Patient#2 was qualified for CAR-T therapy. Later, Pola-BR (polatuzumab vedotin/bendamustine/rituximab) regimen was implemented as bridging therapy, nevertheless because of PD, the patient received afterward 1 cycle of R-DHAP, with macroscopic progression during the cycle. Following the CAR-T infusion, Patient#1 experienced no adverse events, whereas Patient#2 developed grade 3 cytokine release syndrome (CRS) and grade 1 neurotoxicity. The CRS onset was on day +1 post-infusion and manifested with tachycardia, hypotension, fever, head and neck edema, and required oxygen therapy. Tocilizumab and vasopressors were administered, resulting in CRS subside. On day +6, mild neurotoxicity developed.

Conclusions

The abovementioned cases show different clinical presentations following the treatment, which could not be determined beforehand. Current guidelines state that CRS prediction is not yet possible. Recently, CRS has been linked to endothelial dysfunction, and various endothelial activation markers have been proposed as predictors, prompting extensive research on the associated molecules.

[1578] "Mutation in SDHD and SDHB genes in a 22-year-old patient with multiple familial paragangliomas."

Authors: Monika Kukawska-Rytel, Łukasz Banaszek, Elżbieta Szczepanek- Tyrak, Kazimierz Niemczyk, Anna Rzepakowska

Affiliation: 2. Department of Otorhinolaryngology, Head and Neck Surgery, Medical University of Warsaw

Trustee of the paper: MD, PhD Anna Rzepakowska

Corresponding author: Łukasz Paweł Banaszek (s077657@student.wum.edu.pl)

Background

Paragangliomas are rare neuroendocrine tumors arising from the paraganglia bodies of the autonomic system. A significant part of paragangliomas and pheochromocytomas occur sporadically, but in recent years, with the knowledge of more than 20 mutations of predisposing genes, the proportion of genetically determined cases has increased. Molecular testing is now recommended as the standard of care for patients with paragangliomas in order to establish a confident diagnosis, plan appropriate follow-up and prognosis.

Case report

The case report concerns a 22-year-old man who presented to his physician after an episode of fainting in 2012. As a result of the tests performed, a proliferative lesion was detected in the upper mediastinum. The lesion was removed in 2013 with the diagnosis of a paraganglioma. Another paraganglioma-like lesion appeared in the retroperitoneal space (removed in 2014) and on the left side of the neck (removed in 2020). The father's medical history included two resections of paragangliomas of the neck. The patient was diagnosed with multiple pheochromocytomas and paragangliomas syndrome with a mutation in the SDHD gene. A follow-up MRI performed in 2022 revealed a 16x13x21 mm focal lesion in the division of the right common carotid artery. The patient had recently begun to feel pressure in this area. He did not experience pressure elevations, and a daily urine collection for methoxycatecholamines showed no abnormalities. As part of hospitalization, the lesion was removed, and histopathological examination revealed a paraganglioma with cells without SDHB expression, which supports loss of function of this gene (SDHB deficient).

Conclusions

Mutations in the SDHB and SDHD genes are associated with a higher risk of pheochromocytoma and paraganglioma neuroendocrine tumors. Patients burdened with multiple pheochromocytoma and paraganglioma syndromes associated with gene mutations require multispecialty care. Because of its rarity and the diagnostic difficulties associated with the need for targeted genetic testing, it often takes a long time from the onset of symptoms to final diagnosis.

[1597] Delayed diagnosis of retroperitoneal solitary fibrous tumor: a case report

Authors: Arnoldas Grinys

Affiliation: Vilnius University, Faculty of Medicine, Lithuania

Trustee of the paper: Prof. Tomas Poškus, MD Ugnius Mickys

Corresponding author: Arnoldas Grinys (arnoldasgrinys@gmail.com)

Background

Solitary Fibrous Tumors (SFT) are rare mesenchymal neoplasms that can occur in various locations throughout the body. Intra-thoracic locations are the most common, followed by intra-abdominal sites. Due to their rarity and nonspecific clinical and radiological features, SFTs can present a diagnostic challenge, particularly when located in the retroperitoneum.

Case report

A 56-year-old male presented with a two-year history of abdominal pain and weight loss, reporting a loss of 6 kg and a palpable mass in the lower part of the abdomen. During this period, the patient presented with recurrent hypoglycemic episodes. The patient had no other significant past medical history. One year ago, during a visceral sonoscopy, a tumor was discovered and the patient was referred for an MRI of the abdomen. The results of the MRI were inconclusive due to an incorrectly specified body area. The patient was then referred to a tertiary university hospital where a repeat examination was performed and a CT scan of the abdomen and pelvis was ordered which revealed a large retroperitoneal tumor (21cm in diameter), in the pelvis. The patient underwent laparotomy, tumor excision, and sigmoid resection. The postoperative period went without complications. Histopathological examination results revealed a solitary fibrous tumor that had spread to the mesocolon and showed areas of necrosis. Additionally, reactive lymphadenopathy was observed in the mesentery. The tumor was found to be positive for CD34, Bcl-2 and STAT6 on immunohistochemical staining. Based on the histopathological characteristics of the tumor, the patient was found to have a moderate risk of recurrence, as calculated using the modified Demicco risk scoring system.

Conclusions

The prediction of the biological behavior of SFT is challenging, as benign but potentially locally aggressive tumors may exhibit malignant behavior. Early diagnostics of neoplasms and thorough patient examination can help prevent complications and lower the risk of malignancy. Due to the lack of randomized control trials, an established and globally accepted treatment strategy for solitary fibrous tumors has not been determined. Therefore, they should be approached similarly to other soft tissue sarcomas. A follow-up after surgery is necessary to detect any relapses early.

[1722] Incidental pancreatic cystic neoplasm and mesenteric low-grade fibromyxoid sarcoma: a case report

Authors: Elena Čijauskaitė

Affiliation: Vilnius University, Faculty of Medicine, Lithuania

Trustee of the paper: Dr. Rolandas Vaicekuskas

Corresponding author: Elena Čijauskaitė (ecijauskaite@gmail.com)

Background

The increased availability of various radiologic imaging options has resulted in an increase in incidental findings, for example, pancreatic cystic neoplasm, which has been reported relatively frequently. In comparison, fibromyxoid sarcoma on the mesentery is a much more unusual finding. In our case, we discuss the diagnostics and management of both mentioned pathologies.

Case report

A 61-year-old male patient was referred to an abdominal surgeon due to an accidentally discovered cystic lesion in the pancreas on a chest CT that included part of the abdominal cavity. The patient had mild, generalized abdominal pain and diarrhea. The complete blood count and cancer blood markers (carcinoembryonic antigen, carbohydrate antigen 19-9 and chromogranin A) were within normal limits. Follow-up abdominal CT and MR cholangiopancreatography showed a 48×28×44 mm cystic neoplasm in the uncinate process of the pancreas. Pancreatic cyst fluid and a fragment of the wall were obtained through endoscopic ultrasound-guided fine needle aspiration (EUS-FNA) and EUS-guided fine needle biopsy (EUS-FNB). Most of the pancreatic cyst fluid was drained during the procedure. No abnormalities were found in the tested fluid or in the cyst wall biopsy, and the cyst was most likely non-mucinous. However, the follow-up radiology scans revealed another solid mass on the mesentery. Extirpation of the mass was performed, and pathologic analysis indicated that the mass was a low-grade fibromyxoid sarcoma (pT2b). A non-complete resection was suspected, but a decision was made against revision surgery. Instead, the tumor site was treated with radiotherapy. The patient underwent a whole-body CT and mannitol enterography three months after the surgery. The pancreatic cyst had not increased in size, and at the former fibromyxoid sarcoma site, post-operative lesions were visible, but no tumor recurrence was identified.

Conclusions

A patient with mild symptoms was found to have two incidental findings: a more commonly seen pancreatic cyst and a much rarer mesenteric fibromyxoid sarcoma. This case illustrates that it is important to carefully evaluate all the available cross-sectional scans, and that, as the number of incidental findings increases, less common nosological entities should be considered.

[1901] Hemophagocytic lymphohistiocytosis as a complication of Hodgkin's lymphoma - case report

Authors: Weronka Ploch

Affiliation: Student Scientific Association of Hematology, Department of Hematology, Oncology and Internal Medicine, Medical University of Warsaw

Trustee of the paper: Rafał Machowicz, MD, PhD, MSc; Dorota Szczeń, MD; Prof. Krzysztof Jamrozia

Corresponding author: Weronika Ploch (wera.ploch@gmail.com)

Background

Hemophagocytic lymphohistiocytosis (HLH) is a self-accelerating hyperactivation of the immune system. Release of the inflammatory cytokines stimulates the macrophages in bone marrow leading to uncontrolled phagocytosis. Usually, it's triggered by a malignancy, autoimmune disease, or an infection. Although there is no pathognomonic symptom of HLH, it is crucial to establish the diagnosis and look for underlying disease, because untreated HLH is fatal.

Case report

A 46-year-old patient with inherited protein S deficiency, leading in childhood to right nephrectomy, has been dealing with an unproductive cough for years. In the last 6 months, he lost 10 kg and started having episodes of pyrexia up to 40°C with shivers every few days. He didn't experience any specific symptoms. His condition was deteriorating, he became thrombocytopenic (PLT 94 thousand/mm³) and developed hypertriglyceridemia (TG 531 mg/dL) with iron deficiency. His WBC and Hgb remained within normal range. To narrow down the diagnosis, tests for infectious and rheumatological diseases were performed but all came out negative. A PET scan revealed increased metabolism in the bone marrow and a focused lesion located in the nephrectomy bed. Then his WBC dropped to 2.2 thousand/mm³, ferritin level reached 1670 ng/mL and myelogram showed increased hemophagocytosis.

After these results patient was admitted to the Department of Hematology, Oncology and Internal Medicine due to suspicion of secondary HLH. At that moment he met 7 of 8 HLH diagnostic criteria with fever, splenomegaly, cytopenia (NEU 0.56; HGB 7.9; PLT 71), hyperferritinemia (1388 ng/ml), hemophagocytosis in bone marrow, elevated sCD25 concentration (25435 u/ml) and hypertriglyceridemia (503 mg/dL). To distinguish between inflammatory and neoplastic triggering factor, a histopathological examination was necessary. Due to the patient's portal vein and vena cava thrombosis and collateral circulation, surgical access to the tumor was denied to avoid massive hemorrhage. Core-needle lymph node biopsy results allowed to establish the diagnosis of Hodgkin's lymphoma stage IV. Then ABVD (adriamycin-bleomycin-vinblastine-dacarbazine) treatment was initiated.

Conclusions

Although HLH symptoms are nonspecific such as pyrexia or cough they aggravate over time. It is important to diagnose this syndrome as soon as possible and find its triggering factor to start adequate treatment and prevent patient's death.

[1922] Unexpected diagnosis in a patient with oncological background - adrenocortical carcinoma misdiagnosed with general metastatic disease

Authors: Paweł Szajewski, Paulina Kalman

Affiliation: Student's Scientific Society "Thyoldea" of Department of Oncological Endocrinology and Nuclear Medicine, Maria Skłodowska-Curie National Research Institute of Oncology, Warsaw

Trustee of the paper: Agnieszka Żyłka MD, PhD

Corresponding author: Paweł Szajewski (pawelszajewski@gmail.com)

Background

Adrenocortical carcinoma (ACC) is an aggressive cancer originating in the cortex of the adrenal gland. It is a rare tumor, with incidence of one to two per million population annually and most cases are hormone-secreting. Surgical removing of the tumors is the most promising treatment option, but many of them are non-operative. However, new treatments continue to improve survival rates for people with ACC.

Case report

The case presents a 74-year-old patient with a significant oncological background. In 2020 he underwent a Transurethral Resection of Bladder Tumor (TURBT) because of the urothelial carcinoma. It was followed by a neoadjuvant pembrolizumab therapy as a matter of clinical trial. Few months later surgeons performed a radical cystoprostatectomy with urine diversion. During follow-up a lesion in the left adrenal gland was detected and thought to be metastatic but lymph nodes weren't suspected of meta. In an abdominal cavity magnetic resonance imaging (MRI), the lesion's size continued to grow in relation to its size prior to the previous scan, showing signs of a restricted diffusion and heterogeneous contrast enhancement. A fluorodeoxyglucose positron emission tomography-computed tomography (FDG PET/CT) confirmed the tumor's metabolic activity and detected a lesion in the right adrenal gland with a low FDG uptake. A left-sided adrenalectomy was performed but histopathological examination revealed the presence of adrenocortical carcinoma (ACC). The laboratory studies of hormones levels were carried out but results were within normal range. The right adrenal gland tumor wasn't suspected of a malignant neoplasm four months after the last imaging test and the patient was qualified for adjuvant mitotane treatment of ACC. Patient ceased taking pembrolizumab through a treatment and quickly after that he stopped taking mitotane due to side effects. During a follow-up, a lesion in the right adrenal gland changed its morphology in MRI and was suspected of pheochromocytoma, which was declined after hormone studies. The patient was qualified for a right sided adrenalectomy.

Conclusions

Initially, a tumor in the left adrenal gland was thought to be metastatic and may delayed the diagnosis. Regional lymph nodes were also ignored but according to the guidelines local regional lymphadenectomy seems to lead to a favorable oncological outcome. Moreover, pembrolizumab in this case may influence the ACC because it is also considered to be a third-line treatment in this cancer.

[1959] Stereotactic re-irradiation of spinal metastases from malignant peripheral nerve sheath tumor: a case report

Authors: Arkadiusz Moskwa

Affiliation: Students' Scientific Group of Multidisciplinary Oncology 'Onkosfera', Department of Soft Tissue/Bone Sarcoma and Melanoma, Maria Skłodowska-Curie National Research Institute of Oncology in Warsaw

Trustee of the paper: Mateusz Spalek, MD, PhD

Corresponding author: Arkadiusz Jan Moskwa (amoskwa2001@gmail.com)

Background

In a selected group of patients, intensive local treatment for spinal metastases may provide a benefit in quality of life and survival. The preferred method of local therapy for spinal oligometastases is stereotactic body radiotherapy (SBRT) that could be combined with surgery. However, in the case of local progression, reirradiation remains a challenge due to the fear of radiation-induced myelopathy.

Case report

A thirty-year-old female patient after surgical excision of a tumor of the left femur in 2015 with the diagnosis of desmoid fibroma was referred to a tertiary cancer center due to the suspicion of disease recurrence. After central pathological review the primary tumor was reclassified as low-grade osteosarcoma. She received perioperative chemotherapy and a limb-sparing resection. Two years later, positron emission tomography (PET) revealed a lesion in the 2nd thoracic vertebra that was resected. Pathology report confirmed metastatic dedifferentiated osteosarcoma. She received SBRT for the tumor bed, 27 Gy in three fractions. After half a year, PET showed progressive disease. She began the second line chemotherapy, gemcitabine with docetaxel. After 18 months he presented progressive disease in the thoracic area. Th2/Th3 tumor was removed with laminectomy and posterior spinal stabilization. The pathological report showed a new diagnosis of malignant peripheral nerve sheath tumor. Shortly after surgery she presented rapid progression with multiple in-transit lesions in the thoracic area. She received salvage reirradiation with hybrid SBRT, 32.5/45 Gy in ten fractions. She continued chemotherapy. Three months later she developed symptomatic progression in the thoracic vertebrae with lung metastases and underwent salvage spinal surgery. Chemotherapy was switched to etoposide with ifosfamide and three months later to cisplatin with doxorubicin and additional dacarbazine. After several months CT revealed borderline recurrence of spinal metastases at the C5-C7 level. The patient received third SBRT, 35 Gy in five fractions. Chemotherapy was changed into paclitaxel monotherapy. The patient remained stable for the next three months and she still receives systemic treatment (02.2023).

Conclusions

Aggressive local therapy combined with chemotherapy may provide a benefit for selected patients with oligometastatic or oligoprogressive disease. Repeated spinal SBRT seems to be a safe and feasible treatment.

[1974] Primary plasma cell leukemia with extraosseous involvement in the abdominal cavity. Description of case.

Authors: Kacper Pająk

Affiliation: Medical University of Warsaw, Department of Hematology, Oncology and Internal Diseases

Trustee of the paper: Piotr Boguradzki, MD, PhD

Corresponding author: Kacper Julian Pająk (kacper.pajak17@gmail.com)

Background

Plasma cell leukemia (PCL) is a rare and aggressive form of plasma cell dyscrasia. It can arise de novo (primary-PCL) or develop from pre-existing multiple myeloma (secondary-PCL). The incidence ranges between 0.4-2.4 cases per million individuals. PCL is diagnosed after detecting circulating plasma cell count constituting at least 5% of peripheral leukocytes. It usually has a progressive course and a very poor prognosis. We highlight a pPCL case with extraosseous involvement in the abdominal cavity.

Case report

69 years old male with a history of polymyalgia rheumatica was admitted to the hospital with an abnormal complete blood count, general weakness, weight loss of 10 kilos, and ostealgia. Hepatomegaly and splenomegaly were spotted during physical examination. Laboratory tests revealed: leucocytosis, normocytic anemia and thrombocytopenia. Furthermore, 10% of abnormal plasmacytes were found among peripheral white blood cells. Additionally, elevated total protein levels, monoclonal IgG and light kappa and lambda chains were detected. The patient initially responded to VTD (bortezomib-thalidomide-dexamethasone) therapy with further plans for autologous stem cell transplantation, but after 2 months patient began to complain about intense visceral pain. Computed tomography revealed enlarged celiac and periaortic nodes. Ascites and increased echogenicity of abdominal fat was also noted. Histopathological analysis of abdominal biopsy material was performed revealing a CD138, CD56, KI-67 positive and CD20 negative cell population confirming the presence of pPCL infiltration. The patient began daratumumab therapy and is currently still hospitalized.

Conclusions

In this case report we highlight a case of pPCL, one of the rarest neoplasia of the hematopoietic system. Besides the involvement of the bone marrow, and the peripheral blood the involvement of the other internal organs has to be considered. Any signs of extraosseous progression of pPCL should be carefully evaluated by physicians, because areas such as the abdominal cavity may be affected.

Online Poster

Date: 22nd April 2023, 9:00 AM

Coordinators:
Karolina Puerto Cardozo
Aleksandra Serafin

[1565] 7-year outcomes in diabetic patients after coronary artery bypass graft in a developing country

Authors: Parmida Sadat Pezeshki 1, Farzad Masoudkabar, MD, MPH 2, Mina Pashang, Msc 3, Ali Vasheghani-Farahani, MD 2, Arash Jalali, PhD 3, Saeed Sadeghian, MD 3, Kaveh Hosseini, MD, MPH 3, Soheil Mansourian, MD 4, Shahram Momtahan, MD 4, Abbasali Karimi, MD 3

Affiliation: 1Student Scientific Research Center,2Cardiac Primary Prevention Research Center,3Tehran Heart Center,4Research Center for Advanced Technologies in Cardiovascular Medicine,Cardiovascular Diseases Research Institute Tehran University of Medical Sciences

Trustee of the paper: Farzad Masoudkabar, MD, MPH (Corresponding author)

Corresponding author: Parmida Sadat Pezeshki (pezeshkiparmida@gmail.com)

Introduction

Revascularization in diabetic patients with coronary artery disease remains a challenge in cardiology practice. Although clinical trials have reported the mid-term superiority of coronary artery bypass grafting (CABG) surgery over percutaneous coronary intervention in these patients, little is known about the long-term outcomes of CABG in diabetic patients compared to non-diabetics, particularly in developing countries.

Aim of the study

This study aimed to assess the long-term outcomes of CABG in diabetic patients and compare them to non-diabetic patients.

Materials and methods

Between 2007 and 2016, we recruited all patients who underwent isolated CABG in a tertiary care cardiovascular center in a developing country. The patients were followed at 3-6 months and 12 months after surgery, and then annually. The study endpoints were 7-year all-cause mortality and major adverse cardiac and cerebrovascular events (MACCE).

Results

Of 23873 patients (17529 males, mean age 65.67 years) who underwent CABG, 9227 (38.65%) patients were diagnosed with diabetes. After adjustment for potential confounders, patients with diabetes experienced a 31% increase in MACCE seven years after surgery compared to the non-diabetic patients (HR = 1.31, 95%CI: 1.25-1.38, P-value<0.0001). Meanwhile, diabetes contributes to a 52% increase in the risk of all-cause mortality after CABG (HR= 1.52, 95% CI: 1.42-1.61, P-value<0.0001).

Conclusions

Our study showed a higher risk of all-cause mortality and MACCE at seven years in diabetic patients undergoing isolated CABG. The outcomes in the studied center in a developing country were comparable to western centers. The high incidence of adverse outcomes in the long term in diabetic patients implies that not only short-term but long-term measures should be taken to improve the CABG outcomes in this challenging patient population.

[1664] MAY VIRTUAL REALITY BASED TRAINING REPLACE STANDARD DENTAL EDUCATION?

Authors: Dominika Domanowska, Aleksandra Orlańska, Martyna Czeakańska, Iwona Bąk

Affiliation: Medical University of Warsaw

Trustee of the paper: Łukasz Zadrożny, Piotr Sulikowski, Anu Polster

Corresponding author: Dominika Domanowska (dominikadomanowska@gmail.com)

Introduction

Dental students' competency and manual dexterity that allows working in a clinical setting is traditionally reached through training on typodonts and phantom heads first. Recently modern teaching aids incorporating augmented and virtual reality have been more widely used to train dental students. Simodont allows training on typodonts in virtual reality setting with automated real-time feedback. This study adds to the recently emerging research on haptic technology use in dental training.

Aim of the study

The aim of the study is to evaluate dental students' subjective feedback on a Simodont training experience and through this help understand augmented reality-based teaching aids' perspectives and limitations in modern dental university teaching, with focus on its implementation in the preclinical curricula.

Materials and methods

Ethics clearance for this study was obtained from the local Ethics Committee. 90 students trained on Simodont for 1, 3 or 4 hours - practicing cariology preparations, with clinical stage students additionally practicing endodontics and crown preparations. An online survey was prepared using Microsoft Forms and distributed via Microsoft Teams after students' training was completed. This qualitative survey was divided into 2 sections: A. Background information B. Simodont experience. Part A consisted of single-choice questions about sex, stage at university, training length, preferences towards analog and digital aids and usage of glasses or contact lenses. Part B consisted of 5 single-choice questions and 18 five-point Likert scale statements. Collected data was anonymised prior to statistical analysis.

Results

Students received Simodont training positively, three in four wanting to continue training. 41% disagreed that Simodont provides experience similar to treating real teeth. Majority (68,9%) would prefer to practice with teachers' supervision. Of students wearing glasses, 38% had difficulties. Contact lenses disrupted 3% of respondents. 66% prefer studying with analog teaching aids over digital.

Conclusions

Although Simodont is valuable educational tool well accepted by students, it is not perceived to adequately replace traditional training on phantom heads. Besides Simodont provides an instant feedback and automatic evaluation of performed task students do not wish to use it without supervision from an academic teacher, thus making the idea of removing tutor supervision costs a vain hope.

[1687] Statin therapy in chronic kidney disease patients undergoing hemodialysis

Authors: Santa Strapcane

Affiliation: Riga Stradiņš University, Faculty of Medicine

Trustee of the paper: E.g. Assoc. Prof. Andris Skride, Dr.Dana Kigitoviča/ Rīga Stradiņš University, Pauls Stradiņš Clinical University Hospital, Latvia.

Corresponding author: Santa Strapcane (036476@rsu.edu.lv)

Introduction

Patients receiving hemodialysis present significantly higher risk for cardiovascular events and, furthermore, benefits of statins are controversial in these patients (Fellström et al., 2009).

Aim of the study

Analyze data of statins use in patients from different Latvian hemodialysis centers.

Materials and methods

A cross-sectional study included consecutive patients from four hemodialysis centers from June till October 2022. Data was analyzed with SPSS statistics.

Results

Among 113 included patients, 64.6% were man, mean age was 62.8 ± 14.9 years. Current smokers were 14.2%. Most common primary cause for hemodialysis (47.2%) was glomerular diseases. Comorbidities as primary arterial hypertension and diabetes were diagnosed in 39.8% and 17.7% of patients, respectively. History of arterial vascular disease was present in 47 (41.6%) patients, 26 (23%) patients underwent revascularization. Anamnesis of kidney transplantation was present in 17.7%. Mean plasma concentration for total cholesterol, LDL cholesterol and triglycerides were 4.4 ± 1.3 mmol/L, 2.5 ± 1.1 mmol/L and 1.7 ± 1.3 mmol/L, respectively. Statins were used in 60 (53.1%) patients, majority of them (68.3%) were using atorvastatin. Majority of statin users (49.2%) had unknown therapy starting date regarding haemodialysis, while 31.7% of patients were using statins before haemodialysis and only 19% of patients started statin therapy while undergoing haemodialysis. Patients who had transplantation were associated with 2.4 times increased usage of statins ($p > 0.05$). No significant lipid concentration difference was observed between patients who underwent transplantation and those who did not. ($p > 0.05$). LDL concentration with and without statin use was 1.97 and 2.73 ($p = 0.03$), respectively. Patients with history of cardiovascular events had 8.4 times higher probability of using statins than patients without cardiovascular events ($p < 0.001$, CI 3.47-20.53) and 10.3 times higher probability of using statins after revascularization than patients without revascularization ($p < 0.001$, CI 2.98-37.11).

Conclusions

Statin therapy was related to history of cardiovascular events and revascularization, as well expressing significantly lower LDL concentration, that might be beneficial in secondary prophylaxis. History of transplantation was associated with increased statin administration.

[1781] **Women's awareness of the prevention of the oral mucosa and periodontium diseases before and during the pregnancy**

Authors: Magdalena Mikołajewicz, Maria Januszek, Beata Wnuk, Aleksandra Orlańska

Affiliation: Medical University of Warsaw/ Department of the Periodontology and Oral Diseases

Trustee of the paper: Andrzej Miskiewicz, PhD, MD, DDS,

Corresponding author: Magdalena Ewa Mikołajewicz (mag.mikolajewicz@gmail.com)

Introduction

Pregnant women's oral health and its link to adverse pregnancy outcomes continuously attracts research attention, as evidence is mounting in support of it being a significant factor of fetal well-being, term, birth weight and eventually oral health of the child itself. We deemed it necessary to investigate women's awareness on prophylaxis of mucous and periodontal diseases, so that the systemic educational efforts aimed at lowering disease prevalence can be better tailored.

Aim of the study

This paper examines women's level of awareness on oral periodontal diseases prophylaxis before and during pregnancy. Correlations between level of awareness with age, number of pregnancy and women' source of knowledge about oral prophylaxis were also performed.

Materials and methods

The study was conducted in the form of a electronic survey (CAWI method). It was attended by 115 women aged 20-40. Seven respondents were pregnant during presented study, 72 women were before or during their first pregnancy. Respondents answered seven single choice questions. The total awareness of diseases of the oral mucosa and periodontium before or during the planned pregnancy was calculated as a % of answers consistent with current medical knowledge. Respondents also indicated their preferred source of knowledge on prophylaxis of the oral cavity (single choice question) and preferred methods of oral hygiene for pregnant woman (multiple choice questions).

Results

The level of awareness on oral periodontal diseases prophylaxis was relatively low – mean value in whole group was only 53,79% of correct answers (SD = 26,85). Only seven respondents got maximum score. There was no significant correlation between the level of awareness and age of participants. Women before or during their first pregnancy didn't differ in the level of awareness from women after their first pregnancy. The level of awareness was significantly lower in respondents that would most likely obtain knowledge about oral prophylaxis from Internet or family / friends compared to ones whose source of knowledge would be from dentists, science publications or gynecologist.

Conclusions

Women's knowledge on dental prophylaxis around pregnancy leaves much to be desired. Despite broad access to information on this subject, many do not know how many dental visits should occur during pregnancy and how to care for oral hygiene and therefore how to prevent mucosal and periodontal diseases.

[1830] Academic teaching during Covid-19 pandemic- Unanticipated Challenges and Opportunities

Authors: Parham Motamedi, Aleksandra Sroka, Małgorzata Rylska, Ewa Pietrzkiwicz, Julia Soszyńska, Magdalena Osiak, Zofia Tetela

Affiliation: SKN przy Zakładzie Propedeutyki i Profilaktyki Stomatologicznej WUM

Trustee of the paper: Dr. Małgorzata Ponto-Wolska, Dr. Łukasz Zadrożny

Corresponding author: Parham Motamedi (parham96motamedi@gmail.com)

Introduction

The development of the pandemic (Covid-19) made the world become to a sudden halt. The immediate change to online teaching and the lack of contact with students, the lack of experience of teachers in new teaching methods paradoxically resulted in their rapid development and implementation into university teaching.

These incidents caused the need for new educational methods to be felt. After the pandemic period, it is possible to evaluate these methods and use them daily depending on educational needs.

Aim of the study

This study aims to verify and assess students' satisfaction with teaching methods forced by the pandemic and changes in contact with teachers and colleagues.

Materials and methods

In order to conduct this survey study, ethics clearance was granted by the local ethics committee at the Medical University of Warsaw, code AKBE/14/2021. A 24-question survey was prepared in a Google form and shared with students of the Medical University of Warsaw. Descriptive statistics were performed to analyze the data.

Results

Responses were received from 255 students from different divisions of the Medical University of Warsaw. The results of the survey showed how much online education has affected the quality of teaching in students' perceptions. To what extent the pedagogy used during COVID-19 has been accepted by students and positively received in the future curriculum. Almost half of the students considered communication with students and teachers and the possibility of interactive cooperation to be successful. 93% of students believe that online education should be used to some extent in the future.

Conclusions

The challenges and lessons learned from teaching during the COVID-19 pandemic have prompted us to introduce new methods into the curriculum. Using traditional teaching methods along with electronic education. We also gained valuable information on how to change the direction of teaching medical professionals in the future. However, personal interactions are essential in medical school education, such as professional activities and patient contact.

[1851] Cocaine- and amphetamine-regulated transcript (CART) – a new potential promitotic factor in the prostate.

Authors: Jan Pawłasek¹, Maja Owe-Larsson¹, Alicja Sztokfisz-Ignasiak¹, Mikołaj Pater¹, Tomasz Piecha²

Affiliation: 1. Department of Histology and Embryology, Medical University of Warsaw, 02-004 Warsaw, Poland. 2. Department of General, Oncological and Functional Urology, Medical University of Warsaw, Lindleya 4, 02-005 Warsaw, Poland.

Trustee of the paper: Izabela R. Janiuk¹

Corresponding author: Jan Pawłasek (janpawlasek1903@gmail.com)

Introduction

Benign prostatic hyperplasia (BPH) is characterized by an adenomatous, non-clonal overgrowth of prostatic stroma and epithelium. BPH is the most common benign illness of the prostate and occurs widely among aging men. In humans, the proliferative process appears only in the transition zone and periurethral glands. This issue is a frequent cause of lower urinary tract symptoms. Even though many risk factors of BPH have been well defined, its pathogenesis is still unclear and the factors involved in its development are still to be established. Cocaine- and amphetamine-regulated transcript (CART) is a protein known mainly as a neurotransmitter, but it is also associated with cell cycle modulation and promotion of cell proliferation. Because of its proproliferative function, it is possible that CART may participate in the pathogenesis of BPH.

Aim of the study

The aim of this study was to perform immunodetection and immunolocalization of the CART peptide in structures of the prostatic gland in patients with BPH.

Materials and methods

Prostate samples from patients with bladder outlet obstruction were obtained through transurethral resection of the prostate. These samples were later examined histopathologically and by immunohistochemistry (IHC). The severity of changes in the samples was assessed using a standard staining technique (H&E). A reliable and selective visualisation of CART-positive structures was performed by IHC, using the Dako EnVision Flex+/HRP detection system and a polyclonal antibody against CART (Phoenix Pharmaceuticals Inc., USA).

Results

Microscopic analysis of H&E-stained slides showed excessive proliferation of epithelial and stromal cells, which confirmed BPH in all samples. Assessment of IHC-stained samples revealed high CART expression in the glandular epithelial cells of prostate glands in all specimens.

Conclusions

According to our knowledge, CART expression in prostatic glandular epithelial cells was shown for the first time in our study. The role of this peptide in BPH pathogenesis is still unknown and remains to be explained. It is worth noting that our results are mainly of scientific importance when it comes to the identification and localization of CART in the prostate gland.

[1874] Residents learning ultrasound guided subclavian central venous cannulation: does practice make perfect?

Authors: Jakub Olszewski, Jakub Zieniewicz, Jan Mastalerek, Mateusz Zawadka

Affiliation: 2nd Department of Anesthesia and Intensive Care, Medical University of Warsaw, Warsaw, Poland.

Trustee of the paper: dr. n. med. Mateusz Zawadka

Corresponding author: Jakub Olszewski (s072527@student.wum.edu.pl)

Introduction

Ultrasound guided subclavian central venous cannulation has recently been proven to be a safer and more effective approach in comparison to the traditional landmark technique. Because of the novelty of this approach there are no available data regarding the learning curve of this approach. Some authors claim 10 and other 30 but there are no evidence supporting these claims.

Aim of the study

The aim of our study was to determine minimum number of ultrasound guided subclavian central venous cannulation to allow for safe practice.

Materials and methods

Total of 40 US-guided subclavian vein cannulation procedures were performed by two inexperienced residents specializing in anesthesiology and intensive care over a period of 8 months. The first ten attempts performed were compared to the last ten in terms of success rate and average time needed to insert the catheter. The learning curve was defined as the period of ongoing improvement in first attempt success rate and access time.

Results

The last ten procedures compared to the first ten were associated with a higher success rate (80% versus 60%). The mean time from the start of the procedure to successful catheter insertion calculated for the first and last ten procedures was not statistically significant ($85s\pm 60$ versus $82,37s\pm 54.35$; $p = 0.77$). The learning curve showed that 40 procedures was required to achieve first attempt success rate of at least 80%.

Conclusions

80% success rate in US-guided subclavian central venous catheterization can be gained after 40 attempts. No correlation between number of procedures performed and decreased time needed to place a catheter has been ascertain.

[3011] Application of prebiotic antisepsis for purulent complications in patients with type 2 diabetes mellitus

Authors: Yevhenii Prykhodko

Affiliation: Department of General Surgery, Bogomolets National Medical University, Kuiv, Ukraine

Trustee of the paper: Doctor of Medical Sciences (MD), professor Oleksandr Ioffe, Candidate of Medical Sciences, docent Oleksandr Stetsenko, Candidate of Medical Sciences, assistant Stepan Kindzer, Candidate of Medical Sciences (PhD), assistant Mykola Kryvopustov

Corresponding author: Yevhenii Prykhodko

Introduction

Every year, the number of patients with type II diabetes (T2D) in the world increases by 5–7%, and every 12–15 years it doubles. Along with the incidence of type II diabetes mellitus, the number of its purulent-necrotic complications is rapidly increasing, and accordingly, the level of antibiotic resistance in this group of patients.

Aim of the study

Purpose: to improve the results of surgical treatment of patients with type II diabetes and purulent-necrotic wounds by using probiotic antiseptics.

Materials and methods

66 patients with type II diabetes and purulent-necrotic complications took part in this study. Probiotic antiseptics were used for local treatment in the experimental group (n=31), and traditional antiseptics were used in the control group (n=35). The levels of pro-inflammatory markers in the blood (IL-6, TNF- α , CRP) were studied; microscopic material was taken to study the type of cytogram during bandaging, before wound treatment with antiseptics or debridement on admission to the hospital (1st day), on the 3rd day and on the 7th day.

Results

Analysis of dynamic changes in pro-inflammatory markers between the first and seventh days proved that only in the experimental group there was a statistically significant difference (IL-6 (P=0.004), TNF- α (P=0.001), CRP (P=0.018)). Detection of regenerative-inflammatory and regenerative cytogram types on the 7th day in the experimental group had a statistically significant difference compared to the control group (p=0.002 and p<0.001, respectively).

Conclusions

1. Local use of probiotic antiseptics leads to faster statistically significant positive dynamics of changes in systemic inflammation indicators in patients with purulent-necrotic wounds in type II diabetes. (P=0.001).
2. Probiotic antiseptic accelerates the healing of wounds in these patients, compared to the use of chemical antiseptics. (P <0.001).

Ophthalmology

Date: 21st April 2023, 15:00 PM

Coordinators:
Maria Źmijewska
Sylwia Adamus

[1702] The impact of COVID-19 infection and vaccination on ophthalmologic thromboembolic complications

Authors: Natalia Zalewska, Anna Skoczek-Wojciechowska, lek. Ahmad Shaer

Affiliation: First Department of Ophthalmology, Medical University of Warsaw

Trustee of the paper: dr hab. n. med. Joanna Brydak-Godowska

Corresponding author: Natalia Zalewska (natalia.zalewska2700@gmail.com)

Introduction

The pandemic caused by severe acute respiratory syndrome coronavirus 2 (SARS-CoV-2) had been one of the most demanding medical issues of current decade. COVID-19 disease affected multiple organs including eye. Among numerous ophthalmological complications of this infection, those connected with hypercoagulability causing vascular occlusive events seem the most deleterious. Furthermore, despite COVID-19 vaccinations are crucial in prevention of severe course of infection, thromboembolic events are suspected to be vaccine side effect as well.

Aim of the study

The aim of this study was to assess the impact of COVID-19 infection and vaccination on thromboembolic complications concerning eye (including retinal venous thrombosis, central retinal artery occlusion and ischemic optic neuropathy).

Materials and methods

The retrospective study was based on 92 medical records of thromboembolic events considering eye collected over a period of two and a half years (from March 2020 to September 2022).

Results

Among 92 patients of both sexes with thromboembolic events, 77,17% (n=71) presented retinal venous thrombosis, 16,30% (n=15) – central retinal artery occlusion (CRAO), 1,09% (n=1) with coexisting retinal venous thrombosis and CRAO and 5,44% (n=5) – anterior ischemic optic neuropathy (AION). In 16 cases there was a possible correlation between undergoing COVID-19 vaccination or infection.

Conclusions

All registered vaccinations against COVID-19 disease have been proved to be safe and effective in clinical trials. However, there is the possibility that they might cause hypercoagulability states resulting in thromboembolic events considering eye vessels. Our study shows the importance of vigilant monitoring of ophthalmologic side effect of vaccination and COVID-19 infection, especially in patients with other hypercoagulability risk factors.

[1721] "Eales disease - A case report"

Authors: Dominika Kuźmiuk, Aleksandra Skorupa, Aleksandra Nowińska

Affiliation: Uniwersytet Medyczny w Lublinie, SKN przy Katedrze i Klinice Okulistyki Ogólnej i Dziecięcej

Trustee of the paper: Opiekun pracy Dr hab. n. med. Anna Woźniak, Prof UM

Corresponding author: Dominika Kuźmiuk (dominikakuzmiuk1@gmail.com)

Introduction

Eales disease is a rare, idiopathic, inflammatory disease of the retinal vessels leading to their obstruction and secondary neovascularisation. It is characterised by the occurrence of spontaneous, recurrent haemorrhages into the vitreous which can result in loss of vision. It occurs mainly in males and boys between 15 and 30 years of age and usually involves both eyeballs.

Aim of the study

The aim of our work was to present a 26-year-old patient with Eales disease.

Materials and methods

The patient was referred to the Department of General and Paediatric Ophthalmology, Medical University of Lublin, with the referral : "retinal detachment with tear of the left eye". Detailed ophthalmological examination revealed many ocular abnormalities: nystagmus in both eyes, retinal neovascularisation and haemorrhage into the vitreous body without concomitant retinal detachment in the left eye.

Results

The patient was diagnosed with Eales' disease on the basis of the clinical presentation and additional investigations. Treatment included intraocular injections of anti-VEGF drugs and laser panphotocoagulation in both eyes and pars plana vitrectomy (TPPV) with silicone oil in the left eye. Encorton was administered as a pharmacological treatment. Currently, the patient is under the constant care of the outpatient clinic due to the risk of recurrent vitreous haemorrhages.

Conclusions

Conclusions: Eales disease is insidious and can become a cause of dangerous complications leading to significant deterioration or loss of vision. Early treatment is the only way to protect against complete loss of vision.

[1824] Effectiveness of ozonated liposome gel in treatment of superficial corneal injuries

Authors: Authors: 1. MD Krzysztof Rękas [1], PhD, MD Maksymilian Onyszkiewicz [2], Paweł Oszczędlowski [1] Supervisors: Post-doctoral degree, PhD, MD Tomasz Choraǳiewicz [2], Professor Robert Rejda, MD [2], Professor Mario Toro [2] [1]

Affiliation: Students' Scientific Association at the Chair and Department of General and Paediatric Ophthalmology, Medical University of Lublin, 20-079 Lublin, Poland

Trustee of the paper: PhD, MD Tomasz Choraǳiewicz

Corresponding author: Krzysztof Rękas (kriss.rekas@gmail.com)

Introduction

Introduction: Post-traumatic corneal erosions are one of the most prevalent ophthalmological diseases. They manifest themselves as a feeling of pain, photophobia, eye burning, reduced vision, lacrimation. Incorrect treatment of corneal erosion, can result in corneal infection, which can even lead to permanent blindness. The main goals in corneal erosions treatment are corneal epithelium regeneration and prevention of infections. Currently used antibacterial preparations (aminoglycosides, fluoroquinolones) are effective against majority of bacteria that cause keratitis and ineffective against a few bacteria, fungal and viral infections. The most frequently used moisturizing preparations are drops containing sodium hyaluronate. Its main disadvantage is that it does not stay on the surface of the eye and its effect wears off quickly. Ozone has been previously used as a clinical therapeutic agent for long-lasting wounds such as ischemic ulcers and diabetic wounds. To apply ozonated oil safely, the formula (Ozodrop®, FB Vision, Ascoli Piceno, Italy) contained liposomal ozonated oil.

Aim of the study

To assess the effectiveness of ozonated liposome gel in treatment of superficial corneal injuries (erosions).

Materials and methods

60 patients with superficial corneal erosions were divided into 2 groups. In 1st they were treated with topical antibiotic and Ozodrop Gel preparation. In 2nd (control group) patients were treated with: topical antibiotic and drops containing sodium hyaluronate. All patients underwent ophthalmological examination before treatment and after 24 and 48 hours after application of preparations, including slit lamp examination with use of fluorescein and blue cobalt filter.

Results

Treatment with Ozodrop Gel resulted in regeneration of corneal epithelium comparable with standard treatment. Regeneration was expressed in erosion surface 24 and 48 hours after application of preparations.

Conclusions

The results show that liposomal ozonated oil could be a potentially useful agent in treatment of corneal erosions. Our data suggest that regeneration is no worse than in standard treatment- and when synthesised with data from literature, it can be concluded that ozone-containing drops could be beneficial against pathogens, and they change their viscosity under the influence of body temperature, they stay longer on the surface of the cornea compared to alternatives. We recommend further studies to explore the effectiveness of ozonated liposome oil on larger group of patients.

[1943] Patients' perspective on Visual Snow Syndrome

Authors: Przemysław Rusztyn, Wiktoria Stańska, Anna Maria Torbus, dr. n. med. Piotr Maciejewicz

Affiliation: SKN Lens przy Katedrze i Klinice Okulistyki WUM

Trustee of the paper: dr n. med. Piotr Maciejewicz

Corresponding author: Przemysław Rusztyn (prusztyn@gmail.com)

Introduction

Visual snow syndrome (VSS) is a rare phenomenon described as seeing through a translucent mesh of many small points superimposed on the field of view, resembling a snowy image on a TV. The pathophysiology of this condition remains unknown and no effective treatment was yet discovered.

Aim of the study

The aim of this study is to increase awareness of this condition between medical professionals and to see it from patients' perspective. Other people's experiences may also help newly diagnosed patients to find their way of living with a diagnosis of an incurable disease of an unknown origin.

Materials and methods

Two anonymous surveys were conducted on two support groups on Facebook (one polish and one international) for people suffering from VSS. In total 198 people affected by this condition participated. Questions were focused mainly on assessing the symptoms, their influence on everyday life, exacerbating and relieving factors, comorbidities, diagnostic path, and implemented treatments.

Results

About 40% of responders do not remember anything that preceded the first appearance of VSS. Most of those who associate its appearance with anything believe that it was induced by stress which along with lack of sleep, and physical fatigue was also one of the main exacerbating factors. The main comorbidity was anxiety, however, most patients weren't diagnosed with anything else than VSS. Nearly 50% of patients visited an ophthalmologist as the first physician to diagnose VSS but only about 1% assessed the knowledge of doctors about VSS as good or very good. The most commonly used pharmacological treatment were vitamins from group B and magnesium supplements however mainly no improvement was shown. Responders were also asked to advise people who may be newly diagnosed with this disease and the main message was clear: " don't panic, learn how to live with it and it will be better".

Conclusions

These results show that there is no simple way to improve the lives of patients with VSS, however, most of them need mainly understanding and support from their doctors. That is why education among medical professionals may be, for now, the best way to help our patients.

[1569] Loss of vision in the course of giant cell arteritis.

Authors: Wiktoria Stańska

Affiliation: Students' Scientific Association in the Department of Internal Medicine and Rheumatology, Military Institute of Medicine – National Research Institute, Warsaw, Poland

Trustee of the paper: Robert Kruszewski, MD, PhD

Corresponding author: Wiktoria Stańska (wstanska@gmail.com)

Background

Giant cell arteritis is a rare disease of arteries, occurring mainly in the elderly population. Although the involvement of temporal arteries can be most symptomatic, occlusion of ophthalmic arteries has the most serious consequences. That's why early diagnosis and treatment are essential.

Case report

A 74-year-old female patient with hypertension was consulted by a family medicine doctor several times because of neck pain radiating to the temporal areas of the head. The pain did not respond to nonsteroidal anti-inflammatory drugs. The painful sensation was gradually increasing. Moreover, she began having headaches, night sweating, edema of the submandibular area, and trismus also occurred. The condition was treated as a common cold, but two days after administering the antibiotic patient's vision deteriorated in the right eye, and she experienced flashes of light. Eventually, blindness occurred. So, the patient was admitted to the Ophthalmological Department. The patient had anisocoria. The pupillary light response was medium, and she denied having any sense of light. No pursuit movements of the eyes were observed.

Fundus examination revealed papilledema and optic nerve atrophy. CT of the face, MRI of the orbits, and head MRI did not reveal any significant abnormalities. Ultrasound examination showed thickened walls of the temporal and carotid arteries with a halo sign. Laboratory blood tests revealed elevated c-reactive protein (CRP) (109,8mg/l). Upon above mentioned findings, giant cell arteritis was suspected. Steroids and IV vinpocetine were administered. Nevertheless, the vision did not improve.

The patient was referred to the Rheumatology Department to continue the treatment. On admission, she presented vision loss in both eyes and swelling of both temporal arteries. Erythrocyte sedimentation rate (ESR) and CRP were back to normal. A lack of contrast filling in the ophthalmic arteries was observed in CT angiography. The whole clinical picture confirmed the primary diagnosis. Dexamethasone was upped to 45 mg/day, and methotrexate in a dose of 25mg per week in subcutaneous injections was added.

Conclusions

New onset headaches in elderly patients should alert healthcare professionals. That's why differential diagnosis is crucial here, as giant cell arteritis if left untreated leads to blindness in 30% up to 50% of patients.

[1786] **Visual snow: Pixelated vision without any abnormalities in ophthalmic examinations – case report**

Authors: Wiktoria Stańska, Anna Maria Torbus, Przemysław Rusztyn,

Affiliation: Students' Scientific Association, Department of Ophthalmology, Medical University of Warsaw

Trustee of the paper: Piotr Maciejewicz, MD, PhD

Corresponding author: Wiktoria Stańska (aurelia.wstanska@gmail.com)

Background

Visual snow (VS) is a clinical entity from neuro-ophthalmology. It is described as dynamic, flickering dots affecting the whole visual field, compared to pixelated television static. Unfortunately, patients often face a lack of understanding from medical professionals as the nature of the condition is subjective and elusive.

Case report

We present a case report of a 23-year-old woman presenting visual snow. The patient was admitted to the Ophthalmological Department of Clinical Hospital Dzieciątka Jezus in Warsaw. The main symptoms were bright, flickering dots seen with opened and closed eyes, particularly disturbing while looking at plain backgrounds and reading paper books. It was accompanied by severe photophobia, nyctalopia, and oscillopsia. She has had VS for as long as she can remember, but only two years ago, she realized that her visual symptoms were not physiological. Interestingly, the patient's identical twin also experiences VS. Our patient had been previously diagnosed with fibromyalgia, psoriasis, and Sjogren's syndrome, treated with methotrexate.

In our department, we performed an extensive ophthalmological examination. All the results were correct except for low myopia, -0,75 diopters in both eyes. Magnetic resonance also did not reveal any abnormalities. According to the patient wearing eyeglasses with a filter of blue light improves her condition. In April 2021, she had COVID-19 and experienced a depressive episode simultaneously. After administering duloxetine, her VS worsened. Nevertheless, the patient continued taking the drug.

Conclusions

Visual snow can be a distressing condition for many patients, lowering the comfort of daily life. Moreover, it is often labeled as purely psychogenic, which is stigmatizing for patients. That is why even though the pathophysiology of VS remains unknown and there is no strong recommendation for effective treatment, we believe that by expanding the knowledge about it, we can have a real impact on the comfort of patients.

[1888] Ocular manifestation of malignant hypertension

Authors: Maria Żmijewska, Anna Zaleska-Żmijewska

Affiliation: Department of Ophthalmology, Medical University of Warsaw

Trustee of the paper: Anna Zaleska-Żmijewska

Corresponding author: Maria Żmijewska (zmijewska01@gmail.com)

Background

Systemic hypertension may cause changes in small retinal vessels and at the last stage of hypertensive retinopathy may severely decrease vision.

Case report

43- years old man was sent for an ophthalmology consultation from Internal Ward. He has been hospitalized because of high blood pressure and cardiomyopathy diagnosed after Covid-19 infection. At admission his blood pressure was 200/140, heart rate: 98/min. He had no vision deterioration. We found edema of optic nerve heads in both eyes, with areas of retinal ischemia (cotton wool spots) and hemorrhages on the disc. The diagnosis of the 4 th stage of hypertensive retinopathy due to malignant hypertension was done. There were also severe changes in the morphology of small retinal arteries examined with adaptive optics- rtx1 microscope. 6 months after the first consultation he was checked again. We found no edema of the optic discs, but defects in retinal nerve fiber layer around optic nerve head. The adaptive optics examination revealed similar changes in retinal arteries with highly increased wall to lumen ratio and thickening of artery walls.

Conclusions

Thinning of the retinal nerve fiber layer and changes in retinal microcirculation are the consequence of malignant hypertension.

[1965] CMV retinitis in patient with myelofibrosis and oncological history

Authors: Maciej Dyda, Paweł Skowron, Maria Kręcicka

Affiliation: Wrocław Medical University/ Department of Ophthalmology

Trustee of the paper: Anna Turno- Kręcicka, MD, PhD, professor at Wrocław Medical University

Corresponding author: Maciej Dyda (macdyda@gmail.com)

Background

A case of rare bilateral cytomegaloviral retinitis in a patient with both hematological and oncological history.

Case report

A 70-year-old Caucasian male was admitted to the hospital because of a progressive visual deterioration lasting 3 weeks, initially limited to the left eye, afterward bilateral. The patient presented with renal impairment, splenomegaly, and at the time treated with ruxolitinib for myelofibrosis with myeloid metaplasia. The patient had a history of renal clear-cell carcinoma, treated with a left-sided nephrectomy a year before followed by chemotherapy. Ophthalmological history of bilateral glaucoma. On examination, vitreous opacities and zones of peripheral retinal necrosis and atrophy were noted. The patient was admitted for further diagnosis.

General tests were ordered, as well as the determination of CMV early antigen levels and CMV-DNA by PCR in patient's plasma. Both results were positive. The patient's medical history combined with the results of all tests, strongly suggested that his ocular disease was cytomegalovirus retinitis. Accordingly, the patient was treated with an intravitreal injection and intravenous infusions of ganciclovir in doses modified by the eGFR value. The patient was transferred to an area hospital for further hematologic and ophthalmologic treatment. The patient responded well to the treatment, and the disease stabilized.

Conclusions

Combined intravitreal and intravenous infusions of ganciclovir can prevent the progression of vision-threatening CMV retinitis and reduce intraocular complications.

Orthopedics & Traumatology

Date: 21st April 2023, 15:00 PM

Coordinator:
Robert Kołaczyński

[1521] Comparison of Copper Oxide Dressings (COD) to Negative Pressure Wound Therapy (NPWT) Preliminary results of wound healing parameters in a randomized controlled trial

Authors: Eyal A. Melamed, MD1; Jihad Dabbah, MD2; Ithamar Cheyne3; Michael S. Pinzur, MD4

Affiliation: 1 Department of Orthopedics, Rambam Health Care Campus, Haifa, Israel. 2 Department of Orthopedics, Rambam Health Care Campus, Haifa, Israel. 3 Medical University of Warsaw, Warsaw, Poland. 4 Loyola University Health System, Maywood, IL, USA.

Trustee of the paper: Eyal Melamed MD

Corresponding author: Ithamar Cheyne (ithamar1512@gmail.com)

Introduction

Negative Pressure Wound Therapy (NPWT) is the standard of care for treating large and deep wounds and deep cavities. Copper Oxide Dressings (COD) have been recently introduced into clinical practice due to their antimicrobial properties. Research and clinical experience showed their positive effect also in inducing wound healing, including stimulation of autolytic debridement, granulation tissue formation and epithelization.

Aim of the study

The aim of this RCT is to prove non-inferiority of COD in compared to the standard of care of large and deep wounds, NPWT, in the areas of wound healing, convenience, and application time.

Materials and methods

We initiated a randomized controlled trial with 60 diabetic patients comparing the reduction of wound size during 3 months of treatment between COD management to NPWT, by using an artificial intelligence program (Tissue Analytics, TA).

Results

29 patients have finished the study. Of the 14 patients in the NPWT, 5 dropped from the study, 4 due to worsening foot condition and 1 due to his general health condition. All 15 patients in the COD arm completed the study. Average wound area was 21.02 ± 23.36 cm² in the COD arm and 14.84 ± 13.17 cm² in the NPWT arm ($p=0.41$). Reduction of wound size assessed by TA was 61.5% and 41% ($p=0.04$) after 1 month, 80.9% and 69% ($p=0.28$) after 2 months, and 88% and 84% ($p=0.17$) after 3 months, in the COD and NPWT arms, respectively. 7 wounds (46.7%) were closed in the COD arm and 4 wounds (28.6%) were closed in the NPWT arm. The average time to closure the wounds was 60.14 and 77.75 days in the COD and NPWT Arms, respectively ($p=0.18$). COD therapy was statistically significantly more convenient (Visual Analog Score [VAS] was 8.44 vs. 5.33; $p=0.002$) and less painful (VAS was 1.15 vs. 2.19; $p=0.67$) to the patients in the COD arm than in the NPWT arm. The medical personnel scored COD application as more convenient than the NPWT application (8.29 vs. 6; $p=0.007$). The mean application time was shorter for the COD compared to the NPWT (8.5 vs. 13.25 minutes; $p<0.001$). Cost is estimated to be ~15% in the COD Arm compared to NPWT Arm.

Conclusions

The preliminary results of this RCT study indicate statistically significant non-inferiority of COD therapy compared to NPWT in terms of wound healing rate and superior results in terms of convenience, and reduced application time in addition to lower cost. The findings suggest that COD may be considered as first line of treatment for wounds in diabetic patients when NPWT deemed necessary.

[1555] Assessing the length of the pedicle of the anterolateral thigh flap

Authors: Bartłomiej Wilk¹, Ewa Trams³ MD, Ewa Nosarzewska¹ MD, Marcin Złotorowicz^{2,3} MD, PhD

Affiliation: 1 Medical University of Warsaw, 61 Żwirki i Wigury St, 02-091 Warsaw, Poland 2 Centre of Postgraduate Medical Education, Warsaw, Poland 3 Department of Orthopaedics, Pediatric Orthopaedics and Traumatology, Gruca Teaching Hospital, Otwock, Poland

Trustee of the paper: Bartłomiej Wilk

Corresponding author: Bartłomiej Wilk (wilk.wilkbartlomiej@gmail.com)

Introduction

Anterolateral thigh flap (ALT) was first described by Song et al. in 1984. The authors reported the possibility of using a septocutaneous flap with blood supply from the descending branch of the lateral femoral circumflex artery (LFCA). Since then the idea evolved resulting in numerous improvements in the operative technique and practical applications of the flap. The ALT flap has many advantages. The flap has a wide pedicle thus anastomosis can be easily performed. What is more the flap can cover a large surface. A commonly described advantage of the ALT flap is its long vascular pedicle. Although the data about exact pedicle length is inconsistent and varies regarding measurement method and acquired results. In our opinion, there is a significant need for a study that would help to assess the length of the pedicle of the ALT flap.

Aim of the study

To assess the length of the ALT flap pedicle.

Materials and methods

Study group consisted of patients who underwent computed tomography angiograms ranging minimally from anterior superior iliac spine (ASIS) superiorly and patella inferiorly. We included in the study 44 patients with mean age of 65,9 years (range: 47-87). In the axial window we identified single scans with: (1) ASIS, (2) superolateral corner of the patella, (3) the origin of the descending branch of LFCA. Knowing the scan density in every study and the difference in scan number we calculated (4) the distance between the scans (1) and (2). This distance (4) represented the length of the line connecting anterior superior iliac spine (ASIS) and superolateral corner of the patella (AP line). Next we identified (5) the midpoint of the distance (4) representing the midpoint of the AP line. The midpoint of the AP line is well proven to be the point of the highest concentration of perforators for the ALT flap. Then we calculated (6) the distance between the scan (3) and the midpoint (5). This distance (6) could serve as the approximate length of the ALT flap pedicle since it is the distance between the origin of the branch of the artery that gives blood supply for the ALT flap and the point of the highest concentration of the ALT flap perforators.

Results

Mean distance (4) was 45,34 cm (SD=4,14). Mean distance (6) was 11,69 cm (SD=1,62). There was insignificant moderate correlation between the distance (4) and the distance (6) ($r=0,48$; $p>0.05$).

Conclusions

Our study suggests that the mean estimated length of the ALT flap pedicle is 11,69 cm and it is not significantly dependent on the length of the AP line.

[1626] Measuring proprioception using inertial motion sensors - checking for reliability and validity

Authors: Szymon Stupnicki, Łukasz Żytka, Przemysław Lubiowski

Affiliation: Sport Traumatology and Biomechanics Unit, Rehasport Clinic, Poznań University of Medical Sciences, Poznań.

Trustee of the paper: Szymon Stupnicki

Corresponding author: Szymon Stupnicki (sszymon0303@gmail.com)

Introduction

Inertial motion sensors function is based on the inertial measurement units (IMU) system. Each sensor contains an accelerometer, magnetometer and gyroscope, which enable orientation in three-dimensional space. These three components measure position of reference object by process of sensory fusion created with specialized mathematical algorithms. It can be used to assess proprioception, athlete's basic movement patterns, checking for kinesitherapy according to given movement patterns or as an orthopedic protractor.

Aim of the study

The purpose of this study was to check for reliability and validity of RSQ Motion inertial motion sensors in measuring proprioception.

Materials and methods

We recruited 8 healthy patients. Study was directly performed by 2 researchers. Elbow joint was the one we analyzed in this study. Biodex proprioception protocol was a reference method of assessment. Patients performed 2 modules of proprioception testing: active proprioception and passive proprioception. In each module patients had to reproduce previously shown reference angle of elbow flexion or extension. There were 3 angles we assessed: 50,70 and 110 degrees of elbow flexion. Starting position was 90 degree of elbow flexion. 50 and 70 degree angle was reproduced by extension from starting position, 110 angle by flexion. Each angle was repeated 3 times, both limbs were screened (9 measurements in each limb, in each module). Every patient was examined 3 times in order to assess intra and inter-rater reliability. Overall, study was based on 864 angles measurement.

Results

Kendall's coefficient of concordance, which assessed inter-rater agreement reached 0,67 ($p < 0,05$). This is considered as good and almost strong (from 0,7). Wilcoxon test for paired samples showed that there is no statistical difference between measurements done by the same rater (intra-rater reliability). Moving to validity, Bland–Altman plot results were very good, with mean difference between sensor and Biodex measurement of just 0,11 degree. Moreover, the Wilcoxon test showed that there are no statistical differences between these two methods of proprioception examination.

Conclusions

Both reliability and validity of RSQ Motion inertial motion sensors in measuring proprioception was proved in this study. Using this tool to measure proprioception can be repeatable and reproducible, as well comparable to Biodex. Further research on different planes of the human body and examination of the other joints may be beneficial to confirm that they are universal.

[1795] Magnetically controlled growing rods for the treatment of early onset scoliosis: a cohort study

Authors: Kacper Stolarz, Tomasz Koziół, Aleksander Osiowski, Maksymilian Osiowski

Affiliation: 1.Ortho and Spine Research Group, Poland 2.Department of Orthopaedics, Orthopaedics-Rehabilitation University Hospital in Zakopane, Poland

Trustee of the paper: Dominik Tattera MD, Tomasz Potaczek MD, PhD

Corresponding author: Kacper Maciej Stolarz (kacperstolarz2001@gmail.com)

Introduction

Early onset scoliosis (i.e., scoliosis which has been diagnosed before the age of 10 years) is a serious condition concerning patients suffering from neuro-muscular diseases. Moreover, still many of the cases are classified as idiopathic. Conservative treatment is frequently insufficient and therefore surgical intervention is necessary. However, traditionally used growing rods require repeated surgeries which may expose patients to higher risk of long-lasting complications. Magnetically controlled growing rods were introduced almost a decade ago as an alternative to traditional growing rods for management of early onset scoliosis. MAGEC rods can be lengthened non-invasively which reduces risks connected with numerous surgical interventions. However, there is still a lack of research on this system with long postoperative follow-up time.

Aim of the study

The purpose of this study was to evaluate clinical and surgical outcomes of early onset scoliosis treatment with MAGEC® system in patients with long follow-up time.

Materials and methods

Preoperative, postoperative and follow-up protocols of 48 paediatric patients from orthopaedic ward were reviewed. Cobb angles were measured on radiographs before and after the surgery, and after the latest follow-up visit. Moreover, distraction lengths as given by external remote controller and as measured on radiographs were noted on each visit. Paired student t-test or ANOVA was used when normality of the data was met. For nonparametric analyses Wilcoxon signed-rank test was utilized.

Results

The mean age of patient at the time of surgery was 8.2 years (SD = 1.96) and mean follow-up time was 24.96 months (SD = 15.77). Mean percentage of correction of scoliosis immediately after the surgery was 50.7% (SD = 14.2%) and 46.8% (SD = 18.4%) after the latest follow-up visit with differences being statistically significant ($p=0.021$). The distraction length shown by the external remote controller used for magnetic distraction was significantly larger than actual distraction measured on x-ray ($p=0.014$). Moreover, type of scoliosis influenced postoperative and follow-up correction values ($p=0.011$).

Conclusions

Our results show that the initial correction after the surgery was larger than at the last follow-up. Moreover, distraction length as given by manufacturer's device deviated significantly from real-life measurements. Nonetheless, MAGEC is a feasible system for treatment of early onset scoliosis.

[1796] Transpedicular screw fixation for neuromuscular scoliosis – what are the differences between DMD and SMA patients ?

Authors: Maksymilian Osiowski; Aleksander Osiowski; Kacper Stolarz; Tomasz Koziol

Affiliation: 1. Ortho and Spine Research Group, Poland 2. Department of Orthopaedics, Orthopaedics-Rehabilitation University Hospital in Zakopane, Poland

Trustee of the paper: Dominik Tattera MD, Tomasz Potaczek MD, PhD

Corresponding author: Maksymilian Marek Osiowski (maks.osiowski@gmail.com)

Introduction

One of the most common deformity in neuromuscular diseases is scoliosis. The scoliosis may vary from mild to severe in different cases and often a corrective surgery that can significantly improve quality of life is needed. Spinal muscular atrophy (SMA) and Duchenne muscular dystrophy (DMD) are two neuromuscular disorders which often lead to serious spinal deformities. Unfortunately, previous research often included them together in one neuromuscular type of scoliosis despite being separate medical conditions with specific pathogenesis, symptoms and also differing spinal deformities. Therefore, there was a need for a study that would systematically compare surgical treatment outcomes between patients with SMA and DMD.

Aim of the study

The purpose of this study was to evaluate and compare clinical and radiological outcomes of the scoliosis surgery treatment in SMA and DMD patients.

Materials and methods

Preoperative and postoperative protocols of 70 pediatric patients with SMA or DMD were reviewed. Measurements of Cobb angle, range of the curvature, pelvic and shoulder tilt, length from central sacral vertical line to apical vertebrae of scoliosis were taken on every radiograph in sitting and elongated positions to determine improvement after the surgery. Student t-test and Welch's t-test were utilized to compare means. For nonparametric analyses Mann-Whitney U was employed. Multiple regression was used when adjusting for confounders.

Results

The mean weight was 52.21kg (SD=14.59) in DMD patients and 39.86kg (SD=11.05) in SMA patients. The mean percentage of Cobb angle correction was 47.49% (SD=17.06) in DMD patients and 57.53% (SD=14.83) in SMA patients with differences being statistically significant ($p < 0.04$). There was no significant difference in mean Cobb angle before surgery ($p = 0.32$), pelvic obliquity change ($p = 0.89$), post-op hospital stay time ($p = 0.77$), time spent in ICU ($p = 0.61$), post-op blood units transfusions ($p = 0.31$) and BMI ($p = 0.39$) between these two groups of patients.

Conclusions

When adjusted for weight and initial Cobb angle, the type of disease (DMD vs. SMA) remained the only predictor of higher Cobb angle change after surgery. No other analyzed factors played a significant role in surgical outcomes.

[1810] Change in the size of the anterior part of the distal femur after TKA affects knee flexors force

Authors: Bartłomiej Wilk, Grzegorz J. Maciąg, Marcin Łapiński, Maciej Świercz, Bartosz M. Maciąg

Affiliation: Department of Orthopedics and Rehabilitation, Międzyleski Specialist Hospital, Medical University of Warsaw, 2 Bursztynowa St, 04-749 Warsaw, Masovian Voivodeship, Poland

Trustee of the paper: Bartłomiej Wilk

Corresponding author: Bartłomiej Wilk (bartlomiejwilk00@gmail.com)

Introduction

Total knee arthroplasty (TKA) is an effective procedure in the treatment of osteoarthritis of the knee joint. Throughout the years of improvements in the operative technique and implant designs the number of postoperative complications has profoundly decreased. Nevertheless, there is room for improvement since up to 20% of the patients remain unsatisfied after the procedure. One of the reasons for it may be improper knee flexors and extensors muscles biomechanics. If the femoral component of the implant is placed more anteriorly, it increases the tension in the knee extension mechanism and decreases it in the flexion mechanism. These changes may affect the postoperative results such as range of motion, pain and muscle force. However, it is still uncertain how preoperative femoral anatomy affects postoperative effects in the aspect of biomechanics.

Aim of the study

To assess how femoral component placement in TKA affects knee biomechanics in relation to preoperative femoral anatomy.

Materials and methods

In the study we included 35 patients who underwent TKA. All patients had a standard preoperative and postoperative radiographic examination performed in the anteroposterior and lateral planes. On pre and postoperative lateral radiographs we measured: posterior condylar offset (PCO) defined as the distance between the line tangent to the posterior femoral cortex and a parallel line tangent to posterior femoral condyles, posterior femoral cortex ratio (PCOR) defined as the ratio between PCO and the distance between the line tangent to the anterior femoral cortex and a parallel line tangent to posterior femoral condyles and Anterior Femur Index (AFI): the distance between the line tangent to the anterior femoral cortex and a parallel line tangent to the most anteriorly placed point of the distal femur. We calculated the difference in each parameter pre to postoperatively (Δ). Additionally, we calculated postoperative knee flexors and extensors peak and average muscle force using Activeforce dynamometer. Statistical analysis of data was performed using Pearson's and t-student tests.

Results

Neither Δ PCO nor Δ PCOR does not significantly affect postoperative flexors or extensors muscles force. An increase in Δ AFI causes mild significant decrease in flexors muscle force peak ($r=-0.38$, $p=0.03$) and flexors muscle force average ($r=-0.42$, $p=0.01$).

Conclusions

A postoperative increase in the size of the anterior part of the distal femur after TKA decreases the force of knee flexors muscles.

[1870] **The patellar height change in relation to joint line measured with Miura-Kawamura index after primary total knee arthroplasty does not correlate with patient-reported outcome – an observational study of 89 patients with 1 year follow-up**

Authors: Bartosz M. Maciąg, Tomasz Kordyaczny, Mateusz P. Nawrocki, Krystian Żarnovsky, Grzegorz J. Maciąg, Olga Adamska, Krzysztof Modzelewski, Jakub Świderek, Artur Stolarczyk

Affiliation: Department of Orthopedics and Rehabilitation, Międzyzleski Specialist Hospital, Medical University of Warsaw

Trustee of the paper: Mateusz P. Nawrocki

Corresponding author: Mateusz Piotr Nawrocki (mateusz.nawrocki@student.wum.edu.pl)

Introduction

One of the main reasons for the significant percentage of patients not satisfied with their total knee arthroplasty (TKA) remains anterior knee pain associated with patellofemoral joint. Patella and joint line relation is very important considering extensor mechanics in the knee. It was demonstrated that joint line level change might alter patella biomechanics and lower patient-reported outcome in various types of prostheses.

Minor joint line level change could, however, not alter the outcome of primary total knee arthroplasty with use of „patella-friendly” implants. This state of affairs could create an acceptable margin of error in joint line re-creation with uninfluenced patient-reported outcome.

Aim of the study

The aim of the study was to assess a correlation between a change in patellar height index following total knee arthroplasty, with the use of anatomic, “patella-friendly” implant, and the patient-reported outcome measures.

Materials and methods

89 consecutive patients with diagnosis of end-stage primary knee osteoarthritis who underwent TKA from 2020 to 2021 were analyzed retrospectively. TKA was performed with on-label usage of cemented JOURNEY II BCS Total Knee System (Smith and Nephew, Warsaw, IN) without patella resurfacing. Pre- and postoperative standard fullweightbearing X-rays were performed in the AP and lateral 30 degrees flexion, non-weight bearing views. Patellar height was assessed using the Miura-Kawamura index, which is based on distal femoral condyle to patella relation. Knee injury and Osteoarthritis Outcome Score (KOOS) questionnaire results were obtained from patients preoperatively and 12 months after arthroplasty procedure by the independent researcher during standard follow-up. Inclusion criteria were: 1) age over 45 2) clinically and radiologically confirmed end-stage knee joint arthritis 3) TKA performed utilizing Journey II BCS implant without patella resurfacing. Pre and postoperative MKI and KOOS values were assessed for correlation using Spearman’s correlation coefficient.

Results

There were no statistically significant correlations between KOOS subscale scores/total score and both change of value and of absolute value of MKI.

Conclusions

MKI change does not correlate with patient-reported outcome. Joint line level change is well tolerated after TKA in examined ranges. We believe that „patella-friendly” implants could forgive minor errors in patellofemoral joint alterations.

[1898] Anatomical predisposing factors for subsequent patellar dislocation

Authors: Anna Kupczak, Bartłomiej Wilk

Affiliation: Medical University of Warsaw, Warsaw, Poland; Gruca Orthopaedic and Trauma Teaching Hospital, Otwock, Poland

Trustee of the paper: Ewa Tramś, MD

Corresponding author: Anna Małgorzata Kupczak (akupczak01@gmail.com)

Introduction

Patellar dislocation occurs when the patella moves laterally beyond the trochlear groove. The primary dislocation is usually caused by an injury, however a certain group of people are more predisposed to it due to a particular knee structure. The first dislocation may often lead to a subsequent one and some anatomical factors may have a significant impact on the recurrence rate.

Aim of the study

The aim of the study was to analyze the anatomical structure of the knee joint among patients who had suffered a patellar dislocation and to find anatomical factors which may suggest predisposition to subsequent dislocations.

Materials and methods

The study includes 100 patients after a primary patellar dislocation. The parameters measured on the MRIs were: tibial tuberosity to trochlear groove distance (TT-TG), tibial tuberosity to posterior cruciate ligament distance (TT-PCL), Insall-Salvati index, sulcus angle and patellar tilt angle (PTA). Moreover, trochlear dysplasia type in the Dejour classification was assessed. Information was then obtained from all patients as to whether there had been another dislocation of the patella - 56 patients did report a recurrent injury. The control group included 44 patients who suffered from patellar dislocation only once.

Results

All factors studied were significantly elevated in relation to the population norm in both the primary and subsequent patellar dislocation groups. The anatomical factors which values differed most between the two groups were TT-TG and PTA. The mean TT-TG distance among the control group was 16.34 mm and the mean PTA was 20.12 degrees. The mean TT-TG distance among patients who dislocated their patella again was 18.72 mm and the mean patellar tilt in this group was 24.45 degrees. There was no significant correlation in the values of TT-PCL, Insall-Salvati index and sulcus angle between the two groups. Trochlear dysplasia was observed in both groups of patients.

Conclusions

Anatomical factors which, after a primary dislocation of the patella, are particularly predisposing to recurrent injury may be significantly increased TT-TG value and PTA. Other parameters measured, which are usually elevated in cases of patellar dislocation according to the results obtained, do not appear to have a significant effect on subsequent dislocations. However, this requires a further examination.

[1917] Does flat foot have a negative impact on the biomechanics of movement in school - aged children?

Authors: Monika Zaborska, Bożena Kielbasa, Bartłomiej Jasiulewicz, Dawid Fornalski

Affiliation: Department of Orthopaedic & Trauma Surgery, University Hospital in Opole, University of Opole

Trustee of the paper: dr hab. n. med Piotr Morasiewicz, prof. UO

Corresponding author: Monika Zofia Zaborska (zaborska.monika.pl@gmail.com)

Introduction

Flat foot is a common postural defect, but its impact on the development of movement biomechanics in children is not fully understood.

Aim of the study

The aim of our study was to examine gait parameters in children with flat feet compared to a control group of children without this defect.

Materials and methods

We conducted a study among children aged from 9 to 11 years old, in which we examined gait parameters using a G-sensor device (BTS Bioengineering). The study group consisted of 36 children with flat feet, and the control group included 33 children without flat feet. We analyzed parameters such as gait cycle duration, percentage of step length, support and swing phase duration, single and double support duration, and the number of analyzed steps. We also compared the duration of analysis, cadence, velocity, and step length between the group with flat feet and the group of children with healthy feet.

Results

The study showed that 17.39% of children had left-sided flat feet, 7.25% had right-sided flat feet, and 27.54% were diagnosed with bilateral flat feet. Among boys, the percentage of children with flat feet was 59.38%, and among girls, it was 45.95%. Despite analyzing gait parameters between the study and control groups, no statistically significant differences were found.

Conclusions

Flat foot is a common postural defect in school-aged children, and it occurs more frequently in boys than in girls. However, no significant differences were observed in gait parameters between children with flat feet and the control group. These results suggest that flat foot does not have a negative impact on the biomechanics of movement.

[1925] Gait analysis in patients with symptomatic pes planovalgus following subtalar arthroereisis with the Spherus screw.

Authors: Bartosz Śnietka, Marcin Pelc, Damian Chruścicki

Affiliation: Department of Orthopedic and Trauma Surgery, University Hospital in Opole, University of Opole

Trustee of the paper: dr hab. n.med. Piotr Morasiewicz prof. UO

Corresponding author: Bartosz Tomasz Śnietka (barteksnietka@gmail.com)

Introduction

Pes planovalgus is one of the most common deformities of the skeletal system in children. If there are no symptoms due to flat foot, no treatment is required. Symptomatic flatfoot can cause pain, problems with wearing shoes, limping, limitation of physical activity and gait disturbances. When conservative treatment fails, various surgical techniques are used to treat symptomatic flatfoot. Removable implants inserted into the tarsal sinus, screws locked in the calcaneus, bone blocks placed between the talus and calcaneus, tendon extensions, tendon transfers, osteotomies of the talus or calcaneus, and arthrodeses are described. The available publications present arthroereisis surgical techniques consisting in placing a movable implant in the tarsal sinus or locking the screw in the calcaneus. There are no studies evaluating the use of the Spherus screw in the treatment of symptomatic flat foot.

Aim of the study

Evaluation of selected gait parameters in patients after treatment of pes planovalgus foot following subtalar arthroereisis using a Spherus screw.

Materials and methods

The study included 23 children who underwent surgical correction of symptomatic flat foot. The G-SENSOR device (BTS Bioengineering) was used to assess gait using the WALK protocol. The study consisted in measuring the following parameters: step length, gait cycle duration, duration of the transfer phase, duration of the single and double support phases.

Results

In the comparison of selected gait parameters of the operated limb to the healthy limb, there were no statistically significant differences, except for the length of the step (%) $48,84 \pm 3,74$ vs $51,15 \pm 3,74$ ($p < 0,05$).

Conclusions

The results obtained using G-SENSOR device (BTS Bioengineering) indicate the effectiveness of flat foot correction with the use of the Spherus screw. Normal gait parameters of the operated limb were noted.

[1979] Anatomical variability assessment of calcaneofibular ligament as the key to the success of lateral collateral ligament complex reconstruction surgery – pilot study.

Authors: Adrian Balcerzak, Kacper Ruzik

Affiliation: Medical University of Łódź / Department of Anatomical Dissection and Donation

Trustee of the paper: prof. UM, dr. hab. Łukasz Hubert Olewnik

Corresponding author: Adrian Andrzej Balcerzak (adrian.balcerzak@stud.umed.lodz.pl)

Introduction

The lateral collateral ligament complex (LCL) of the ankle joint consists of the calcaneofibular (CFL), anterior talofibular (ATFL) and the posterior talofibular ligaments (PTFL). According to classical anatomy textbooks the CFL origin is located on tip of the lateral malleolus and courses posteroinferiorly and medially to insert onto the lateral surface of the calcaneus. Ankle sprains are one of the most common musculoskeletal injuries which usually occur during sport activities. Most common mechanism of injury is inversion of the foot. CFL rupture combined with ATFL may be found in 20% of sprained ankles. Understanding the anatomy of ligament and the tools providing its reliable preoperative assessment are crucial for effective reconstruction procedure of LCL.

Aim of the study

The main aim of this project was to investigate morphology of calcaneofibular ligament and present classification, that allow a precise morphological description of its variability and topographic relationships. Second scope of interest was to evaluate compliance of the morphological features observed during anatomical preparation and in imaging diagnostics (USG).

Materials and methods

Twenty human fetuses (male, female, forty lower limbs) aged 18–38 weeks of gestation at death and forty adult human cadavers aged 38-85 years (male, female, eighty lower limbs) fixed in 10% formalin solution were examined. Dissection was performed with previously established protocol. Morphometric measurements were then obtained twice by two researchers. Ten ultrasound examinations of the area were performed. The results were analyzed and compared with the results of anatomical preparation.

Results

According to proposed classification system, in fetuses, Type I (band shape) was present in 52,5% of cases, Type II (Y-shape) in 17,5% of cases, Type III (V-shape) in 17,5% and Type IV (variable origin) in 12,5%. In adults – type I was present in 48,75% of cases, type II with two subtypes in 8,75%, type III – 21,25% and type IV with three subtypes – 21,25%. Compliance of certain morphological features visible in ultrasound compared with preparation findings was considered reliable.

Conclusions

The CFL is characterized by high morphological variability, the variants being associated with distinct clinical aspects. Evaluation of the correspondence of observations occurring during anatomical dissection and ultrasound examination. The introduction of a new, structured and detailed classification enabling reliable assessment of CFL anatomical aspects.

Pediatrics

Date: 21st April 2023, 15:00 PM

Coordinators:
Katarzyna Szawłoga
Elena Sztemberg

[1627] Clinical characteristics of lower respiratory tract infections induced by respiratory syncytial virus and rhinovirus in young children: a systematic review and meta-analysis

Authors: Izabela Orzolek

Affiliation: Warszawski Uniwersytet Medyczny, SKN przy Klinice Pulmonologii, Alergologii Wieku Dziecięcego i Pediatrii

Trustee of the paper: Dominika Ambrożej

Corresponding author: Izabela Orzolek (iza.orz77@gmail.com)

Introduction

Bronchiolitis is the leading cause of infant hospitalization and the most common lower respiratory tract infection at an early age. Two main viral agents causing bronchiolitis include respiratory syncytial virus (RSV) and rhinovirus (RV). RSV and RV elicit distinct cytopathic and immune responses and have different long-term outcomes. RV infection in infants has been associated with a higher risk for recurrent wheezing and childhood asthma. RSV has been reported to cause more severe course of the disease with oxygen demand. Although guidelines do not recommend testing for respiratory viruses in bronchiolitis, the viral agent may guide endotyping and personalized treatment and asthma preventive measures.

Aim of the study

To systematically compare the clinical and atopic characteristics of bronchiolitis in young children caused by RSV and RV.

Materials and methods

A search of electronic databases PubMed, Cochrane, and Embase was performed from inception to March 2022. Studies involving data on clinical presentation of children with RV and RSV-induced bronchiolitis younger than three years old were included. The Newcastle-Ottawa Scale was used to assess the risk of bias in the included studies. Our primary outcomes included wheeze at enrollment, personal history of eczema, parental atopy, and severity of bronchiolitis such as intensive care unit admission, fever, and ventilation support.

Results

1441 records were found, with 38 studies included in qualitative analysis and 30 in quantitative syntheses. The meta-analysis of 7 studies revealed that patients with RV-bronchiolitis more frequently have previous history of eczema (RR 0.70, 95% CI 0.55-0.91, $p < .05$). Based on 10 studies, RSV-positive patients required oxygen supplementation during hospitalization more often than RV-positive ones (RR 1.31, 95% CI 1.05-1.64, $p < .05$). No significant differences were found in the remaining primary outcomes.

Conclusions

Although personal history of eczema and oxygen supplementation was found to be significantly associated with either RSV or RV, the clinical picture and atopic history are not satisfactory evidence to objectively determine the viral etiology of bronchiolitis. Thus, the more accessible respiratory viral panels testing for RSV and RV, are eagerly anticipated to identify the group at risk of a more severe course of the disease and those at increased risk of developing asthma.

[1767] Influence of the COVID-19 pandemic on the prevalence and clinical course of IgA vasculitis in pediatric patients

Authors: Karol Poplicha*, Tomasz Ufniarski*, Jarosław Ucieklak, Małgorzata Mizerska-Wasiak *first author

Affiliation: 1 Science Students' Association at the Department of Pediatrics and Nephrology, Medical University of Warsaw 2 Department of Pediatrics and Nephrology, Medical University of Warsaw

Trustee of the paper: Małgorzata Mizerska-Wasiak

Corresponding author: Tomasz Andrzej Ufniarski (tomasz.eku@gmail.com)

Introduction

IgA vasculitis (IgAV) is an autoimmunological disease that more frequently affects the pediatric population. It is caused by the deposition of immune complexes built of antibodies immunoglobulin IgA in the small blood vessels. This pathomechanism causes changes in the skin (purpura), joints (arthritis), abdomen (abdominal pain) and kidneys (hematuria, proteinuria, chronic kidney disease). During the COVID-19 pandemic there has been an increase in prevalence of some diseases connected with changes in blood vessels.

Aim of the study

Assessment of the influence of the COVID-19 pandemic on the prevalence and clinical course of IgA vasculitis in pediatric patients.

Materials and methods

Retrospective review of medical records of patients presenting to one University Pediatric Hospital with IgAV in one year prior (group A) to the announcement of the state of COVID-19 epidemic in Poland (20.03.2020) and in the first year after (group B). We compared their laboratory results (urine: blood and protein, serum: creatinine, urea, IgA, IgG, IgM, complement C3 and C4, WBC, HGB, PLT, eGFR), hospitalization time, occurrence of preceding infection, SARS-CoV-2 infection status, clinical presentation, and allergy history. We compared the number of patients from group A and B to the total number of patients administered to the hospital in the same periods.

Results

88 patients were included in the study: 24 (68% male) during the first year of pandemic (group A) and 64 (58% female) in the year preceding (group B). Mean age was significantly higher ($p=0.003$) in group B (6.92 ± 3.43 years) than in group A (4.66 ± 1.88 years). Hospitalization time was significantly higher ($p=0.031$) in group A (8.88 ± 9.12 days) than in group B (5.58 ± 4.82 days). There were more patients with nephritis (IgAVN) in group A (20.8%) than in group B (9.4%) but the difference was not significant ($p>0.05$). There were no significant differences in the occurrence of preceding infection, allergies, lab results and the extent of involved biological systems. Only 3 patients had a confirmed SARS-CoV-2 infection. The ratio of the number of patients in group A and group B to the total number of patients admitted to the hospital was higher for group A than B, but not statistically significant ($p>0.05$).

Conclusions

The COVID-19 pandemic did not have influence on the prevalence of IgAV but the hospitalization time was higher during it. That can suggest a more severe course of the disease among admitted patients. Study requires further research in a wider time range.

[1792] TDI and -APSE values assessed in pediatric population to evaluate ventricular function in different ages

Authors: Mari Esho, Eric Brabner

Affiliation: Medical University of Gdansk. Department of Paediatric Cardiology and Congenital Heart Defects

Trustee of the paper: Supervisor Dr. Jarosław Meyer- Szary, PhD.

Corresponding author: Mari Esho (mariesho98@gmail.com)

Introduction

Assessment of myocardial motion with echocardiography tissue doppler imaging is widely used to evaluate ventricular function. TAPSE, MAPSE and SAPSE modality provide additional information about ventricular function. The latest data available on the distribution of tissue doppler indexes in healthy children range of age 1-18 was done around 20 years ago.

Aim of the study

Is preliminary analysis of TAPSE, SAPSE and MAPSE as well as TDI parameters in a range of age 0-18 and prior to future revision of reference values for these parameters. The focus was to assess the influence of age on TDI and -APSE.

Materials and methods

288 healthy children range of age 0-18 were examined with Vivid electrocardiography system with pediatric cardiologist using standard protocol. Statistical analysis was carried out with Wizard 2 software. Variables are reported in mm (-APSE) or cm/s (TDI) and as mean \pm SD if having normal distribution or as median (min-max) otherwise. Pearson correlation was used to assess correlation between variables. R² (p-value) are reported. P-value less than 0.05 was considered significant.

Results

Median age was 5.33 (0.0 max 18.0) years.

TAPSE was 21 \pm 5, SAPSE 12 \pm 3 and MAPSE 14 \pm 4.

All the parameters positively correlated with age: 0.27 (<0.001), 0.26 (<0.001) and 0.36 (<0.001) respectively.

LS` 10.2 \pm 29, SS` 8.3 \pm 15, RS` 0.12.9 \pm 23.

LE` 17.3 \pm 36, SE` 13.9 \pm 24, RE` 16.3 \pm 33.

LA` 6.3 \pm 23, SA` 6.4 \pm 2.2, RA` 9.2 \pm 3.9.

Respective parameters positively correlated with age -
LA` 0.05 (0.002), LS` 0.44 (<0.001), LE` 0.24 (<0.001)
SA` 0.09 (<0.001), SS` 0.28 (<0.001), SE` 0.25 (<0.001),
RA` 0.14 (<0.001), RS` 0.15 (<0.001), except for RE` (0.583).

Conclusions

Analyzed echocardiographic variables correlate with age preventing the use of singular cut-off value in the pediatric population. Proper reference / normative values in form of charts need to be developed.

[1842] Effectivity of Virtual Reality to Improve Balance, Motor Function, Activities of Daily Living, and Upper Limb Function in Children with Cerebral Palsy: A Systematic Review and Meta-Analysis of Randomized Controlled Trials

Authors: Shakira Amirah, Muhammad Fahd Abdurrahman, Mohammad Farrel Shaquille Handimulya

Affiliation: Universitas Indonesia

Trustee of the paper: Shakira Amirah

Corresponding author: Shakira - Amirah (Shakiraamirah@gmail.com)

Introduction

Cerebral palsy (CP) is a common motor disorder among children, affecting between 1 and 4 out of every 1000 children. This disorder can limit movement and interfere with a child's daily activities. Virtual reality (VR) is a technology that offers intensive practice for children and creates an interactive and motivating environment. VR can be customized by the therapist to provide individualized therapy and feedback. It has great potential to improve the quality of life for CP patients by offering a safe, enjoyable, and playful environment.

Aim of the study

This systematic review and meta-analysis aimed to evaluate the effectiveness of VR for children with CP.

Materials and methods

We followed the PRISMA guidelines and performed an extensive search of relevant literature through several databases including PubMed, Scopus, Embase, Wiley, and Proquest. The purpose of this search was to evaluate how effective virtual reality (VR) is in treating children with cerebral palsy (CP) up to the date of September 15th, 2022. We assessed the risk of bias using the Cochrane RoB 2 tool.

Results

Thirty-one randomized controlled trials with a total of 483 and 427 patients with CP were included in the intervention and control groups, respectively, in both qualitative and quantitative analyses. From all studies conducted, VR showed significant results where VR can improve balance (MD: 3.40 [2.06, 4.75]; $p < 0.00001$), motor function (MD: 3.73 [1.67, 5.79]; $p = 0.0004$), Wee-FIM (MD: 6.76 [3.17, 10.35]; $p = 0.0002$), CHAQ (MD: -0.50 [-0.81, -0.19]; $p = 0.002$), and Upper Limb Function (MD: 2.10 [1.89, 2.30]; $p < 0.00001$).

Conclusions

In general, with its advantages and excellent effectiveness, VR may improve functional mobility and the quality of life of children with CP.

[1889] Details and characteristics of pre-hospital pharmacotherapy of seizures in pediatric population

Authors: Mateusz Piętak, Barbara Kruczyk, Jan Stachurski PhD

Affiliation: Student Research Association of Pediatric Emergency Medicine, Medical University of Warsaw

Trustee of the paper: Jan Stachurski PhD

Corresponding author: Mateusz Piętak (mateusz.pietak98@gmail.com)

Introduction

Seizures are a frequent problem in the pediatric population. It is always a distressing situation for the parents when a seizure occurs – especially when it is the first episode ever.

Aim of the study

Due to its disturbing manifestation and acute onset, Emergency Medical Services (EMS) are usually called when a seizure develops. Therefore, it is important to be aware of potential manifestations, means of treatment, and complications of the seizure. That's why we decided to take a look into the details of seizure management in the out-of-hospital setting and in the emergency department (ED) of the Pediatric Hospital in Warsaw.

Materials and methods

We collected 2444 copies of the patients' documents transferred by the EMS to the ED throughout the year 2020 in this retrospective study. Then, we analyzed the documentation of every patient with an ICD code related to seizures.

Results

The mean age for a child being transported to an Emergency Department due to seizures by EMS was 74,4 months (6 years 2 months). There were 72 EMS interventions due to seizures, which accounted for 12,2% of all the 591 patients transported to the ED in the year 2020. 19 patients (26,4%) were admitted to the hospital, and 53 were discharged home after receiving essential help within the ED. All 72 patients received pharmacotherapy in the pre-hospital setting with the most common medication being diazepam. It was administered to 35 patients (48,6%). Other commonly used drugs included paracetamol – 19 patients (26,4%) and clonazepam – 9 patients (12,5%).

Conclusions

Febrile seizures are the most common type of seizure among younger children before the age of six, while other pathomechanisms are common behind seizures in older children. Febrile seizures by definition are associated with fever, while not being caused by an intracranial infection or another underlying disease. They are usually self-limiting and do not last long. If a seizure lasts longer than 5 minutes, or if there are 2 seizures within an hour without a return to full consciousness, a status epilepticus (SE) can be diagnosed – a major neurological emergency. It is estimated that a seizure lasting more than 30 minutes is likely to cause severe, long-term consequences. The sooner adequate pharmacotherapy is initiated, the higher chances are that the seizure does not develop into a dangerous SE with serious neurological deficits. Therefore it is of great importance to emphasize adequate treatment in the out-of-hospital setting, which is usually performed by EMS.

[1980] **Albumin and diuretic therapy treating paediatric patients with nephrotic syndrome**

Authors: Gintarė Gedvilaitė¹, Alvieta Steponavičiūtė¹, Jūratė Masalskienė²

Affiliation: 1Lithuanian University of Health Sciences, Academy of Medicine, Faculty of Medicine,
2Lithuanian University Lithuanian University of Health Sciences, Department of Children diseases,
Kaunas, Lithuania

Trustee of the paper: Jūratė Masalskienė

Corresponding author: Gintarė Gedvilaitė (gintare.gedvilaite@stud.lsmu.lt)

Introduction

Nephrotic syndrome (NS) is characterized by nephrotic range proteinuria, oedema, hyperlipidaemia and hypoalbuminemia. The main treatment of NS is corticosteroids. Albumin and diuretic therapy are considered as symptomatic treatment if patient has significant swelling, hypoalbuminaemia (< 20 g/l) and oliguria. About 50 % of pediatric patients diagnosed with NS have disease relapses.

Aim of the study

To evaluate albumin and diuretic therapy treatment features for pediatric patients with nephrotic syndrome during first episode and relapse.

Materials and methods

A retrospective analysis was performed based on the medical histories of the paediatric patients treated in LUHS Kaunas clinics Department of Children Disease in the period of 2017-2021. A total of 71 cases of NS were identified. 21 patients were excluded from the study due to missing data or not receiving albumin or diuretics. The study sample consisted of 50 patients, of whom 11 were diagnosed with the first episode of NS, 14 with the first relapse, and 25 with two or more relapses. Pearson χ^2 criterion was used in statistical analysis based on IBM SPSS Statistics program. Results were statistically significant if $p < 0,05$.

Results

Men accounted for 70,0 % of the subjects and women for 30,0 %. Mean of age was 6,36 (1-16). Oliguria on arrival at the hospital was more often observed in patients with first NS relapse ($p=0,034$). 63,6 % of patients with first NS episode, 71,4 % with NS first relapse and 72,0 % with 2 or more relapses were treated with albumin and diuretics combination. There was no statistically significant difference between first NS episode and relapse comparing the length of stay in hospital.

Conclusions

NS relapse is associated with more often prescribed albumin and diuretics combination but there is a lack of data to assess the reliability of the results.

Pharmacy

Date: 21st April 2023, 10:00 AM

Coordinators:
Oliwia Wróblewska
Karolina Baracz

Patronage:

Okręgowa izba Aptekarska Oddział Warszawa
Polskie Towarzystwo Studentów Farmacji Oddział Warszawa
Polskie Towarzystwo Farmaceutyczne
Łukasiewicz Sieć Badawcza

[1515] Quality evaluation of herbal products containing root of *Eleutherococcus senticosus*

Authors: Katarzyna Kupniewska (1), Andrzej Patyra (1,2), Anna K. Kiss (1)

Affiliation: (1) Department of Pharmaceutical Biology, Faculty of Pharmacy, Medical University of Warsaw, Medical University of Warsaw; (2) Institut des Biomolécules Max Mousseron, Université de Montpellier, CNRS, ENSCM

Trustee of the paper: Andrzej Patyra

Corresponding author: Katarzyna Kupniewska (kaszanus@gmail.com)

Introduction

Eleutherococcus senticosus (Rupr. & Maxim.) Maxim. also known as Siberian ginseng, Shigoka or Ciwujia is a shrub belonging to Araliaceae family that is native to Russia, China, Japan, and Korea. A root of *E. senticosus* was found to be an effective treatment of symptoms of asthenia, such as fatigue and weakness, and is included in the 10th Edition of European Pharmacopoeia.

Aim of the study

The aim of the study was to assess the quality of herbal products which contain the root of *E. senticosus*.

Materials and methods

The quality of 19 commercially available products containing the root of *E. senticosus* or its ethanolic extract in the form of cut root, capsules, tablets, and tinctures was evaluated according to the monograph in the 10th Edition of European Pharmacopoeia. The authenticity of the plant material was examined using microscopic anatomical analysis and thin-layer chromatography (TLC). Quantitative analysis of marker compounds syringin (eleutheroside B) and syringaresinol 4,4'-di-O- β -D-glucoside (eleutheroside E) was performed using high-performance liquid chromatography (HPLC). Results were compared with pharmacopoeial requirements and amounts labeled by the manufacturer.

Results

The samples tested had different qualitative and quantitative profiles. The concentrations of marker compounds varied greatly from product to product.

Conclusions

None of the samples were following the requirements listed in Pharmacopoeia, nor did they contain labeled amounts of eleutherosides. Furthermore, some samples did not contain any of the marker compounds. These results illustrate the importance of quality control and standardization of plant material.

[1523] **¹³C CP MAS NMR and Molecular Modeling Studies of Chromanyl Glycosides-promising derivatives of Vitamin E**

Authors: Łukasz Szeleszczuk, Aleksandra Kowalska

Affiliation: Medical University of Warsaw, Department of Organic and Physical Chemistry

Trustee of the paper: Łukasz Szeleszczuk

Corresponding author: Aleksandra Klara Kowalska (aleksandra.kowalska00@gmail.com)

Introduction

Vitamin E is a fat-soluble antioxidant which helps to protect cell membranes from reactive oxygen species. Vitamin E is essential to maintain proper functions of human body. New medical applications of Vitamin E are being intensively studied, including its potential role in the therapy of conditions such as cataracts, cardiovascular diseases, various types of cancer or Parkinson's disease.

Vitamin E is a group of 8 fat soluble compounds that include 4 tocopherols and 4 tocotrienols. α -Tocopherol is one of the form of vitamin E that is preferentially absorbed and accumulated in humans. Unfortunately, the low bioavailability of the known forms of α -Tocopherol is the main problem of this drug. One of the most promising solution of this problem is to convert α -Tocopherol into amphiphilic glycoconjugates. These derivatives, as prodrugs, would gain a good solubility in physiological fluids and a proper permeability through membranes and natural biological barriers e.g., blood-brain. It is obvious, that for understanding the molecular properties of any complex (bio)organic entity, a good knowledge of its structure is necessary

Aim of the study

Determination of the molecular structure of the chosen 4 derivatives of Vitamin E

Materials and methods

The newly obtained derivatives of Vitamin E have been synthesized by our collaborates. Then, to determine the molecular structure of those biomolecules, we have recorded the ¹³C CP MAS NMR spectra and SCXRD measurements. The physicochemical analysis has been supported by various molecular modelling methods

Results

Out of 4 studied compounds, the crystals of the proper size for SCXRD measurements have been obtained for only two (1 and 2). Therefore, to acquire the missing structural information for the other two (3 and 4) the NMR crystallography approach has been used. This included the registration of the ¹³C CP MAS NMR spectra, together with the calculations of NMR properties. This method has been validated on the two compounds (1 and 2) and then successfully used for the other two (3 and 4)

Conclusions

In this work the molecular structure of four newly obtained derivatives of Vitamin E, with the anticipated high bioavailability, has been studied. While for the two compounds the SCXRD measurements allowed to determine the crystal structure, for the other two the NMR crystallography approach was found to be successful. This study shows the great potential of combined physicochemical/computational analysis in the structural studies of active pharmaceutical ingredients

[1563] Effect of *Serpylli herba* extracts and their fractions on the inflammatory response of skin fibroblasts and wound healing in vitro

Authors: Aleksandra Michalak¹, Weronika Skowrońska¹, Katarzyna Bączek², Agnieszka Bazyłko¹

Affiliation: 1 Department of Pharmaceutical Biology, Faculty of Pharmacy, Medical University of Warsaw, 2 Department of Vegetable and Medicinal Plants, Institute of Horticulture Sciences, Warsaw University of Life Sciences

Trustee of the paper: dr hab. n. farm. Agnieszka Bazyłko

Corresponding author: Aleksandra Michalak (aleksandra.m329@gmail.com)

Introduction

In recent years, we have observed an increase in the incidence of dermatological diseases associated with prolonged inflammation, such as atopic dermatitis (AD). The skin becomes sensitive and susceptible to damage. Inflammation may be exacerbated by the penetration of irritants and pathogens into the skin, such as *Staphylococcus aureus*, colonization of which is found in about 90% of patients with AD. Topical glucocorticoids reduce inflammation, but due to their side effects, they cannot be used long-term. Therefore, it is necessary to search for new alternative therapies that are effective and safe for patients. *Serpylli herba* (SH) from *Thymus serpyllum*, used in traditional medicine to treat chronic wounds, eczema and itching, could be an attractive alternative.

Aim of the study

The aim of the study was to examine the effect of extracts from SHs from tree populations and their fractions on the secretion of pro-inflammatory cytokines by human skin fibroblasts, as well as to examine their effect on the migration of keratinocytes in the in vitro wound healing assay.

Materials and methods

The 60% (v/v) methanolic extracts of SH from three populations (Sejny, Ukraina and Koziół) were tested, as well as their fractions prepared with solvents of increasing polarity (dichloromethane, diethyl ether, ethyl acetate, n-butanol, water residue). Normal human dermal fibroblasts (NHDF) were stimulated with lipoteichoic acid (LTA) from *S. aureus*. After 24h of incubation with the tested samples, the levels of interleukin 6 and interleukin 8 in the supernatants were determined using ELISA tests. In the in vitro wound healing assay, the effect on the migration of immortalized human skin keratinocytes (HaCaT) to the site of injury was investigated. Tested samples were analysed at concentrations of 100, 50 and 5 µg/mL, which showed no negative effect on NHDF and HaCaT cell viability by the Neutral Red Uptake assay.

Results

Studies have shown that SHs extracts and their fractions reduce the inflammatory response of LTA-stimulated NHDF. The extract from the Koziół population had the strongest effect, at the concentration of 100 µg/mL it inhibited the secretion of IL6 and IL8 by 51 and 54%, respectively. From the fractions, dichloromethane, ethyl ether and ethyl acetate fraction showed the strongest anti-inflammatory effect. The tested samples increased the migration of keratinocytes to the site of injury.

Conclusions

Thymus serpyllum herb may be beneficial in wound healing and treatment of inflammatory dermatological diseases.

[1596] A salt-cocrystal transition studied by in silico methods.

Authors: Katarzyna Milcarz, Ewa Napiórkowska, Łukasz Szeleszczuk

Affiliation: Department of Organic and Physical Chemistry, Faculty of Pharmacy, Medical University of Warsaw

Trustee of the paper: dr hab. n. farm. Łukasz Szeleszczuk

Corresponding author: Katarzyna Joanna Milcarz (katarzyna.milcarz5@gmail.com)

Introduction

Solid forms of drugs are the most convenient and most popular among all types of active pharmaceutical ingredients (APIs). The most known and used solid forms are salts, organic basis and hydrates but relatively new forms of APIs are cocrystals. Under special conditions some salts could change into cocrystals, creating new polymorphs. This may affect properties like bioavailability or solubility and have an impact on pharmacokinetic profile. Factors like heating or pressing are common agents for polymorphic transitions occurring in pharmaceutical manufacturing. For example, 2-iodoaniline picrate is proven to exist in three forms: I and II are salts but the structure of III has not been registered yet. This last form is supposed to exist as cocrystal at higher temperature.

Aim of the study

The aim of the study was to evaluate a new method in modelling unknown structures like III form of 2-iodoaniline picrate and to explore the usage of in silico methods in prediction of behaviour of known API (salt I and II) under different conditions.

Materials and methods

Structures of polymorphs I and II were acquired from The Cambridge Crystallographic Data Centre. Preparation of cocrystal form was done, as described in literature, by a proton transfer. All polymorphs have been examined using density functional theory calculations (DFT). Geometry optimization was performed in CASTEP and DFTB+ software. To determine stability of forms calculations of thermodynamic functions and molecular dynamics simulations at different temperatures were performed. Additionally, to verify the computational results and hypothesis about form III, simulation of VIS and IR spectra were carried out to compare with experimental results.

Results

Data obtained from studies showed promising results in predicting stability of 2-iodoaniline picrate. Calculations helped to propose the possible structure of form III –not registered so far, as well as helped to interpret and compare experimental IR and VIS spectra with calculated ones, allowing to fill experimental data and learn on atomic level.

Conclusions

The application of DFT calculations gives us the ability to determine stability of crystal forms, examine dynamic of proton and predict phase transformation. Promising results of this method may very likely to be used on other cases of determination and description of salt-cocrystal transformation.

[1604] Molecular modelling studies of hydrates: the case of thiamine hydrochloride

Authors: Ewa Napiórkowska, Katarzyna Milcarz, Łukasz Szeleszczuk

Affiliation: Department of Organic and Physical Chemistry, Faculty of Pharmacy, Medical University of Warsaw

Trustee of the paper: dr hab. n. farm. Łukasz Szeleszczuk

Corresponding author: Ewa Anna Napiórkowska (napiorkowskaewa07@gmail.com)

Introduction

Thiamine (vitamin B1) is one of the most important water-soluble vitamins and it has been experimentally verified that thiamine hydrochloride monohydrate and hemihydrate are characterized by different vulnerability to dehydration. The presence of crystalline water can alter drug stability or solubility, therefore, the effectiveness and safety of pharmacotherapy. What is more, the usage of water in many manufacturing processes e.g. granulation and humidity during storage, could favour hydration. The reasons mentioned above justify the need to study the mechanisms of dehydration of hydrates of APIs.

Aim of the study

The aim of the study was to evaluate the efficiency of the application of periodic functional theory (DFT) calculations in hydrate modelling. The work was also conducted to support experimental research of thiamine hydrochloride hydrates with molecular modelling results

Materials and methods

The study has been performed by applying periodic density functional theory (DFT) calculations. The crystal structures from the Cambridge Crystallographic Data Centre have been chosen to simulate gradual dehydration for mono and hemihydrate. The next step was to optimize obtained structures, simulate their NMR spectra and compare the results acquired using ab initio and semi-empirical methods as well as with the experimental data. To include the temperature factor on dehydration, the ab initio molecular dynamic simulations under NPT conditions simulation have been performed.

Results

Obtained computational results are in good agreement with an experimental finding, that thiamine hydrochloride monohydrate and hemihydrate have significantly different behaviour during dehydration. The presented work has allowed us to clarify experimentally observed differences in the NMR spectra at the molecular level and show the need of performing calculations using ab initio methods to model hydrates.

Conclusions

As it is described in the example of thiamine hydrochloride hydrates, DFT periodic calculations are effective tools in modelling the hydrates and their vulnerability to dehydration. Exploring various solvatomorphic forms, including hydrates, can result in the discovery of novel API forms with improved properties. What is more, the application of theoretical studies in designing new solid forms of drugs can significantly speed up this process with the minimalization of costs.

[1629] Application of chemometric methods to predict the toxicity of xenoestrogens and microplastics towards embryos of the *Danio rerio* species

Authors: Adrianna Gabryś, Katerina Makarova

Affiliation: Medical University of Warsaw / Department of Physical Chemistry

Trustee of the paper: Katerina Makarova

Corresponding author: Adrianna Karolina Gabryś (adriannagabrys.lote@gmail.com)

Introduction

Zebrafish is cheap, robust in vivo model, widely used to study the toxicity of various compounds. The results obtained with zebrafish are often highly correlated with higher vertebrates.

Aim of the study

The aim of this study was to find a model that will predict the mortality of zebrafish embryos after exposure to xenoestrogen and microplastic compounds. Xenoestrogens are considered toxic for living organisms and can disrupt the functioning of the reproductive system, while microplastic can cause oxidative stress, changes in metabolic parameters and even compromise growth and reproduction of organisms in long-term exposure. The *Danio rerio* species is commonly used for studying the properties and toxicity of these compounds in vivo. In this study, we will test the predictions of zebrafish embryo mortality rates after exposure for 24, 48, 72, 96, and 120 hours, using various types of Artificial Neural Networks to identify the most effective one.

Materials and methods

The research involved the collection and analysis of data on zebrafish embryo mortality rates after exposure to xenoestrogens and microplastic compounds, as well as the distribution coefficients of the compounds. I performed molecular docking for microplastic compounds including parameters such as docking to estrogen receptors, logP, NMR structure of the compound and presence of ethanol or DMSO in the sample. Additionally, we used PCA methods to analyze the relationship between the collected data.

Results

The next stage of the project involves the creation of a model using Artificial Neural Networks.

Conclusions

Given the growing use of artificial intelligence in pharmacy, this model may prove to be useful for researchers planning in vitro toxicity testing of xenoestrogen and microplastic compounds on zebrafish embryos.

[1669] **Analysis of the advantages and disadvantages of ecological marketing in the pharmaceutical industry**

Authors: Matsiuk Olha, Sakhnatska Nataliia

Affiliation: Bogomolets National Medical University, pharmaceutical faculty

Trustee of the paper: Sakhnatska Nataliia

Corresponding author: Olha Matsiuk (sakhnatskaya@ukr.net)

Introduction

Today, in the conditions of the globalization of the planet, the issue of preserving the environment is acute. However, not only ecologists but also representatives of the pharmaceutical business are trying to fight environmental problems. They adhere to rational consumption of natural resources, conscious production, and disposal of pharmaceutical waste. Given the relevance of the above topic, it is worth analyzing the advantages and disadvantages of green marketing as a tool for the formation of competitiveness and sustainable development of pharmaceutical companies.

Aim of the study

The purpose of the work is to analyze the advantages and disadvantages of using the principles of ecological marketing in the activities of pharmaceutical companies.

Materials and methods

In the course of the research, content analysis, analysis of electronic resources, the method of generalization, and systematization of the obtained results were used.

Results

Aspects of environmental marketing are widely practiced by pharmaceutical companies striving for sustainable development and corporate social responsibility. They can make their products more attractive to consumers while reducing costs for packaging, transportation, energy, water consumption, etc. The advantages of using the principles of ecological marketing are that medicine's packaging causes less harm to the environment, but the production of such packaging takes much more financial resources and time. Distribution of medicines is carried out with the help of more ecological transport, however, the use of ecological transport slows down the speed of the transportation process and sometimes reduces the volume of the transported goods. The price of the product includes a price premium for ecological approaches, which enables the enterprise to adhere to an ecologically oriented strategy and develop it, but the disadvantage for the consumer is the increase in the price of the product due to the improvement of all previous stages by certain environmental standards.

Conclusions

So, after analyzing the possible advantages and disadvantages of ecological marketing, it can be noted that there are quite enough advantages for increasing the competitiveness and customer orientation of pharmaceutical companies and medicinal products, however, there are some disadvantages that cause mistrust and reluctance of the client to buy product.

[1672] Novel inhibitors of PEX14-PEX5 protein-protein interaction

Authors: Emilia Pykacz, Michał Nowacki, Maciej Dawidowski

Affiliation: Department of Drug Technology and Pharmaceutical Biotechnology, Faculty of Pharmacy, Medical University of Warsaw, 1 Banacha Street, 02-097 Warsaw, Poland

Trustee of the paper: Emilia Pykacz

Corresponding author: Emilia Pykacz (s078273@student.wum.edu.pl)

Introduction

Trypanosomatids are parasitic species that infect humans and mammals leading to severe mortality and economical losses throughout the world. *T. brucei* causes Sleeping Sickness, called also African Trypanosomiasis, while *T. cruzi* is the pathogen responsible for the Chagas Disease. Existing medication have serious side effects and are ineffective in the chronic phases of the diseases caused by the parasites.

Aim of the study

The aim of current research is to synthesize small-molecule inhibitors of PEX14-PEX5 protein-protein interaction (PPI). PEX14 and PEX 5 are the two crucial peroxins involved in the post-translational import of matrix enzymes into glycosomes in *Trypanosoma*.

Recently, it was found that blocking PEX14-PEX5 PPI in *Trypanosoma* parasites leads to ametabolic catastrophe causing death of parasite. Hence, inhibiting the PEX14-PEX5 complex formation emerged as a potential way to combat *Trypanosoma* infections.

Materials and methods

Dibenzo[b,f][1,4]oxazepin-11(10H)-one scaffold was identified through High-Throughput Screening as a promising PEX14 ligand. Ugi four-component reaction enables installation of complex residues derived from aldehydes and isocyanides onto the aforementioned scaffold resulting in potential increase of the compound's affinity to binding pockets of PEX14 protein.

Results

First tricyclic dibenzo[b,f]oxazepine PEX14-PEX5 PPI inhibitors were obtained. Some of them displayed mid-micromolar activities in disrupting the PEX14-PEX5 PPI.

Conclusions

It is concluded that the developed synthetic pathway can be a rich source of interesting compounds to address this difficult new molecular target.

[1873] The impact of painful diabetic neuropathy and coadministration of magnesium sulfate and/ or morphine on brain-derived neurotrophic factor (BDNF) level in periaqueductal gray (PAG) in rats

Authors: Natalia Wróblewska, Agnieszka Kowalczyk, Kamila Kulik

Affiliation: Medical University of Warsaw/ Department of Pharmacodynamics

Trustee of the paper: Przemysław Kurowski

Corresponding author: Natalia Wróblewska (natalia.wroblewska25@gmail.com)

Introduction

Brain-derived neurotrophic factor (BDNF) belongs to a family of neurotrophins, that are expressed in CNS. BDNF plays an important role in synaptic functions, neuroplasticity, growth, survival, and regeneration of neurons. Diabetic neuropathy is a neurodegenerative disorder that cause cell damage of the entire neuronal tree. The effectiveness of opioids in the treatment of diabetic neuropathy pain is limited. Several published studies shows that the coadministration of magnesium ions increase the analgesic activity of morphine in a model of experimental diabetic neuropathy.

Aim of the study

This study aimed to investigate the effect of treatment with magnesium sulfate and/or morphine on BDNF level in periaqueductal gray (PAG) in streptozotocin (STZ)-induced diabetic neuropathy in rats.

Materials and methods

The study was performed on the male Wistar rats. Diabetes was induced by intramuscular administration of STZ (40 mg/kg). Study animals were treated with magnesium sulfate (40 mg/kg intraperitoneally) and /or morphine (5 mg/kg intraperitoneally). The control group (healthy rats) received 0,9% NaCl intraperitoneally. PAG was separated from the isolated brain. The changes in BDNF content in the brain tissue was determined with the enzyme-linked immunosorbent assay (ELISA).

Results

The experiment showed a significant decrease ($p < 0,001$) in BDNF level in PAG in diabetic groups (STZ-treated) compared with control (healthy rats). Treatment with magnesium sulfate enhanced ($p < 0,05$) BDNF level compared with non-treated STZ rats. Administration of morphine and coadministration of magnesium sulfate and morphine had no impact on BDNF level compared with non-treated STZ rats.

Conclusions

In diabetic neuropathy, BDNF expression in PAG was alleviated. The results suggest that a diabetic neuropathy state might cause loss of neurotrophic factors due to irreversible neuronal damage. It is possible that, deficiency in levels of BDNF could impaire regeneration ability. Treatment with magnesium sulfate enhanced BDNF levels in PAG. Therefore, magnesium ions, due to antagonist properties to NMDA receptor channels, may be able to reduce the risk of excitotoxicity caused by glutamate and have a neuroprotective effect through BDNF up-regulation.

The study was supported by the Medical University of Warsaw (grant number: FW3/3/F/MG/N/21).

PhD Basic & Preclinical Science

Date: 22nd April 2023, 15:15 PM

Coordinators:

Pawel Tyrna

Aleksandra Kowalska

Patronage:

Polskie Towarzystwo Immunologii Doświadczalnej i Klinicznej

Polskie Towarzystwo Genetyczne

Polskie Towarzystwo Biofizyczne Warszawskie Stowarzyszenie Biotechnologiczne

„Symbioza”

Narodowy Instytut Onkologiczny im. Marii Skłodowskiej-Curie - Państwowy Instytut

Badawczy

[1542] The influence of extracellular vesicles from mesenchymal stem cells on bladder cancer cells – preliminary research.

Authors: Karolina Kowalska, Małgorzata Maj, Łukasz Kaźmierski, Anna Bajek

Affiliation: Nicolaus Copernicus University in Torun, Collegium Medicum in Bydgoszcz/ Tissue Engineering Department, Faculty of Medicine

Trustee of the paper: Małgorzata Maj

Corresponding author: Karolina Magdalena Kowalska (karolina99kowalska@gmail.com)

Introduction

Mesenchymal stem cells from adipose tissue (ASCs) are multipotential cells, which may be isolated by non-invasive methods. Therapies based on ASCs are used in tissue regeneration and wound healing. As all living cells ASCs secrete extracellular vesicles (EVs), small particles (exosomes: 30-150nm, microvesicles: 100-1000nm) involved in cell-cell communication. The content of EVs reflects the content of the releasing cell. They carry bioactive molecules which may affect close and distant cells. Recent studies show that soluble mediators from the tumor microenvironment affect the phenotype of ASCs and change released EVs. This study verifies the reverse interaction: the influence of EVs from ASCs on bladder cancer cells.

Aim of the study

Aim of a study was to determine how ASCs- derived exosomes affect cancer cells viability.

Materials and methods

To isolate EVs we used a conditioned medium from ASCs after 72h culture. To compare isolation efficiency two methods were used. The first uses Total Exosome Isolation Reagent (Invitrogen) and the second method uses Capturem Extracellular Vesicle Isolation Kit (Takara Bio). The exosome protein content was measured using the spectrophotometric method. To confirm that isolated particles are exosomes Exo-Check Exosome Antibody Array was used. Finally, the vitality of four bladder cancer cell lines (5637, HB-CLS-1, HT-1376, T24) after 72h incubation with EVs (50, 100, 200 ug/ml) was investigated using Cell Counting Kit-8 (Sigma).

Results

Spectrophotometric measurement indicated that Total Exosome Isolation Reagent allowed the isolation of significantly more exosomes than Capturem Extracellular Vesicle Isolation Kit. Isolated particles expressed markers characteristic of exosomes. Depending on the cell line, the vitality of cancer cells was modified after incubation with exosomes.

Conclusions

The exosome isolation method based on Total Exosome Isolation Reagent proved more effective than Capturem Extracellular Vesicle Isolation Kit. EVs from ASCs influence bladder cancer cells biological characteristics. Therefore, they may affect the tumor environment.

[1546] Preparation and spray drying of liposomes - Different protectants evaluation

Authors: Hořavová Hana (1), Zvonar Pobirk Alenka (2), Sterle Zorec Barbara (2)

Affiliation: (1) Masaryk university Brno, Faculty of pharmacy, Department of Pharmaceutical technology; (2) University of Ljubljana, Faculty of pharmacy, The Chair of Pharmaceutical Technology

Trustee of the paper: Sterle Zorec Barbara

Corresponding author: Hana Hořavová (422926@muni.cz)

Introduction

Liposomes represent nanoscale spherical vesicles consisting of a phospholipid bilayer surrounding an aqueous core. They are very potent modern delivery system, however, their physical and chemical instability in aqueous dispersions can be problematic. Converting the dispersions into liposomal dry powders could be a solution. One of the most used technologies to produce dry powders is spray drying. To achieve good stability of liposomes during this process, it is important to find a suitable protective material.

Aim of the study

This study aimed to optimize the preparation process of liposomes and to investigate the ability of different protectant materials to maintain the size of liposomes during the spray drying process.

Materials and methods

Liposomes were prepared by the hydration of a thin film formed by evaporation of chloroform solution of Lipoid S PC-3 plus cholesterol (85:15 mg). For hydration Milli-Q water was used (4, 8, or 12 ml) at a temperature of 65 °C. For size homogenization a sonication probe was used. The resulting suspension was divided into 1, 2, 4, or 6 ml aliquots, and 20, 30, 40, or 50 sonication cycles were performed, respectively. Liposome DLS size measurements were performed using the Zeta sizer.

Then 5 thin films were hydrated with an aqueous solution containing lactose, trehalose, maltodextrin, sucrose, or sorbitol respectively. After the application of 50 sonication cycles of 5 ml aliquots, the dispersions were spray dried using Buchi Mini spray drier B-290. The products were rehydrated with water and DLS measurement was performed.

Results

A higher number of sonication cycles leads to better homogenization. It is possible to increase the sonication volume, but preferably not more than 6 ml to keep the polydispersity index (PI) acceptable. With higher hydration medium volume, the size of liposomes and PI decrease. The liposomal dispersions were stable for 24. The changes in liposome size with lactose, trehalose and sucrose were minimal (+14.7%, -2.2%, and +7.2% respectively) and the PI was very low. The size of liposomes in maltodextrin increased significantly (by more than 2-fold) and the system was polydisperse. Spray drying of the sorbitol dispersion did not result in particles under the used conditions. In all samples except lactose and sucrose, sediment was visible after rehydration.

Conclusions

We were able to prepare optimal liposomal dispersions and find suitable carbohydrates to protect liposomes from stress during spray drying, for possible future drug incorporation.

[1556] Thermoreversible hydrogels as potencial material for tissue engineering

Authors: Marta Tuszyńska, Anna Bajek, Joanna Skopińska-Wiśniewska

Affiliation: Department of Tissue Engineering, Ludwik Rydygier Collegium Medicum in Bydgoszcz Nicolaus Copernicus University in Torun

Trustee of the paper: Prof. Anna Bajek

Corresponding author: Marta Tuszyńska (503348@doktorant.umk.pl)

Introduction

Cartilage damage is observed increasingly in association with joint injuries alone or in combination with other wounds. The poor healing capacity of the damaged cartilage leads to significant disability and pain, and over time it can develop into osteoarthritis (OA). In recent years, injectable therapeutic agents based on biomaterials have gained a lot of interest in cartilage and joint damage treatment due to their minimal invasiveness and ability to repair irregular defects. However, the design and control of injectable bioactive biomaterials for effective treatment remain challenging. Tissue engineering combined with hydrogel-based biomaterials is a promising strategy for repairing damaged cartilage tissue. Poloxamers are nonionic triblock copolymers composed of a central hydrophobic polypropylene chain surrounded by two hydrophilic polyoxyethylenes chains. An attractive feature of poloxamer-based solutions is their temperature-dependent self-assembly and thermo-gelling behavior.

Aim of the study

The study aimed to test the gelation temperature and biocompatibility of Poloxamer 407 and 188-based biomaterials.

Materials and methods

The experiment consisted of 30% poloxamer 407 and 10%/15% poloxamer 188 based hydrogels, DMEM / F12K medium containing 10% FBS, and 1% mixture of antibiotics (identical to the 2D culture medium) and mouse embryonic fibroblasts - 3T3 cells. Appropriate amounts of polymers extracts were prepared, and the MTT test was performed based on ISO 10993 standard. Gelation temperatures in the range from 20-40 °C on a magnetic stirrer with a temperature sensor, were tested.

Results

The obtained results showed that the tested combinations of poloxamers 407_188 in various percentages achieved gelation temperatures close to the temperature of the human body. The conducted cytotoxicity studies demonstrated the biomaterials themselves did not negatively affect the metabolic activity of 3T3 cells.

Conclusions

Based on the conducted research, poloxamer-based gels presented promising results for future medical applications. The gelation temperature and cytotoxicity values of the obtained hydrogels are suitable for further research on injectable hydrogels for cartilage regeneration.

[1583] CD37 as a molecular target for CAR-T cells against chronic lymphocytic leukemia

Authors: Aleksandra Kusowska, Marta Krawczyk, Magdalena Winiarska, Małgorzata Bobrowicz

Affiliation: Department of Immunology, Medical University of Warsaw, 02-927 Warsaw, Poland

Trustee of the paper: Małgorzata Bobrowicz

Corresponding author: Aleksandra Maria Kusowska (aleksandra.kusowska@wum.edu.pl)

Introduction

CD37 is a tetraspanin predominantly expressed on the surface of mature B cells. Recent studies demonstrate that CD37 is involved in the regulation of B-cell survival and proliferation, apoptotic signaling, and tumor evasion. CD37 has recently gained attention as a target for chimeric antigen receptor (CAR)-T cells and has proven efficacy in preclinical studies in B- and T-cell malignancies. CD37 is stably expressed across multiple B-cell malignancies, however, its levels are exceptionally high on the surface of chronic lymphocytic leukemia (CLL) cells. In the majority of cases, CLL can be managed thanks to the advent of targeted therapies, however, there is a small population of patients not achieving complete response. For those patients, CAR-T cells offer an attractive alternative to standard treatment options.

Aim of the study

To investigate the utility of CD37 as a target for CAR-T cells to be used in CLL.

Materials and methods

We performed quantitation of surface expression of B-cell specific proteins CD19, CD20, and CD37 on CLL cell lines – HG-3, Mec-1, PGA, and on 20 primary CLL samples. Further, we evaluated the sensitivity of CLL cell lines and patient-derived CLL cells to anti-CD19, anti-CD20, and anti-CD37 CAR-T cells. For this purpose, healthy donor peripheral blood mononuclear cells stimulated with anti-CD3/CD28 mAbs were used as a source of T cells for transduction with CAR constructs. In cytotoxicity assays, CLL cell lines or primary CLL cells were stained with CellTrace Violet and incubated overnight with different effector-to-target ratios. Cell viability was assessed using flow cytometry upon propidium iodide staining.

Results

By analyzing Leukemia MILE study data we observed that across multiple hematological malignancies, CD37 levels are exceptionally high in CLL cells. Moreover, by phenotyping CLL cell lines and patient-derived CLL cells we demonstrate that CD37 expression is high and quantitatively superior to CD19 and CD20. We then investigated the potency of CAR-T cells against CLL cells. Among the three CARs tested, CD20 CAR-T cells were the least effective. In contrast, CD37 CAR-T cells demonstrated profound cytolytic activity against CLL cell lines and primary CLL cells comparable to the efficacy of CD19 CAR-T cells currently used in clinics.

Conclusions

Targeting CD37 via CAR-T cells is a promising therapeutic option for CLL patients and an attractive alternative to CD19-directed therapies. Further in vivo studies are warranted.

[1621] Revealing genetic heterogeneity and morphological changes at single-cell level of microglia after depletion and repopulation

Authors: Zuzanna M. Luczak-Sobotkowska^{1*}, Patrycja Rosa^{1,2*}, Maria Banqueri¹, Natalia Ochocka¹, Aleksander Jankowski², Bozena Kaminska¹,

Affiliation: 1 Laboratory of Molecular Neurobiology, Nencki Institute of Experimental Biology of the Polish Academy of Sciences, 02-093 Warsaw, Poland; 2 Faculty of Mathematics, Informatics and Mechanics, University of Warsaw, 02-097 Warsaw, Poland

Trustee of the paper: Bozena Kaminska

Corresponding author: Zuzanna Małgorzata Łuczak-Sobotkowska (z.luczak-sobotkowska@nencki.edu.pl)

Introduction

Microglia (MG) are myeloid cells residing in the central nervous system that carry out many functions in homeostatic states and disease. Their survival depends on colony stimulating factor 1 receptor (CSF1R) signaling. A common way to study a role of MG in a given process is its genetic or pharmacological depletion. For this purpose CSF1R inhibitors (i.a. BLZ-945) that in mice deplete 99% of microglia in 21 days are used. After cessation of the treatment, a normal density of MG is restored within 7 days in adult mice.

Aim of the study

The aim of this study was to investigate the origin and functionality of repopulated microglia (MG) using single-cell RNA sequencing (scRNA-seq) and immunohistochemistry.

Materials and methods

We used Cx3cr1-CreER::Rosa-floxedTom transgenic mice having red fluorescent MG. Each animal received 200 mg/kg dose of BLZ-945 in peanut butter or peanut butter every day for 21 days. After this time, the administration of BLZ-945 was stopped. Animals were left to recover for 7 days. Brains were fixed in PFA for immunohistochemical staining (IHC). Sections were stained for TMEM 119 (a MG marker) and Ki67 (a proliferation marker). Confocal images were analyzed by the Imaris Software. ScRNAseq of immunosorted CD11b⁺ was conducted and data were analyzed with computational methods.

Results

Treatment with BLZ-945 resulted in almost complete MG depletion (<1%) after 21 days. Repopulation was complete in 7 days, as demonstrated by TMEM 119 IHC and flow cytometry. Interestingly, confocal analysis of microglial cell body and branching revealed that repopulated MG display distinct morphology. ScRNAseq showed numerous functional cell clusters but the main myeloid clusters in control and repopulated MG showed the same functionality. We noticed significant changes in gene expression, which define the premature state of microglia consistent with the presence of the progenitor MG (Pre-MG). Certain genes engaged in inflammatory processes were activated in the repopulated MG. Gene Ontology analysis showed the enrichment of inflammatory pathways in Pre-MG.

Conclusions

We present the detailed, single-cell transcriptomic analysis and morphology evaluation of repopulated MG. Our data confirm that repopulated MG renew from the preexisting microglial progenitors and reconstitute functional clusters in the brain.

Studies were supported by a grant ERA-NET-NEURON/18/2018 from the National Center of Research and Development, Poland and by the Polish National Agency for Academic Exchange (PPN/PPO/2019/1/00042).

[1628] Role of RNF43 in Common Bile Duct Cancer

Authors: Joanna Madej, Chiara Falcomata, Stefanie Baerthel, Angelika Kroemer, Christan Veltkamp, Katja Peschke

Affiliation: Klinikum rechts der Isar, Munich

Trustee of the paper: Prof. Dr. med. Dieter Saur (Preliminary results from not submitted paper)

Corresponding author: Joanna Madej (joanna.madej.123@gmail.com)

Introduction

Common Bile Duct (CBD) cancer is a rare human malignancy arising outside of the liver and forming cancerous lesions inside the bile duct. The 5-year survival rate of CBD is 30%. Due to a lack of appropriate biomarkers as well as difficulties in diagnosing CBD early on, the majority of patients are considered unrespectable and receive radiotherapy or chemotherapy. However, the mechanisms driving CBD onset and progression are still unknown. In order to discover a new relevant set of genes possibly involved in CBD carcinogenesis, piggyBactransposon mutagenesis screening was performed in genetically engineered mouse models with PIK3CAH1047R/+ background.

Aim of the study

Characterization and role of ring finger protein 43 (RNF43) in CBD cancer as well as translation importance of RNF43 loss of function for targeted therapy in CBD cancer.

Materials and methods

Bioinformatic analysis of CIS (common insertion sites) pattern based on piggyBactransposon mutagenesis screening for in silico study of relevance and role of RNF43 in CBD development. In order to elucidate the consequences of RNF43 loss of function, we crossed mice with a hetero- and homozygous knockout (KO) of RNF43 into the PIK3CA-mutant mice. Drug screen performed on the establishment of organoid culture from murine CBD to pinpoint the best targets for further studies on targeted therapies in CBD cancer.

Results

The ring finger protein 43 (RNF43) was identified as one of the top genes in this screening, indicating its importance in CBD development. Preliminary results further validated the tumor suppressive role of RNF43 in CBD, since RNF43 KO resulted in significantly shortened survival compared to RNF43 wild-type mice due to the development of CBD cancer. Genomic and transcriptomic analyses are performed to identify possible signaling pathways involved in CBDcancer progression upon RNF43 knockout. Furthermore, organoid culture was established for conducting in vitro assays such as screening for possible drug targets as well as WNT reporter activity assay.

Conclusions

In conclusion, using the piccyBac transposon screening allowed the identification of novel gene candidates involved in CBD development. In addition, our data support the tumor suppressive role of RNF43 in CBD cancer due to a shortened survival in RNF43 KO mice. Further experiments might unravel possible vulnerabilities upon RNF43 loss of function for targeted therapy in CBD.

[1650] The effect of adoptive cell therapy in combination with anti-PD-1 treatment on T cells activation in patients with non-operative lung adenocarcinoma-preliminary research

Authors: Irena Wieleba, Kamila Wojas-Krawczyk, Paweł Krawczyk

Affiliation: Department of Pneumonology, Oncology and Allergology

Trustee of the paper: Scientific Reports Nature

Corresponding author: Irena Wieleba (i.m.wieleba@gmail.com)

Introduction

Most of lung cancer patients are diagnosed in advanced non-operative stage of disease and due to the lack of driver mutations could not benefit from targeted therapy. Those patients could be treated mainly by chemotherapy, immune-chemotherapy or immunotherapy based on PD-L1 expression. Introduction of immune checkpoint inhibitors into lung cancer therapy improved the patients' outcomes, however, the high frequency of severe adverse effects during treatment remains a significant problem. Regarding adoptive cell therapy, despite its' sufficient safety profile, only short-term positive response was observed. Therefore, the crucial issue is to optimize immune response when combined therapy (adoptive and immunotherapy) could be applied.

Aim of the study

Aim of the study was to prove that combination of adoptive cell therapy with anti-PD-1 monoclonal antibody may involve optimal reactivation of T cellular antitumor response. The study aimed to indicate optimal dose of anti-PD-1 drug for in vitro activation of autologous T cells differentiation.

Materials and methods

Peripheral blood was collected from eligible patients in Department of Pneumonology, Oncology and Allergology, Medical University of Lublin (Poland) prior to treatment initiation. CD14⁺ and T cells were isolated with magnetic beads based on MACS[®] technology. Generation of dendritic cells from CD14⁺ was performed according to our protocol. The ratio of T lymphocytes to mature dendritic cells was 10:1. Nivolumab concentrations were calculated based on pharmacokinetics information included in the product safety data sheet. The mixed cultures were conducted for 48 h, and after that, the cells' immunophenotype was analyzed with flow cytometry. Bioethical Committee at the Medical University of Lublin. (KE-0254/318/2018) had approved the study.

Results

Generated dendritic cells were able for antigen presentation. A significant increase in the expression of early activation markers and the CD28 molecule was observed in both CD4⁺ and CD8⁺ subpopulations of lymphocytes. Differentiation of CD4⁺ lymphocytes towards Th1 cells were observed based on intracellular marker expression. Significantly increase in the intracellular CD107a expression, typical for CD8⁺ and NK lymphocytes with cytolytic properties, was found.

Conclusions

Conducted data showed no deep extinction of patients' immune response and indicated minimal effective dose of nivolumab for in vitro examination. Full description: doi.org/10.1038/s41598-022-12136-1

[1703] *Paulownia tomentosa* extracts fighting against staphylococcal biofilm formation

Authors: Gabriela Škovranová¹, Lenka Molčanová¹, Blaž Jug², Anja Klančnik², Sonja Smole-Možina², Alice Sychrová¹

Affiliation: ¹Department of Natural Drugs, Faculty of Pharmacy, Masaryk University, Czech Republic
²Department of Food Science and Technology, Biotechnical Faculty, University of Ljubljana, Slovenia

Trustee of the paper: PharmDr. Alice Sychrová, Ph.D. and PharmDr. Gabriela Škovranová

Corresponding author: Gabriela Škovranová (gabriela.skovranova@gmail.com)

Introduction

Staphylococcus aureus is a pathogen responsible for skin and soft-tissue infections, which are challenging to therapeutic treatment especially if biofilm occurs. [1] Plant-derived natural compounds including prenylated phenolics provide a significant source of potent antimicrobial agents. [2]

Aim of the study

The aim of the study was to find active plant formulations from *Paulownia tomentosa* fighting against staphylococcal infections.

Materials and methods

Ethanol extract from fresh fruits of *Paulownia tomentosa* was divided by liquid-liquid extraction, analyzed by HPLC-UV-DAD, and with three prenylated flavonoids investigated for their antibacterial activity. The minimum inhibitory concentration (MIC) and growth curves were described by kinetic measurement. The morphology of bacteria was observed using TEM. Plant formulations were examined for quorum-sensing inhibition including the adhesion to the specific surface by counting the colony-forming units (CFU)/mL and inhibition of the intercellular signalization by measuring the bioluminescence.

Results

Ethanol extract was rich in active compounds, but prenylated flavonoids were dominant in the chloroform fraction. MIC of ethanol extract, chloroform fraction, and three flavonoids showed significant antimicrobial activity, while lower concentrations prolonged the lag phase. Selected compounds reduced the adhesion of bacteria to the abiotic surface (42–86%), and also the measurement of bioluminescence showed inhibition (47–66%) of intercellular signaling in bacterial suspension treated with plant formulations at 0.25×MIC.

Conclusions

To sum up, *Paulownia tomentosa* fruits (rich in prenylated flavonoids) are promising candidates for the treatment of staphylococcal infections, regarding their strong antibacterial and antibiofilm activity. The study was supported by Masaryk University (MUNI/A/1212/2022).

References:

- [1] Moormeier DE, Bayles KW. *Staphylococcus aureus* biofilm: a complex developmental organism. *Mol Microbiol.* 2017;104(3):365-376
- [2] Navrátilová A, Nešuta O, Vančátová I, et al. C-Geranylated flavonoids from *Paulownia tomentosa* fruits with antimicrobial potential and synergistic activity with antibiotics. *Pharm Biol.* 2016;54(8):1398-1407

[1725] Impact of *Bifidobacterium longum* sp. *infantis* cell-free culture supernatant on biofilm formation by *Fusobacterium nucleatum*

Authors: Kinga Markowska

Affiliation: Medical University of Warsaw, Chair and Department of Medical Microbiology

Trustee of the paper: Anna Majewska

Corresponding author: Kinga Aleksandra Markowska (kinmarkowska@gmail.com)

Introduction

Fusobacterium nucleatum is an anaerobic oral commensal and periodontal pathogen, which is associated with serious diseases, such as cardiovascular disease, ulcerative colitis, and colon cancer. Bacteria mostly grow as biofilms attached to dental surfaces and others tissues. *F. nucleatum* is considered a 'bridge organism' that facilitates colonization of other bacteria by coaggregation-mediated mechanisms *inter alia* by making the environment conducive for oxygen-intolerant anaerobes. The use of probiotics is a promising strategy to ameliorate disorders associated with infections complicated by biofilm.

Aim of the study

The study aims to evaluate the effect of supernatant from *Bifidobacterium longum* sp. *infantis* DSM 20090 on the biofilm formed *in vitro* by a reference and clinical strain of *Fusobacterium nucleatum*.

Materials and methods

A single species of *F. nucleatum* (clinical strain) and *F. nucleatum* ATCC 25586 (reference strain) biofilms were grown anaerobically at 37°C for 48h, 72h, and 96h with the addition of 25% and 50% concentration of supernatant from *B. longum* on 96-well plastic plates. Biofilm mass was quantified using crystal violet (CV) staining and absorbance was measured at 492 nm. The results were compared with untreated culture. Biofilm architecture and thickness were analyzed by CLSM (confocal laser scanning microscopy).

Results

Biofilm mass produced by the clinical strain *F. nucleatum* was inhibited by a 25% concentration of supernatant (reduction of 26% biofilm mass at 48h, 72h, and 96h compared to controls) and 50% supernatant of *B. longum* at 48h, 72h, and 96h (40%, 38%, 44%, respectively). The biofilm mass of *Fusobacterium nucleatum* ATCC 25586 was reduced only in 96h influenced by 50% supernatant of *B. longum* (only of 5% compared to the control of 96h). In all other tested configurations, biofilm production increased under influence of *B. longum* supernatants.

Conclusions

The supernatant of *B. longum* inhibits formation of the biofilm by the clinical strain of *F. nucleatum* but did not reduce biofilm mass produced by the reference strain. There is a need for further research to understand the effect of supernatant components on biofilm formation and the differences in formation between these strains.

[1735] The role of DNA polymerase II in pathogenesis of uropathogenic *Escherichia coli*

Authors: Anna Bętkowska

Affiliation: Centre for Postgraduate Medical Education, Department of Cell Biology and Immunology

Trustee of the paper: dr hab. Damian Gawęł, prof. CMKP

Corresponding author: Anna Bętkowska (anna.betkowska@cmkp.edu.pl)

Introduction

Urinary tract infections (UTIs) are one of the most common infections affecting the human population, particularly women. The main etiological factor of UTI is uropathogenic *Escherichia coli* (UPEC). During infection, a complex immune response of the host cells results in the destabilization of the bacterial genome, leading to the activation of stress responses, including the SOS system. It has been shown that DNA polymerases activated as part of the SOS response play an important role in bacterial survival strategies, including acquiring antibiotic resistance. Nevertheless, their role in this process is still unclear. Especially, data concerning the role of polymerase II DNA (Pol II) in the maintenance of genome stability and UPEC pathogenesis in vivo remains unknown.

Aim of the study

The study aimed to investigate the role of DNA polymerase II in maintaining bacterial genome stability and pathogenesis of *Escherichia coli*.

Materials and methods

Non-pathogenic *E. coli* strains (MG1655) and uropathogenic strains (UTI89 and CFT073), as well as a bladder carcinoma cell line 5637, were used in the study. The lambda red-mediated homologous recombination was used to generate a Pol II DNA-deficient (Δ polB) strain and a mutant lacking Pol II exonuclease activity (polBexo-). The obtained constructs were subjected to mutational frequency analysis and methyl methanesulfonate (MMS) treatment to establish the role of Pol II DNA in UPEC cells in stress conditions in vitro. The gentamicin protection assay was used to determine the ability of the Pol II mutants to infect and form intracellular colonies within bladder epithelial cells (in vivo conditions). Data were analysed using GraphPad Prism and the statistical significance was determined at $p < 0,05$.

Results

The obtained results indicate that the Pol II DNA replicase presents antimutator activity in the tested *E. coli* strains. It was also observed that lack of active Pol II DNA significantly increases the survival of UPEC subjected to MMS treatment. Most importantly, the inactivation of Pol II DNA resulted in a decrease in the number of intracellular colonies formed by UPEC in infected bladder epithelial cells.

Conclusions

The study further elucidates the role of *E. coli* DNA polymerase II in UPEC pathogenesis and suggests that Pol II DNA may constitute a novel virulence factor of UTIs. Lack of its activity leads to a significant reduction of the infectious potential of uropathogenic *E. coli*.

The study was funded by a National Science Centre Grant nr 2019/35/B/NZ6/03996.

[1769] Evaluation of the effect of BCAA's on the proliferation, glucose-lactate metabolism and expression of the BCKDC in human lung cancer cells

Authors: Julian Chrzanowski, Wojciech Graboń, Marta Struga, Agnieszka Cudnoch-Jędrzejewska

Affiliation: Chair and Department of Biochemistry, Chair and Department of Experimental and Clinical Physiology, Medical University of Warsaw

Trustee of the paper: Julian Chrzanowski

Corresponding author: Julian Chrzanowski (julian.chrzanowski.md@gmail.com)

Introduction

Branched chain amino acids (BCAA) play an important role in cancer progression, both as building component of tissues and as donors of carbon skeletons used for energy production. The branched α -keto acid dehydrogenase complex (BCKDC) is the next step in this pathway, which plays an important role in providing energy substrates necessary in the metabolism of cancer cells. An interesting fact is that this complex is regulated by BCAAs, which can affect the activity of the enzyme by covalent modification. Therefore, it seems reasonable to investigate the effect of BCAA supplementation on cancer cell proliferation and BCKDC expression.

Aim of the study

Thus, the aim of this study was to determine the expression of BCKD complex before and after BCAA supplementation. The influence of BCAA's on the rate of cell proliferation, concentration of amino acids as well as glucose and lactate in cancer and normal cells was also examined.

Materials and methods

The study was performed on human lung cancer cells A549 and human normal keratinocytes HaCaT cultured with various concentration of BCAAs: leucine (Leu), isoleucine (Ile) and valine (Val) in different combinations. Glucose and lactate levels were determined colorimetrically, amino acids by HPLC, proliferation by TB method and expression of BCKD by Western blot.

Results

We observed the highest rate of proliferation of cancer cells A549 after supplementation with Leu in concentration 1,5 times higher than physiological level. The antiproliferative effect was pronounced after treatment with mixture of all tested BCAAs whereas in normal cells HaCaT the mixture of amino acids enhanced proliferation. The highest BCKD intensity was observed after leucine supplementation, whereas the lowest expression after valine addition. Interestingly all branched amino acids in concentration 2 times higher than physiological decreased cancer cell growth rate. A549 cell line showed higher consumption of glucose (after 24h and 48 h) than normal keratinocytes especially after supplementation with ketogenic Leu. At the same time, lactate production was more abundant in A549 than HaCaT cell line. The most significant decrease in amino acid concentrations was observed in a combination of all three BCAA's.

Conclusions

We conclude that BCAAs has a significant effect on cancer cell metabolism. This effect depends not only on different combinations of amino acids but also on their concentrations.

[1770] Liposomes in hydrogel combined with ultrasound stimulation as a novel curative dressing for diabetic wound

Authors: Josef Skopalik, Jiri Sekora, Tomas Parak

Affiliation: Dept. of Pharmacology and Toxicology, Faculty of Pharmacy, Masaryk University

Trustee of the paper: Josef Skopalik

Corresponding author: Josef Skopalik (j.skopalik@gmail.com)

Introduction

Skin pathology is registered in majority of patients with diabetes mellitus. Chronic wounds are an increasingly common diagnosis.

Aim of the study

Addition of liposomes with bioactive factors into the wound could accelerate the curing process and regenerating of the original dermal and subdermal structures. Pilot test of this method was prepared on diabetic rats (type ZDF) and kinetic of liposomes delivery were monitored by experimental MR imaging.

Materials and methods

We have prepared synthetic liposomes using components DOTAP/DOPE/Cholesterol/PEG, moreover VEGF, FGF and synthetic miRNA-30 were encapsulated inside the liposomes using previously published methodology. Gadolinium was encapsulated in advanced synthesis for better liposome visualisation. Liposomes were mixed into the semi-liquid collagen hydrogel, solution was incubated to 37°C, and injected into the open diabetic wound on skin of ZDF rats. The wound was prepared as 1 cm large excision of derma and subdermal layer on scapula area. Experimental groups (A - application of liposomes in gel, B- application of liposomes into gel + ultrasound, C - gel only, D - simple covering by gauze) was monitored and compared during 21 days.

Results

The gel was found to be adhesive and pseudoplastic for more than 5 days (variant A/B/C). Postmortem analysis showed a higher transport of liposomes from gel and bioavailability of liposomes in tissue for variant B with used ultrasound. Photographic analysis showed the better epidermis regeneration for all variant with liposomes. The capillary amount was significantly increased in liposome variants. Noninvasive MR monitoring of gadolinium deposit from gel to tissue show acceleration of liposome transport after using of ultrasound, MR proved better kinetic of wound closure. The correlation of computer tomography and histological analysis was approved.

Conclusions

The modern curative methods based on liposomes addition directly to skin wound were tested on animal model and can be prepared for clinical test of specific chronic pathology in dermatology. The hydrogel can prevent rapid liposome clearance from the skin site and ultrasound stimulation support liposome migration. Supported by Technology Agency of Czech Republic project FW01010106.

[1775] Multi-omic analysis shows increased de novo synthesis of serine in breast cancer cells

Authors: Monika Pankevičiūtė-Bukauskienė, Sergio Bordel

Affiliation: Lithuanian University of Health Sciences, Institute of Cardiology, Laboratory of Cell Culture, Kaunas, Lithuania

Trustee of the paper: Sergio Bordel

Corresponding author: Monika Pankevičiūtė-Bukauskienė (monika.pankeviciute-bukauskiene@lsmu.lt)

Introduction

Breast cancer is the most common malignancy not only amongst women, but amongst the entire human population worldwide, according to the latest records of World Health Organization. Since the discovery of the Warburg effect, metabolic diversity between healthy and malignant cells is seen as one of the hallmarks of cancer. Assessing the different metabolic profiles of this disease is important for developing new therapy formulations, markers for early diagnostics and a better understanding overall.

Aim of the study

The goal of this study was to identify the differences in metabolic activity between healthy and malignant breast epithelial cells, to find potential targets for therapeutic purposes.

Materials and methods

MCF-10A pre-neoplastic mammary epithelial cells were used for healthy control while MCF-7 epithelial mammary adenocarcinoma cells and primary breast cancer cells BCC, isolated in our lab, were used as a model for breast cancer. Ultra-high performance liquid chromatography was used to analyze cell extracts for metabolomics data and next-generation RNA sequencing was used for transcriptomics data. A genome scale metabolic model was used to correlate changes in metabolite levels with changes in gene expression.

Results

Serine and pyroglutamic acid were found to have higher concentrations in breast cancer cells, in comparison to healthy cells. RNA-sequencing data showed an overexpression of the genes PHGDH and PSPH, coding phosphoglycerate dehydrogenase and phosphoserine phosphatase respectively, in both malignant cell lines. These two genes are involved in the biosynthesis of serine from 3-phosphoglycerate. Serine is a known donor of methyl groups to the foliate cycle though one-carbon metabolism pathways. Besides from that, serine is also known to stimulate the synthesis of glutathione, which helps alleviate the effects of oxidative stress, by acting as an antioxidant in a variety of organisms. Transcriptomic analysis showed that the gene CHAC1 was overexpressed in MCF-7 and BCC. The function of the enzyme this gene codes is to break down glutathione into cysteinylglycine and pyroglutamic acid. Heightened intracellular pools of pyroglutamic acid might be the result of increased glutathione degradation.

Conclusions

Due to higher concentration of the amino acid serine in MCF-7 and BCC cell lines and the overexpression of PHGDH and PSPH, we conclude an increase of serine biosynthesis in breast cancer cells as compared to healthy cells.

[1811] Preparation of inhalable spray-dried microparticles for ciprofloxacin encapsulation.

Authors: Pešťalová Andrea, Gajdziok Jan

Affiliation: Masaryk University, Department of Pharmaceutical technology

Trustee of the paper: Pešťalová Andrea

Corresponding author: Andrea Pešťalová (Andy.Pestalova@gmail.com)

Introduction

Formulation of porous microparticles is one of the innovative approaches in the inhalation treatment of lung diseases where deep pulmonary drug deposition is required. By maintaining a low aerodynamic diameter with higher geometric diameter and porosity, particles formulated in this way achieve higher values of respirable fraction. The addition of porogens or some amino acids leads to porous structure and better aerosolisation of the particles during inhalation. LPPs are therefore a suitable form for the encapsulation of antibiotics.

Aim of the study

The study focused on the optimization of the composition of spray-dried microparticles for pulmonary administration using different excipients. The aim was to prepare microparticles for ciprofloxacin encapsulation meeting the parameters required for inhalation delivery.

Materials and methods

Firstly, liquid media containing equal amounts of leucine (15%) and porogen (1%) were prepared and differed in the carrier used (D-mannitol, chondroitin-sulfate and their mixture). Subsequently, ciprofloxacin (20%) was added to the media. The total concentration of the solid content was 10% in case of mannitol and mixture of carriers, and 5% when chondroitin-sulfate was used. Thus, a total of 6 batches (three containing ciprofloxacin and three control) were prepared. Formulations were spray dried using Buchi Mini spray drier B-290. The spray dried powder was then evaluated regarding their morphology, flow properties, geometric and aerodynamic diameter.

Results

The results of the measured particles showed that due to the addition of porogen, the internal porosity of the particles was high and ranged from 73.32-80.81 %, which is also related to the relatively low bulk density (0.30-0.57 g/cm³). Based on the SEM images, the shape of the mannitol-containing particles was mostly spherical with no agglomerates present, while the chondroitin-containing particles were largely wrinkled. However, the particle structure changed after ciprofloxacin encapsulation. The aerodynamic particle size was ~ 6 μm, thus, modification of process parameters is needed to its lowering. However, the fine particles fraction reached values up to 27.01 %, indicating suitable aerosolization properties.

Conclusions

Based on the measured results, in this study we were able to prepare microparticles containing ciprofloxacin aimed for further optimization of parameters (mainly aerodynamic diameter) that would meet the requirements for powder particles intended for administration into the lungs.

PhD Clinical & Health Science

Date: 22nd April 2023, 15:15 PM

Coordinators:
Katarzyna Mączka
Zofia Czartoryska

[1517] Alcohol consumption by primary health care patients and minimal anti-alcohol intervention

Authors: Małgorzata Znyk* (M.Z), Dorota Kaleta (D.K.)

Affiliation: Department of Hygiene and Health Promotion, Faculty of Sciences about Health, Medical University of Lodz, ul. Żeligowskiego 7/9, 90-752, Lodz, Poland

Trustee of the paper: *e-mail: znyk@poczta.onet.pl

Corresponding author: Małgorzata Znyk (znyk@poczta.onet.pl)

Introduction

Worldwide, 5.3% of all deaths annually are due to harmful alcohol consumption. In addition to the health consequences, the harmful use of alcohol brings significant social and economic losses to individuals and society at large. Minimal anti-alcohol interventions in primary care can reduce harmful alcohol consumption by patients.

Aim of the study

The aim of the study was to assess alcohol consumption by primary care patients and to assess the frequency of anti-alcohol counseling provided by family physicians to patients during the COVID-19 pandemic.

Materials and methods

The study covered 896 primary care patients from the city of Łódź in 2020-2021. The research tool was an anonymous questionnaire. The Bioethics Committee at the Medical University of Lodz gave a positive opinion of the project (RNN/315/18/KE).

Results

82% of the respondents indicated that they drink alcohol-containing beverages, and this usually takes place once a month or less (51.8%).

72.8% of patients admitted that they had consumed alcohol in the last 7 days. The most frequently consumed alcohol was wine (36.5%) and beer (36.3%). Wine was most often consumed in the amount of 2-3 glasses (47.1%), and beer in the amount of 2-3 beers (42.3%). In the group of patients consuming alcohol, only 8.3% indicated that they were asked about alcohol consumption during a visit to a GP. 2.3% of patients received minimal anti-alcohol intervention from a general practitioner. 6.4% of alcohol-consuming patients were informed about negative alcohol consumption and health consequences by a doctor.

In the multivariate logistic regression analysis, men (OR=4.94; $p<0.01$) and participants with primary education (OR=13.60; $p<0.01$) more often received minimal anti-alcohol interventions than women with secondary and higher education.

Conclusions

It is necessary to implement minimal anti-alcohol interventions conducted by a primary care physician and to educate the patient about the possible negative health effects of alcohol consumption.

[1614] Antioxidant balance parameters (MDA, GPx, CAT, TAS) at birth and after 48 hours of life in term newborns with different concentration of total serum bilirubin

Authors: Wiktoria Osiak-Sieńko¹, Sławomir Wątroba², Dorota Luchowska-Kocot¹

Affiliation: ¹Department of Medical Chemistry, Medical University of Lublin, 20-093, Poland

²Neonatal Department, Independent Public Health Care Facility, Puławy 24-100, Poland

Trustee of the paper: Professor Jacek Kurzepa MD, PhD

Corresponding author: Wiktoria Osiak-Sieńko (wiktoria.osiak@gmail.com)

Introduction

Elevated bilirubin concentration leads to a yellowish colorization of the sclera and the skin, called jaundice. Neonatal jaundice is a physiological phenomenon which occurs due to increased hemoglobin catabolism and insufficiency of a liver glucuronyltransferase. Although high bilirubin level is known to cause encephalopathy and kernicterus, bilirubin is also a potent antioxidant and anti-inflammatory factor, which has been confirmed by in vitro studies.

Aim of the study

The aim of the study was to evaluate antioxidant balance parameters and the intensity of oxidative stress in term newborns with different concentration of total serum bilirubin.

Materials and methods

For the research purpose two consequent blood samples were collected - a cord blood sample and blood sample 48 hours after birth. At the collection, total bilirubin concentration (TSB) was determined in the hospital laboratory. Patients were divided retrospectively into three groups regarding their risk zone at 48h of life for subsequent significant hyperbilirubinemia according to 1999 Bhutani normogram: low risk (TSB <8.5 mg/dl), intermediate risk (TSB 8.5-13 mg/dl) and high risk (TSB >13mg/dl). In total, 49 healthy term neonates were enrolled to the study. Malondialdehyde (MDA) concentration, glutathione peroxidase (GPx) activity, catalase (CAT) activity and total antioxidant status (TAS) in serum were measured with spectrophotometric methods.

Results

MDA concentration was used to measure intensity of oxidative stress; it did not show any differences between groups nor a significant change during two first days of life. CAT, GPx activity and TAS value increased 48 hours after birth ($p < 0.05$). Both CAT activity and TAS value were the highest in the high risk (TSB >13mg/dl) group and they were positively correlated with TSB ($R = 0.43$ and $R = 0.49$, $p < 0.05$). No differences of antioxidant parameters according to genders were observed. However, neonates born vaginally had higher GPx activity at birth and higher CAT activity after 48h than babies born by cesarean section (334.6 ± 31.9 vs 239.7 ± 56.8 U/l and 15.7 ± 1.9 vs 11.4 ± 3.6 nmol/min/ml, $p < 0.05$).

Conclusions

The results indicate that newborns with more intensive hyperbilirubinemia have better antioxidant defense status. These findings support the hypothesis that high bilirubin concentration can be protective in the first days of life. The way of delivery might affect antioxidant enzymes activity.

[1652] IL-6 AS A MARKER OF LUNG COMPLICATIONS IN CHILDREN WITH ACUTE LEUKEMIA

Authors: Victoria Koval

Affiliation: Kharkiv National Medical University. Department of pediatrics №2

Trustee of the paper: Supervisor – Nataliia Makieieva

Corresponding author: Victoria Koval (1.victoria.koval@gmail.com)

Introduction

Acute leukemia (AL) takes a leading place in the structure of pediatric cancer incidence. Recently, there is an improvement in the prognosis of AL and more attention is concentrated on studying the complications of AL, including pulmonary ones.

Aim of the study

To assess the level of IL-6 in exhaled breath condensate (EBC) in children with AL and their prognostic value.

Materials and methods

We examined 51 children aged 6-18 years with AL and 15 healthy children for the control group. Children with AL were divided into 2 groups: 1st group –during induction phase of chemotherapy (n = 24), 2nd group – in remission (n= 27). The presence of congenital or chronic diseases of the respiratory system before the debut of AL and diagnosed primary immunodeficiency were exclusion criteria. IL-6 level in EBC was assessed by ELISA. Data analysis was performed by Statistica 8 and MedCalc 17.2.

Results

Pulmonary complications were recorded in 86.27% % of children with AL. Acute pulmonary complications were presented in 87.50% of children (group 1). In 18.52% of children, pulmonary complications persisted during remission (group 2). The increased levels of IL-6 in 1st group (52,71 (48,28; 60,71) pg/ml) and 2nd group (20.74 (18.34; 24.08) pg/ml) compared with control (8.12 (7.02; 9.45) pg/ml) were found: $p1-C=0.0000$; $p2-C=0.0000$. Children with AL during chemotherapy (group 1) had higher levels of IL-6 in EBC than children in remission (group 2): $p1-2=0,0000$. Despite the decrease in IL-6 in children in the remission group, it is higher than the level of the control group. According to ROC analysis level of IL-6 in EBC collected during the induction phase of chemotherapy $>47,64$ pg/ml can be predictive for acute pulmonary complications (AUC 0,952; sensitivity 85,71%; specificity 100%); $>52,08$ pg/ml can be indicative of the development of pneumonia (AUC 0,843; sensitivity 100%; specificity 78,57%); $>61,33$ pg/ml shows possibility to predict distant pulmonary complication in remission (AUC 0,738; sensitivity 75%; specificity 95%). IL-6 level in EBC in remission $>25,19$ pg/ml can predict persistent pulmonary complications in AL survivals (AUC 0,891; sensitivity 80%; specificity 95,45%).

Conclusions

Children with AL have significantly increased levels of IL-6 in EBC both during chemotherapy and in remission, which proves the activity of the inflammation process in the blood-air barrier of the lungs in these patients. The level of IL-6 in EBC can be used as a possible predictor of pulmonary complications in children with AL.

[1764] Proximal femoral morphology and Non-Contact ACL Injuries: Comparing Injured and Uninjured Extremities

Authors: D.Musliu, S.Bexheti, Q.Kida, A.Kafexholli, A.Mahmuti, L.Berisha, A.Karakushi, J.Shatri

Affiliation: Institute of Anatomy, Faculty of Medicine, University of Prishtina. Clinic of Orthopedics, University Clinical Center of Kosovo.

Trustee of the paper: Dijon Musliu

Corresponding author: Dijon Musliu (dijonmusliu@gmail.com)

Introduction

Non-contact ACL injury is a common and debilitating injury among athletes, with high rates of recurrence and long-term consequences. Identifying individuals who are at risk of ACL injury can help prevent or reduce the severity of these injuries. One potential risk factor is the alpha angle, which measures the shape of the femoral head-neck junction.

Aim of the study

The aim of this study is providing an overview of non-contact ACL injury and the potential role of the alpha angle in identifying individuals at risk of this injury.

Materials and methods

This is a case-control study that aimed to compare the alpha angles of the ACL injured patients with healthy contralateral extremity. The study included 58 patients who had suffered ACL injuries. The alpha angles of the injured and healthy extremities were measured using a standardized protocol, using Dunn View X-ray with hips flexed and 90° and abducted 20°. Patients who had a prior injury to the contralateral knee were excluded from the study. We have used the alpha angle of 55° as the cut off point for femoro-acetabular impingement. Additionally, the study measured the ACL laxity pre and post-operation using a Lachmeter. We have used OsiriX MD software to do the measurements. For statistical analysis SPSS v.23 was used.

Results

The results of the study showed a mean difference of 3° of the alpha angle between the 2 groups. Independent samples t-test was used to test the groups and the results showed a statistically significant difference in the alpha angles between the injured and healthy knees, with $p < 0.05$.

Conclusions

This study suggests that the alpha angle may be a useful tool for identifying individuals who are at risk of ACL injury. The study found no significant difference in the alpha angles between the different three sports groups when tested for One Way Anova, indicating that the alpha angle may be useful in identifying individuals at risk of ACL injury regardless of the sport they participate in.

[1942] A new approach to the treatment of nasopharyngeal carcinomas in laryngology

Authors: Piotr Strus, Karol Sadowski, Julia Kostro, Izabela Młynarczuk-Biały, Karolina Dżaman

Affiliation: HESA; Department of Otolaryngology, Centre of Postgraduate Medical Education

Trustee of the paper: Izabela Młynarczuk-Biały, Karolina Dżaman

Corresponding author: Piotr Strus (struspiotrek@gmail.com)

Introduction

Podophyllotoxin (PPT) is a plant-derived drug with anticancer potential widely used in 90's in oral HPV infection and nowadays in HPV ano-genital warts. Due to its toxicity, it can not be used systemically. PPT stabilizes microtubules and stops the replication of cellular DNA, however, the exact mechanism of action remains unknown. There are PTT derivatives such as Picropodophilin with promising effects in nasopharyngeal cancer. In our project, we aim to obtain a novel PPT derivative with a better toxicity profile and anti-cancer effect.

Aim of the study

Evaluation of potential applications of new derivatives of PPT in the treatment of HPV(+) nasopharyngeal carcinomas. Analysis of PPT and derivatives cytotoxicity to human keratinocytes (HaCaT), fibroblasts (NIH 3T3) and mononuclear blood cells (PBMC).

Materials and methods

The changes of the structure of HaCaT cells were described on the basis of photos taken by electron microscopy. Cytotoxic effects in HaCaT, NiH-3t3, and PBMC were described by PrestoBlue assay, Apo-Necro Kit and ATP-assay. Cells were cultured in accordance with the ATCC and treated with the corresponding concentrations of PPT (Sigma Aldrich) and a new derivative - KL3, synthesized in cooperation with the University of Warsaw.

Results

PPT causes a stronger cytotoxic effect on HaCaT, Nih-3T3 and PBMC cells than KL3 in the corresponding concentration. In HaCaT after a 24h incubation, both compounds lead to mitochondrial swelling, stress of the endoplasmic reticulum and elongation of the cytoplasmic processes, but in cells incubated with KL3 after 48 hours the changes regress and autophagosomes are formed. We did not observe a similar regression effect in cells after incubation with PPT. In addition, in PPT-incubated cells, the vacuolization of the cytoplasm and the loss of cell membrane continuity were observed.

Conclusions

Due to the cell adaptive mechanisms of reversal of changes and the formation of autophagosomes, when incubated with the KL3, the new derivative appears to be less cytotoxic than the parental PPT. Based on that and our previous research, we already know KL3 is more effective on cancer cells and less toxic on non-tumorigenic cells than PPT, making KL3 more likely to be used topically.

[1992] New properties of cinnamnic acid –nutraceutical effects in treatment of functional gastrointestinal dyspepsia

Authors: Andrzej Chomentowski

Affiliation: Medical Univeristy of Bialystok, Department of Biophysics

Trustee of the paper: Assoc. Prof. Tomasz Kleszczewski

Corresponding author: Andrzej Chomentowski (chomentowskiandrzej@gmail.com)

Introduction

Natural, plant-derived substances named nutraceuticals, are increasing in popularity as their beneficial properties in human body are discovered. Cinnamnic acid is a plant-sourced polyphenol that has been reported for its multiple beneficial properties as anti-diabetic and anti-oxidative capacity. However up to now it has not been examined as possible muscle-relaxant agent.

Aim of the study

The main objective of the study is to assess the effect of cinnamnic acid on contractility of smooth muscles of the stomach, as well as to determine the relations between its action and endogenous synthesis of nitric oxide.

Materials and methods

Tissues were obtained from patients undergoing sleeve gastrectomy due to morbid obesity (N=10). The layer of smooth muscles were dissected, attached to strain gauge and placed in a tissue bath with Tyrod buffer at physiological temperature. After acclimatization contraction of muscles was stimulated using carbachol. Only strips showing stable activity in response to agonist were proceeded further in the experiments. Cinnamnic acid was diluted in ethanol and increasing concentrations were added cumulatively to the tissue chamber. Endogenous NO synthesis was blocked by L-NNA, L-NAME and ODQ. The area under the curve (AUC) average baseline muscle tone, and relative change in muscle contraction were evaluated using strain gauge. The statistical analysis was performer using ANOVA or the Kruksal-Wallis, where appropriate. The results were considered statistically significant at $p \leq 0.05$.

Results

Exposure to cinnamnic acid caused significant dose-dependent relaxation of strips, manifested by decrease of AUC comparing to control. Preincubation with L-NNA, L-NAME, or ODQ – inhibitors of endogenous NO synthesis pathway did not prevent the cinnamnic acid-induced relaxation.

Conclusions

Cinnamnic acid relaxes gastric smooth muscles without activation of nitric oxide synthase. Moreover our results indicate that it might become potential nutraceutical for treatment of functional gastrointestinal dyspepsia as well as other gastric motility disturbances.

[1644] Atherosclerotic Plaque Characteristics in Carotid Arteries Detectable by Non-invasive Imaging Methods Compared to Histology: A Systematic Review and Diagnostic Test Accuracy Meta-analysis

Authors: David Pakizer(1), Jiří Kozel(1), Patrick Taffé(2), Jolanda Elmers(3), Janusz Feber(1,4), Patrik Michel(5), David Školoudík(1*), Gaia Sirimarco(5*)

Affiliation: (1) Faculty of Medicine/University of Ostrava; (2) Division of Biostatistics/University of Lausanne; (3) Medical Library/University of Lausanne; (4) Department of Pediatrics/University of Ottawa; (5) Stroke Center/Lausanne University Hospital; (*) equal

Trustee of the paper: David Pakizer

Corresponding author: David Pakizer (david.pakizer@email.cz)

Introduction

Atherosclerotic disease is responsible for up to one third of all strokes. In addition to the degree of focal carotid stenosis, plaque components appear to be an important risk factor for plaque instability and subsequent cardiovascular events.

Aim of the study

The aim of this study was to estimate diagnostic accuracy of several atherosclerotic carotid plaque characteristics using non-invasive plaque imaging methods when compared to histology, in adult patients with symptomatic and asymptomatic carotid plaques.

Materials and methods

We searched Medline Ovid ALL, Embase.com, Central Cochrane Library Wiley, and Web of Science Core collection, supplemented by search in Google Scholar and citation searching of key studies, for diagnostic accuracy of non-invasive imaging methods (US, CT, MRI) in detecting carotid plaque characteristics compared to histology. We used QUADAS-2 to assess the quality of studies and carried out the statistical analyses using univariate and bivariate random-effects meta-analysis models.

Results

We found 107 published studies, representing a total of 253 evaluations of the diagnostic accuracy of 16 specific plaque characteristics, under three different imaging technics (28 CT, 120 MRI, and 105 US studies). In the univariate meta-analyses, CT was able to detect only 6 characteristics, but with the highest diagnostic accuracy (sensitivity 82% [95% CI: 76-87], specificity 93% [95% CI: 87-97], accuracy 89% [95% CI: 84-93]). MRI was able to detect the highest number of visualizable characteristics (15) with non-significant difference in accuracy compared to CT (sensitivity 84% [95% CI: 81-86], specificity 89% [95% CI: 87-91], accuracy 87% [95% CI: 85-88]). US was able to visualize 12 characteristics and showed the worst diagnostic accuracy with significant difference in specificity and accuracy compared to CT and MRI (sensitivity 78% [95% CI: 74-82], specificity 79% [95% CI: 74-82], accuracy 78% [95% CI: 75-81]).

Conclusions

CT had the best sensitivity and specificity, but was able to visualize only the basic 6 characteristics, for which it may be used as the first-line method. MRI visualized 15 characteristics (out of 16) with almost the same sensitivity and specificity as CT and should be used particularly to detect the plaque characteristics that cannot be seen on CT and to obtain a comprehensive assessment of plaque vulnerability, whenever possible. US seems to have similar sensitivity, but worse specificity and diagnostic accuracy.

[1729] Selected eating styles and diet quality among Polish adults

Authors: Aleksandra Małachowska, Marzena Jeżewska-Zychowicz

Affiliation: Department of Food Market and Consumer Research, Institute of Human Nutrition Sciences, Warsaw University of Life Sciences (SGGW-WULS)

Trustee of the paper: prof. dr hab. Marzena Jeżewska-Zychowicz

Corresponding author: Aleksandra Małachowska (aleksandra_malachowska@sggw.edu.pl)

Introduction

Available studies suggest that adaptive eating styles (AES), e.g. intuitive eating (IE), and maladaptive eating styles (MAES), e.g. restrained (RE) and external eating (EE), may be useful in explaining intake of the selected foods. Nevertheless, so far, only few studies have included both AES and MAES as determinants of the diet quality.

Aim of the study

The study aim was to assess the correlation between IE, RE, EE and diet quality, separately among women and men.

Materials and methods

The cross-sectional study was conducted between October 2022 and January 2023 among 708 Polish adults (477 women and 231 men) via Internet. The questionnaire consisted of: 1/'Restrained eating' (RE) and 'External eating' (EE) subscales from the Dutch Eating Behaviour Questionnaire; 2/Intuitive Eating Scale 2 with 4 subscales - 'Reliance on Hunger and Satiety Cues' (RHSC), 'Eating for Physical Rather Than Emotional Reasons' (EPR), 'Body-Food Choice Congruence' (B-FCC), 'Unconditional Permission to Eat' (UPE); 3/questions regarding intake of food groups from the KomPAN questionnaire that allowed to calculate 3 diet quality indexes – Non-Healthy Diet Index (nHDI-14), Pro-Healthy Diet Index (pHDI-10), Diet Quality Index (DQI); 4/metrics. Spearman's correlation coefficient and Mann-Whitney's U Test were used to analyse the data.

Results

Men presented higher level of EPR in comparison to women (3.75 ± 0.99 vs. 3.13 ± 1.16 , $p < 0.001$), while women scored higher in RE and EE than men (2.70 ± 0.88 vs. 2.45 ± 0.86 , $p < 0.001$ and 3.04 ± 0.73 vs. 2.85 ± 0.67 , $p < 0.01$, respectively). Gender did not differentiate the scores for all IE subscales. pHDI-10 and DQI scores were higher among women, while higher nHDI-14 score was observed in men ($p < 0.001$). Weak significant correlations were found between eating styles and all diet quality indexes in both women (ranging from $r = -0.328$ to 0.400 , $p < 0.001$) and men (ranging from $r = -0.337$ to 0.341 , $p < 0.01$). nHDI-14 correlated positively with UPE and EE and negatively with B-FCC and RE among both men and women. pHDI-10 and DQI correlated positively with B-FCC and RE, while DQI correlated negatively with UPE, in both men and women. Additionally, among women, negative correlations between pHDI-10 and UPE as well as between nHDI-14 and EPR were noted.

Conclusions

IE, RE and EE may explain diet quality in the similar manner among women and men. Future research should also include other eating styles, e.g. mindful eating or emotional eating, to enable better understanding of the relationship between AES, MAES and diet quality.

[1732] Congenital toxoplasmosis in Poland during 2007-2021: an epidemiological study based on a national hospital registry.

Authors: Rząd Michał; Nitsch-Osuch Aneta; Goryński Paweł; Tyszko Piotr; Andruszuk Izabela; Kanecki Krzysztof

Affiliation: Department of Social Medicine and Public Health, Medical University of Warsaw, Warsaw, Poland

Trustee of the paper: Kanecki Krzysztof, MD, PhD, Assistant Professor

Corresponding author: Michał Rząd (michal.rzad.1994@gmail.com)

Introduction

Congenital toxoplasmosis (CT) is a rare entity and may pose a life-threatening disease for the newborns. Due to public health and clinical importance of CT infection in infants, the recent data on this disease in Poland should be investigated.

Aim of the study

The aim of the study was to evaluate incidence and other factors related to CT in Poland.

Materials and methods

Our study is population-based, retrospective study based on 2133 hospital discharge records of CT patients in 2007-2021. Data were obtained from National Institute of Public Health in Poland. Based on ICD-10 codes, we analyzed comorbidity among the study group.

Results

The study group consisted of 1493 hospitalizations records of first-time diagnosis of CT newborns - 758 males (50,77%) and 735 females (49,23%). Among this group 89.62% were infants up to 90 days of age and 69.79% of patients were neonates up to 28 days of age. The mean and median age was 31 days (95% CI: 28-34 days) and 10 days (IQR: 0-36 days) respectively. Based on hospital registry the mean annual CT incidence of was estimated to be 2.6 per 10,000 live births (95% CI: 2.0-3.2 per 10,000 live births). The incidence of CT cases fluctuated over the years 2007 to 2021 with the highest incidence in 2010 and the lowest in 2014. There were no statistically significant differences between the incidence of CT between genders or in the comparison between rural and urban areas. In the analyzed period, 8 deaths were recorded (0.54% of all patients): 5 males and 3 females. The median age in this subgroup was 0 days (IQR: 0-10).

Conclusions

CT incidence based on infants hospitalization fluctuated in Poland in 2007-2021. The periodic increase in the number of cases of congenital toxoplasmosis indicates the need to develop effective prevention programs to effectively counteract the disease and its consequences. The results of the study may be helpful in further research into this disease and building methods for education and more effective prevention efforts.

[1610] Thanatophoric dysplasia type 2 – case report

Authors: Jakub Kociuba, Diana Massalska, Artur Skowyra, Miłosz Dymon, Michał Ciebiera

Affiliation: Second Department of Obstetrics and Gynecology, Center of Postgraduate Medical Education

Trustee of the paper: Diana Massalska, Michał Ciebiera

Corresponding author: Jakub Michał Kociuba (jakubkociuba@gmail.com)

Background

Tanatophoric dysplasia (TD) is a rare, lethal, genetic skeletal disease caused mostly by de novo mutation in FGFR3 gene. The dysplasia is characterized by severe micromelia with rhizomelic predominance, small thoracic circumference, macrocrania or skull deformities. Classically, TD has been divided into two subtypes, TD type 1 (85%) and TD type 2 (15%) according to the shape of femur and skull. Cloverleaf skull is the most characteristic feature for TD2. We present a case of prenatal diagnosis of TD2 confirmed by genetic testing after termination of pregnancy.

Case report

27-years old primigravida presented for the first trimester screening at 12 weeks of pregnancy which revealed nuchal translucency (NT) of 3.7mm, shortening of the femur (6 percentile), free beta-hCG 2.97 multiple of median (MoM), PAPP-A 0.64 MoM, what indicated the risk for trisomy 21 of 1:4. The chorionic villus sampling with chromosomal microarray analysis (CMA) revealed no abnormalities. The ultrasound scan at 16 gestational weeks revealed shortening of all long bones (<1 percentile), decreased circumference of the thorax, profile and skull deformities. After genetic counselling amniocentesis was performed and subsequent normal results of CMA were obtained. At 19 weeks, ultrasound scan performed in the tertiary center, revealed cloverleaf skull deformity, partial agenesis of corpus callosum, ventriculomegaly, hypertelorism, abnormal profile, decreased thorax circumference and micromelia. The suspicion of TD2 was confirmed. After termination of pregnancy due to a lethal defects at 20 gestational weeks performed on maternal request, exome sequencing (ES) of the fetus was performed. The result of ES was nonsynonimic variant in FGFR3 gene, which was observed in the patients with TD1 (OMIM 187600) as well as TD2 (OMIM 187601). ES results of both parents were normal. Postnatal babygram confirmed ultrasound findings. One year later the patient got pregnant and gave birth to a healthy girl.

Conclusions

Fetuses with TD2 may present with increased NT and abnormal results of screening. In case of skeletal system deformities targeted genetic testing for skeletal dysplasia should be considered to establish diagnosis antenatally. Although TD2 is hereditary autosomal dominant disease, most cases concern de novo mutation and the recurrence risk in subsequent pregnancies is not significantly increased over the general population.

Radiology

Date: 22nd April 2023, 9:00 AM

Coordinators:
Patryk Pindłowski
Magdalena Skudzińska

Patronage:

Polskie Towarzystwo Ultrasonograficzne
Polskie Towarzystwo Inżynierii Klinicznej

[1782] Is the first step the most important one? -Ultrasound in patients with acute abdominal symptoms.

Authors: Julia Budzyńska, Ilona Koziół, Magdalena Leśniewska, Katarzyna Drelich, Olga Pustelniak, Weronika Mielnik, Monika Zbroja

Affiliation: Students' Scientific Society at the Department of Pediatric Radiology, Medical University of Lublin

Trustee of the paper: dr hab. n. med. Magdalena Woźniak

Corresponding author: Julia Budzyńska (julciab42@gmail.com)

Introduction

Acute abdomen is a medical condition that occurs unexpectedly, progresses rapidly and is commonly life-threatening. Although the underlying etiology may vary from inflammation, intussusception to gastrointestinal bleeding, ultrasound remains the primary imaging modality.

Aim of the study

The aim of study is to show the importance of ultrasound in diagnostics of acute abdomen.

Materials and methods

The study enrolled 312 patients (150 girls) aged 3 weeks to 18 years, with acute abdominal pain. Abdominal US with evaluation of intestinal loops was performed in each patient, along with laboratory and pathological tests or other imaging studies, depending on the suspected pathology.

Based on clinical presentation, patients were divided into four groups:

- (a) 189 - appendicitis susp.
- (b) 63 - pylorostenosis susp.
- (c) 49 - inflammatory bowel disease susp.
- (d) 11 - intestinal intussusception susp.

Results

From 79 patients in group (a) in whom signs of appendicitis were visible on US, 52 were qualified for appendectomy - pathological evaluation of the specimen confirmed inflammation in all cases. In the remaining 27 patients the appendix was not visualized; as clinical picture stabilized over time – there was no indication for further diagnosis and intervention.

52 patients from group (b) were qualified for surgery based on US images and clinical symptoms, and the diagnosis was confirmed intraoperatively.

In 36 patients of group (c) US images were highly suggestive of active Crohn's disease, while in 4 patients - for ulcerative colitis. The findings were confirmed by MRE and histopathologically.

In group (d), in all patients intestinal intussusception was visible on US. Moreover, due to severe thickening of the affected intestine's wall, Burkitt lymphoma was suspected. Laboratory tests, bone marrow evaluation and MR/CT scans confirmed the initial diagnosis.

Conclusions

In any child with abdominal complaints, an abdominal US with evaluation of the gastrointestinal tract is performed first. US is a reliable imaging modality in differential diagnosis of the acute abdomen; in our series, all US findings were later confirmed by pathological evaluation or intraoperatively.

[1940] The evaluation of atherosclerotic plaques' features on ultrasound examination – the utility of contrast-enhanced ultrasound (CEUS)

Authors: Małgorzata Matuszek¹, Ewa Kopyto¹, Marcin Czeczelewski¹, Karolina Nieoczym¹, Eryk Mikos¹, Maja Kopyto¹, Adam Czarnecki¹, Karol Stępnia¹

Affiliation: 1. Students Scientific Society at the Department of Interventional Radiology and Neuroradiology, Medical University of Lublin, Poland 2. Department of Interventional Radiology and Neuroradiology, Medical University of Lublin, Poland

Trustee of the paper: Maryla Kuczyńska², Anna Drelich-Zbroja²

Corresponding author: Małgorzata Matuszek (gosiamatuszek15@gmail.com)

Introduction

Approximately 15% of all ischemic strokes are caused by large arteries atherosclerosis. The severity of stenosis is the leading parameter in determining the risk of developing a stroke in the future. On the other hand, there are some plaques ("vulnerable" plaques) causing low-grade stenosis that can lead to vascular complications. Intraplaque neovascularization and surface ulceration are the most powerful independent predictors of plaque rupture. Ultrasound imaging is a tool of choice in identifying not only plaque's presence but also may help to distinguish vulnerable ones. Non-contrast-enhanced ultrasound can provide data about the size, morphology and echogenicity of the plaques. Plaque surface and its neovascularization can be evaluated using the contrast-enhanced ultrasound method (CEUS).

Aim of the study

The objective of the study was to assess plaques characteristics in patients with carotid atherosclerosis using CEUS as an imaging modality for predicting plaque vulnerability.

Materials and methods

The study included 31 patients referred to carotid arteries ultrasound examination. Patients' symptoms, medical history and basic parameters were recorded. Ultrasound scans in B-mode and the Color Doppler option were first performed. After obtaining the consent form, patients (n=21) were administered an intravenous contrast medium of 1.5 ml SonoVue (Bracco, Italy) and flushed with 10 ml of 0.9% saline. As contrast reached the carotid artery, the plaques (n=24) were assessed for contrast enhancement.

Results

The average thickness of the plaque was 28,2 mm (min. 13, max. 44). Eccentric plaques were found in 15 cases and concentric in 9. On B mode ultrasound of 31 plaques: 13 were type I and 18 were type II according to Gray-Weale classification. On CEUS 6 plaques did not show any contrast enhancement, in 14 it was weakly enhanced and in 4 cases significant enhancement was found. Of these 20 plaques, 6 patients reported potential ischemic symptoms (headaches, dizziness, cognitive function impairment). The ulcerated surface was found in 6 plaques, in 9 cases the plaque surface had irregularities and the remaining 9 plaques were smooth.

Conclusions

CEUS provides valuable information on atherosclerotic plaque vulnerability. Finding vulnerable plaques may help to identify high-risk patients that can lead to proper, preventative management.

[1983] The differences between the types of bicuspid aortic valve – retrospective study evaluated accompanying cardiovascular disorders and the presence of coronary artery stenosis using ECG-gated MDCT

Authors: Piotr Machowiec, Elżbieta Czekajska-Chehab

Affiliation: Medical University of Lublin, Students' Scientific Association at the 1st Department of Medical Radiology

Trustee of the paper: Piotr Machowiec

Corresponding author: Piotr Machowiec (piotr.machowiec1997@gmail.com)

Introduction

Bicuspid aortic valve (BAV) is the most common congenital heart disease in general population with an estimated prevalence of 0.1 to over 2% according to various authors' reports. This defect may coexist with other cardiovascular disorders such as ventricular or atrial septal defects, patent foramen ovale (PFO), aortic coarctation and patent ductus arteriosus. Based on the Sivers-Schmidtke classification, three types of BAV are distinguished: type 0 with no raphe, type 1 with only one raphe and type 2 – two raphes.

Aim of the study

The aim of the study was to characterize the cardiovascular disorders coexisting with specific Sivers-Schmidtke types of BAV and to assess the relationship between the type of bicuspid aortic valve and the incidence of significant stenosis of coronary arteries using ECG-gated multidetector computed tomography.

Materials and methods

The retrospective study included 664 patients with the presence of bicuspid aortic valve who underwent ECG-gated MDCT in the years 2008-2022. The imaging examinations were performed at the 1st Department of Medical Radiology (Medical University of Lublin) using 256-row GE Revolution and 64-row Light Speed VCT scanner.

Results

The most common cardiovascular disorders associated with BAV were PFO and aortic coarctation in subjects with type 0 (11.9% and 9.5% respectively). PFO and atrial septal aneurysm were recognized as the most distinctive in group of patients with type 1 (13.6% and 6.0%) as well as type 2 (16.7% and 9.3%).

Significant coronary artery stenosis was significantly more frequent in patients with type 1 of BAV compared to type 0 and monocusp variant (type 2). In addition, the presence of a raphe between the coronal and non-coronal cusps (subtype 1N-R and 1N-L) was associated with a significantly higher percentage of significant coronary stenosis compared to subtype 1R-L ($p < 0.001$).

Conclusions

Cardiovascular defects associated with a bicuspid aortic valve are characterized by a different prevalence depending on the type of valve defined according to the Sivers-Schmidtke classification. The presence of a raphe between the coronary and non-coronary cusps seems to be a potential risk factor for significant coronary stenosis in patients with BAV. However, there is a need for further studies in a larger group, including prospective studies, to more accurately assess this relationship.

[1822] Malposition of central venous catheter into coronary sinus throughout the persistent left vena cava superior: a case report

Authors: Barbara Syska, Anna S. Veér

Affiliation: Students' Scientific Group at the Department of Diagnostic Imaging, CMUJ, Kraków, Poland, Department of Diagnostic Imaging, University Hospital, Kraków, Poland.

Trustee of the paper: Patrycja Matusik, MD, PhD

Corresponding author: Anna Veer (annas.veer@gmail.com)

Background

Central venous catheter (CVC) is an instrument placed into a central vein, permitting venous access for administration of intravenous therapy or for the purpose of dialysis. The most common location for CVC is the superior vena cava or right atrium. Placement of the CVC utilizes different assist techniques including but not limited to ultrasounds or real time X ray. Misplacement is one of the most common complications associated with CVC's, whilst this mistake can be attributed to several different factors, the case reported focuses on persistent left superior vena cava (PLSVC) which is a rare vascular anomaly.

Case report

A 72-year-old woman with renal insufficiency in the course of anti-glomerular basement membrane diseases, was admitted to the hospital due to recurrent bleeding from permanent CVC placed in the right common jugular vein, probably caused by mechanical injury. Said catheter required replacement, following an unsuccessful attempt, a secondary catheter was placed in the left jugular vein. Subsequently the patient developed swelling of the neck and face. Radiological techniques including x-ray and computed tomography (CT) were utilized and depicted a catheter placement in the PLSVC and coronary sinus, and hematoma of the posterior mediastinum. Subsequently the CVC was removed, and further CT studies were utilized to assess patient progress and regression of the hematoma was observed. Finally, the permanent CVC was removed from the PLSVC and a temporary CVC was implanted into the left femoral vein. One month later, temporary CVC was complicated by an extensive hematoma of the soft tissues of the thigh, and the patient required surgery. Two months later, the patient was hospitalized due to catheter dysfunction. It was decided to insert a long permanent CVC into the right femoral vein, and now the patient is waiting for creation of an arteriovenous fistula for dialysis.

Conclusions

This case highlights the importance of the use of imaging techniques for both the procedural technique and detection of congenital anomalies when placing a CVC. Clinicians who routinely place CVC should be well versed with the possible complications of the procedure, especially in high-risk patients.

[1878] The usefulness of MRI and the Pi-RADS v. 2.1 scale in the process of detecting prostate cancer in a very rare location.

Authors: Olga Pustelniak

Affiliation: Students' Scientific Society at the Department of Interventional Radiology and Neuroradiology, Medical University of Lublin, Lublin, Poland

Trustee of the paper: M.D., PhD. Anna Drelich - Zbroja, dr. Maryla Kuczyńska

Corresponding author: Olga Pustelniak (olgamariapustelniak@gmail.com)

Background

Prostate cancer (PCa) is the most common malignancy in male population. PCa's are most frequently located within the peripheral zone - transition and central zones, as well as anterior fibromuscular stroma (AFS) are relatively rare. There are several diagnostic tools applied in the assessment of the extent of prostate tumors. Multiparametric magnetic resonance imaging (mpMRI) is recommended for the early detection of clinically relevant prostate cancer. A 5-point Prostate Imaging and Reporting and Data System (Pi-RADS) is used to indicate the probability that lesions detected in mpMRI correlate with the presence of clinically significant cancer.

Case report

We present a 67-year-old man with elevated levels of PSA = 4.27ng/ml and no apparent abnormalities in the DRE. MRI was performed to screen for possible lesions of the prostate. T2-weighted images revealed a well-defined, strongly hypointense area (16mm in the biggest dimension), showing diffusion restriction and pathologic contrast enhancement – Pi-RADS 5 – localized in the AFS at the midportion of the gland. The MR examination additionally showed signs of benign prostate hyperplasia and irrelevant mildly hypointense areas within the peripheral zone – assessed as post-inflammatory or fibrotic changes (Pi-RADS 2).

Conclusions

mpMRI include anatomical (T1 and T2-weighted images) and functional sequences (DWI and DCE images). Such constellation enables a detailed characterization of the prostate zones and focal lesions, providing excellent contrast between various tissues. This is of particular importance especially in case of strong clinical suspicion of a malignancy localized in a rare location, possibly out of range for digital rectal examination or biopsy.

[1911] Rare and Fatal: The Role of MR Imaging in Diagnosing Sporadic Creutzfeldt-Jakob Disease

Authors: Marcin Czeczelewski

Affiliation: Students Scientific Society at the Department of Interventional Radiology and Neuroradiology, Medical University of Lublin, Lublin, Poland.

Trustee of the paper: Maryla Kuczyńska MD

Corresponding author: Marcin Czeczelewski (marcin.czeczelewski@gmail.com)

Background

Due to its diverse clinical manifestations, the diagnosis of sporadic Creutzfeldt-Jakob disease (sCJD) is still a challenge. In its early stages, sCJD can resemble various reversible or treatable diseases. Definitive diagnosis during a patient's lifetime is rare as it requires an invasive procedure, especially given the frequent involvement of deep-seated gray matter. However, recognizable clinical features and magnetic resonance images (MR) may allow a confident diagnosis without the need for pathological confirmation.

Case report

A 47-year-old male patient presented with rapidly progressive behavioral disturbances that were inconsistent with psychiatric disorders. The suspicion of autoimmune encephalitis was raised. On admission, the patient was alert but had impaired allopsychic orientation. There were no significant medical history findings.

Neurological examination revealed cognitive impairment, behavioral disturbances, and akathisia. There were no motor deficits, such as weakness of the limbs or involuntary movements. The rest of the physical examination was unremarkable. In laboratory tests, slightly elevated leukocytes, and markers of inflammation.

MR examination revealed increased signal intensity on DWI images in the cortical regions of the frontal lobes, cingulate gyrus, insulas and temporal lobes of both hemispheres. The heads of the caudate nuclei and the anterior segments of the putamen also showed increased signal intensity, especially on the left side.

Based on the clinical picture, the positive 14-3-3 protein in the CSF, and the MR findings, a diagnosis of sCJD was made.

After hospitalization in the neurological rehabilitation ward, the patient was discharged home with instructions to take medications and continue outpatient neurological care.

Conclusions

The most common MR imaging pattern in sCJD is characterized by cortical and basal ganglia hyperintensity on DWI. This hyperintensity may be attributed to reduced water diffusion due to compartmentalization within vacuoles or the deposition of the prion protein. The increases in signal intensity on DWI correspond to disease duration and the degree of spongiform degeneration, and they may serve as a noninvasive biomarker of disease severity. Strict adherence to diagnostic criteria and careful interpretation of MR images are the recommended approaches for in vivo diagnosis of sCJD. DWI features play a crucial role in the diagnostic workup of sCJD.

[3006] **Diagnosis of liver trichinellosis using magnetic resonance imaging (case report)**

Authors: Matsiievska Anastasiia-Violetta

Affiliation: Bogomolets National Medical University

Trustee of the paper: Candidate of Medical Sciences (PhD), docent Bogomaz Volodymyr

Corresponding author: Anastasiia-Violetta Matsiievska ()

Background

The prevalence of helminthiasis in the world remains quite high and most of them involve the hepatobiliary system. Considering the specificity of treatment plans, timely nosological diagnosis of liver lesions is extremely relevant. The amount of research on this topic is currently very limited but some of them proved MRI capability in the diagnosis of liver trichinellosis. Retrospective medical case analysis and literature review were performed.

Case report

Nonspecific focal changes in the liver parenchyma were found in a 30-year-old woman without an oncological history during standard abdominal ultrasound examination. It is known about trips to Asian countries several years ago. Clinical manifestations that are specific to trichinellosis or any malignancy were not found in the patient. Examination of the patient's abdominal organs on magnetic resonance imaging with 3.0 T field induction (T1-WI, T2-WI, DWI-sequences, bolus dynamic contrast enhancement) showed the presence of a sign of a "curved tunnel" in the liver parenchyma. Serological tests that confirmed the diagnosis of trichinellosis were performed. The patient has no other clinical and laboratory signs of pathology and she still be under clinical observation. According to the data of the literature and our observation, the sign of the "curved tunnel" on magnetic resonance imaging is a sensitive criterion for the diagnosis of trichinellosis of the liver.

Conclusions

In the case of clinical and diagnostic uncertainty of local changes in the liver parenchyma after basic radiological studies (sonography, computer tomography) and in the presence of risk factors for helminthiasis, despite the high cost, it is advisable to include MRI of the liver in the patient examination algorithm to speed up the duration and ensure the accuracy of the diagnosis.

Surgery

Date: 22nd April 2023, 9:00 AM

Coordinators:
Zofia Głowniak
Michał Koprowski

[1507] **Low-cost laparoscopic simulator – viable way of enabling access to basic laparoscopic training for medical students?**

Authors: Monika Lis, Joanna Łysak, Piotr Więckowski

Affiliation: Medical University of Warsaw

Trustee of the paper: Piotr Więckowski

Corresponding author: Piotr Roman Więckowski (murmurmice@gmail.com)

Introduction

Medical students do not have an easy access to laparoscopic training. Our project of low cost laparoscopic training box could provide easier access to basic laparoscopic training for medical students.

Aim of the study

Using materials available at standard hardware store we managed to construct a laparoscopic training box with four eye-hand coordination modules. This work contains instructions on creating such a training box

Materials and methods

We conducted a survey of students who were provided training using commercial box trainer and our homemade box trainer.

Results

The Likert Scale Survey taken at the end of the course indicated that the laparoscopic training was successful and regarded a positive experience. Students surveyed responded that the homemade trainer was of comparable quality to the commercial trainers (85,7% strongly agreed, 14,3% agreed). When asked, all of the 35 students responded that the training using homemade trainers was a positive experience (97,1% strongly agreed, 2,9% agreed).

Conclusions

Based on the survey answers, basic laparoscopic training using homemade training boxes seems to be a viable alternative to the use of commercial simulators in the situation of limited funding. Such simulator is relatively easy to construct from widely available materials. Low-cost simulators can increase the availability of laparoscopic training for medical students.

[1509] Early postoperative oral nutrition effects in patients undergoing laparoscopic cholecystectomy: a randomized clinical trial

Authors: Mahsa Arabzadeh, MD

Affiliation: Department of Medicine, Tehran University of Medical Sciences

Trustee of the paper: Mahsa Arabzadeh, MD

Corresponding author: Mahsa Arabzadeh (mahsaarabzadehmd@gmail.com)

Introduction

Early oral nutrition remains the most important issue to be addressed in postoperative care following laparoscopic cholecystectomy. Delay in the discharge of patients increased the risk of ileus, nosocomial infections and medical costs.

Aim of the study

This study aimed to evaluate the effect and safety of early oral nutrition in patients undergoing laparoscopic cholecystectomy.

Materials and methods

100 patients of both gender, which underwent cholecystectomy were randomized to the early feeding group (n=50) and routine feeding group (n=50). All patients were followed up daily with particular attention to nausea, bowel sounds, vomiting, defecation and other signs of diet intolerance.

Results

There was no significant difference in nausea, vomiting, defecation and acceptance of diet between early and routine feeding groups. The mean time of hearing of bowel sounds in the intervention group was significantly lower than the control group ($P = 0.002$). Hospitalization was considerably shorter in the early group rather than the routine-fed group ($P = 0.006$).

Conclusions

This study indicated that early oral diet was associated with a considerable reduction in length of hospital stay and onset of bowel sounds auscultation. There were no notable differences in the risk of complications. The findings of various previous studies in some abdominal surgeries were consistent with the current research. In conclusion, our study showed that early oral nutrition programs in patients undergoing laparoscopic cholecystectomy are safe and tolerated by most patients.

[1527] Optimizing the treatment of patients with gastroesophageal varices and portal hypertension of the hepatic type - a 5-year experience in the specialized center.

Authors: Leshchynska N.O.

Affiliation: Bohomolets` national medical university, Surgery chair №3

Trustee of the paper: Supervisor: Ph.D., Assistant of the Department of Surgery No. 3 Kurbanov A.

Corresponding author: Natalia Leshchynska (nata.a.lesch@gmail.com)

Introduction

Treatment of patients with acute variceal bleedings (AVB) associated with portal hypertension (PH) is accompanied by high mortality rates in either surgical, endoscopic or therapeutic methods of treatment.

Unsatisfactory treatment results, caused primarily by the complexity of the pathology, require the treatment optimization of this patient population, and it is an urgent scientific task of high practical and social importance.

Aim of the study

To analyze the indicators and causes of patient mortality with VB phenomena in PH.

To conduct a structured analysis of treatment results (survival rate) using various treatment methods (prophylaxis) for this patient population.

According to the comparative analysis to determine potential ways of promising techniques of VB secondary prevention and treatment results optimization.

Materials and methods

A retrospective analysis of the treatment results was carried out on 871 patients treated in the Center from 2015 to 2019. Survival rate analysis was performed according to the Kaplan-Meier method.

Results

During 5 years, from 2015 through 2019, 871 patients were treated in the Center, and 233 died. According to the results of the database analysis, 179 (79%) of them died during the peak of the first (and single in their life) bleeding episode, and the remaining 21% - in the re-emergence of bleeding episode (recurrent). During the first day of hospitalization, 124 or 53.22% of patients died, and 156 (67%) died within 72 hours. In general, this indicates shortcomings in the organization of patient treatment with diffuse liver diseases preceded an episode of VB, lacking "portal vigilance" specialists, who treat patients with advanced chronic liver disease (ACLD). We consider as expedient to perform a Diagnostic screening Ultrasound, Doppler, and endoscopic examination for all patients with DLD to identify early signs of clinical PH manifestations and potential threats to VB. When varicose veins of the esophagus and stomach are detected, there is an urgent need to consider the risk of bleeding in further treatment programs and refer such patients to specialized centers to develop prevention programs. According to the severity of the clinical course of VB and the high lethality, early prevention is a significant reserve for improving treatment results.

Conclusions

The priority of organizational measures to improve the treatment results of patients with AVB is the development and improvement of primary prevention measures and effective screening to identify the risk groups.

[1553] Normalization of inflammatory parameters after perioperative intravenous lidocaine administration in pediatric patients undergoing laparoscopic appendectomy – a retrospective analysis

Authors: Ignacy Maciejewski, Marek Wolski

Affiliation: Medical University of Warsaw/Student Scientific Club of Pediatric Surgery

Trustee of the paper: Marek Wolski

Corresponding author: Ignacy Zbigniew Maciejewski (ignacy.3.11@gmail.com)

Introduction

It has been proven that adult patients who were presented for surgery and whose anesthesia included intravenous lidocaine required fewer opioids and had lower inflammation parameters. There is very limited information about that effect in the pediatric population.

Aim of the study

This study is looking for such an impact on the population of children undergoing laparoscopic appendectomy.

Materials and methods

71 children (5–17 years old) undergoing laparoscopic appendectomy were divided into two groups: the experimental group (n = 35) and the control group (n = 36). Patients from the experimental group received lidocaine intravenous infusions during the procedure. The two groups were comparable.

Results

There were no significant differences between the groups in the analyzed parameters, which were white blood count, hemoglobin, thrombocytes, percentage of lymphocytes and neutrophils, C-reactive protein (3-5 days after the operation), the day when peristalsis was first detected, and the day when the diet was extended (noted in the medical history by the leading doctor).

Conclusions

Intravenous lidocaine administered perioperatively has no impact on inflammation parameters in children after laparoscopic appendectomy.

[1752] Factors associated with variation in perioperative quality of life assessment: a prospective observational study.

Authors: Antoni Cierniak, Wojciech Skupnik, Klaudia Czech

Affiliation: SSC of Centre for Intensive Care and Perioperative Medicine, Jagiellonian University Medical College

Trustee of the paper: Paweł Pasięka, MD, Prof. Wojciech Szczeklik, MD, PhD

Corresponding author: Antoni Tomasz Cierniak (antonicierniak1@gmail.com)

Introduction

Euro-QoL visual analog scale (EQ-VAS) is a simple tool assessing health-related quality of life (HRQoL). This questionnaire might indicate the quality of patient's recovery after the surgery. Numerous factors (such as age, physical condition, extent of surgery) contribute to worse recovery and quality of life among surgical patients.

Aim of the study

The aim of the study was to assess quality of life in surgical patients undergoing general anesthesia using EQ-VAS and identify potential factors that may impact preoperative and postoperative health status.

Materials and methods

This study was carried out as a part of the project of Polish validation of the Quality of Recovery-15 (QoR-15) questionnaire. Participants were voluntarily recruited from patients qualified for surgical procedures in general anesthesia. Every patient was asked to evaluate their current health status using 0-100 scale EQ-VAS twice: a day before and a day after the procedure. Data concerning patients' age, sex, clinical frailty scale (CFS), ASA scale, comorbidities and duration of the surgery were collected. Wilcoxon signed-rank test, Mann-Whitney U test, and Spearman's correlation analysis were performed. Data were analyzed with usage of STATISTICA 13.3 software (StatSoft®).

Results

A total of 51 patients (30 females; 58.9%) were included in the study. The mean age of the participants was 52.9 ± 14.8 years with 18 (35%) patients being over 60 years old. There was no significant statistical difference between preoperative and postoperative VAS in the whole study group. In the male subgroup, the median preoperative VAS score (80, IQR 70-90) was significantly higher than the postoperative score (75, IQR 57.5-92.5; $p=0.049$). Males' preoperative VAS score (80, IQR 70-90) was higher than in the female group (65, IQR 50-80; $p=0.033$). Increased operative time ($\rho=-0.58$; $p=0.005$) and CFS score ($\rho=-0.45$; $p=0.037$) were negatively correlated with postoperative VAS scores in males.

Conclusions

There were significant differences in perioperative quality of life self-assessment between males and females. The results also suggest that clinical frailty and prolonged operative duration might be associated with worse quality of life early after surgery. Our study seems to support the value of assessing CFS for every surgical patient.

[1847] The role of endovascular treatment of celiac trunk pathologies

Authors: Katarzyna Morawiec, Janusz Świeczkowski-Feiz, Aleksandra Maciejczyk

Affiliation: Medical University of Warsaw; Department of General, Vascular and Transplant Surgery
University Clinical Center of the Medical University of Warsaw; Students' Scientific Group "Graft"

Trustee of the paper: prof. dr hab. Tadeusz Grochowicki, dr Łukasz Wielocha

Corresponding author: Katarzyna Morawiec (kasia.morawiec123@gmail.com)

Introduction

Celiac trunk is the first major visceral branch of the abdominal aorta. Pathologies of this short vessel can cause among others abdominal pain, weight loss or nausea. Symptoms are the major indication for treatment and the choice of method depends on the diagnosis. Dunbar syndrome is treated by surgical division of the median arcuate ligament. Stenoses or aneurysms can be treated endovascularly.

Aim of the study

Our study aims to analyze the effectiveness of endovascular interventions for celiac trunk pathologies.

Materials and methods

We retrospectively identified 9 patients diagnosed with celiac trunk pathologies. Our analysis focused on the initial presenting symptoms, indications for the intervention, the type of procedure and its outcomes.

Results

All among 9 identified patients reported abdominal pain, 1 patient had nausea and emesis. The indications for primary endovascular interventions were: atherosclerotic stenosis in 4 cases and aneurysm in 1 case, Angioplasty with stent as a reintervention after surgical treatment of Dunbar syndrome in 3 cases. In one case stenting was performed as a part of elective hybrid procedure post-surgical division of median arcuate ligament. Balloon angioplasty was performed in 2 cases and both were unsuccessful. Among 7 primary stenting procedures, only 3 were considered technically successful – the circulation in the artery was restored. Reintervention was performed in 1 case after 5 years. In summary only 33% (3/9) of performed procedures were successful, the stent was implanted in all of them.

Conclusions

This study indicate that primary balloon angioplasty procedure alone is not effective. Angioplasty with stent, despite being successful in some cases, also appeared unsatisfactory in general. Hybrid treatment may be considered in selected cases.

[1855] **Surgical analysis of aberrant hepatic arteries – cadaveric pilot study**

Authors: Adrian Balcerzak

Affiliation: Medical University of Łódź / Department of Anatomical Dissection and Donation

Trustee of the paper: prof. UM, dr. hab. Łukasz Hubert Olewnik

Corresponding author: Adrian Andrzej Balcerzak (adrian.balcerzak@icloud.com)

Introduction

Aberrant hepatic artery (AbHA) is an artery, which originate from an anomalous trunk and supplies a portion of the liver. Changes in the vascularity of the liver remain one of the most frequently observed anatomical variability and cause a number of complications that have a significant impact on the outcomes of surgical procedures and their complications. In order to avoid them, preoperative examinations are performed to assess the vascularity and topography of the region. However, the current classifications describing AbHA variability are inconsistent and too extensive to be easily used in everyday clinical practice. New, simple, updated and clinically relevant system seems necessary for clinicians operating in this area.

Aim of the study

To access the occurrence of aberrant hepatic arteries, compare AbHA incidence in intraoperative studies with incidence in present cadaveric study and to introduce a new, simplified and clinically highly useful classification of hepatic vascular variabilities.

Materials and methods

The presence and anatomical variations in the AbHA origin were examined in 54 cadavers fixed in a 10% formalin solution. Study was carried out with classical dissection techniques, during which the sex, aberrant hepatic artery morphology, the point where it branched off the corresponding trunk in reference to the abdominal aorta, its width at origin, its width at porta hepatis and additional branches parameters were evaluated. Morphometric measurements were then obtained twice by two researchers.

Results

The aberrant hepatic artery was present in 25,93% of cases. Introduction of new classification system dividing the abdominal cavity into four quadrants, which are representing the area of aberrant hepatic artery origin - upper right labelled as "I", upper left as "II", lower left as "III", and lower right as "IV". According to proposed classification the frequency of the AbHA origin point in the first quadrant (I) was equal to 42,86%, in second quadrant (II) to 21,43%, in third quadrant (III) to 0% and in the fourth quadrant (IV) to 35,71%.

Conclusions

Aberrant hepatic arteries are relatively common vessels, the incidence of which was observed to be higher during anatomical analysis of cadavers than during intraoperative assessment. AbHA is characterized by a great variability in its origin and course. The introduction of a new, structured and simplified anatomical classification, that seems to have more clinical implications than previous systems.

[1902] Minimally invasive procedures in treatment of the superior mesenteric artery pathologies

Authors: Aleksandra Maciejczyk, Janusz Świeczkowski-Feiz, Katarzyna Morawiec

Affiliation: Medical University of Warsaw; Department of General, Vascular and Transplant Surgery
University Clinical Center of the Medical University of Warsaw; Students' Scientific Group "Graft"

Trustee of the paper: dr Łukasz Wielocha, prof. dr hab. Tadeusz Grochowicki

Corresponding author: Aleksandra Maciejczyk (aleksandramaciejczyk99@gmail.com)

Introduction

Pathologies of the superior mesenteric artery are serious, but not common, medical conditions that often require intervention to prevent complications and improve patients' quality of life.

Aim of the study

Our study aims to analyze the effectiveness of balloon angioplasty or primary stenting for emergent and planned treatment of superior mesenteric artery pathologies.

Materials and methods

In this study we evaluate 17 patients who underwent primary endovascular interventions due to superior mesenteric artery pathology. Patients were divided into two groups: Group A - emergencies (5 patients) and Group B - elective procedures (12 patients). In our analysis, we focused on the clinical indications for the intervention and subsequent outcomes.

Results

Indications for intervention in Group A (5pt) included in one case emboli unsuccessfully treated with local fibrinolysis and symptomatic atherosclerotic stenosis in 4 cases treated with percutaneous angioplasties. Out of Group A PTAs 25% (1/4) were treated with balloon angioplasty and 75% (3/4) were treated with primary stenting. In Group B (12pt, elective interventions), atherosclerotic stenosis was an indication for 11 patients: 3 (27%) of them were treated with balloon angioplasty (including 1 with coexisting Leriche's syndrome) and 8 (72%) patients were treated with primary stenting. We also identified elective 1 patient (Group B) with SMA pseudoaneurysm who was successfully treated with covered stent implantation. In 1/12 cases in Group B the procedure of primary stenting was unsuccessful. As a result this patient required reintervention and elective aortomesenteric bypass surgery was performed. Reinterventions due to restenosis happened in 3 cases of primary angioplasty - one patient (Group A) was treated with aortomesenteric bypass and two patients (Group B) were treated with redo endovascular procedure. The mean time between the first endovascular procedure and subsequent procedure was 15 months.

Conclusions

Balloon angioplasties and primary stenting were effective in both emergencies and elective procedures. Endovascular reinterventions were necessary as a result of restenosis or failure of the procedure. Open aortomesenteric bypass remains the best operative procedure in treatment of superior mesenteric artery pathologies when the other treatment options have failed.

[1927] Transplant renal artery stenosis (TRAS) – treatment and outcomes

Authors: Janusz Świeczkowski-Feiz, Aleksandra Maciejczyk, Katarzyna Morawiec

Affiliation: Department of General, Vascular and Transplant Surgery - University Clinical Center of the Medical University of Warsaw

Trustee of the paper: Dr Łukasz Wielocha, Prof. dr hab. Tadeusz Grochowicki

Corresponding author: Janusz Świeczkowski-Feiz (feiz.janusz@gmail.com)

Introduction

Transplant renal artery stenosis (TRAS) is a possible cause of graft failure. Detection of TRAS may be difficult due to nonspecific manifestations. It occurs usually during the first 6 - 24 months after the transplantation.

Aim of the study

To evaluate the effectiveness of endovascular procedures in TRAS.

Materials and methods

We retrospectively identified 24 patients diagnosed with TRAS. Preliminary diagnosis was made on the basis of newly observed hypertension and/or deterioration of graft function, confirmed in USG-Doppler and angio-CT scan. TRAS was diagnosed in 13 (54%; 13/24) and in 11 (45%; 11/24) patients within the first 6 months and between 6 to 24 months, respectively. Patients were divided into two groups. Group A (11 patients): underwent primary balloon angioplasty; and group B (13 patients): underwent primary stent implantation.

Results

In Group A primary intervention was successful in 55% (6/11) of patients, 45% (5/11) of patients required reintervention within 2-8 months. 40% (2/5) of patients that underwent reintervention within 2 months to 6 years required secondary reintervention within 3-10 months. Both of them were successfully treated intravascularly.

In Group B (primary stent implantation) treatment was successful in 54% (7/13) patients, 46% (6/13) patients required reintervention within 10-35 months. Out of these 6 patients 50% (3/6) were successfully treated intravascularly and the remaining 3 required secondary reintervention within 2-17 months. In these 2 cases secondary reintervention was unsuccessful and the patients underwent tertiary reinterventions within 9 months (unsuccessful).

In 54% of patients (13/24) TRAS was successfully treated endovascularly with primary intervention, 38% patients (9/24) required one or more reintervention, and in only 8% (2/24) endovascular treatment was unsuccessful despite 4 endovascular interventions.

Conclusions

Primary balloon angioplasties and primary stenting were effective as a treatment of TRAS. Overall success rate was 92% (22/24), however in significant number of cases reinterventions were necessary.

Cardiology Case Report

Date: 22nd April 2023, 15:15 PM

Coordinators:
Dorota Słupik
Aleksandra Reda

[1531] Recurrent postinfarction ventricular tachycardia in multimorbid patient with implantable cardioverter defibrillator - a complex case report

Authors: Jakub Michal Zimodro, Magda Mucha, Joanna Rogozik

Affiliation: 1st Chair and Department of Cardiology, Medical University of Warsaw; Faculty of Medicine, Medical University of Bialystok

Trustee of the paper: Joanna Rogozik MD

Corresponding author: Jakub Michal Zimodro (zimodro.jakub@gmail.com)

Background

Patients after myocardial infarction (MI) are prone to develop ventricular tachycardia (VT). Sustained VT might result in hemodynamic instability and sudden cardiac death (SCD). Thus, antiarrhythmic pharmacotherapy, ablation and implantable cardioverter defibrillator (ICD) implantation might be required.

Case report

A 75-year-old multimorbid male with a recent history of (1) non-ST-segment elevation MI, treated with drug-eluting stent implantation, (2) chronic heart failure with reduced left ventricular ejection fraction (HFrEF) and (3) arrhythmia, initially misdiagnosed as atrial flutter with right bundle branch block aberration, was admitted to the Cardiology Department due to palpitations. Electrocardiography showed wide QRS complex tachycardia with ventricular rate of ca. 130/min. VT was recognized and terminated by electrical cardioversion. Recurrent episode of VT was terminated by administration of lidocaine. Implantable cardioverter defibrillator (ICD) was implanted as a secondary prevention measure. Subsequently, VT reoccurred, thus electrophysiology study (EPS) was performed. EPS revealed VT originating from the basal-septal region, as well as self-limiting VT originating from the left ventricular outflow tract. The former origin was ablated. Pharmacotherapy with amiodarone was initiated. After 10 months, patient was readmitted due to electrical storm. VT was terminated after several attempts of anti-tachycardia pacing. EPS showed VT originating from the basal-septal region, where two post-MI scars were located. Another catheter ablation was performed. No VT episodes were recorded after the procedure.

Conclusions

In post-MI patients with sustained VT and symptomatic HFrEF, ICD implantation should be considered in SCD prevention. Catheter ablation might additionally reduce the number of VT episodes and ICD interventions. Pharmacotherapy with amiodarone, and eventually ablation, should be considered in patients experiencing recurrent episodes of VT or electrical storm.

[1608] Heart failure and concomitant lung cancer causing aortic arch pseudoaneurysm in a 78-year-old patient

Authors: Aleksandra Bętkowska

Affiliation: 1st Chair and Department of Cardiology, Medical University of Warsaw

Trustee of the paper: Piotr Baruś, MD, Mariusz Tomaniak, MD, PhD, FESC

Corresponding author: Aleksandra Elżbieta Bętkowska (ola.betkowska@gmail.com)

Background

Cardiovascular diseases and cancer remain the leading causes of morbidity and mortality worldwide. Given the high prevalence of heart failure (HF) and cancer, the two can co-occur. The growing overlap between HF and cancer patients has led to the emergence of cardio-oncology. Oncological patients, particularly long-term survivors, are especially vulnerable to cardiovascular diseases, potentially due to the toxicity of antineoplastic drugs. On the other hand, HF may disqualify patients from effective oncological therapies.

Case report

A 78-year-old woman with a history of hypertension, persistent atrial fibrillation, tricuspid valve regurgitation, and heart failure (New York Heart Association, NYHA class III) was admitted to the hospital due to chest pain and dyspnea on exertion. Two months prior, the patient was examined in another hospital for possible metastatic cancer of the left lung. The diagnostic process revealed an aortic arch pseudoaneurysm which resulted from neoplastic infiltration, for which endovascular repair was performed. Current examination revealed mild anemia, leukocytosis, increased C-reactive protein (CRP) levels, elevated D-dimer and NT-proBNP levels. Serum CA-125 tumor antigen level was more than three times the upper limit of normal. An echocardiogram showed enlarged atria, systolic dysfunction of the right ventricle, and large mitral and tricuspid valve regurgitation. Coronary angiography did not reveal any significant stenoses. The diuretic dose was increased, and dapagliflozin was administered. A decision was made that the heart valve defect could be treated surgically once a histopathologic diagnosis of the lung mass was established, along with disease staging and the patient's prognosis. The diagnostic process is set to continue within a specialist lung disease clinic.

Conclusions

Patients with either HF or lung cancer may present with heterogenic and often non-specific symptoms, making the clinical diagnosis challenging. Despite the increasingly significant co-occurrence of HF and cancer, access to individualized treatment varies significantly for these two patient populations. The two groups have specific needs and require well-coordinated health and social care, including specialist palliative treatment, which is not always easily accessible to patients suffering from non-malignant chronic illnesses.

[1660] Asymptomatic giant popliteal artery aneurysm in a patient with Marfan syndrome

Authors: Wojciech Kubacki

Affiliation: Medical University of Warsaw, Department of Internal Medicine, Hypertension and Vascular Diseases, SKN Professor

Trustee of the paper: Izabela Łoń MD

Corresponding author: Wojciech Kubacki (wkubacki93@gmail.com)

Background

Marfan syndrome (MFS) is a genetically determined disease with an abnormal structure of the connective tissue with a prevalence of 1 in 5000 individuals. The classic manifestations are found in the skeletal system, joints, skin, eyes, but the leading cause of morbidity and mortality are cardiovascular complications. These include the formation of aneurysms and dilatation of large vessels, aortic dissection, and the development of valvular defects. The abnormal structure of the vascular wall may also affect peripheral and visceral arteries. The example shows the validity of a more detailed assessment of peripheral arteries during routine follow-up of patients with genetic defects in the vascular wall.

Case report

A 45-year-old male with MFS was admitted for a routine cardiovascular follow-up, one year after cardiac surgery due to dissection of the ascending aorta. The procedure was complicated in the acute period by thrombosis of the veins of the lower limbs. The patient was in good general condition, without any symptoms, with normal systemic blood pressure. On examination, a well-palpable pulse in the peripheral arteries was found. Echocardiography showed the satisfactory function of the heart, valves, and implanted supra coronary graft. Control Doppler ultrasound revealed organized thrombi in the right femoral and popliteal vein, without thrombosis in the veins of the lower left limb. In the same examination, a large left popliteal artery aneurysm with maximum dimensions of 80 × 51 mm was found. CT angiogram was performed and it confirmed the presence of the large vascular malformation. The patient was referred for emergency vascular surgery, which was successful.

Conclusions

In patients with MFS, regular echocardiographic monitoring with the assessment of the heart and aorta is recommended due to the risk of aneurysm formation or dissection. Assessment of peripheral arteries is not routinely performed. In the presented case, the large, asymptomatic, potentially life-threatening popliteal artery aneurysm was detected accidentally during the examination for deep vein thrombosis. Although literature describes cases of peripheral artery aneurysms in MFS patients, such large asymptomatic aneurysms are rare. This example shows the validity of a more detailed assessment of peripheral arteries during routine follow-ups of patients with genetic defects in the vascular wall.

[1712] Takayasu Arteritis complicated by aortic valve regurgitation. A case report.

Authors: Dominika Kondyjowska, Natalia Szopa

Affiliation: Students' Scientific Group of Clinical Angiology, Jagiellonian University Medical College

Trustee of the paper: Marzena Frolow, MD, PhD

Corresponding author: Dominika Kondyjowska (d.kondyjowska@gmail.com)

Background

Takayasu's arteritis is a chronic vasculitis of medium and large vessels, mainly affecting women under 40. The most involved vessel is the aorta and its major branches. The vessels are characterized by mononuclear infiltration and granulomatous inflammation of vascular media, which leads to arterial wall thickening with stenosis, occlusion, and aneurysmal dilation. Symptoms often occur in two stages: firstly, symptoms are often non-specific, such as fever, weakness, and fatigue, and the second is associated with vascular changes and includes weakness and pain in the extremities, fainting, dizziness, or lack of pulse in the extremities.

Case report

Our patient is a 49-year-old woman diagnosed with Takayasu's disease, referred for a periodic ultrasound examination. The patient claimed to have good control of her blood pressure by measuring her blood pressure on the right arm and achieving an average of 90/60, while on the left arm, the pressure was unmeasurable. Physical examination revealed a diastolic murmur over the aortic valve, vascular murmurs at the base of the neck and over the subclavian arteries, no pulse on the left radial artery, and a faint pulse on the right radial artery. Systolic blood pressure assessed by continuous wave Doppler at the lower extremities was 180 mmHg. Ultrasound on B-presentation with color Doppler showed the characteristic changes of Takayasu's disease of long segmental normoechogenic, circular thickening of the wall of the common carotid arteries and in the initial segments of the internal and external carotid arteries. The brachiocephalic trunk's flow velocity spectrum and the subclavian arteries' initial segments showed an atypical retrograde wave in the diastolic and end-diastolic phases, indicating aortic valve regurgitation causing holosystolic retrograde flow seen in the large arteries departing from the aortic arch.

Conclusions

The patient's severe hypertension, which was complicated by aortic regurgitation, was not previously detected due to unreliable measurement of upper limb pressure. In order to avoid this severe complication, and the consequent accelerated development of atherosclerosis, which significantly worsens the course of the disease, patients should be carefully informed about the need to control lower extremity pressure. In these cases, the blood pressure may be measured using a wide cuff on an uninvolved thigh or by palpation by examining a well-palpable dorsal artery of the foot while deflating a cuff placed on the lower leg.

[1734] Severe, chronic mitral regurgitation against the pandemic backdrop

Authors: Radu Alexandra-Maria, Reșetar Maria-Melissa, Savin Bianca- Alexandra

Affiliation: Faculty of Medicine, Iuliu Hațieganu University of Medicine and Pharmacy, Cluj-Napoca, Romania

Trustee of the paper: Pop Dana, Tomoaia Raluca

Corresponding author: Alexandra Maria Radu (alexandramaria.radu@yahoo.com)

Background

Mitral regurgitation represents an abnormal flow of blood from the left ventricle into the right atrium during ventricular systole. Primary mitral regurgitation is a disease of the mitral valve apparatus, whereas secondary mitral regurgitation is caused by a disease of the left ventricle.

Case report

A 69-year-old male was admitted to the hospital after accusing dyspnea. He had been diagnosed with primary mitral regurgitation two years prior and was recommended for surgery, but the treatment was deferred owing to the pandemic. The patient presented a systolic apical murmur, without signs of cardiac decompensation. An echocardiography reconfirmed the diagnosis: grade III mitral regurgitation with rupture of the chordae tendineae caused by myxomatous degeneration of the anterior leaflet, without dilatation or systolic dysfunction of the left ventricle. In addition to the previous examination, pulmonary hypertension was detected, therefore the patient underwent a cardiopulmonary effort test that highlighted a severe loss of effort capacity. As the possibility of underlying coronary artery disease was raised, the patient also underwent coronary angiography. The patient declined surgery, thus a successful percutaneous angioplasty with stenting of the LAD and circumflex coronary artery was conducted. The surgical approach will also be reconsidered at the subsequent evaluation in a month.

Conclusions

Untreated severe mitral valve regurgitation will eventually lead to left ventricular dilatation and dysfunction. The optimal time for surgery would be before the decompensated stage where irreversible damage to the left ventricle could occur. Although surgery has been shown to be the only efficient treatment, operative mortality is certainly not negligible. Therefore, a close follow-up is important in patients with mild symptoms and requires shortening the reevaluation interval if any symptoms appear. The particularity of this case is that, despite the pandemic preventing a thorough follow-up, the patient's left ventricular ejection fraction remained stable.

[1742] Intracoronary acetylcholine provocation testing in a patient with ischemia and non-obstructed coronary arteries

Authors: Kinga Gładys

Affiliation: Jagiellonian University Medical College, Student's Scientific Group at the Department of Interventional Cardiology, John Paul II Hospital, Cracow, Poland

Trustee of the paper: prof. Bartłomiej Guzik, MD, PhD

Corresponding author: Kinga Agnieszka Gładys (kinga.gladys64@gmail.com)

Background

Coronary artery spasm may be involved in the pathogenesis of various cardiac disorders, such as ischemic heart disease. It has been reported that a large part of Caucasian patients with stable angina and unobstructed coronary arteries on coronary angiography suffer from coronary vasomotor disorders. Therefore, the intracoronary administration of acetylcholine (ACh) has been recommended in assessment of both epicardial and microvascular spasm in patients with angina pectoris and unobstructed coronary arteries. The positive diagnosis of the provocation test is defined as total or subtotal coronary artery narrowing, which is accompanied by chest pain and/or ischemic electrocardiographic changes.

Case report

A 67-year old smoking woman with stable angina (CCS II) and non-obstructed coronary arteries, arterial hypertension, type II diabetes, hypothyroidism and paroxysmal AF was referred to the cardiology department. The guiding purpose of admission was to provide extended diagnostic evaluation. During the admission many extensive investigations were undertaken. Echocardiography revealed preserved left ventricular ejection fraction of 65% and absence of any significant valvular pathologies. An exercise electrocardiogram (ETT) revealed ST depression in II, III, aVF, V5-V6 up to -0,27mV with the MET score established at 7,9. Laboratory results showed no significant abnormalities. Coronary angiography confirmed non-obstructed coronary arteries. Eventually, invasive diagnostics in the form of the provocative test with acetylcholine was performed and resulted in the angiographic spasm of LAD, severe chest pain and ventricular tachycardia documented on electrocardiogram. Ultimately, the patient underwent the cardiac denervation procedure.

Conclusions

The presented case highlights the importance of intracoronary acetylcholine provocation testing in the evaluation of coronary vasomotion disorders. The procedure can be useful in determining the optimal treatment and would, ultimately, lead to better patient outcomes.

[1797] Common aortic stenosis or rare cardiomyopathy?

Authors: Małgorzata Blecharczyk

Affiliation: Medical University of Warsaw, Department of Internal Medicine, Hypertension and Vascular Diseases

Trustee of the paper: Piotr Sobieraj, MD, PhD

Corresponding author: Małgorzata Blecharczyk (gosia.blech20@gmail.com)

Background

Cardiac amyloidosis is a major cause of mortality in patients with systemic amyloidosis. However, cardiac amyloidosis can be diagnosed also as a separate disease. Despite the evolution of medical imaging technologies, diagnostic process of cardiac amyloidosis still remains challenging.

Case report

An 82-year-old man was admitted to hospital presenting progression of heart failure with NYHA IV class after massive bleeding from lower limb varicose veins. Initial tests revealed iron deficiency anemia with hemoglobin of 8 g/dL and elevated NT-proBNP concentration (6662 pg/ml). Echocardiographic examination showed severe aortic stenosis with left ventricular hypertrophy and diastolic dysfunction. In fact, the patient was followed for years by experienced cardiologist due to aortic stenosis. However, diastolic dysfunction and extreme hypertrophy (intraventricular septum diameter 22 mm) was suggestive for cardiac amyloidosis. The serum free-light chains kappa concentration and kappa/lambda ratio was elevated with normal range of gamma globulin. Cardiac magnetic resonance imaging showed diffused, delayed hyper-enhancement pattern throughout heart walls characteristic of cardiac amyloidosis. Finally cardiac amyloidosis was confirmed using scintigraphy. Further evaluation showed no evidence for bone marrow pathology. Typical treatment for heart failure with mildly reduced ejection fraction was started resulting in improvement of symptoms to NYHA class II/III. Finally subtype of transthyretin amyloidosis was diagnosed.

Conclusions

Due to nonspecific clinical manifestation, cardiac amyloidosis can be misdiagnosed as a much more common aortic stenosis. Moreover, typical diagnostic examinations like echocardiography or MRI are unable to exclude cardiac amyloidosis. Scintigraphy should be performed as a part of diagnostic workup in cardiac patients suffering from cardiac distress with unknown etiology.

[1826] Treatment of coronary pseudoaneurysm in a patient with multivessel coronary disease ineligible for cardiac surgery.

Authors: Karolina Skonieczna

Affiliation: Collegium Medicum UMK in Bydgoszcz/Student Scientific Club of Cardiology/Department of Cardiology and Internal Medicine, Ludwik Rydygier Collegium Medicum in Bydgoszcz, Nicolaus Copernicus University in Toruń

Trustee of the paper: Piotr Niezgoda MD PhD, Collegium Medicum UMK in Bydgoszcz

Corresponding author: Karolina Skonieczna (karolina.skonieczna05@gmail.com)

Background

Multivessel heart disease is often associated with numerous coronary angioplasty procedures over the years. However, it increases the risk of complications related to this procedure, such as pseudoaneurysms. Patients with multivessel heart disease are often consulted by cardiothoracic surgeons and coronary artery bypass grafting is proposed. Unfortunately, some patients will not be able to qualify for the procedure due to numerous comorbidities. Data on the management of patients with multivessel disease complicated by a pseudoaneurysm and are not eligible for cardiac surgery are limited, which makes it difficult to make decisions regarding further treatment in these patients.

Case report

A 65-year-old patient was admitted to the Department of Cardiology for scheduled coronary angiography due to paroxysmal chest pain and dyspnea. 2 months earlier the patient was hospitalized due to NSTEMI myocardial infarction which was treated invasively by PCI of left main stem (1 DES stent) and right coronary artery (1 DES stent). The patient is burdened with many cardiological diseases, in connection with which he underwent CABG surgery in 2003 and coronary angioplasty with stent implantation to ramus intermedius and right coronary artery in 2015.

After admitting the patient to the Department of Cardiology, coronary angiography revealed three-vessel disease, an unobstructed LIMA-LAD graft and the presence of a pseudoaneurysm of the proximal segment of the right coronary artery, which was confirmed by angio-CT of the chest. Due to the patient's comorbidities and unacceptable risk of open-heart surgery, it was not possible to attempt CABG surgery. Instead, two stentgrafts were implanted in the right coronary artery to treat the pseudoaneurysm located there. The procedure was successful, the patient was qualified for conservative treatment and was discharged home in good general condition.

Conclusions

Coronary artery pseudoaneurysm is a rare but possibly a very dangerous complication of PCI with stent implantation, therefore there are no specific guidelines providing information about the management of this condition. This case presents one of the strategies that can be used to treat coronary pseudoaneurysms when undergoing CABG surgery is not an option due to patient's medical contraindications and excessive perioperative risk.

[1834] Diagnostic challenge of advanced primary cardiac angiosarcoma with non-specific symptomatology

Authors: Dominika Hanusek

Affiliation: Collegium Medicum , University of Warmia and Masuria, Olsztyn, Poland

Trustee of the paper: Centre Hospitalier Brugmann, Brussels, Belgium

Corresponding author: Dominika Aleksandra Hanusek (dominika.hanusek@student.uwm.edu.pl)

Background

Angiosarcomas of heart are rare pathologies, among cardiac malignances they occurs up to 33%. Despite modern diagnostic techniques, cardiac tumors aren't easily detected. The overall prognosis for all types of malignant tumors of heart is poor with median survival ratio 9-27 months. Treatment consists of total surgical resection, followed by chemotherapy. Localization next to pulmonary arteries and aorta, makes resection difficult and transplantation impossible.

Case report

49- years old women was admitted to the hospital emergency department because of non-specific epigastric abdominal pain. She was in a good general condition without any cardiac problems or comorbidities. Patient felt unwell since couple of days, she was constipated and had a feeling of swelling abdomen. At the physical examination: diffused abdominal pain, highly marked in the epigastric region, peristaltic was audible, abdomen swelling, no defense, inflammatory signs were negatives. There wasn't signs of heart failure, vascular examination was normal. Laboratory tests released C-protein elevated up to 28 [U/dl], hyperkalemia up to 6.9 [mmol/l].

At the CT scan pericardial effusion 25 mm thickness, hepatic swelling with diffuse ascites, may be secondary to the large pericardial effusion, followed by tamponade. In total 1150 cc of pericardial liquid was evacuated with content of blood. Further analysis confirmed malignant cytology similar to angiosarcoma metastasis. To find a primary source of malignancy the PET scan was performed. Examination confirmed presence of hypermetabolic mass in the right atrium, measured 4x2.3x5 cm. Echocardiography excluded valvular pathologies or ventricular dilatation, ultrasound guided needle biopsy confirmed an angiosarcoma. MRI evocated absence of distal metastasis. Patient was designated for surgery. Total resection was impossible and risky, due to infiltration of pulmonary vessels, ascending aorta and superior vena cava. We proposed a palliative treatment by chemotherapy. Patient received in total 3 cures of Doxorubicin.

Conclusions

Typical cardiac angiosarcomas occurs right atrium, giving symptoms due to inflow and outflow obstruction of blood, presented as right heart failure or hemopericardium with dyspnea and hemoptysis. Poor and nonspecific symptomatology is common for primary cardiac tumors, that's why the diagnosis can be dismissed. This case shows, that the use of echocardiography for extended diagnostics is recommended to exclude cardiac pathological mass.

[1948] Iatrogenic perforation of aortic valve cusp as a complication of percutaneous coronary intervention. A case report.

Authors: Piotr Walczak, Mateusz Koziół

Affiliation: Department of Coronary Artery Disease and Heart Failure, Jagiellonian University Medical College, John Paul II Hospital, Kraków, Poland

Trustee of the paper: lek. Konrad Stępień, lek. Karol Nowak, dr hab. n. med. Jarosław Zalewski, dr hab. n. med. Andrzej Gackowski, prof. UJ

Corresponding author: Piotr Michał Walczak (piotr1.walczak@student.uj.edu.pl)

Background

The iatrogenic perforation of the aortic valve represents a very rare complication of percutaneous coronary intervention. Its approximate prevalence is 0.0001% and only 16 similar cases have been reported in the literature. Mostly clinical presentation is acute, and it results from the laceration or perforation of a cusp via the catheter.

Case report

A 64-year-old obese male, former smoker, was hospitalized due to de novo HFrEF diagnosis. The patient reported increased fatigue, episodes of chest pain and palpitations during physical activity in the past 1-2 years (NYHA II, CCS II). Echocardiography revealed decreased left ventricular ejection fraction (LVEF) (25-30%), akinesia of the basal and middle segments of the inferior wall and hypokinesia of the remaining left ventricle segments, without significant valve pathologies. Angiography revealed significant proximal left anterior descending artery (LAD) stenosis. Catheterisation of right coronary artery (RCA) required multiple diagnostic catheters and the injection was sub-selective. Significant proximal stenosis of RCA was suspected. RCA intubation was achieved and finally the significance of RCA stenosis was ruled out. The LAD was successfully treated with DES implantation. The asymptomatic patient was discharged with a scheduled admission in 3 months for re-evaluation and ICD qualification. After 3 months the patient reported a reduction of previously reported symptoms (NYHA I, CCS I). There was no fever or other signs of inflammation. CRP was normal. As previously, the global left ventricular hypokinesia was visualized in echocardiography, however, with an increase in LVEF up to 40%. Moreover, the presence of previously absent mobile subvalvular structure in left ventricular outflow tract (up to 8 mm) was stated. It was confirmed by transesophageal echocardiography showing moderate/severe aortic regurgitation due to iatrogenic perforation of the non-coronary cusp. The patient was again presented to Heart Team and qualified to surgical valve replacement, which was successfully performed. The postoperative course was uneventful. The patient was discharged in good general condition.

Conclusions

In our case diagnostically crucial is the differentiation with infective endocarditis. According to the largest systematic review, aortic valve replacement is the most common treatment. In accordance with the current guidelines, the Heart Team is decisive in qualifying for the appropriate treatment method of that rare complication.

[1986] Difficulties in therapeutic management in a patient with myocardial infarction during extensive non-cardiac surgery

Authors: Olimpia Wiciun, Karolina Skonieczna

Affiliation: Ludwik Rydygier Collegium Medicum in Bydgoszcz, Nicolaus Copernicus University in Torun/Student of Scientific Club of Cardiology/Department of Cardiology and Internal Medicine

Trustee of the paper: Piotr Niezgodą MD PhD, Ludwik Rydygier Collegium Medicum in Bydgoszcz, Nicolaus Copernicus University in Torun

Corresponding author: Olimpia Wiciun (olimpia.ca@wp.pl)

Background

It is estimated that every year several hundred thousand patients undergoing non-cardiac surgery suffer from serious cardiovascular complications in the perioperative period and one of which is myocardial infarction. Treatment of this condition includes usage of anticoagulants which prevent the formation of blood clots and allow its dissolution however they also contribute to an increased risk of bleeding which can be very dangerous in fresh postoperative wounds. Therefore the therapeutic management in the case of perioperative myocardial infarction is not well specified.

Case report

A 68-year-old patient was transferred to the Department of Cardiology from the Department of Oncological Surgery, due to inferior wall myocardial infarction, complicated by acute respiratory failure and cardiogenic shock, which occurred during gastrectomy because of gastric cancer. The patient, in a serious general condition, intubated (mechanically ventilated), receiving intravenous catecholamines, was immediately transported to the cath lab for coronary angiography. The patient had a very high risk of cardiovascular events as a consequence of previous myocardial infarction treated invasively and several comorbidities including arterial hypertension, hyperlipidemia and type 2 diabetes mellitus. Coronary angiography revealed total occlusion of the right coronary artery, therefore balloon angioplasty was performed without stent implantation due to the impossibility of administering antiplatelet drugs orally. The vessel was revascularized and TIMI 3 flow was restored. Final angioplasty with stent implantation was planned one month after index hospitalization. On day 3, the patient was extubated, and on day 5th it was confirmed there was no leakage through the gastrointestinal anastomosis and so it was decided to start the antiplatelet therapy but with one antiplatelet drug only due to the high risk of bleeding complications. On day 7th in a stable condition, the patient was transferred back to the Oncological Surgery Department for further treatment.

Conclusions

This case highlights myocardial infarction that may occur within periprocedural period may cause serious difficulties regarding appropriate pharmacotherapy and coronary interventions especially in patients undergoing gastrectomy. Data on therapeutic management in this area are limited and the development of such strategies would enable a better prevention and treatment of perioperative cardiovascular complications.

[1988] TREATMENT OF A PATIENT WITH CONGENITAL CARDIAC DEFECT AND POST-TRANSPLANT LYMPHOPROLIFERATIVE DISORDER WITH ANTHRACYCLINES

Authors: Klaudia Zielonka

Affiliation: Medical University of Warsaw, Department of Hematology, Transplantation and Internal Medicine

Trustee of the paper: dr n. med. Joanna Drozd-Sokołowska

Corresponding author: Klaudia Zielonka (klaudiazielonka99@gmail.com)

Background

Left ventricular outflow tract obstruction (LVOTO) is a disrupted ejection of blood from the left ventricle (LV) of the heart due to stenosis. Post-transplant lymphoproliferative disorder (PTLD) is a serious complication of transplantations, including an orthotopic liver transplantation (oLT), linked to Epstein-Barr Virus (EBV) in most cases. Treatment of monomorphic PTLD is response-adapted and may require anthracyclines-containing chemoimmunotherapy. Currently, there is no data regarding the use of anthracyclines in patients with congenital cardiac defects including LVOTO. Herein, we report a case of a patient with LVOTO who was treated with anthracyclines without deterioration of the cardiac function.

Case report

A 22-year old patient after oLT for autoimmune hepatitis was diagnosed with monomorphic PTLD, diffuse large B-cell lymphoma EBV+ (DLBCL), clinical stage IV according to Lugano classification due to extensive extranodal involvement of different organs within abdominal cavity and pelvis. In anamnesis, LVOTO subaortic stenosis had been diagnosed upon the qualification for oLT. The patient did not have any symptoms of her heart defect.

Initial PTLD management comprised immunosuppressive therapy reduction and 4 doses of rituximab (375 mg/m²) administered weekly. Complete metabolic remission (mCR) as assessed by PET-CT imaging was not obtained. Despite LVOTO and unspecified risk of anthracyclines-induced cardiomyopathy in such patients, the decision to switch to R-CHOP (rituximab, cyclophosphamide, doxorubicin, vincristine, prednisone) chemoimmunotherapy was made. Prior to each R-CHOP cycle, cardiac function was monitored by LV ejection fraction in echocardiography and remained stable (equal to 60%) while cardiac biomarkers (NT-proBNP and troponin) concentrations remained within normal limits. The patient received 4 cycles of R-CHOP as per protocol and achieved mCR without the deterioration of her cardiac function.

Conclusions

Use of anthracyclines in the presented patient with LVOTO and PTLD was not associated with the deterioration of the cardiac function. Hypothetically, in cases with normal myocardium function before treatment and LVOTO, use of anthracyclines is not associated with an increased risk of cardiotoxicity in comparison to that observed in a general population. Further research is needed to enable formulation of dedicated recommendations for this group.

[1995] No time to... fall - a case of new hope in the treatment of mixed type vasovagal syncope.

Authors: Patryk Pindlowski, Jakub Kosma Rokicki MD

Affiliation: 1st Chair and Department of Cardiology, Medical University of Warsaw, Warsaw, Poland

Trustee of the paper: Jakub Kosma Rokicki, MD

Corresponding author: Patryk Pindlowski (ppindlowski@gmail.com)

Background

The most common cause of temporary loss of consciousness is vasovagal syncope (VVS) due to transient global cerebral hypoperfusion. VVS it is the result of an abnormal reflex reaction leading to peripheral vasodilation with subsequent hypotension or bradycardia. It's a condition that can cause an injury, has a significant impact on everyday life, worsening mental health and reducing the quality of life. Midodrine is a prodrug, agonist of alfa1-adrenergic receptor which may help to prevent VVS.

Case report

A 25-year-old woman with recurrent syncope since 3 year with most number episodes of fainting per year was 11. The VVS occurs mostly in standing position, occasionally sitting, in tight and crowded rooms and after exercise. During syncope patient is complaining about palpitations, sometimes fast heart rate. Woman also has severe headache and malaise. Several tests were performed to find the cause of disease. MR, doppler ultrasound of carotid arteries, holter ECG (no bradycardia) and EEG was normal. Echocardiogram (LVEF 58%) was also without any abnormalities. She also admitted that her mother suddenly died at the age 41 and brother at the age 26, father had atrial fibrillation. A passive tilt test was performed to find a cause of syncope. During procedure patient performed: tachycardia (HR max: 134/min), after 2 minutes sinus rhythm (HR:94/min), then 2:1 AV block (5 sec), next was PEA (3,5 sec), at the end nodal rhythm (HR:42/min) with syncope. 5 minutes after that test woman regained consciousness. After this it was decided to implant an arrhythmia monitor BIOMONITOR III. Implantable Cardiac Monitor (ICM) started working on June 2020. Since implantation there was no significant bradycardia which could explain syncope or other symptoms. No alarming values have been recorded, but symptoms of the disease didn't disappeared. On 05.2022 it was decided to include midodrine in the treatment. After one month of using the drug, every symptoms including: headache or bad mood has ended. There were no episodes of fainting. Heart rate hasn't changed, and heart rate variability was the same as before. None of side effects of midodrine occurred.

Conclusions

In patients with no explanation of recurrent mixed type of VVS, and midodrine can be consider in treatment. It's significantly effective, safe and underrated.

Emergency Case Report

Date: 22nd April 2023, 15:15 PM

Coordinators:
Łukasz Sęczyk
Bulganmaa Enebish

[1552] Effectiveness of rehabilitation for the patient after traumatic myelopathy

Authors: Paulina Petkevičiūtė, Justina Valinčiūtė

Affiliation: Lithuanian University of Health Sciences, Faculty of Medicine, Kaunas, Lithuania

Trustee of the paper: MD Laura Petrusevičienė

Corresponding author: Paulina Petkevičiūtė (paulina.petkeviciute@gmail.com)

Background

Spinal cord injury (SCI) – damage to the spinal cord from trauma, disease, or degeneration. The estimated annual incidence is around 40 to 80 cases per million population globally. Up to 90% of SCI are due to traumatic events such as road traffic crashes, falls, or violence.

Case report

A 24-year-old woman was hospitalized after a motorcycle accident and complained of legs weakness. A magnetic resonance imaging of the spine revealed a fracture of the Th6 vertebra, resulting in absolute stenosis of the spinal canal and visible traumatic myelopathy in the Th5-Th6 level. After neurosurgical treatment the patient was hospitalized in the neurorehabilitation department and spent 98 days there. During that time, the patient received physical therapy, occupational therapy, massage, physiotherapy, and psychological consultations. Changes in muscle strength of the limbs according to the Lovett scale at the beginning and end of rehabilitation: in the right arm proximally from 4 to 5, distally from 4 to 5, in the left arm proximally from 3 to 5, distally from 2 to 4, in the right leg proximally from 0 to 1, distally from 0 to 1, in the left leg proximally from 0 to 3, distally from 0 to 3 points. To assess hand strength dynamometry was evaluated and results enhanced in the right hand from 20.5 to 36 kg, and in the left hand from 3.3 to 28 kg. Functional independence test results changed from 39 to 84 points. Barthel index results improved from 10 to 35 points. Over the year, the patient underwent rehabilitation 3 more times, the total duration of which was 138 days. Unfortunately, at that time the strength of the right leg remained 1 point, but after the last hospitalization, during which additional repetitive transcranial magnetic stimulation (rTMS) was applied, the muscle strength of the right leg increased to 2 points, both proximally and distally.

Conclusions

The patient's young age and individual rehabilitation, during which rTMS was applied, led to good functional results after this type of trauma. Researchers from all over the world are investigating the therapeutic indications of rTMS, and various indications for use are emerging. We hope that more research will emerge analysing the benefits of rTMS after traumatic spinal cord injury.

[1726] Should a patient with IPF and end-stage renal disease be treated with antifibrotic drugs?

Authors: Karolina Siemiątkowska

Affiliation: Department of Nephrology, Dialysis and Internal Medicine, Medical University of Warsaw

Trustee of the paper: Zuzanna Jakubowska, MD

Corresponding author: Karolina Siemiątkowska (ksiemiatkowska32@gmail.com)

Background

Idiopathic pulmonary fibrosis (IPF) is a chronic, progressive fibrotic disease of the lower respiratory tract. It usually occurs in older people, mostly after 50 years of age, more often in men and smokers. IPF is associated with a poor prognosis with a 3-year mortality rate of up to 50% when without antifibrotic treatment. Currently, the treatment and prevention of progression in IPF consist of therapy with anti-fibrotic drugs. Co-occurrence of IPF and end-stage renal disease is a difficult clinical situation in terms of initiation of this treatment.

Case report

A 70-year-old chronically hemodialyzed man with end-stage renal disease caused by polycystic kidney disease and suffering from interstitial lung disease was admitted to the Nephrology Department due to aggravation of breathlessness and decreased exercise tolerance. After the exclusion of hypervolemia and circulatory stasis, pulmonary diagnostics were extended. High-resolution CT of the lungs showed a progression of images typical for UIP (usual interstitial pneumonia). Plethysmography was performed and restriction without obstruction was found. In cooperation with the Rheumatology Institute, connective tissue diseases that could be the cause of interstitial lung disease were excluded. Subsequently, the patient was consulted by a pulmonologist who advised referral to the Interstitial Disease Clinic and consideration of starting treatment with antifibrotic drugs due to IPF.

Conclusions

A correct diagnosis of IPF in this patient revealed the problem of co-occurrence the end-stage renal disease and this type of interstitial lung disease. Antifibrotic drugs give a chance to slow down the progression of IPF but have not been used in patients with end-stage renal disease until now. As antifibrotic drugs are currently gaining more and more indications for use, it is important to conduct broader research on this topic.

[1774] Emergency decompression of cardiac tamponade following percutaneous coronary intervention- modified surgical approach

Authors: Aleksandra Barabasz, Stanisław Dudek

Affiliation: 2nd Department of Anesthesiology and Intensive Care, Medical University of Warsaw, Poland. Department of Descriptive and Clinical Anatomy, Medical University of Warsaw, Warsaw Poland

Trustee of the paper: Bartosz Sadownik MD

Corresponding author: Aleksandra Barabasz (ola.barabasz@gmail.com)

Background

Cardiac tamponade belongs to reversible causes of cardiac arrest. If it occurs, pericardiocentesis or surgical approach should be performed. Additionally, in case of cardiac arrest with tamponade and failure of pericardiocentesis, guidelines provide us with another method of treatment – a resuscitative thoracotomy

Case report

A 69-year-old female presented with a sudden onset of hypotension and desaturation during an elective percutaneous intervention. Echocardiographic examination has revealed cardiac tamponade with 7mm of pericardial effusion.

After a few minutes, the patient's clinical condition deteriorated. Repeated echocardiography showed 15 mm of fluid in the pericardium. Despite intensified therapy, patient's clinical condition progressed to cardiac arrest with PEA. ALS was applied by the Medical Emergency Team. In the meantime, unsuccessful attempts at pericardiocentesis were made.

Considering failure of pericardial drainage and the long estimated arrival time of the cardiac surgeon, the decision on resuscitative thoracotomy was made. Due to a lack of equipment the Resuscitation Team decided to make an incision under the rib arches using available basic surgical tools. The diaphragm was visualized, incised, and dilated which gave direct access to the pericardial sac. The tamponade was directly punctured and decompressed, achieving ROSC. Initial evaluation of internal organs revealed no visible injury with minimal blood loss during procedure.

After 7 minutes of hemodynamic stabilization, hypotension and bradycardia were developed. USG reassessment revealed akinesis of the left ventricle and absence of signs of pericardial effusion, pointing to severe myocardial infarction. Due to BP of 40/20 mmHg, high efficiency direct cardiac massage was applied through a previously created incision. During procedure, SBP over 130 mmHg was generated. Cardiac massage was performed for 45 minutes. Then sternotomy was done by cardiac surgeon, who revealed akinesis of the left ventricle and massive coronary thrombosis.

After 2 hours, in the absence of surgical treatment options, intensive resuscitation efforts were withheld.

Conclusions

The decision on emergency room thoracotomy was made despite of lack of equipment. The procedure described in this case is unique due to the applied methods of proceeding. Direct access created with modified surgical approach can provide us with highly efficient pericardial drainage and direct cardiac massage.

[1788] From the suspicion of the meconium aspiration syndrome to the diagnosis of the total anomalous pulmonary venous return – the significance of prenatal diagnostic tests based on the case study

Authors: Zofia Kurek

Affiliation: Students' Scientific Group of Neonatology and Neonatal Intensive Care, Department of Neonatology, Princess Anna Mazowiecka Clinical Hospital in Warsaw

Trustee of the paper: Agata Wójcik-Sęp, MD

Corresponding author: Zofia Kurek (kurekzofia@icloud.com)

Background

Total anomalous pulmonary venous return (TAPVR) is a rare congenital heart disease (the incidence: 0,6- 1,2/10000 live births) in which all pulmonary veins are not connected to the left atrium. Instead, oxygenated blood returns to the right atrium and reaches the systemic circulation through the persistent foramen ovale. It results in hypoxia and volume overload of the right atrium and ventricle. If it remains undetected, it can be fatal, therefore an immediate cardiac surgery is necessary.

Case report

A female newborn, weighing 3670 g, born by a natural delivery from an uncomplicated, first and carried to term pregnancy, was transferred on the first day of its life to the Neonatal Intensive Care Unit in the Princess Anna Mazowiecka Clinical Hospital in Warsaw due to respiratory failure and the suspicion of the meconium aspiration syndrome. The Apgar scores were 9-8-8, and the newborn needed Neopuff ventilation. After the admission, features of pulmonary hypertension and circulatory failure were found, and the pneumothorax was confirmed in an X-ray examination. Despite the treatment, no improvement was obtained and it prompted to perform echocardiography that revealed the presence of the supracardiac TAPVR. The newborn was transferred in unstable condition to the Children's Memorial Health Institute in Warsaw for further treatment.

Conclusions

This case study highlights the importance of prenatal diagnostic tests, also in uncomplicated pregnancies. The fetal examinations increase the chance of establishing the diagnosis before birth and enable organizing a delivery in a hospital with a specialized ward, minimizing the risk of complications due to delay in implementation of an effective treatment.

[1823] Removal of an aspirated tooth from the bronchus using a cryoprobe: a case report.

Authors: Katarzyna Kwapisz, Maja Olczyk

Affiliation: SKN Iron Lung, Klinika Chorób Wewnętrznych, Pneumonologii, Alergologii i Immunologii Klinicznej

Trustee of the paper: Michał Rząd MD

Corresponding author: Katarzyna Kwapisz (kwapiszkasia64@gmail.com)

Background

Cryobiopsy is a medical procedure that is used as a technique to collect tissue material for diagnostic testing. The expansion of the gas at the end of the cryoprobe causes a rapid decrease in its temperature, which leads to the adhesion of frozen organic tissue around the probe.

Case report

This case presents an unusual use of cryoprobe as a method of removing a foreign body (molar tooth) from the trachea. The procedure was performed in a 70-year-old patient who suffered a multi-organ injury during a fall from a height. The patient remained without verbal-logical contact (GCS 5). His airway was secured by creating a tracheostomy. The patient had recurrent fevers. Fluctuating levels of inflammatory markers and respiratory failure were observed. On several occasions, after his vital signs were stabilized, the patient was discharged from the hospital to a long-term care facility, and then readmitted to the hospital because of recurrent symptoms of pneumonia and aggravation of respiratory failure. Follow-up chest x-rays showed no abnormalities other than the presence of inflammatory changes at the time of exacerbations. Due to recurrent radiological signs of pneumonia and elevated D-dimers, angio-CT was performed, which revealed a hyperdense foreign body in the bronchus to the lower lobe of the right lung.

Due to the ineffectiveness of other endoscopic methods, such as grasping the foreign body with forceps, a basket or pulling it out with a Fogarty catheter, cryosonde was used during bronchoscopy. Covering the hard foreign body with a small amount of liquid allowed it to be frozen to the instrument. It was then extracted through the tracheostomy opening, pulling the cryoprobe and bronchoscope together.

Conclusions

The occurrence of recurrent respiratory tract infections requires further diagnosis, including but not limited to a CT scan. One of the causes of these conditions may be the presence of a foreign body in the airway. The use of a cryoprobe can be an effective method of removing foreign bodies from the airway, and with the use of additional fluid, also those that are poorly susceptible to freezing.

[1907] Coronary artery embolism - the root of an atypical Myocardial Infarction

Authors: Michał Pałuchowski

Affiliation: Medical University of Warsaw / Department of Cardiology

Trustee of the paper: Aleksandra Gąsecka MD, PhD

Corresponding author: Michał Marcin Pałuchowski (mich.paluchowski@gmail.com)

Background

Coronary artery embolism is a rare cause of myocardial infarction (MI). Its incidence is not accurately defined as the diagnosis process poses many difficulties. It is estimated that 4 to 7% of all patients with MI do not have coronary artery disease. One of the conducted autopsy studies has revealed coronary artery embolic infarction in 13% of patients.

Case report

A 59-year-old patient was admitted to the emergency room from Chopin Airport due to MI with ST-segment elevation. The patient was traveling from the United States via Paris to Warsaw. Since the landing in Paris, he had had several episodes of vomiting accompanied by chest tightness. His medical record mentioned the implantation of 3 stents into the anterior descending branch and lipid disorders.

Directly from the emergency room, the patient was transferred to the invasive cardiology department, where coronary angiography revealed sufficient blood flow in the anterior descending branch, 50% stenosis in the marginal and right coronary artery, and peripheral embolization in the posterolateral branch. Due to the embolic cause of vessel closure, the patient was qualified for further pharmacological treatment. Acetylsalicylic acid, clopidogrel, PPI, and the patient's medications (lisinopril, atorvastatin) were administered. On admission to the intensive care unit, the patient was in good general condition, without chest pain, circulatory efficient. The ECG revealed the resolution of ST-segment elevation.

Conclusions

The most probable cause of the event was an embolus that arose in the lower limbs during a long air travel. It presumably passed through a patent foramen ovale from the right to the left atrium during the "natural" Valsalva maneuver as the patient vomited on the plane and then suddenly felt a pain in his chest.

Coronary artery embolism should not be excluded in the differential diagnosis of MI, despite its rare prevalence. Practitioners should take it into consideration especially in patients presenting with high thromboembolic risk factors.

[1921] Use of Percutaneous Left Ventricular Assist Device (Impella) and Veno-Artery Extracorporeal Membrane Oxygenation (VA-ECMO) for Severe Ischemic Cardiogenic Shock; Case Study

Authors: Agnieszka Kamińska, Wojciech Górski

Affiliation: Cardinal Stefan Wyszyński University

Trustee of the paper: Student Scientific Circle of Anaesthesiology and Intensive Therapy UKSW at PIM MSWiA and IP CZD in Warsaw

Corresponding author: Agnieszka Kamińska (akami6@wp.pl)

Background

Cardiogenic shock is an extreme form of heart failure, which results in a decrease in its output below 2.2 l/min/m². Its most common cause is acute myocardial infarction. In extreme cases, there is a possibility of extracorporeal unloading of the left ventricle and increasing cardiac output by various invasive methods.

This paper presents the case of a ??-year-old man treated at the Department of Anaesthesiology and Intensive Therapy of the State Medical Institute of the Ministry of Interior and Administration in Warsaw, who was treated with a complex extracorporeal therapy consisting of an Impella microaxial pump and VA ECMO as part of the treatment of cardiogenic shock.

Case report

A patient was admitted to the hospital due to a multi-place injury he suffered after a fall from a height of 7 m. He was hospitalized at the Department of Trauma, no neurological deficits were found in him. The patient reported shortness of breath, so passive oxygen therapy was applied, and then right pleural drainage was placed. Then he was transported to the Intensive Care Unit of MSWiA.

On the second day of hospitalization, the patient reported worsening dyspnoea. ECG was done, after which the suspicion of ACS was raised. The patient underwent coronary angioplasty, and then he was qualified for CABG.

Next day, there was a SCA in the VF mechanism. CPR was started and normal heart rhythm was restored. The Heart Team qualified the patient for angioplasty of the left main coronary artery in the Impella device.

Implantation of the Impella left ventricular assist device was performed. Due to the features of renal failure, anuria and increasing renal parameters, it was necessary to start continuous dialysis.

Due to the exhaustion of the possibilities of effective cardiac treatment and the deteriorating haemodynamic condition of the patient, a decision was made to apply VA-ECMO. This allowed to stabilize the patient's circulatory system.

After 2 weeks, when the circulatory system was stable, it was decided to abandon VA ECMO. Subsequently, the Impella device was removed and the supply of catecholamines was reduced.

After 10 days, the patient bled from anal and rectal varices and went into hemorrhagic shock. However, the patient's condition deteriorated and multiple organ failure persisted despite intensive therapy.

Conclusions

The use of Impella and VA-ECMO in a patient in cardiogenic shock enabled temporary circulatory stabilization.

[1926] Song of Fire and Ice – is it possible to survive with hemoglobin 1.7?

Authors: Paweł Siuciak

Affiliation: Medical University of Gdańsk, Department of Hematology & Transplantology

Trustee of the paper: Dr Ewa Zarzycka

Corresponding author: Paweł Siuciak (psiuciak99@gmail.com)

Background

Mixed autoimmune hemolytic anemia (MAIHA) is rare (<1/1 000 000) type of anemia in which there is the presence of both warm and cold autoantibodies. Because of that the course of the disease can be quite unpredictable.

Case report

A 50-year-old female patient was admitted to the emergency room due to impaired consciousness, jaundice, and life-threatening anemia. The family of the patient reported skin changes – livedo reticularis and escalating weakness that started a few days before. A head CT revealed changes like in brain edema. Laboratory tests showed signs of hemolysis (LDH 1828U/L, BIL 6.88mg/dl) with extremely low hemoglobin level (Hb 1.7g/dl) and isolated AST and ALT increase with other liver enzymes, aPTT and INR staying within the normal range. Blood smear revealed presence of spherocytes. Direct antiglobulin test for autoantibodies IgG and IgM was performed – the results were positive for both. The diagnosis was made – mixed type autoimmune hemolytic anemia. Aggressive treatment with rituximab, bortezomib, cyclophosphamide, IVIG, and plasmapheresis was started. Meanwhile, CT and MR of the abdomen were performed which revealed thrombosis of the left portal vein. Anticoagulation treatment with enoxaparin was initiated. In search of the cause autoimmune disease tests and genetic test for JAK2V617F mutation were carried out – all returned negative. It was concluded that the thrombosis was a result of a hypercoagulable state associated with severe hemolysis.

The patient's condition significantly improved and on the 9th day blood transfusions were stopped. After two weeks of hospitalization the patient was discharged from the hospital following neurological consultation – no neurological deficits were noted. The patient returned to their normal routine.

Conclusions

This case shows that it is possible to survive and return to health without any neurological deficits after episode of very severe hemolytic anemia. Also, it is worth to note that brain edema isn't well established symptom of autoimmune hemolytic anemia hence it is important to keep an open mind during diagnosis of such rare and complex diseases such as MAIHA.

[1931] Loss of vision after ignoring the first symptoms in a contact lens wearer.

Authors: Łukasz Biesiadecki

Affiliation: Medical University of Warsaw, First Department of Ophthalmology

Trustee of the paper: Piotr Maciejewicz MD PhD

Corresponding author: Łukasz Adam Biesiadecki (lbiesiadecki2001@gmail.com)

Background

The purpose of the presentation is to remind of the importance of urgent medical examination of patients with acute ophthalmic symptoms. Contact lenses are a widely used method of correcting refractive disorders. Their usage is associated with corneal scratches and conjunctival hyperemia. When the first symptoms are neglected can also cause vision-threatening infection and ulceration of the cornea.

Case report

A 37-year-old myopic patient was referred from an addiction treatment clinic to an emergency department with general symptoms. General examination revealed that ophthalmic symptoms require hospitalization in an ophthalmology department with the risk of permanent loss of vision in the left eye. The patient reported pain in the left eye lasting four days, photophobia, and loss of vision in the left eye. The examination revealed bacterial keratitis. The patient was infected with HIV and HCV, addicted to heroin (on replacement treatment), and on antiviral and antidepressant therapy. Microbiological and additional examinations were performed. Elective local and general antibiotic therapy and intraocular injections of antibiotics were implemented. Reduction of inflammation and improvement of vision was obtained. After eleven days of hospitalization, further outpatient treatment was ordered, which the patient neglected and continued to use contact lenses. Two months later the patient was referred to the ophthalmologist with a history of pain and loss of vision in the right eye. The patient again disregarded symptoms for six days. The patient was admitted to the ophthalmology department with keratitis of the right cornea. After nine days of hospitalization and partial improvement of vision in the right eye. The ophthalmological examination revealed a severe vision deficit in both eyes. The patient was discharged on request.

Conclusions

The case shows how disregarding the first symptoms can lead to severe complications. If the patient had come for an ophthalmologist consultation a few days earlier, there probably would have been no permanent vision damage. To prevent contact lenses-related complications, initial specialist consultation is needed. Specifically in a patient with contradictions or a potential immunodeficiency.

[1934] A multidisciplinary approach to the treatment of salivary malignant cancer of right parotid gland in 44-years old male patient - case report

Authors: Karol Paradowski, Oliwia Burdan, Antoni Błaszczyk, Grzegorz Kurec, Julia Pawłowska 1

Affiliation: 1 Student Scientific Association by Department of Clinical Oncology and Chemotherapy, Medical University in Lublin, Lublin, Poland 2 Department of Clinical Oncology and Chemotherapy, Medical University in Lublin, 8 Jaczewski Street 20-090 Lublin, Poland

Trustee of the paper: lek. med. Katarzyna Szklener 2

Corresponding author: Karol Henryk Paradowski (karol.paradowski66@gmail.com)

Background

Malignant tumors of the salivary glands account for approximately 2–3% of head and neck tumors. Most tumors are found in the large salivary glands, most commonly the salivary gland. Around 20% of parotid tumors are malignant, circa 2/3 of the benign parotid tumors are pleomorphic adenomas. Large salivary glands usually require a lot of complex therapeutic systems due to late detection and proliferative features of the tumor quickly occupying many nerves and vessels, which makes it difficult to remove the lesion.

Case report

Two years ago, a 44-year-old patient reported to the Neurology Department in Military Hospital in Lublin with sudden symptoms of weakness of the right corner of the mouth. The neurological examination revealed a central lesion of the VII nerve on the right side. Possible AICA loop recognized. About a year later, the MRI revealed an ambiguous infiltration of the right parotid gland. Material was collected with the help of FNAB, on the basis of which a possible diagnosis was made in histopathological examination: suspect of Warthin's tumor. Parotidectomy and lymphadenectomy were performed on the right side - histopathological examination showed ductal carcinoma of the right parotid gland and numerous metastases to the lymph nodes. The patient was given an oncology card. In the further course of treatment, the patient underwent radiotherapy. The healing process of patient in the Department of Clinical Oncology and Chemotherapy, Medical University in Lublin is in progress.

Conclusions

Malignant tumors of the parotid glands are a huge therapeutic challenge for physicians of many specialties and require a multidisciplinary approach. The anatomical features of the arrangement of vessels and nerves is an unfavorable feature of the area of surgical intervention, and late onset of symptoms, and thus detection, reduces the effectiveness of oncological treatment. For these reasons, it is important to remember the role of oncological prophylaxis and to quickly detect disturbing craniofacial changes in order to prevent the progression of the disease or the formation of metastases.

[1970] Facial and cranial bone reconstruction as a consequence of injuries sustained in a motorcycle accident in a 19-year-old patient.

Authors: Palina Skipar, Alicja Kowalewska

Affiliation: Medical University of Warsaw / Department of Cranio-Maxillofacial Surgery, Oral Surgery and Implantology

Trustee of the paper: Zygmunt Stopa

Corresponding author: Palina Skipor (polinaskipor@gmail.com)

Background

Maxillofacial injuries resulting from motorcycle accidents are a significant clinical problem that requires an interdisciplinary approach to patient care. According to current regulations, motorcyclists should wear appropriate protective helmets; however, not every helmet provides equal protection. A thorough physical examination and the use of diagnostic imaging are essential for proper preparation for surgical procedures, which are crucial due to the location of the reconstructed area and their impact on the patient's quality of life. Such an approach allows for achieving satisfactory results after surgery.

Case report

A 19-year-old patient was admitted to the Department of Craniofacial, Maxillofacial, and Oral Surgery and Implantology after being hospitalized in another facility due to head injuries sustained from a motorcycle accident in June 2022. Despite the use of preventive measures, the patient suffered severe maxillofacial injuries due to the motorcycle accident. The physical examination revealed facial asymmetry, scarring, left-sided facial depression, and changes in occlusion. The patient required reconstruction of the anterior cranial fossa and the left maxillofacial bones due to the facial injuries sustained and medical procedures undertaken to save the patient's life. The preparation for surgery included extraction of teeth 18 and 28 and removal of titanium miniplates. During the surgery, an osteotomy of the zygomatic arch was performed on the left side, stabilizing it on the lateral edge of the orbit. The orbital hernia was reduced, a titanium mesh was placed, and the lower edge of the orbit was sutured using microscrews. The nasal bone was repositioned, and the upper edge of the left orbit was reconstructed. A thorough physical examination and the use of diagnostic imaging were essential for proper preparation for the surgery. Utilization of pictures of the patient's face that display the enhancement of the patient's facial appearance following the surgical procedure. The operation went successfully and without complications, and it yielded satisfying results.

Conclusions

Satisfactory functional and aesthetic results were achieved due to maxillofacial reconstruction. This surgery enabled further orthodontic treatment to restore the occlusion conditions before the accident.

Gynecological Case Report

Date: 22nd April 2023, 15:15 PM

Coordinators:
Aleksandra Śliwka
Weronika Fortuniak

[1526] Successful pregnancy in karyotype 46,XY patient (Swyer's syndrome)

Authors: Augustė Žurauskaitė

Affiliation: ¹ Faculty of Medicine, Lithuanian University of Health Sciences, Kaunas, Lithuania;

²Lithuanian University of Health Sciences, Department of Anaesthesiology, Kaunas, Lithuania

Trustee of the paper: MD PhD Vilda Baliulienė

Corresponding author: Augustė Žurauskaitė (auguste.zurauskaite@inbox.lt)

Background

Complete gonadal dysgenesis (Swyer syndrome) is a rare disorder of sexual differentiation characterized by normal or low development of the external genitalia, uterus and fallopian tubes, with non-functioning gonads. The incidence of this rare condition is estimated to be approximately 1 per 80,000 births. Treatment of this condition is based on hormone replacement therapy and bilateral gonadectomy to prevent the development of gonadal tumor. Even though infertility resulting from aplastic gonads is a common problem among individuals with Swyer syndrome, oocyte donation is an effective method of fertilization, which enables affected women to become pregnant.

Case report

There is a presentation of a woman diagnosed by XY gonadal dysgenesis at the age of 16 years. The patient underwent a physical examination because of primary amenorrhea. Chromosome analysis revealed a 46 XY karyotype. Regarding the high risk of tumors, prophylactic bilateral gonadectomy was performed after diagnosis, followed by treatment with hormone replacement therapy to ensure normal puberty and bone mineral density formation. In 2009 years, Th4-Th5 spine correction and fixation surgery was performed due to idiopathic scoliosis. At the age of 34 years she underwent oocyte donation and IVF (Intracytoplasmic sperm injection procedure with donated oocyte). Day-3 embryo was transferred into her uterus successfully. The course of the pregnancy was smooth. At the 39th week of gestation, the patient was presented to the hospital because of possible leakage of amniotic fluid with some blood. It was decided to perform a C-section due to an adverse medical history and spinal fixation surgery. Spinal anesthesia was unsuccessful because it was not possible to localize the intervertebral space therefore general endotracheal anesthesia was performed. A healthy baby with an Apgar score of 9 was delivered. Further treatment was without complications.

Conclusions

This case report aimed to show that patients with Swyer syndrome may become pregnant without any major problems through assisted reproduction. Due to certain abnormalities in organ development, such cases may be higher-risk pregnancies. After delivery, hormone replacement therapy should be used for the preservation of bone health in all such patients.

[1577] Herpes simplex encephalitis in pregnancy

Authors: Julia Jurga

Affiliation: Jagiellonian University Medical College, Department of Obstetrics and Perinatology

Trustee of the paper: Magdalena Kotak, MD, PhD; Andrzej Jaworowski, MD, PhD

Corresponding author: Julia Katarzyna Jurga (jjurga@outlook.com)

Background

Herpes simplex encephalitis (HSE) is the most common sporadic cause of encephalitis, usually due to the relapse of HSV type 1 infection. It usually presents itself with headache, fever, impaired consciousness, and seizures. Characteristic changes in MRI and EEG as well as PCR confirmation of HSV presence in CSF are necessary for diagnosis. Without treatment, mortality reaches up to 70% and even when treated with acyclovir i.v., HSE is fatal in 20-30% of patients. More than half of the survivors of the HSE experience long-term neurological complications.

Case report

A 27-year-old woman who was 32+3 weeks pregnant (gravida 1, para 1) was transferred from the Neurology Department with the diagnosis of HSE. The day before she had experienced 3 seizures, possibly of tonic-clonic morphology, nausea and vomiting. On the day of admission patient's state of consciousness deteriorated (she was conscious, but with impaired auto- and allophysic orientation) with onset of fever and symptoms of meningitis. The diagnosis of HSE was based on characteristic MRI changes within the left temporal lobe and hippocampus and PCR confirmation of HSV type 1 presence in CSF. In line with consultations of neurologists and infectious diseases specialists, the patient was administered paracetamol i.v., acyclovir i.v., lamotrigine p.o. (later changed for levetiracetam p.o.), dexamethazon i.v., and later also enoxaparin i.m. After two days of treatment, the fever has ceased, and the patient has regained auto- and allophysic orientation. State of the fetus has been strictly monitored – apart from the periodic tachycardia no abnormalities have been found and there were no signs of possible premature birth. The patient was discharged at her own request after 25 days of hospitalization, with viable pregnancy, no recurrent seizures and residual bilateral positive Sterling, Jacobsohn, Hoffmann, Babinski and Chaddock reflexes. The baby boy was delivered at 37+3 weeks' gestation via cesarean section.

Conclusions

HSE in pregnant patients is usually diagnosed in 2nd and 3rd trimester, possibly due to the immunological shifts. Differential diagnosis should include e.g. eclampsia, venous sinus thrombosis and metabolic imbalances. The use of acyclovir in pregnancy is proved to be safe and is not associated with an increased rate of birth defects. Anti-epileptic drugs should be administered in lowest effective doses and treatment should be continued long-term, even after the delivery, to prevent further seizures.

[1606] Prenatal manifestation of progressive familial intrahepatic cholestasis type 5

Authors: Klaudia Łuczak

Affiliation: Department of Obstetrics, Perinatology and Gynecology, Medical University of Warsaw, Poland

Trustee of the paper: Przemysław Kosiński MD, PhD, Associate Professor

Corresponding author: Klaudia Łuczak (klaudialuczak99@gmail.com)

Background

Progressive familial intrahepatic cholestasis (PFIC) is a heterogeneous group of autosomal recessive disorders defined by defects in bile excretion and transport. PFIC type 5 is an exceedingly rare cause of rapidly progressive neonatal cholestasis leading to liver failure and death if liver transplant is not performed. To the best of our knowledge prenatal presentation of this disease has never been published before.

Case report

We present a case of a 27-year-old primigravida who was referred to Department of Obstetrics, Perinatology and Gynecology of Medical University of Warsaw at 24 weeks gestation due to bilateral hydrothorax. On the ultrasound scan the growth of the fetus was within normal ranges with normal amniotic fluid volume and Doppler flows. The fetus was severely hydropic (prenasal thickness of 15,9 mm) and there was severe bilateral hydrothorax. The anatomy of the baby was otherwise normal, and the microarray (aCGH) testing revealed no abnormalities. Invasive procedures such as cordocentesis and thoraco-amniotic shunt placement both to the left and right side were performed. The pleural drainage was temporarily successful, lung tissue was visible on both sides with mild pleural effusion. At 26 weeks of gestation further deterioration of fetal hydrops was noted with prenasal thickness measuring 18 mm. The patient started complaining on oedema, her blood test results revealed progressing mirror syndrome. Emergency cesarean section at 27 weeks and 3 days was performed as CTG tracing was abnormal and sudden deterioration in umbilical artery blood flow was noted. Male neonate was delivered with the birthweight 1300 g with APGAR score 1 in both 1 min and 5 min. Due to severe hydrops and cardiovascular arrest and despite intensive treatment the baby died on day 3 of life. Nonspecific prenatal presentation and rapidly progressive symptoms were the causes of genetic testing. Whole exome sequencing revealed that the patient was homozygous for the NRH1H4 mutation, which indicates the diagnosis of PFIC-5.

Conclusions

The case shows that progressive familial intrahepatic cholestasis type 5 may manifest not only during neonatal period, but also prenatally. Clinical features such as bilateral hydrothorax and severe hydrops may suggest PFIC-5 as a potential cause. Given the combination of severity and rarity of this disorder, additional reporting and research for the potential prenatal treatment and management strategies is greatly needed.

[1666] A case report of a 25-year-old patient with a complete hydatidiform mole

Authors: Piotr Rzychniok, Aleksandra Woskowska, Aleksandra Śledziwska

Affiliation: Medical Faculty, University of Opole

Trustee of the paper: Dariusz Kowalczyk PhD

Corresponding author: Aleksandra Maria Śledziwska (masledziwska@gmail.com)

Background

Hydatidiform mole is a benign form of gestational trophoblastic disease. It develops as a result of improper fertilization of the egg cell, which properly implants and proliferates in the uterus. There are two types of moles: complete and partial. The incidence, including both types, is estimated at 1 in 1000 pregnancies and 1 in 41 miscarriages in Europe and the USA.

Case report

A 25-year-old female patient was admitted to the gynecology department due to a suspicion of a hydatidiform mole. Two months earlier, a complete miscarriage was reported in the second month of the patient's first pregnancy. Vaginal bleeding continued since then. Laboratory tests showed anemia and significantly elevated levels of human chorionic gonadotropin, which were outside the normal range for the patient's period. An ultrasound examination was performed, which revealed a hydatidiform mole with pathological flows and bilateral multilocular ovarian cysts measuring 6x6.5 cm without the presence of fluid in the pouch of Douglas. After establishing the diagnosis, a decision was made to surgically remove the mole by vacuum evacuation under the guidance of transabdominal ultrasound and curettage of the uterine cavity. The procedure was successful. Tissues expelled during the procedure were sent for histopathological examination, which confirmed the presence of a complete hydatidiform mole. The level of beta HCG after the procedure significantly decreased.

Conclusions

Due to the presence of a mole in the population of pregnant women in the range of 1 permille, one should take into account the possibility of encountering a patient with the described condition in medical practice. Early diagnosis allows appropriate treatment to avoid adverse complications, such as transformation into choriocarcinoma, which may arise as a result of a persistent mole after surgical removal. Fast and proper treatment often allows patients with this medical condition to maintain normal reproductive functions.

[1679] A case of acute Sheehan's syndrome

Authors: Marcelina Grzelak, Katarzyna Mączka

Affiliation: Medical University of Warsaw

Trustee of the paper: dr n. med. Monika Grymowicz

Corresponding author: Marcelina Grzelak (marcelinegrzelak@gmail.com)

Background

Pituitary volume increases during pregnancy due to the hyperplasia of lactotrophs in anterior pituitary gland and hence the nutritional and metabolic demand by the anterior pituitary gland is increased. The blood supply of this part does not increase which, combined with severe postpartum hemorrhage, leads to a rare disorder named Sheehan syndrome. It results from ischemic necrosis of anterior pituitary during peripartum period leading to loss of one or more pituitary cell lines. The most common symptoms of an arisen hypopituitarism are lactation failure (due to prolactin deficiency), fatigue (due to corticotrophin and GH deficiency) and amenorrhea (due to gonadotrophin deficiency).

Case report

A 32-year-old patient was admitted to the hospital in Radom 30 week pregnant due to the central placental previa. In the 19th day of hospitalization, the patient experienced profuse vaginal bleeding. She was immediately transported to the delivery ward, where caesarean section was performed. Despite attempts to stop the bleeding with pharmacological agents and tamponing, atony of the uterus occurred. It was decided to perform hysterectomy without adnexa. After the procedure, the patient was in a serious general condition and hence she was transported to the ICU ward. In the 7th day after delivery, the patient was consulted by an anesthesiologist due to disturbances of consciousness and numbness of the body. The patient also reported deterioration of well-being, weakness, apathy, nausea, vomiting, tremors of the whole body and significant polyuria. On physical examination, fine-fascicular tremor of the limbs was noted. Laboratory tests showed increasing deep hyponatremia, hypokalemia, hypomagnesaemia, hypocalcemia. The T1- and T2-weighted images showed that the pituitary gland is enlarged. After the administration of the paramagnet, intensive contrast enhancement was obtained in the narrow periphery and a posterior fragment of the glandular part. MRI image strongly suggested ischemic stroke of the glandular part of the pituitary gland without noticeable hemorrhagic changes within and hence the patient was diagnosed with Sheehan's syndrome. Following treatment with mannitol, fludrocortisone, and infusions of NaCl solution, her condition improved.

Conclusions

Clinicians should pay attention to the possibility of an occurrence of Sheehan's syndrome after profuse bleeding during delivery. The supervision of the patients after such occurrences is crucial for quick diagnosis.

[1711] Rocky road to May-Thurner Syndrome diagnosis. A case report.

Authors: Dominika Kondyjowska, Marcin Wojnarski

Affiliation: Students' Scientific Group of Clinical Angiology, Jagiellonian University Medical College

Trustee of the paper: Łukasz Drelicharz, MD, PhD

Corresponding author: Dominika Kondyjowska (d.kondyjowska@gmail.com)

Background

May-Thurner Syndrome (MTS) is an anatomical condition in which there is compression of the left common iliac vein by the right common iliac artery causing venous outflow obstruction. The spectrum of symptoms of this disease is wide and includes pelvic pain, swelling of the extremities (more pronounced on the left side), or venous thrombosis in the iliac-femoral segment. The disease occurs in 2-5% of the population, but can often be masked by other diseases leading to pelvic pain conditions. The diagnosis of MTS is made based on the clinical picture of the characteristic image in phlebography.

Case report

A 40-year-old female patient with a long history of lower abdominal pain presented to the Angiology Department for a more extensive diagnosis. The patient has been diagnosed with endometriosis since she was 16 years old, and has been treated repeatedly with oral contraceptives without much improvement. During the second cesarean section, in 2010, some of the endometriosis foci were removed from the bladder and bowel. The procedure was performed twice more over the next 12 years. The patient was repeatedly denied further diagnosis, explaining that all the pain was caused by endometriosis. For several years, the pelvic pain was no longer exacerbated only during menstruation but also when sitting and standing - a suspicion of passive pelvic congestion was made. The patient was referred to the oncology department to rule out tumor pressure on the abdominal and pelvic venous vessels, but no malignant lesions were detected, so the patient was referred to an angiologist for further diagnosis. An ultrasound examination performed in the angiology department showed obstructed venous outflow. In phlebography, the left common iliac vein (LCIV) narrowed at the junction with the right iliac artery - significant compression of the left common iliac vein (May-Thurner syndrome) with subsequent passive pelvic congestion syndrome was confirmed. The patient was scheduled for a left iliac vein stent implantation.

Conclusions

May-Thurner syndrome is one of many causes of chronic lower abdominal pain, but the diagnosis of another cause does not relieve the search for other causes if treatment of the underlying disease has not reduced the pain. Based on this case, I would like to encourage routine vascular ultrasound in patients with chronic abdominal pain to look for vascular abnormalities, especially since the diagnosis of this syndrome is relatively simple, yet the syndrome is still underdiagnosed.

[1910] **The Retrograde Vein Approach as new effective way of treatment – a case report**

Authors: Eryk Mikos, Marcin Czeczelewski, Sara Moqbil

Affiliation: Students' Scientific Society at the Department of Interventional Radiology and Neuroradiology, Medical University of Lublin

Trustee of the paper: dr hab. n. med. Krzysztof Pyra, dr n. med. Maciej Szmygin

Corresponding author: Eryk Mikos (mikoseryk@gmail.com)

Background

Arteriovenous malformations (AVMs) are a rare congenital condition characterized by abnormal connections between arteries and veins, which can cause a range of symptoms, including pain and bleeding. AVMs are usually diagnosed during childhood or adolescence, but they can also be diagnosed in adulthood. AVMs located in the pelvis are particularly difficult to treat due to their proximity to vital organs and their complex vascular anatomy. Treatment options include embolization, surgical resection, and radiation therapy.

Case report

We report on a 28-year-old female who presented to the gynecological department with non-cyclic pelvic pain. A computed tomography scan of the abdomen and pelvis showed an AVM type IIIa by the Yakes Classification, located in the pelvis. The AVM had arterial supply from the right or left internal iliac and inferior mesenteric artery with a single outflow vein drainage towards the left iliac and ovarian vein. The patient underwent embolization of the feeding arteries, closure of the outflow vein from direct percutaneous access with needle-inserted coils, and obliteration of the malformation with ethanol. Control angiography performed immediately after the procedure and one year later showed no blood flow in the malformation.

Conclusions

This case highlights the effectiveness of embolization as a treatment option for AVM. However, type IIIa AVMs, which are characterized by multiple inflow arteries and an enlarged aneurysmal vein with fistulas present in the wall, require a different treatment approach. Closing the outflow vein from direct percutaneous access allows for the complete exclusion of the malformation from blood circulation. In cases where embolization is not feasible or effective, surgical resection or radiation therapy may be considered. Further research is needed to determine the optimal treatment approach for AVMs located in the pelvis.

[1932] Pregnancies after heart transplantation - a multidisciplinary challenge

Authors: Emilia Piotrkowicz

Affiliation: Medical University of Warsaw

Trustee of the paper: Ass. Prof. Zoulikha Jabiry-Zieniewicz, MD, PhD

Corresponding author: Emilia Piotrkowicz (emilia.piotrkowicz@student.wum.edu.pl)

Background

The first report of a pregnancy in a cardiac transplant recipient with good outcomes for both the mother and infant was described in Argentina in 1988. Eight years later, the first successful pregnancy in a heart transplant recipient was documented in Poland. Recommendations and reports of maternal and fetal outcomes of pregnancy amongst women who are cardiac transplant recipients are relatively limited in the current literature. This proves, how crucial reporting those pregnancies is.

Case report

A 24-year-old woman was admitted to the clinic in the 7th week of pregnancy, 6 years after heart transplantation for dilated cardiomyopathy. Immunosuppressive therapy included Tacrolimus (5 mg/day) and Azathioprine (100 mg/day). The patient was also treated with Metformin (500 mg/day) for impaired glucose tolerance, Levothyroxine (25 mcg/day) for elevated TSH levels (2,8 μ IU/ml), and Metoprolol (150 mg/day) for arterial hypertension. The first-trimester ultrasonography showed a high risk of preeclampsia (1:44), and the patient was prescribed acetylsalicylic acid (150 mg/day). In the 17th week of pregnancy, the Levothyroxine dosage was doubled. In the coming months, anti-diabetic drugs were modified - Insulin was included, and Metformin dosage was reduced to finally be discontinued in the 33rd week of pregnancy. Tacrolimus dosage was temporarily increased during pregnancy from 5 mg/day to 16 mg/day to maintain the usual therapeutic drug levels. Because of the high risk of eclampsia, the Caesarian section was performed in the 37th week of pregnancy. A male newborn, 3110 in weight, Apgar score of 10 points, was delivered. Following the first pregnancy, Tacrolimus dosage was decreased to 5 mg/day.

Eight months later, the patient was admitted to the clinic again, in the 8th week of unplanned pregnancy. Current immunosuppressive therapy includes Tacrolimus (18 mg/day) and Azathioprine (100 mg/day). Because of the high risk of preeclampsia (1:96), the patient was prescribed acetylsalicylic acid (150 mg/day) in the 16th week. The estimated due date is May 12th, 2023.

Conclusions

Advances in cardiac transplantation make pregnancy an attainable goal for many heart transplant recipients. Even though those pregnancies confer a high risk to the mother and fetus, the presented case shows that a multidisciplinary approach and modified immunosuppressant regimens make favourable pregnancy outcomes achievable.

[1972] From prenatal suspicion of kidney disorder to postnatal diagnosis of novel mutation in NOTCH2 gene - a case report

Authors: Bartosz Korzeb

Affiliation: 1st Department of Obstetrics and Gynecology, Medical University of Warsaw

Trustee of the paper: Ass. Prof. Monika Szpotańska, MD, PhD

Corresponding author: Bartosz Korzeb (bartosz.korzeb@student.wum.edu.pl)

Background

Pathogenic variants in NOTCH2 gene have been identified as a cause of several autosomal dominant congenital disorders. Phenotypically they might manifest as Alagille syndrome and Hajdu–Cheney syndrome, but their rarity and wide range of possible genetic variants makes diagnosis difficult. One of the manifestations, which might prenatally lead to suspicion of NOTCH2 mutation is kidney abnormality, including polycystic kidney.

Case report

A 39-year-old primigravida was admitted to the hospital at 28 weeks of gestation due to oligohydramnios. The ultrasound scan at 32 weeks revealed enlarged hyperechogenic kidneys, hyperechogenic intestines and anhydramnios. The patient's history showed that she had been taking angiotensin receptor blocker since the beginning of her pregnancy. At 34 weeks of gestation she delivered vaginally a male neonate, who died in the 10th hour of his life, due to critical general health condition and respiratory failure. Blood was tested to rule out a genetic cause of confirmed kidney disease. Next-generation sequencing identified in a heterozygous variant of the NOTCH2 gene (c.7160C>A) likely pathogenic of paternal origin. However, the father remains free of symptoms of chronic kidney disease until now. Currently, the patient is in the middle of her second pregnancy, which this time was planned in consultation with the gynecologist and free of ACEI exposure. The fetus does not demonstrate ultrasound signs of kidney disease.

Conclusions

During the differential diagnosis, the possible genetic background of the disease should always be borne in mind. The importance of pregnancy planning should be emphasized and the need to modify drugs potentially harmful to the fetus should be remembered at the stage of pregnancy planning. In fetuses with a high genetic risk of kidney disease, these symptoms may be even more pronounced. Further research is needed to determine whether a given variant of the NOTCH2 mutation is actually harmful.

Internal Case Report

Date: 22nd April 2023, 15:15 PM

Coordinators:
Wiktoria Niegowska
Monika Ryglewicz

[1584] The less drugs the better?

Authors: Karolina Furgala

Affiliation: University of Warmia and Mazury in Olsztyn, Department of Family Medicine and Infectious Diseases

Trustee of the paper: Małgorzata Stompór MD, PhD

Corresponding author: Karolina Róża Furgala (karolina.furgala.99@wp.pl)

Background

A typical geriatric patient is characterized by an atypical manifestation of diseases, multimorbidity and polypharmacy. We define it as taking many drugs at the same time, which usually leads to undesirable interactions between them, as well as between drugs and food. The awareness of this problem is increasing among both patients and doctors. On the other hand, "deprescribing" (the phenomenon of discontinuing the use of some drugs in order to improve the patient's health and reduce the number of side effects) may be associated with certain risks and is not always a positive action.

Case report

An 89-year-old female patient, treated for hyperthyroidism, heart failure, atrial fibrillation, chronic venous insufficiency and chronic kidney disease, was under the care of a geriatric clinic since 2018. She was taking furosemide, ramipril, bisoprolol, levcarnidipine, thiamazole, apixaban, potassium chloride and diosmin on a regular basis. She was functioning well, with no physical or cognitive decline. On September 15, 2022, she was admitted to the department of internal medicine due to gastroenteritis. On admission, potassium and TSH levels were normal. After five days, the patient was discharged. Physician recommended discontinuation of thiamazole, levcarnidipine and potassium chloride, and replaced furosemide with spironolactone. After 8 days, the patient was readmitted to the department due to cardiopulmonary decompensation and hyperkalemia (potassium level 5.79 mmol/l). The treatment was changed again to some of the drugs used before (furosemide, ramipril, levcarnidipine), but under a changed trade name. Also empagliflozin was added to the treatment. The patient was discharged home with massive edema of the right lower limb. The geriatrician recommended a return to the drugs used before hospitalization, including the continuation of treatment with thiamazole; after returning to the original treatment, the edema subsided, and the patient's condition stabilized.

Conclusions

Despite the fact that we try to prescribe as little drugs as possible to elderly patients, we should be careful when changing treatment. Changes should be well thought out and, if possible, not too sudden (the "start low, go slow" principle applies both when starting and ending treatment). An additional goal of our conduct must be to ensure good cooperation with the patient ("compliance"), and this is definitely not achieved by changing the trade names of chronically used drugs.

[1588] Dementia – rare manifestation of Primary Sjögren's syndrome

Authors: Anna Jereczek

Affiliation: The Medical University of Gdańsk, Department of Rheumatology, Clinical Immunology, Geriatrics and Internal Medicine

Trustee of the paper: Marta Jaskólska MD, PhD

Corresponding author: Anna Jereczek (annajereczek@gumed.edu.pl)

Background

Sjogren's syndrome is a disorder of immune system, in which antibodies mistakenly attack the body's own tissues, particularly exocrine glands. Women are more frequently affected by this condition. The two most common symptoms are keratoconjunctivitis sicca and xerostomia but every organ and system can be affected. Among neurological complications peripheral neuropathies are most common. Central nervous system (CNS) involvement is rare but untreated can lead to permanent functional impairment.

Case report

A 60-year-old man was admitted to the hospital due to anemia, rapid cognitive decline, urosepsis and acute kidney injury. The patient also had purpura-like skin lesions and ulcerations on his extremities. Shortly before, the patient was hospitalized in another internal medicine ward, where acute kidney damage with features of active urine sediment and monoclonal gammopathy were diagnosed, and Henoch–Schoenlein purpura was suspected based on skin lesions. From a medical history from the patient's family, first symptoms of cognitive dysfunction occurred after the covid infection. No further diagnostics was performed assuming that this was COVID-related “brain fog” and symptoms would subside over time. MRI of the head was suggestive of atrophic changes caused by a vascular process but without specific etiology. Based on the involvement of the kidneys, skin and possible involvement of the CNS, a rheumatic disease was suspected. Immunological tests were ordered, but in the meantime the patient's condition deteriorated, and he was transferred to the intensive care unit, where he was treated for septic shock caused by *S. Haemolyticus*. Obtained results of immunological tests were suggestive for primary Sjogren's syndrome (pSS). Due to the patient's severe general condition, it was not possible to collect anamnesis of symptoms of dryness. For verification, a biopsy of the minor salivary glands was performed. Based on 2016 ACR/EULAR classification criteria the diagnosis of pSS was established. CNS involvement in the course of the pSS was suspected. After the infection was cured, immunosuppressive treatment was started and the patient's condition improved.

Conclusions

Dementia is a rare manifestation of pSS. In this case it was initially misdiagnosed as post-covid complication, which delayed the proper diagnosis of pSS and initiation of treatment. This resulted in permanent organ damage of the CNS and significantly reduced the quality of life.

[1607] **Pneumocystis jirovecii pneumonia in liver transplant recipient treated with trimethoprim/sulphamethoxazole in desensitization protocol – case report.**

Authors: Karolina Baran, dr n. med. Agnieszka Furmańczyk-Zawiska

Affiliation: Warszawski Uniwersytet Medyczny - Klinika Medycyny Transplantacyjnej, Nefrologii i Chorób Wewnętrznych

Trustee of the paper: Prof. dr hab. med. Magdalena Durlik

Corresponding author: Karolina Baran (karolina.ba01@gmail.com)

Background

Pneumocystis jirovecii pneumonia (PJP) is an opportunistic infection that can progress to severe inflammatory condition with respiratory failure and death in immunocompromised patients. Since (TMP/SMX) six-month chemoprophylaxis against PJP has become a standard management in transplant recipients the prognosis improved. However, there is a growing concern affecting patients with ineffective prophylaxis, with contraindication to prophylaxis or after completion of six-month prophylaxis.

Case report

We report on a 53-year-old male liver recipient due to toxic cirrhosis treated with standard triple immunosuppressive (IS) regimen in whom TMP/SMX chemoprophylaxis was waived due to history of allergy manifested as an itchy, generalized rash with edema over 20 years ago. In 3rd month following engraftment his liver graft was functioning well, suddenly he developed fever, dry cough, dyspnea not responding to antibiotic prescribed by his physician. On admission he was in poor general condition, cyanotic, with dyspnea at rest, required constant passive oxygen therapy – saturation 92-94%, in auscultation crackles were more intense on right side, high inflammatory markers. Ceftriaxone, azithromycin and clindamycin were implemented. Facing severe infection, IS was modified – mycophenolate acid was stopped and tacrolimus was reduced to half of dose. High resolution computed tomography revealed an interstitial pneumoniae. Sars-Cov2 and cytomegalovirus infection were excluded. Bronchoalveolar lavage was positive for P. jirovecii and PJP has been diagnosed. Instead of TMP/SMX second line treatment –pentamidine i.v. and inhalation was implemented, moreover caspofungin also used for PJP was included with no improvement. After 3 weeks the patient deteriorated. Due to life-threatening condition, TMP/SMX i.v. was introduced in the desensitization protocol (hydrocortisone 1x100mg, clemastinum 1x2mg for 7 days) in increasing doses and meropenem, caspofungin were continued. Within four days the patient stabilized with no signs of TMP/SMX intolerance. PJP subsided within a month. His liver graft remained stable and chemoprophylaxis TMP/SMX was prescribed lifelong.

Conclusions

We emphasize the importance of a use of prophylaxis for PJP with TMP/SMX. In case of history of allergy to TMP/SMX the decision of prophylaxis withdrawal should be analyzed carefully in uncertain cases, desensitization protocol should be considered.

[1618] Allopurinol-induced DRESS syndrome in a 37-years-old Asian female

Authors: 1.Magdalena Mąsior 2.Olga Rostkowska MD, PhD 3. Agnieszka Furmańczyk-Zawiska MD, PhD 4. Prof. Magdalena Durlik MD, PhD

Affiliation: Student Research Group by Department of Nephrology, Transplantology and Internal Diseases, Warsaw University of Medicine

Trustee of the paper: Olga Rostkowska MD, PhD

Corresponding author: Magdalena Natalia Mąsior (masiormagdalena@gmail.com)

Background

Drug reaction with eosinophilia and systemic symptoms (DRESS) syndrome is a rare hypersensitivity reaction that involves the skin and various visceral organs. Haematological abnormalities, lymphadenopathy and fever may also occur. Many drugs are reported to be associated with DRESS, particularly anticonvulsants or allopurinol. The symptoms develop two to eight weeks after drug initiation. If the diagnosis is delayed, DRESS can be a life-threatening condition.

Case report

A 37-year-old Asian woman developed fever, acute maculopapular rash with erosions on the lips and conjunctivitis two weeks after starting allopurinol therapy. The patient had medical history of pre-dialysis chronic kidney disease stage V in the course of IgA nephropathy, hypertension, hyperparathyroidism, anemia and a history of type b hepatitis. Upon a dermatological outpatient visit, the patient was advised to discontinue allopurinol and was prescribed prednisone and steroid ointment, which did not lead to improvement. She was admitted to the hospital, where edema of the face, hands and genitals developed. The laboratory tests revealed eosinophilia, elevation of liver enzymes and serum creatinine concentration. Decrease of diuresis was observed. Intravenous administration of hydrocortisone, clemastine and furosemide with intramuscular dexamethasone did not lead to clinical improvement with eosinophilia and laboratory markers increasing. DRESS syndrome was suspected based on fever, eosinophilia, skin and visceral manifestations and exclusion of autoimmune and infectious causes. Treatment with intravenous immunoglobulins with methylprednisolone instead of dexamethasone was administered. To avoid vision impairment, regular eyelids massage with removing of pseudomembranes and administration of ofloxacin-dexamethasone combination eye drops was given. During the next two weeks of hospitalization, gradual clinical improvement with normalization of laboratory results was observed resulting in hospital discharge after 3 weeks.

Conclusions

Due to its rare occurrence and heterogeneous manifestation, diagnosis of DRESS can pose many difficulties. In-depth analysis of symptoms, drug history in the context of the patient's ethnicity, and laboratory test results enabled making the diagnosis and initiating appropriate treatment. Patients of Asian ethnicity tend to have predisposition to severe drug hypersensitivity, including to allopurinol. Allopurinol in case of the patient described is contraindicated for life.

[1649] Non-alcoholic fatty liver disease associated with Marfanoid–progeroid–lipodystrophy syndrome: a case report

Authors: Arnoldas Grinys

Affiliation: Vilnius University, Faculty of Medicine, Lithuania

Trustee of the paper: Dr. Ilona Savlan, Agnė Norbutaitė, MD

Corresponding author: Arnoldas Grinys (arnoldasgame@gmail.com)

Background

Non-alcoholic fatty liver disease (NAFLD) is a prevalent condition characterized by the accumulation of fat in liver cells, affecting at least 5% of the liver parenchyma. The disease spectrum ranges from simple hepatosteatosis to non-alcoholic steatohepatitis (NASH), which can lead to liver cirrhosis and hepatocellular carcinoma. NAFLD is closely associated with metabolic syndrome, insulin resistance, type 2 diabetes and obesity. In rare instances it can be related to lipodystrophies and other genetic syndromes such as Marfan lipodystrophy, a rare syndrome that affects the connective tissue and fat metabolism.

Case report

In 2019, a 48-year-old female patient was admitted to the Vilnius University Hospital Santaros Klinikos for examination due to severe general weakness, previous loss of consciousness, and weight loss with no clear cause (15 kg in the last month, BMI 13.5 kg/m²). The patient's medical history included a diagnosis of jaundice in her childhood and recurrent episodes of hyperglycemia. Hepatomegaly with no underlying cause was diagnosed in 2014. In 2018 she was diagnosed with macrocytic anemia, thrombocytopenia and leukopenia. During the examination, the patient had hepatomegaly and abnormal laboratory blood test results, including anemia, thrombocytopenia, folic acid deficiency, dyslipidemia, hyperglycemia, and elevated liver enzymes. An abdominal CT scan revealed hepatomegaly, hepatosteatosis and hepatic portal lymphadenopathy. Liver biopsy and histological results revealed high-grade steatohepatitis and cirrhosis, with no copper or iron deposition.

In 2020, the patient was admitted to the same tertiary hospital for evaluation for liver transplantation. The patient complained of general weakness, high blood pressure and a BMI of 13.5 kg/m². The blood tests revealed elevated liver enzymes, bilirubin, alpha-fetoprotein, dyslipidemia and hyperuricemia. Radiological tests indicated progressive hepatosteatosis.

Given the suspicion of a genetic disorder associated with abnormal lipid metabolism, she underwent whole genome sequencing which identified a mutation in the fibrillin-1 gene. In 2021, the patient was diagnosed with Marfan lipodystrophy, an exceedingly rare genetic syndrome that leads to the accumulation of fat in the liver.

Conclusions

Due to the significant increase in the prevalence of non-alcoholic fatty liver disease, further investigation is essential to comprehend its pathogenesis to establish targeted therapies and prevent the progression of the disease.

[1661] In search of the cause of AA renal amyloidosis

Authors: Wojciech Kubacki

Affiliation: Student Scientific Society of the Department of Nephrology, Dialysis and Internal Diseases, Medical University of Warsaw

Trustee of the paper: lek. Zuzanna Jakubowska

Corresponding author: Wojciech Kubacki (wkubacki93@gmail.com)

Background

AA amyloidosis is a rare disease characterized by the extracellular tissue deposition of fibrils that are composed of serum amyloid A protein (SAA), a hepatic acute phase reactant. The disease develops in response to chronic inflammation and can be a consequence of long-term infections or various inflammatory diseases such as rheumatoid arthritis, ankylosing spondylitis, inflammatory bowel diseases, or cancer. However, sometimes finding the underlying cause of amyloidosis can be very challenging and requires special testing.

Case report

A 49-year-old woman, who was treated only with L-thyroxine supplementation so far was admitted to the district hospital due to vomiting, headache, and pain in the lumbar region lasting for several days. End-stage renal failure of unknown etiology was diagnosed. For further treatment and diagnosis, the patient was transferred to a higher-level referral hospital. A percutaneous renal biopsy was performed. Histopathological examination showed amyloid deposits and AA amyloidosis was diagnosed. In order to detect the cause of amyloidosis, extensive diagnostics was performed. A number of autoimmune diseases and chronic viral and bacterial infections were ruled out by serological or molecular tests. The serum amyloid A level was elevated to 10.3 mg/l (SAA reference range 0-6.4 mg/l). Gastroscopy showed only numerous small duodenal polyps, sections of intestinal metaplasia and an H.pylori infection. In the histopathology examination of ascending colon biopsy, amyloid deposits were detected. The gynecological examination revealed no abnormalities other than lymphadenopathy of the axillary nodes. Chest and abdominal computer tomography revealed generalized lymphadenopathy, but histopathology of the axillary node showed no major abnormalities. The idiopathic variant of AA amyloidosis was diagnosed.

Conclusions

The list of conditions associated with AA is long and growing. However, in a significant number of cases, up to 29%, the cause of AA amyloidosis cannot be determined. In the presented patient, despite a wide panel of tests performed, the etiology of the disease could not be clearly established. In order to stop the progression of amyloidosis, it is necessary to control inflammation, which in turn requires treatment of the underlying disease. The diagnosis of idiopathic amyloidosis excludes the use of targeted therapy and requires constant, regular monitoring of the patient's state.

[1690] **New subtype of spindle-cell soft tissue sarcoma with PATZ1-EWSR1 fusion**

Authors: Martyna Biernacka

Affiliation: Students' Scientific Group of Multidisciplinary Oncology 'Onkosfera', Department of Soft Tissue/Bone Sarcoma and Melanoma, Maria Skłodowska-Curie National Research Institute of Oncology in Warsaw

Trustee of the paper: Pawel Sobczuk, MD PhD, Hanna Kosela-Paterczyk, MD PhD

Corresponding author: Martyna Biernacka (biernacka.martynaa@gmail.com)

Background

Sarcomas comprise a group of rare mesenchymal tumors of bones and soft tissues. There are over 100 different subtypes and their number is constantly growing, mostly due to a better knowledge of genomic alterations and the molecular biology of sarcomas. Some sarcomas are characterized by the presence of gene fusions, which determine their biology. In this case report we present a patient with soft tissue sarcoma with a presence of new fusion and very aggressive clinical course.

Case report

A 42-year-old male was referred due to a tumor in his left thigh. Further imaging revealed the presence of lesions in right lung, suspected of distant metastases. Due to nondiagnostic biopsy of primary lesion patient underwent metastasectomy of lung lesions in August 2020. Histopathological examination revealed high-grade spindle cell sarcoma with very high mitotic index. Next generation sequencing showed the presence of fusions PATZ1-EWSR1 - a new fusion variant, which was not previously well characterized. Two weeks after surgery, patient experienced paresis of the right upper limb accompanied by severe pain. An MRI scan showed a massive soft-tissue tumor protruding into the prevertebral space and into the spinal canal in the C2-C5 section. Radiotherapy was started with a fractional dose of 3Gy and total dose of 30Gy. Chemotherapy with high-dose ifosfamide was administered, but after 2 cycles patient experienced disease progression with progression-free survival (PFS) of only 1.5 month in the 1st line. In November 2020 patient started treatment with doxorubicin and dacarbazine (ADIC). After 1 course of ADIC chemotherapy new metastases in the central nervous system and progression of other lesion were detected - PFS of 1 month on 2nd line. Next, 3rd line chemotherapy, consisting of etoposide and cisplatin, was commenced in December 2020 and terminated after 1 month due to massive disease progression with quadriplegia and respiratory insufficiency. Patient died in January 2021, 5 months post diagnosis.

Conclusions

The above-described case present a patient with new sarcoma subtype with uncharacterized fusion. It is characterized by an aggressive behavior and resistance to standard treatment, including doxorubicin-based chemotherapy. Further research, including functional genomic and translational studies, is crucial to gain a better understanding of the nature of this sarcoma subtype. This case also highlights the significance of genomic profiling in rare tumors.

[1695] A case of atypical cardiac metastastasis from malignant melanoma.

Authors: Aleksander Gorzeń

Affiliation: Medical University of Warsaw, Department of Soft Tissue/Bone Sarcoma and Melanoma, Maria Skłodowska-Curie National Research Institute of Oncology, Warsaw

Trustee of the paper: prof. dr hab. n. med. Anna Małgorzata Czarnecka, prof. dr hab. n. med. Piotr Rutkowski

Corresponding author: Aleksander Kuba Gorzeń (aleksander.gorzen01@gmail.com)

Background

Melanoma is a malignant tumor that develops from melanocytes, which are neural crest-derived pigment cells. The most common metastatic sites are subcutaneous tissue, lymph nodes, the lungs, liver, brain, and bone. We present the case of a patient with malignant melanoma that spread to the right atrium of the heart.

Case report

A 42-year-old woman presented to the Maria Skłodowska-Curie National Research Institute of Oncology in Warsaw with a history of a pTX BRAF(-) malignant melanoma located in the lumbar area. The tumor was resected in 2015 in a regional hospital. The provided documentation showed that 2 months after the surgery, lymphadenectomy of the left inguinal lymph nodes was performed. On admission, computed tomography (CT) scan revealed metastases in the brain, lungs and L4 vertebra. The patient was qualified for systemic pembrolizumab treatment and stereotactic body radiotherapy (SBRT) for the brain, which stabilized the disease (SD RECIST) after 3 months. Two months later, following CT scans showed regression of the brain and lung metastases. However, the tumor in the L4 area progressed from 7x6mm to 18x12mm over 6 months. Thus, the patient was scheduled for SBRT in the L4 vertebra area. Simultaneously, imaging studies revealed a metastatic lesion in the right atrium of the heart. On MDT, SBRT for the cardiac region was not recommended due to the high risk of AE. It was decided to treat the patient with anticoagulants. Pembrolizumab was safely continued. Two months later, due to CTCAE2 hepatotoxicity, treatment was stopped and second line treatment – ipilimumab – was initiated after 3 weeks. As the repeated genetic test showed the BRAF mutation, after receiving the 4th dose of ipilimumab, the patient started BRAF/MEK inhibitors (Dabrafenib, Trametinib) as 3rd line treatment and achieved SD. Two years later, a CT scan revealed the progression of metastases in the lungs and the patient started BOLD regiment chemotherapy. After 4 months of chemotherapy, laboratory tests revealed CTCAE2 hepatotoxicity and the patient was rechallenged with Dabrafenib and Trametinib. Three months later, as the disease progressed, the patient was qualified for PXL chemotherapy. The patient died 1 month later.

Conclusions

Metastasis of melanoma to the cardiac region is a very rarely observed complication. However, anticoagulant treatment and targeted therapy may be successful in the stabilization of the disease and prevention of thrombosis.

[1696] Stereotactic body radiotherapy in the treatment of oligometastatic soft tissue sarcomas - case report.

Authors: Aleksander Gorzeń

Affiliation: Medical University of Warsaw, Department of Soft Tissue/Bone Sarcoma and Melanoma, Maria Skłodowska-Curie National Research Institute of Oncology, Warsaw

Trustee of the paper: dr hab. n. med. Mateusz Spalek

Corresponding author: Aleksander Kuba Gorzeń (aleksander.gorzen01@gmail.com)

Background

Patients with a limited volume of metastatic disease (known as oligometastatic disease) could benefit from intensive local therapy, possibly combined with chemotherapy. The mainstay of local treatment for oligometastatic soft tissue sarcomas is surgery. However, less invasive approaches also could provide similar results in the selected group of patients. Stereotactic body radiotherapy (SBRT) is a method of delivering very high doses of radiation to a limited target volume under image guidance and motion control. It could also overcome the relative radioresistance of tumors such as sarcomas.

Case report

A 76-year-old man with a history of obesity, chronic obstructive pulmonary disease, and diabetes mellitus presented with abdominal pain. An ultrasound scan revealed a tumor of the right kidney. The patient was referred to the Maria Skłodowska-Curie National Research Institute of Oncology (MSCNRIO). Computed tomography (CT) scans confirmed the lesion and, following multidisciplinary team consultation (MDT), the patient was scheduled for a right-sided nephrectomy. Histopathological results showed high-grade leiomyosarcoma. Six months after surgery, follow-up magnetic resonance imaging (MRI) showed a lesion at the site of surgery, which subsequently progressed. After MDT, the patient underwent stereotactic body radiotherapy (SBRT) at a dose of 12 Gy per fraction to a total dose of 36 Gy. The irradiated lesion was stable on the follow-up MRI 4 months after SBRT. However, at the same time, a follow-up CT scan showed two metastatic lesions in the left lung. The MDT decided to offer local treatment instead of chemotherapy. The patient was qualified for the next SBRT and underwent two procedures, namely 15 Gy per fraction up to 45 Gy for the first lesion and 5 Gy per fraction up to 50 Gy for the second lesion. The next follow-up CT scan revealed another tumor in the left lung which was also treated with SBRT. Seven months later CT scan partial response to the treatment. Almost one year later, another left lung lesion was found and the patient received the fourth SBRT procedure to the left lung. No significant toxicity of either SBRT was noted. The patient continues to be followed at MSCNRIO.

Conclusions

This case highlights the advantages of SBRT in the treatment of oligometastatic soft tissue sarcomas. It provides high local control with minimal toxicity and could be offered as a viable alternative to surgery in patients with significant comorbidities.

[1698] A rare case of tuberculosis at a young age.

Authors: Paweł Jurczak

Affiliation: Students' Association of Cardiopulmonology and Rare Pulmonary Diseases, Department of Pulmonology, Faculty of Health Science, Collegium Medicum, University of Warmia and Mazury in Olsztyn

Trustee of the paper: Anna Romaszko-Wojtowicz MD-PhD, Anna Doboszyńska MD-PhD prof.

Corresponding author: Paweł Jurczak (pawel.jurczak99@gmail.com)

Background

Tuberculosis is an infectious disease caused by mycobacteria belonging to the *Mycobacterium tuberculosis* complex group. The most typical symptom is cough, other less common symptoms include weakness and chest pain. Although the total number of cases has decreased in recent decades, tuberculosis remains a significant infectious disease. The data for 2020 in Poland show that tuberculosis is more frequent in men and tends to increase with aging (most often in the 45-64 age group). The incidence rate in Poland was 13.9/100 000.

Case report

A 22-year-old woman was admitted due to a lack of improvement after treatment for pneumonia with pleural effusion. The patient reported a cough and pleural pain radiating to the left scapular line for two months. Initially, she was treated symptomatically, then an antibiotic was applied without any improvement. The patient has not been hospitalized so far, in 2017 she had contact with her father suffering from tuberculosis. Laboratory tests revealed elevated CRP, D-dimers and anemia. CT angiography showed no signs of pulmonary embolism and left pleural effusion was visualized with a tendency to encapsulate at the base of the lung. A tree-in-bud pattern was visible in both pulmonary fields, especially in the upper and middle ones. An empiric antibiotic therapy was continued and antitussive, antipyretic and analgesic drugs were also used. In the control X-ray of the chest, pneumothorax was found at the base of the left lung with a fluid level. Passive oxygen therapy was applied. *M. tuberculosis* was detected in the pleural fluid collected during thoracentesis. Bronchofiberoscopy was performed and a positive result was obtained from the bronchial washing of the genetic probe for *M. tuberculosis*. The patient was diagnosed with tuberculosis and the place of further treatment was settled in the pulmonology ward.

Conclusions

Despite the fact that tuberculosis in Poland is more common in men and people over 45 years old, it should be remembered it can also affect younger people. Medical history indicating contact with an infected person should raise special attention. A correct diagnosis allows for a full recovery within at least 6 months of therapy.

[1699] **Cancer or benign tumor in the lung? A happy ending story.**

Authors: Paweł Jurczak

Affiliation: Students' Association of Cardiopulmonology and Rare Pulmonary Diseases, Department of Pulmonology, Faculty of Health Science, Collegium Medicum, University of Warmia and Mazury in Olsztyn

Trustee of the paper: Anna Romaszko-Wojtowicz MD-PhD, Anna Doboszyńska MD-PhD prof.

Corresponding author: Paweł Jurczak (pawel.jurczak99@gmail.com)

Background

Lung tumors can be either cancerous or benign. All changes detected in the lung in medical imaging require this differentiation. Non-cancerous tumors are usually not life-threatening, while lung cancer often carries a poor prognosis. Histologic diagnosis may be obtained with sputum cytology, thoracentesis, accessible lymph node biopsy, bronchoscopy, transthoracic needle aspiration, video-assisted thoracoscopy, or thoracotomy. In most cases, benign lung tumors do not require treatment. A tuberculoma is a well-defined focal mass that results from Mycobacterium tuberculosis infection. Tuberculomas most commonly occur in the brain and the lung.

Case report

A 68-year-old patient was admitted to the Department of Pulmonology for the diagnosis of a nodular lesion of the right lung found in a chest X-ray. A nodular mass with a diameter of 31mm in the lower pole of the right lung hilum and parenchymal density with dimensions of 77 x 65 mm in the lower field of the right lung were visualized in a chest X-ray. The patient reported an intermittent dry cough and had lost 8 kg within 2 months. Laboratory tests showed no significant deviations. Chest CT revealed a peripheral nodule of 24x13 mm in the right lung and an enlarged lymph node of approximately 12 mm in the right hilum. Bronchofiberoscopy was performed and bronchial washings were collected for culture as well as cytological examination for tuberculosis. Afterwards, a CT-guided core needle biopsy of the right lung was carried out. In the biopsy material, numerous epithelioid granulomas were visible, some of them with central necrosis, while cancerous changes were not found. Taking into consideration all the clinical, imaging, and laboratory findings, the patient was diagnosed with tuberculosis, and treatment was initiated.

Conclusions

Oncological vigilance must always be maintained when a nodular lesion is detected in the lungs. Performing a full diagnosis is very important because an incorrect diagnosis can have serious consequences. A tuberculoma conglomerates tubercles into a firm nodule and so can mimic cancer tumors of many types in medical imaging studies.

[1714] Misdiagnosis of Alport syndrome and wrongful use of steroids for 20 years

Authors: Mohamed Barakat, Abdulla Hourani

Affiliation: Department of Nephrology, Dialysis and Internal Medicine, Medical University of Warsaw

Trustee of the paper: Zuzanna Jakubowska, MD

Corresponding author: Mohamed Osama Barakat (Hamobarakat2000@gmail.com)

Background

Alport syndrome is a rare genetic disorder characterized by progressive kidney disease, hearing loss, and ocular abnormalities. It is caused by mutations in genes encoding for type IV collagen. Misdiagnosis of Alport syndrome is not uncommon due to its variability in clinical presentation and the lack of awareness among healthcare providers. In this case report, we present a patient with Alport syndrome who was misdiagnosed in 2001 and was treated with chronic steroids. The patient was later diagnosed based on the family history of Alport syndrome with a typical presentation.

Case report

A 45-year-old male patient was diagnosed with kidney disease in 2001 based on proteinuria on routine tests. He underwent a kidney biopsy which revealed Focal Segmental Glomerulosclerosis (FSGS). He was treated with steroids for over twenty years, but his renal parameters continued to worsen gradually. He also reported progressive hearing loss since 2010. In 2014, during the diagnosis of his daughter who was diagnosed with hematuria and Alport syndrome, the patient's diagnosis was extended to include genetic testing. The genetic tests were inconclusive. After that, the patient's brother was diagnosed with chronic glomerulonephritis. Due to family history and typical clinical presentation, Alport's syndrome was diagnosed, and soon after the patient was submitted to the waiting list for a kidney transplant. In March 2019, the patient was admitted to the Department of Nephrology due to worsening renal function with creatinine levels of 6.4 mg/dL. The patient started hemodialysis treatment and two months later, he received an allogeneic kidney transplant.

Conclusions

This case highlights that the diagnosis of Alport's syndrome is complex and requires a much more in-depth medical examination, kidney biopsies assessed by experienced pathologists, and often genetic tests. Misdiagnosis of Alport syndrome can lead to inappropriate treatment and delay in proper management, as in this case. Early diagnosis and appropriate management of Alport syndrome are crucial to prevent the progression of the disease and its complications, such as end-stage renal disease.

[1723] Transthyretin amyloidosis – rare, insidious and terminal disorder

Authors: Michalina Strzedulla, Paulina Ziółkowska

Affiliation: Clinical Department of Internal Medicine, Diabetology and Nephrology SPSK Nr 1 im. prof. S. Szyszko, Faculty of Medical Sciences in Zabrze, Medical University of Silesia in Katowice

Trustee of the paper: G. Wystrychowski MD PhD, M. Śnit MD PhD

Corresponding author: Paulina Ziółkowska (paula.ziolkowska268@gmail.com)

Background

Transthyretin amyloidosis (ATTR) is a serious, rare disease in which abnormal filamentous proteins are accumulated in tissues and organs. The diagnostic process poses a huge challenge due to nonspecific symptoms and signs from many different systems. Progression of the disease leads to the significant dysfunction of the organs and consequently to the patient's death. Delayed diagnosis contributes to worse prognosis for the patient. ATTR can be treated by means of simultaneous heart and liver transplantation, isolated heart transplantation, gene therapy and therapies affecting amyloid metabolism.

Case report

Our case was a 64-year-old man who was in good health until September 2021, when he was hospitalized due to acute myocardial infarction. A multi-vessel coronary artery disease was diagnosed and the percutaneous coronary interventions were performed thrice over the following three months. An episode of AKI occurred after the second procedure, and chronic kidney disease stage G3A persisted. Since January 2022, further deteriorations of kidney, as well as heart and liver functions, were observed. In April the patient was referred to the Department of Internal Medicine, Diabetology and Nephrology. Significant elevations of the enzymatic markers of cholestasis and features of nephrotic syndrome were noted, and implementation of hemodialysis therapy, as well as continuous infusion of norepinephrine were shortly required. Based on the skin and kidney biopsies, the diagnosis of amyloidosis was made. In the absence of monoclonal gammopathy or inflammatory state, as well as the history of patient's uncle's death due to amyloidosis, a hereditary type of ATTR was deduced. Due to rapid deterioration of his condition, the patient was not eligible for a dedicated drug therapy program, and died on the 35th day of hospitalization.

Conclusions

Patients with transthyretin amyloidosis require specialist therapies in the Centers of Excellence and/or organ transplantations in order to live. However, a dynamic course of the disease like in our patient may preclude effective treatment. Therefore, in patients with nephrotic proteinuria, heart failure, and enzymatic cholestasis with no biliary dilatation, amyloidosis should be promptly considered in the diagnostic process.

[1749] Nephrological-vascular manifestation of Ormond's disease

Authors: Nina Kubikowska

Affiliation: Medical University of Warsaw / Student Scientific Society "Pressor" Department of Internal Medicine, Hypertension and Vascular Diseases

Trustee of the paper: Izabela Łoń, MD, PhD

Corresponding author: Nina Marta Kubikowska (nina.kubikowska@gmail.com)

Background

Retroperitoneal fibrosis (RPF), also known as Ormond's disease, is a rare disorder characterized by the abnormal growth of fibrous tissue in the retroperitoneal space. This fibrosis can compress and obstruct the ureters, leading to hydronephrosis and renal failure. The symptoms of RPF are nonspecific and vary depending on the severity of the fibrosis and the extent of ureteral obstruction.

Case report

A 63-year-old patient with cardiovascular risk factors (smoking, hypercholesterolemia, hypertension) was admitted to the hospital with gradually increasing abdominal pain over several days. During diagnosis, a high creatinine level of 5 mg/dL was found, an ultrasound and CT scans showed bilateral hydronephrosis and the presence of an abdominal aortic aneurysm. After the insertion of JJ catheters into the ureters and drainage of the hydronephrosis, normalization of kidney parameters was achieved. Due to the presence of an abdominal aortic aneurysm and the patient's femoral arteries, the patient was referred for surgical treatment at a specialist center. Laboratory test results showed elevated inflammation markers, and angio-CT showed an image typical of an inflammatory aneurysm, leading to a diagnosis of retroperitoneal fibrosis around the dilated aorta and bifurcation. Surgical treatment was abandoned in favor of immunosuppressive therapy. High-dose prednisone was started and gradually reduced until it was completely discontinued in August 2022 (after 11 months of treatment and achieving remission). In September, an increase in inflammatory parameters was noted without accompanying clinical symptoms. Methotrexate was added to a low dose of prednisone, leading to improvement. The patient tolerated the two-year immunosuppression well, but a complication was cataracts. During treatment, the patient developed symptoms of unstable angina, which was treated with revascularization and DES placement.

Conclusions

The diagnosis of RPF is difficult due to the non-specificity of symptoms. So far, optimal management for recurrent RPF after primary glucocorticoid therapy has not been established. Our case shows the usefulness of using methotrexate in case of the recurrence. RPF treatment is long-term, so awareness of its adverse effects is essential.

[1846] **Diagnosis of Melanoma Localized in the Ulcer Associated with Diabetic Foot Syndrome**

Authors: Kamil Tkacz 1, Klaudia Łakomska 2, Marcin Kleibert 1, Anna M. Czarnecka 3, Piotr Rutkowski 3, Wojciech Zgliczyński 4

Affiliation: 1 - Faculty of Medicine, Medical University of Warsaw, 2 - Faculty of Medicine, Wrocław Medical University, 3 - Maria Skłodowska-Curie National Research Institute of Oncology 4 - Department of Endocrinology, Bielanski Hospital

Trustee of the paper: Beata Mrozikiewicz-Rakowska

Corresponding author: Kamil Tkacz (kamilt2001@gmail.com)

Background

The treatment of diabetic foot ulcers (DFU) is usually a long process. Physicians often get used to the protracted time of the therapy. Despite following the doctor's recommendations, the ulceration often does not heal properly, and the wound size does not reduce. In such cases, a dermatological and oncological diagnosis should be included in the management.

Case report

A 71-year-old obese man with type 2 diabetes mellitus, hypertension, hypercholesterolemia, chronic coronary syndrome, heart failure, paroxysmal atrial fibrillation, COPD, and benign prostatic hyperplasia presented with persistent for 2 years ulceration of the first toe of the right foot. The patient's lesioned foot showed impaired superficial sensation of pain, touch, temperature and vibration and a superficial wound measuring 2,0 x 1,5 cm with features of inflammation. With the topical treatment, the inflammation had resolved by the time of the next visit (after 3 months). However, no wound's size reduction was observed at any of the visits (3, 6, 9 months), which prompted the attending physician to consider the etiology other than diabetic foot syndrome. A histopathological examination was performed and the result suggested a diagnosis of melanoma. Microscopic examination revealed acral melanoma (SOX10(+), HMB45(+), PRAME(+)) with a predominant "in-situ" component. The patient was initially qualified for the toe amputation and sentinel node biopsy. A definitive diagnosis of pT1b stage acute melanoma with signs of regression and the presence of lymphoid infiltration was made. The depth of infiltration on the Breslow scale was estimated at 0,8 mm and mitotic rate at 0-1/mm². Angio- and neuroinvasion was not found, and there were no satellite nodules. No melanoma metastases were observed in the sentinel nodes.

Conclusions

Multidisciplinary action by teams of diabetologists, dermatologists, and surgeons could significantly improve the diagnostic efficiency of malignant lesions masking as diabetic foot ulcers. It is essential to increase physicians' awareness of the difficulty of diagnosing acute melanoma in cases of DFU. Speeding up the diagnostic process, by using biopsies more frequently, could have a positive impact on patient survival and treatment success.

[1852] A rare case of chronic neutrophilic leukemia complicated by tuberculosis and hemophagocytic lymphohistiocytosis.

Authors: Jan Pawłasek¹, Karolina Hernik¹

Affiliation: 1. Department of Hematology, Transplantation and Internal Medicine, Medical University of Warsaw, Warsaw, Poland

Trustee of the paper: dr n. med. Joanna Drozd-Sokołowska, prof. dr n med. Tomasz Stokłosa

Corresponding author: Jan Pawłasek (janpawlasek1903@gmail.com)

Background

Chronic neutrophilic leukemia (CNL) is a rare myeloproliferative neoplasm (MPN). It is characterized by chronic leukocytosis and neutrophilia. Genetic testing is crucial in its diagnosis, with mutated CSF3R being the hallmark. Hemophagocytic lymphohistiocytosis (HLH) is a life-threatening disorder, the result of hyperinflammation that may be inherited or triggered by malignant neoplasms, infectious diseases or autoimmune reactions.

Case report

The 75-year-old man with anamnesis of latent tuberculosis (TB) was admitted to the hospital due to leukocytosis, neutrophilia and anemia. He was hospitalized a month earlier due to chronic malaise and recurring fevers. Both cytomorphologic and histopathological examinations of the bone marrow performed at that time were inconclusive, BCR/ABL1 fusion gene and JAK-2 mutation were negative. Blood tests revealed: white blood cells (WBC) 162x10⁹/L, hemoglobin 8.4g/dL, and platelets 39x10⁹/L. Segmented and band neutrophils constituted >80% of WBC, blasts <1% in the peripheral blood. A trephine biopsy was repeated with hypercellular bone marrow and suggestive of myelodysplastic/ myeloproliferative neoplasm (MDS/MPN), without BCR/ABL1 fusion gene. Rearrangements of PDGFRA, PDGFRB or FGFR1 were not detected. Blood sample for NGS (next-generation sequencing) was collected but not analyzed at that time. Based on fever, splenomegaly, hyperferritinemia, hypertriglyceridemia, anemia and thrombocytopenia, a diagnosis of HLH was made. However, the patient did not receive any MDS/MPN- or HLH-directed therapy as his general condition deteriorated. Despite empiric antimicrobial treatment, he succumbed to a septic shock. The autopsy revealed pulmonary TB. Post-mortem NGS detected mutations of ASXL1, TET2, SRSF2, RUNX1, STAG2, and CSF3R, which along with other criteria (>25x10⁹/L WBC, >80% segmented and band neutrophils) allowed for the diagnosis of CNL.

Conclusions

CNL poses a diagnostic challenge to clinicians and cannot be diagnosed without appropriate genetic testing especially useful in difficult differential diagnosis of rare myeloid neoplasms belonging to MDS/MPN group, giving a chance for early, appropriate management. The diagnosis of CNL may be even more challenging when conditions impacting both bone marrow function and peripheral blood parameters develop, e.g. HLH. or infection. Whether HLH results from CNL or other conditions in such cases is a matter of debate.

[1939] Unusual localization of rare postoperative myokymia treated successfully with Botox injections – a case study

Authors: Filip Banyś, Katarzyna Stadnik

Affiliation: Students' Scientific Society at the Department of Neurology, Medical University of Warsaw

Trustee of the paper: Stanislaw Slyk, PhD

Corresponding author: Katarzyna Aleksandra Stadnik (katarzyna.stadnik27@gmail.com)

Background

Myokymia is a condition characterized by an involuntary contraction of muscles, evinced in the form of twitching and shivering movements. This status can be caused by anxiety, dehydration or surgery. Myokymia as a postoperative complication is a rare type of peripheral induced movement disorder (PIMD) manifested by previously mentioned symptoms but atypically close localization to post-operative area is what makes this case unusual.

Case report

A 66-year-old patient was admitted to the hospital due to painful muscle movements in the left abdominal area that had started 1 year ago. Patient underwent the hip-femoral bypass surgery with the complication in the form of hematoma in the abdominal scar, 10 months before symptoms occurred. The atypical movements were localized some distance from the scar what made it unusual in comparison to already described cases of postoperative myokymia. Few years before the patient was diagnosed with duodenal GIST treated with chemotherapy. Based on this facts, involuntary movements of abdominal rectus were suspected to be the result of PIMD or paraneoplastic syndrome. Neurological examination revealed no abnormalities as well as the presence of movements during sleep confirmed the lack of damage to the CNS. Moreover, EMG showed spontaneous, periodic activity in the single location of the left rectus abdominis muscle presented with repeated stimulated muscle activity. Therefore, the idea of paraneoplastic syndrome was rejected. Patient was treated with the 100 units injection of botulinum. After the first injection of the abdominal muscles, the patient noted an improvement in terms of contractions frequency and pain, but they returned 2 months later. The same amount of Botox units injections contributed significant improvement of patient afflictions. Since undergoing last treatment, patient has not reported to the hospital with such symptoms anymore.

Conclusions

Myokymia localized in the muscles in the proximity of the scar may be classified as a postoperative complication included in PIMD. It is probably caused by incorrect reinnervation due to the formation of partially autonomous centers of generating impulses that mistakenly innervated other muscle fibers. It was proven that this type of myokymia can be successfully treated with the Botox injections. The case highlights the importance of completing the PIMD classification with new subtypes to enable clinician diagnosis and treatment of postoperative myokymia more effectively.

[1964] When drugs are the cause not the cure

Authors: Michał Pałuchowski, Olga Jakubik

Affiliation: Medical University of Warsaw / SKN Psychiatrii WUM

Trustee of the paper: Krzysztof Bogusz MD

Corresponding author: Michał Marcin Pałuchowski (adam.kowalski123456789.adam@gmail.com)

Background

Polypharmacy is a term used to describe the simultaneous use of 2 or more medications in the same patient, however, the definitions have ranged from 2 to 7 or more drugs. It may suggest that the patient is being prescribed more medications than is clinically indicated. In different studies, the prevalence of polypharmacy is estimated up to 37%.

Case report

A 34-year-old woman was referred to private practice by her psychotherapist. In the course of the appointment, the patient reported that she had recently been experiencing an exacerbation of depression, practically not leaving the house due to the fear of rejection and negative evaluation.

On Beck's Depression Inventory she initially scored 34 points (severe depression) and on GAD-7 scale 14 points (moderate severity).

The patient was previously diagnosed with social phobias (F40.1), recurrent depressive disorder, current episode severe without psychotic symptoms (F33.2) and overeating associated with other psychological disturbances (F50.4).

She started psychiatric treatment in high school, around the age of 16. She reported that the drugs were modified frequently, even in a span of one month. She was being prescribed olanzapine, fluoxetine, valproic acid, vortioxetine, moclobemide and ketamine. At the time of the visit, she was taking venlafaxine (300 mg), aripiprazole (15 mg), bupropion (150 mg), quetiapine (200 mg) and pregabalin (300 mg) daily as needed. The patient expressed doubts concerning the effectiveness of the current treatment.

Within the next 2 visits bupropion, aripiprazole and quetiapine were gradually discontinued which resulted in the significant improvement on both BDI (5) and GAD-7 (9) scales without the introduction of any new medication.

Conclusions

Although polypharmacy may be justified in certain medical cases, practitioners should be aware of all the concerns associated with the phenomenon. The use of various medications may not necessarily result in a better therapy response, often leading to the exacerbation of the reported symptoms. Therefore adequate caution should be exercised in the prescription of multiple drugs. Furthermore, the effectiveness of the administered medication ought to be regularly assessed and followed by appropriate changes in the treatment plan.

[3007] Catastrophic Antiphospholipid Syndrome – A Case Report

Authors: Liutianska Nataliia, Parsai-Salekhi Leonid

Affiliation: Department of Internal Medicine 1, O.O. Bogomolets National Medical University

Trustee of the paper: V.V. Tishchenko, MD Candidate, docent; A.V. Neverovskyi, PhD

Corresponding author: Nataliia Liutianska ()

Background

Catastrophic antiphospholipid syndrome (CAPS) is the most severe form of antiphospholipid syndrome (APS) and is characterized by multiple thromboses of small vessels and multi-organ damage with poor outcomes. 75% of patients had systemic lupus erythematosus (SLE) and 69% of patients were females.

Case report

A 40-year woman presented to the neurological department with complaints of numbness and weakness in the right side of the face, and right arm, general weakness, and cough. A month before hospitalization she took a course of antibiotics. In 2012 a hysterectomy was performed due to cervical cancer. Laboratory research revealed anemia, increased C-reactive protein, decreased density of urine, antinuclear antibodies (ANA) at a titer of 1:3200, and a positive lupus anticoagulant. The deep venous thrombosis was excluded by duplex ultrasound. Computer tomography revealed multiple inclusions in the brain, thrombosis of the right atrium and pulmonary artery, consolidation of lung tissue, fluid in the left pleural cavity and pericardial cavity, and multiple changes in the parenchyma of the liver, spleen, and kidneys. The preliminary diagnosis of SLE complicated by probable CAPS was made. The probability of prolongation of cervical cancer with multiple metastases was not excluded. Treatment with glucocorticoids and anticoagulants was started. On the 6th day the patient was transferred to the intensive care unit with a preliminary diagnosis of acute pulmonary embolism of high risk and emergency treatment was initiated. Unfortunately, the patient died the next day. The immediate cause of death was a large thromboembolus in the pulmonary artery. An autopsy revealed intravascular thrombosis and squamous cell carcinoma with multiple metastases. Histological examination did not reveal lupus nephritis. We assume that the main trigger factor in the development of CAPS in this patient was squamous cell carcinoma and surgery. The ANA titer can be explained by the tumor process. The multiple areas of carcinoma were probably metastases from cervical cancer.

Conclusions

It is always necessary to consider CAPS in the presence of signs of multiple thromboses and multiple organ failure. It is necessary to prevent APS in aPL-positive patients and in the presence of provoking factors, multiple thrombosis and organ failure, which can prevent further unfavorable consequences.

[3002] Risk management of pharmacotherapy in a patient with arterial hypertension and type 2 diabetes during the treatment of depression

Authors: Maryna Savchuk

Affiliation: Bogomolets National Medical University, Kyiv, Ukraine

Trustee of the paper: Viktoriia Potaskalova, Candidate of Medical Sciences, Associate Professor, Department of Clinical Pharmacology and Clinical Pharmacy.

Corresponding author: Maryna Savchuk (marinkasavchukk@gmail.com)

Background

Arterial Hypertension (AH) is the main cause of morbidity worldwide and pharmacotherapy of depressive and anxiety states in these patients is relevant. For safe treatment, it is necessary to evaluate the effectiveness and safety of drugs and use personalized treatment with monitoring of the patient's condition.

Case report

Patient M., 64 years old, was admitted to the hospital with complaints about burning pains behind the sternum, passing after a rest and taking nitrates, headaches, dizziness, shortness of breath. The patient was also disturbed by insomnia, anxiety and depression. The psychiatrist prescribed mirtazapine. The patient had type 2 diabetes (DM). Diagnosis upon admission: hypertension, ischemic heart disease, DM. At the preclinical stage, depression with anxiety and an inflammatory process of the urinary system were also diagnosed. The patient took 11 drugs at the same time (levofloxacin, hemoderivative from the blood of Bos Taurus, a combination of perindopril and indapamide, lercanidipine, ethacizine, acetylsalicylic acid, glimepiride, metformin, gidazepam, mirtazapine and a salt of alpha-lipoic acid). This is evaluated as polypharmacy. The interactions of the drugs were analyzed. The combination of mirtazapine with iACE or calcium channel blockers can increase blood pressure. Combinations of glimepiride with lercanidipine or levofloxacin and fluoroquinolone or aspirin with metformin increase the risk of hypoglycemia. Using mirtazapine, levofloxacin and indapamide at the same time can prolong the QT interval. iACE in combination with levofloxacin is associated with the risk of toxic reactions of fluoroquinolone. Aspirin with gidazepam increases the concentration of the last one in the blood. The diuretic accelerates the excretion of levofloxacin by inducing diuresis. The patient had 12 potentially dangerous drug interactions due to polypharmacy.

Conclusions

Patients with concomitant chronic diseases have a high risk of adverse drug reactions due to polypharmacy. The described case showed frequent possible unwanted drug interactions in patients with AH and depression, which requires careful monitoring of blood pressure and ECG. Concomitant DM limits the use of some groups of drugs due to the risk of developing hypoglycemia. The effectiveness and safety of the treatment is ensured by the control of laboratory indicators and the patient's condition with the correction of drug doses.

Neurological Case Report

Date: 22nd April 2023, 9:00 AM

Coordinator:
Weronika Górska

[1518] Think zebras – rare case of the Galen Vein thrombosis in 39-Years-Old Patient after COVID-19

Authors: Wiktoria Nowak

Affiliation: Students' Scientific Association Department of Neurology, Faculty of Medical Sciences in Katowice, Medical University of Silesia, 40-752 Katowice, Poland

Trustee of the paper: Tomasz Chmiela MD, Joanna Siuda MD, PhD

Corresponding author: Wiktoria Małgorzata Nowak (vikinowa111@gmail.com)

Background

Cerebral Vein Thrombosis (CVT) is an uncommon condition accounting for less than 1% of stroke cases. Isolated thrombosis of the Galen vein is very rare with only a few cases reported in the literature. Because both thalami drain into the vein of Galen and straight sinus, bilateral thalamic involvement is frequently encountered in internal CVT, however unilateral thalamic infarction may also occur, even if cerebral veins are occluded. Here, we would like to present a case of a previously healthy Polish patient with Galen vein occlusion, after a documented history of COVID-19.

Case report

A 39-year-old male was admitted to the Neurology Department in order to broaden the investigation of non-specific abnormalities in left thalamus revealed in an MRI study. Patient in good overall condition, with 2-month history of moderate headache, memory and attention disorder, which occurred during COVID-19 infection. Neurological examination on admission revealed only mild left side paresis (on the Lovett scale - 4). Digital Subtraction Angiography and Brain MRI showed the occlusion of the Galen vein and the evidence of Unilateral Left Thalamic Ischemic Stroke. Patient was treated with Low Molecular Weight Heparin and then with factor Xa inhibitors with full clinical recovery. Follow-up veno-MRI study performed after 12 months showed partial recanalization of Galen vein. Tests for coagulopathies were uninformative.

Conclusions

Attention should be drawn to the possibility of deep cerebral vein thrombosis occurring after SARS-CoV-2 infection and to indicate that even a relatively mild course of COVID-19 may be associated with this severe neurological complication even in patients without vascular risk factors.

[1537] Importance of psychiatric manifestation - case series of autoimmune encephalitis with anti-LGI-1 antibodies

Authors: Karolina Pendrasik, Dominika Świerczewska, Michalina Wiwatowska-Ligęza

Affiliation: Department of Neurology, University Hospital No 1, Medical University of Lodz.

Trustee of the paper: Bartosz Bielecki MD, PhD

Corresponding author: Karolina Pendrasik (karolina.pendrasik@stud.umed.lodz.pl)

Background

Autoimmune encephalitis (AE) with anti-leucine-rich glioma inactivated-1 (LGI-1) antibodies is rare and not a fully known group of inflammatory diseases of the central nervous system. LGI-1 is a neural protein associated with Voltage Gated Potassium Channel (VGKC) and it plays an extremely important role in synaptic transmission. The deficiencies of this protein can lead to epileptic seizures and psychiatric symptoms, including cognitive deterioration.

Case report

Case 1: A 73-year-old man with rapidly progressive cognitive impairment, psychiatric symptoms and epilepsy. In addition, he suffered from persistent hyponatremia. The serological examination of the cerebrospinal fluid (CSF) and serum revealed anti - LGI-1 antibodies. Magnetic resonance imaging (MRI) showed subtle signal abnormalities in the insula in both brain hemispheres. The same lesion demonstrated restricted diffusion with low signal intensity on an ADC map. He was treated with sodium valproate and steroids.

Case 2: A 68-year-old woman with rapidly progressive dementia, positive psychiatric symptoms and epilepsy. Laboratory blood tests showed hyponatremia. Both the CSF and serum serological tests revealed anti- LGI-1 antibodies. Brain MRI revealed restricted diffusion in subcortical white matter with low signal intensity on ADC map. EEG showed diffuse slow theta waves without seizure activity. She was treated with steroids and plasmapheresis as well as anticonvulsants and antipsychotics.

Case 3: A 61-year-old man with progressive cognitive impairment and epileptic attack. Laboratory blood tests showed hyponatremia. MRI revealed hyperintensity of the medial temporal lobe on FLAIR. CSF analysis revealed the presence of anti-LGI-1 antibodies. EEG showed generalized seizure activity. Oncological screening was performed and revealed gastrointestinal stromal tumor (GIST).

Conclusions

Cognitive decline with productive symptoms may occur and dominate in the AE, consequently it can be misdiagnosed as a psychiatric disorder. Typical features of epilepsy are faciobrachial dystonic seizures (FBDS). Oncological screening is crucial due to common paraneoplastic syndromes. AEs respond well to immunotherapy. The better recognition will be principal for the early diagnosis, treatment and further studies.

[1559] Effectiveness of rehabilitation for the patient after cervical spine ischemic stroke

Authors: Paulina Petkevičiūtė, Saulė Bielinytė

Affiliation: Lithuanian University of Health Sciences, Faculty of Medicine, Kaunas, Lithuania

Trustee of the paper: MD Laura Petrusevičienė

Corresponding author: Saulė Bielinytė (saule.bielinyte@gmail.com)

Background

Spinal cord stroke is a rare but serious disorder. It accounts for up to 1% of all strokes and for up to 2% of all neurological vascular emergencies. Clinical presentation includes anaesthesia, weakness of limbs, back or neck pain, and autonomic symptoms. There is no specific treatment, besides prevention of complications, treatment of the underlying cause and rehabilitation.

Case report

A 67-year-old man was hospitalized for treatment of spinal cord ischemic stroke at C3, C6-7 levels. The possible cause was atherothrombosis related to dyslipidemia. The patient complained of weakness in the hands and left leg, urinary retention. After treatment in the neurology department, the patient was transferred to the neurorehabilitation department. He spent 100 days, during which an individual rehabilitation program was applied including physical therapy, occupational therapy, massage, physiotherapy, and transcranial magnetic stimulation. Changes in muscle strength of the limbs according to the Lovett scale at the beginning and end of rehabilitation: in the right arm proximally from 4 to 5, distally from 0 to 2, in the left arm proximally from 4 to 5, distally from 0 to 1, in the right leg proximally from 3 to 5, distally from 3 to 5, in the left leg proximally from 2 to 4, distally from 0 to 4 points. Hand function and coordination were assessed using a Box and Block Test in the middle and at the end of rehabilitation. Right hand improved from 33 to 38, left hand - from 27 to 46 blocks per minute. To assess hand strength dynamometry was evaluated and results enhanced in the right hand from 0.5 to 1.2 kg, in the left hand from 0.4 to 1.6 kg. A finger grip force also improved in the right hand from 0.4 to 0.5 kg, in the left hand from 0.1 to 0.4 kg. Another positive change was observed during rehabilitation - urinary retention regressed (the need of intermittent catheterization decreased from 5 to 1 time a day). Functional independence test results changed from 48 to 84 points. Barthel index results improved from 10 to 60 points.

Conclusions

Spinal cord stroke is less common than cerebral stroke, but it still causes significant mortality, disability, and reduced quality of life. However, with timely diagnosis of the disorder and comprehensive specialist care, including early rehabilitation, good functional outcomes can be achieved.

[1624] COVID-19-mediated autoimmune encephalitis

Authors: Emilija Šlajūtė, Vytautas Danielius

Affiliation: Faculty of Medicine, Lithuanian University of Health Sciences, Lithuania

Trustee of the paper: Renata Balnytė, Department of Neurology, Hospital of Lithuanian University of Health Sciences Kauno Klinikos, Lithuania

Corresponding author: Emilija Šlajūtė (slajute.emilija@gmail.com)

Background

The SARS-CoV-2 infection generally presents with respiratory symptoms, however, it has also been linked to numerous neurological complications including COVID-19-related autoimmune encephalitis [1]. Many studies point out the role of SARS-CoV-2 in triggering autoimmune reactions, rather than direct invasion, as rRT-PCR positivity for SARS-CoV-2 in CSF and its alterations characteristic to viral encephalitis are rare. Therefore Covid-19 encephalitis might be less evident and prompt the diagnosis of autoimmune encephalitis [2,3].

Case report

A 65-year-old woman with rheumatoid arthritis developed a mild fever on day 1 of the illness and was later revealed to have also experienced a seizure. After 4 days, she was hospitalized due to a suspected ischemic stroke as the patient became confused and had slurred speech. Routine blood tests, brain CT, and CSF analysis were normal. Two days after admission, the patient was diagnosed with COVID-19 infection (SARS-CoV-2 RNA detected in a nasopharyngeal swab) and pneumonia and transferred to the intensive care unit due to respiratory failure and state of consciousness according to the Glasgow Coma Scale (GCS) a score of 6. Repeated CSF analysis showed no evidence of neuroinfection, autoimmune encephalitis panel, and other viral pathogens were negative. Brain MRI and EEG (performed after the observed seizure episode) showed changes characteristic of autoimmune encephalitis. Therefore based on the Graus criteria, the patient was diagnosed with possible COVID-19-mediated autoimmune encephalitis. After treatment with cefuroxime and a course of intravenous methylprednisolone, the patient's condition improved significantly, and neurological symptoms resolved.

Conclusions

The awareness of COVID-19 neurological symptoms and complications is important, and a full diagnostic work-up should be performed to evaluate the etiology of symptoms for accurate diagnosis and effective treatment results. This case also suggests that neurological symptoms may precede or accompany respiratory distress in COVID-19 infection.

[1668] Headache, pyrexia, and meningeal signs do not have to mean neurological infection – diagnosis of arteriovenous fistula secondary to RICA aneurysm

Authors: Weronika Zając

Affiliation: Department of Neurology of Medical University of Warsaw, Bielański Hospital

Trustee of the paper: lek. Agnieszka Andrzejczak-Sobocińska, lek. Stanisław Słyk

Corresponding author: Weronika Helena Zając (weronikazajac182@gmail.com)

Background

Internal carotid artery (ICA) supplies blood to all parts of the brain through its branches, therefore a formation of a fistula between ICA and a cerebral vein is a dangerous condition. The risk factors include Ehlers-Danlos syndrome type IV, neurosurgical procedures, or an aneurysm but it can arise spontaneously. If the blood flow is undisrupted or the fluid accumulates posteriorly in the vessels, neurological symptoms can appear with the most prominent being a headache. In this work, I am discussing a case of a fistula formed because of a ruptured aneurysm of the right internal carotid artery (RICA).

Case report

A 23-year old female without a past medical history of neurological problems but of vaginal hemorrhage, presented with a severe, 2-week headache, pain in the thoracic region of the spine, and pyrexia (up to 39°C) not subsiding after antipyretics. In the emergency room (ER) she was referred to a neurologist on account of her headache. Neurological examination revealed positive meningeal signs (Kernig's sign and neck stiffness), photophobia, hyperacusis, and brisk tendon reflexes on all 4 extremities. Since those symptoms were characteristic of neurological infectious diseases, a lumbar puncture was performed to analyze the cerebrospinal fluid (CSF). However, the test results were normal. Additionally, magnetic resonance imaging (MRI) was performed, not revealing any pathology in the brain. Only after computed tomographic angiography (CTA) of the cerebral vessels, an abnormal structure of RICA on the level of C4 vertebrae could be seen. As there was an interconnection between the artery and cavernous sinus, she was diagnosed with a carotid-cavernous fistula (CCF). The walls of RICA were damaged, so it was assumed that the cause was a rupture in an aneurysm of the artery. After the diagnosis, the patient was referred to a neurosurgical clinic for further treatment.

Conclusions

The arteriovenous fistula between the cavernous sinus and ICA could be caused by a ruptured aneurysm of the artery. It has no specific clinical manifestations that can differentiate it from other neurological problems hence, the fistula is often misdiagnosed with neurological infectious disease due to the presence of headache, brisk reflexes, and meningeal symptoms. Consequently, it is vital to perform radiological imaging as it unveils pathologies in the structure of cerebral tissue and vessels responsible for the unspecific manifestations.

[1683] Is it just epilepsy? – CLIPPERS syndrome case report

Authors: Gabriel Majewski

Affiliation: Students' Scientific Society at the Department of Neurology in Bielański Hospital; Medical University of Warsaw

Trustee of the paper: Agnieszka Korzeluch MD, Stanisław Słyk MD

Corresponding author: Gabriel Franciszek Majewski (g.majewski113@gmail.com)

Background

Chronic lymphocytic inflammation with pontine perivascular enhancement responsive to steroids (CLIPPERS) is an inflammatory central nervous system (CNS) disease, which mostly involves the brainstem, the pons and structures such as the cerebellar peduncles, cerebellum, medulla and the midbrain. The condition features a combination of clinical symptoms related to the affected brain parts pathology and a characteristic magnetic resonance imaging (MRI) appearance with multiple punctate, patchy and linear regions of contrast enhancement. As the name suggests, this syndrome responds to immunosuppressive treatment based on glucocorticoids (GCSs), expressed as both clinical and radiological improvements. Only a few cases were described so far.

Case report

60-year-old woman was admitted to the Neurology Department with 3 separate episodes of generalized seizures. In history, patient had suffered from epilepsy as a result of suspicious cell proliferation in CNS had been treated for Cushing's syndrome due to empty sella syndrome. During the examination, the woman was conscious, with cognitive impairment. The neurological examination revealed aphasia, echolalia and perseverations. Moreover, the patient suffered from right hemispatial neglect and severe problems with short-term and long-term memory. Ataxia of torso and limbs was observed with arms' postural tremors. Bilateral Babinski sign occurred. Additionally, cerebrospinal fluid test showed pleocytosis and mildly elevated protein at 63 mg%. There were no oligoclonal bands or malignant cells. The MRI examination showed punctate and linear changes of contrast enhancement in the right middle cerebellar peduncle, as well as cerebellar peduncles, the pons, cortical and subcortical atrophy, which lead to the diagnosis of CLIPPERS syndrome. Prednisone treatment and motor rehabilitation were applied to detained progression of disease.

Conclusions

CLIPPERS syndrome is characterized by extremely variable symptomatology of symptoms associated with involvement of the affected structures. Although the syndrome responds to steroid treatment, it is not a benign condition. Studies show, that no patient has completely recovered, and without chronic immunosuppression, the disease can recur. Furthermore, no uniform therapeutic procedure has been established so far. Clinicians are advised to take this disorder into consideration in the diagnostic process, as early diagnosis and treatment can result in better long-term functional outcomes.

[1685] Repeated Courses of Gamma Knife Radiosurgery – Potential Approach to Melanoma with Recurrent Brain Metastases

Authors: Krzysztof Tomasz Bieliński

Affiliation: Students' Scientific Group of Multidisciplinary Oncology “Onkosfera”, Department of Soft Tissue/Bone Sarcoma and Melanoma, Maria Skłodowska-Curie National Research Institute of Oncology in Warsaw

Trustee of the paper: Pawel Sobczuk MD PhD, Katarzyna Kozak MD PhD, Prof. Piotr Rutkowski MD PhD

Corresponding author: Krzysztof Tomasz Bieliński (krzysbielinski@wp.pl)

Background

Immunotherapy is a gold standard for the treatment of patients with metastatic melanoma but its activity in brain metastases (BMs) is unclear. A combination of immunotherapy with radiotherapy is known to enhance responses and overall survival in patients with melanoma BMs. Radiosurgery (SRS) is the radiotherapy of choice in the treatment of small lesions. No standardized treatment option has been established for recurrent BMs after SRS. Moreover, benefits of repeated SRS in patients with recurrences remain understudied.

Case report

A 75-year-old male patient diagnosed with back melanoma without BRAF V600 mutation underwent the resection of a primary lesion in October 2018 (pT2bN0, negative sentinel lymph node biopsy). In July 2019, an ultrasound scan and fine needle aspiration of the left axillary lymph node showed lymph node metastasis. A CT scan revealed two pulmonary metastatic lesions, while a brain MRI showed two inoperable BMs. The chosen therapy was a combination of immunotherapy and Gamma Knife radiosurgery (GKR). The patient started systemic treatment with nivolumab (240 mg q2w) in September 2019. After 1st cycle of nivolumab patient experienced an increase of cardiac troponin and creatine kinase but parameters normalized after treatment with prednisone and the patient could continue nivolumab. Simultaneously with the first cycle, he underwent the first SRS with GKR. A Follow-up MRI showed the regression of all BMs, while CT scans confirmed partial response in all extracranial lesions. A year later a Brain MRI in September 2020 showed new BMs. Subsequently, 5 lesions were irradiated with GKR, which resulted in a general decrease in the diameter of all BMs, except one. The patient underwent additional GKR for BMs, up to a total of 8 GKR procedures, with the last one performed in December 2021. Subsequent CT scans confirmed no disease progression. The patient remains on nivolumab for over 3 years.

Conclusions

The optimal approach to melanoma with extracranial dissemination and recurrent BMs is yet to be determined. The presented case demonstrates that immunotherapy and multiple sessions of SRS can be an effective approach to obtaining intracranial disease control in patients with good extracranial response to immunotherapy. Moreover, SRS should be considered in patients with the progression of single lesions, also outside the central nervous system.

[1692] Rare complications of COVID-19: Guillain-Barre-Strohl Syndrome and myocarditis following Pfizer/BioNTech (Comirnaty) vaccine

Authors: Krzysztof Nadgrodkiewicz, Gabriela Trojan

Affiliation: Kazimierz Pułaski University of Technology and Humanities in Radom

Trustee of the paper: Krzysztof Nadgrodkiewicz MD PhD

Corresponding author: Gabriela Trojan (pracanaukowa17@gmail.com)

Background

In recent scientific reports, Guillain-Barré-Strohl syndrome has been reported as an adverse reaction in people who received COVID-19 vaccines. The exact etiology of Guillain-Barré-Strohl is still unclear, although the autoimmune response is believed to play a vital role. An association between vaccination with mRNA preparations and the occurrence of myocarditis or pericarditis in adolescents and young adults is suspected.

Case report

A 32-year-old man with a history of post-vaccination myocarditis was transferred from the Department of Cardiology to the Department of Neurology due to motor disorders resulting from weakness of the lower limbs. In the clinical examination on admission, the cranial nerves were peripherally damaged to the left facial nerve. Upper limbs - distal muscle weakness, rated 4 on the MRC scale. Profound reflexes equal, weak, superficial, and deep feeling undisturbed, coherence normal. Lower limbs - paresis of distal muscles, MRC 3+. Deep reflexes absent, wading gait. Superficial and deep sensation undisturbed, coherence normal. The CSF showed an elevated protein concentration of 76 mg/dl, with cytosis 2. There were no oligoclonal bands in the cerebrospinal fluid and blood serum. IgG index 0.56.

In the EMG examination, slowed conduction in the motor and sensory fibers of large nerve trunks, prolonged latency, and reduced frequency of the F wave in the peroneal and tibial nerves were seen. The following therapy was implemented by applicable standards: intravenous immunoglobulin preparation of 400 mg per kg of body weight/day for five days - Privigen. After the treatment, the patient was transferred to the Rehabilitation Department, where the flaccid paresis of the distal muscles of the lower limbs worsened. After six weeks, an oral preparation of methylprednisolone was administered, achieving a significant regression of the symptoms of polyneuropathy syndrome.

Conclusions

GBS and myocarditis may develop as adverse events after COVID-19 vaccination. This must be considered; the disease should be diagnosed as early as possible to minimize symptoms and consequences and implement effective treatment as early as possible.

[1693] Treatment of multiple sclerosis as a therapeutic challenge

Authors: Krzysztof Nadgrodkiewicz, Gabriela Trojan

Affiliation: Kazimierz Pułaski University of Technology and Humanities in Radom

Trustee of the paper: Krzysztof Nadgrodkiewicz MD PhD

Corresponding author: Gabriela Trojan (pracanaukowa17@gmail.com)

Background

Multiple sclerosis (MS) is the most common inflammatory-demyelinating disease of the central nervous system. Currently, medicine cannot effectively stop the progression of the disease, which is why it is so important to develop and implement an effective individual therapeutic strategy.

Case report

A 27-year-old man diagnosed in 2013 with relapsing-remitting MS presents with pyramidal-cerebellar syndrome from the onset of the disease. From the pedigree analysis, it is known that the patient's mother also suffers from MS. The patient's diagnosis was confirmed by MRI examinations of the brain, cervical and thoracic cord, meeting the McDonald criteria. Type II oligoclonal bands were detected in the CSF. The patient underwent unsuccessful treatment with interferon beta-1a, glatiramer acetate, dimethyl fumarate, and teriflunomide. Individual treatments were interrupted by the patient due to the adverse effects of the drugs. During one of the hospitalizations, an ASCT transplantation procedure was started, which the patient interrupted. Due to high ARR, noticeable PIRA, EDSS increase by 3 points in the pyramidal and cerebellar systems, as well as rapid progression of the demyelinating process in brain MRI, the decision was made to implement induction therapy (1 gram of methylprednisolone + 20 mg of mitoxantrone - 3 cycles every 30 days). The neurological status improved, and natalizumab 300 mg IV every 30 days was started. The patient's anti-JCV serological status was negative. The current degree of functional efficiency was rated at 4 points on the EDSS scale. The presented case report is an example of the high effectiveness of induction therapy followed by escalation treatment.

Conclusions

Treatment of multiple sclerosis is aimed at minimizing the risk of subsequent relapses, inhibiting relapse-independent disability progression, reducing the number and activity of demyelinating plaques in the CNS, and inhibiting brain atrophy.

[1716] Blood pressure rollercoaster – difficulties in hypertension management in patients with autonomic nervous system failure

Authors: Michał Bochenek, Tomasz Piszczek, Natalia Nawrocka

Affiliation: Student's Scientific Group in the First Department of Cardiology, Interventional Electrocardiology and Arterial Hypertension, Jagiellonian University Medical College, Kraków, Poland

Trustee of the paper: dr hab. n. med Agnieszka Olszanecka, prof. UJ

Corresponding author: Michał Sebastian Bochenek (michalbochenek22@gmail.com)

Background

Blood pressure (BP) measurement in supine and standing position is one of the most basic parts of the physical examination, though often underestimated. Its changes might be the first indication of serious neurological conditions and require further diagnosis and treatment. We report a case of a patient with BP fluctuations associated with Multiple System Atrophy and related challenges in BP management.

Case report

A 58-year-old male was admitted to the ER with a suspected ischemic stroke. A few hours before admission he collapsed without the loss of consciousness and had a SBP of 50mmHg. Throughout the day, significant fluctuations of BP were observed and in the evening his neurological status worsened – dysarthria, left eyelid ptosis, and syncope at every try of verticalization appeared, which directly led to calling an ambulance. At admission, his BP was 86/42 mmHg, HR 95/min, SpO2 98%, with increased muscular tone, bradykinesia, dysarthria, and a positive Jacobson sign. The patient had a 7-year-long history of diagnosis towards neurodegenerative disease. After excluding a stroke, autonomic testing (TiltTest, electrophysical nerve test, Valsalva's maneuver) was performed, which showed sympathetic adrenergic dysfunction. A diagnosis of probable Multiple System Atrophy was made, midodrine and fludrocortisone were implemented and the patient was referred to outpatient cardiology care. At a 3-month follow-up, he continued to experience syncopes, and BP was labile (from 60/40 to 200/80 mmHg) – the biggest drops were time-correlated with taking L-dopa. The patient was given a short-acting hypotensive drug (losartan) for the night and ordered to wear compression socks. Further observation showed progression of parkinsonian syndrome, but for a long time there was no syncope.

Conclusions

The case presented highlights the importance of a comprehensive approach to the management of some patients presenting with neurological symptoms. The use of autonomic testing can be valuable in confirming a diagnosis and identifying underlying causes of symptoms. The patient's labile BP and syncope, particularly in relation to taking L-dopa, highlight the need for close monitoring of BP in patients with Multiple System Atrophy. The use of short-acting hypotensive drugs and compression socks can be effective strategies for managing blood pressure fluctuations in these patients.

[1819] Post-stroke epilepsy due to thalamic hemorrhagic stroke

Authors: Dorota Ratajczak, Agata Kaniewska

Affiliation: Department of Neurology Ludwik Rydygier Collegium Medicum in Bydgoszcz Nicolaus Copernicus University in Toruń

Trustee of the paper: dr n. med. Beata Kukulska-Pawluczuk

Corresponding author: Agata Kaniewska (agatakaniewska77@o2.pl)

Background

Stroke is the leading cause of seizures in the elderly. Post-stroke epilepsy develops in about 6% of patients. In the case of hemorrhagic stroke the morbidity increases up to 12%. Seizures are a rare manifestation of thalamic impairment. Neuroconnections between the thalamus and the cerebral cortex may serve as propagators of epileptic seizures and a damage to a specific region of the thalamus may affect the occurrence and specificity of these seizures.

Case report

A 71-year-old patient with a history of hemorrhagic stroke of the left thalamus was admitted to the Department of Neurology due to the first focal epileptic seizures in his life, turning into bilateral tonic-clonic seizures. He presented the classic picture of right-sided thalamic syndrome in the form of neuropathic pain, hemiparesis with the symptom of thalamic hand and chorea-pseudoathetic dyskinesia. Audiovisual recording of patient's movements shows signs of these disorders. Neuroimaging showed a hemorrhagic scar in the left thalamus and the posterior part of the body of the left lateral ventricle. EEG examination in the interictal period did not reveal any seizure activity. Neoplastic, metabolic and inflammatory causes of epileptic seizures were excluded. Post-stroke epilepsy was diagnosed and antiepileptic treatment was started.

Conclusions

The thalamus plays a key role in the global functioning of the brain. On the basis of the presented case, the authors present a diverse clinical picture of thalamic damage, the controversial role of the thalamus as a generator of epileptic seizures, and current recommendations regarding the diagnosis and management of post-stroke epilepsy.

[1821] Multifocal ischemic brain stroke as a clinical manifestation of the Trousseau Syndrome in a patient with lung adenocarcinoma - diagnostic and therapeutic challenges

Authors: Andrzej Kędracki, Andrzej Felski, Pola Altmajer

Affiliation: Chair and Clinic of Neurology, Faculty of Medicine, Ludwik Rydygier Collegium Medicum in Bydgoszcz, Nicolaus Copernicus University in Toruń

Trustee of the paper: PhD Beata Kukulska-Pawluczuk

Corresponding author: Andrzej Maria Kędracki (andrzejke2000@gmail.com)

Background

The Trousseau Syndrome consists in overcoagulation related to mucin-secreting adenocarcinomas. It has a complex pathogenesis. It is assumed that the primary mechanism leading to it is the interaction between mucin and selectin, with an excessive aggregation of trombocytes and the activation of factor X. The symptoms can be exacerbated by the increased secretion of the tissue factor participating in the pathway of exogenous coagulation and cysteine proteinase, also called the cancer pro-coagulant, which activates the factor X. The general medical condition typical for cancer illness is also significant: immobilization, dehydration, infections, and chemotherapy. Clinically, the Trousseau Syndrome manifests via, among others, vein thrombosis, pulmonary embolism, or brain stroke.

Case report

A 68-year-old male patient with lung adenocarcinoma (T2 N3 M0 IIIB TNM), with metastases to the bones and other internal organs, undergoing chemotherapy (cisplatin, pemetrexed), experienced a sudden onset of focal neurologic deficit manifesting through vision loss and muscle weakness in left extremities. Head neuroimaging (CT, MRI with contrast) revealed the presence of numerous, recent ischemic lesions in the supratentorial region of both brain hemispheres (the largest in the right occipital area) and in the cerebellum. No metastasis to the CNS has been observed. The patient was admitted beyond the time window qualifying for thrombolytic treatment/thrombectomy. Cardiac causes for embolism have not been identified, ultrasonography of carotid arteries did not show hemodynamically significant changes. Secondary ischemic stroke prophylaxis included acetylsalicylic acid and atorvastatin; with a preventive dosis of low-molecular weight heparin due to the increased risk of coagulopathy. Additional diagnostic tests prompted by the patient's symptoms revealed thrombosis in the left popliteal vein and pulmonary embolism, after which LMWH dose was increased to therapeutical, and acetylsalicylic acid was withdrawn. The patient was discharged in stable condition, with a subtle regression of neurological symptoms and recommendation to continue the oncological therapy.

Conclusions

On the basis of the presented case study and literature review, the authors discuss the current guidelines related to the diagnosis, as well as primary and secondary prevention of ischemic stroke, and the treatment of acute stroke in cancer patients.

[1848] Hypoaesthesia as a symptom of epilepsy: Case Report

Authors: Patrycja Kowalczyk, Paulina Pawlak

Affiliation: Medical University of Warsaw, SKN przy Klinice Neurologii Szpitala Bielańskiego

Trustee of the paper: lek. Stanisław Słyk, lek. Agnieszka Andrzejczak-Sobocińska

Corresponding author: Patrycja Kowalczyk (kowalczykpatrycja588@gmail.com)

Background

Epilepsy is one of the most common neurological diseases. According to statistical data, about 50 million people worldwide suffer from it. This condition is more often diagnosed in the elderly, but it affects people of every age, race and gender. It is usually manifested by seizures or loss of consciousness. However, the relevance of our case is to distinguish sensory disturbances as atypical symptoms of epilepsy. In the current literature, it is extremely difficult to find research papers concerning their incidence.

Case report

A 76-year-old man with symptoms of hypoesthesia occurring in the right half of the face, right upper limb, and occasionally lower limbs, lasting from a few to several dozen minutes, was admitted to the Neurology Department. Medical history showed a prevalence of hypertension and carotid atherosclerosis. A transient cerebral ischemic episode of vertebral and basilar arteries (in 2014) and other vascular dysfunctions were noted. Initially, medical record and symptoms lead to assumption of transient cerebral ischemic attacks. During neurological examination, patient was conscious and oriented. No abnormalities within motor and sensory cranial nerve innervation were found, as well as in area of spinal nerve innervation. Magnetic resonance imaging (MRI), doppler ultrasound of the intracerebral arteries and transcranial doppler ultrasound revealed no acute abnormalities. Computed tomography angiography (CTA), chest X-ray, Holter monitor showed no abnormalities related to the patient's symptoms. Head MRI with contrast revealed hemosiderin deposition as an outcome of hemorrhage in the Rolandic sulcus and choroid plexus xanthogranuloma. During hospitalization, the episodes of hypoesthesia of the right side of face, right upper extremity or, sometimes, lower extremities, lasting from few seconds to few minutes, were observed after long walk or verticalization. Based on the episodicity of observed hypoesthesia and subsequent EEG results, generalized epilepsy was diagnosed. The treatment was started by administering valproic acid. The patient began to recover - the episodes of hypoesthesia were less frequent.

Conclusions

Broad, non-standard diagnostics may play a crucial role in recognizing a disease. Thanks to this unusual case report, we draw attention to considering such nondistinctive symptoms, but marked by occurring episodically, in diagnosis of epilepsy.

[1885] Paraneoplastic cerebellar degeneration with anti-Yo antibodies: a case report

Authors: Zuzanna Roszkowska, Adam Surma

Affiliation: Medical University of Warsaw/Students Scientific Society Nekon of the Department of Neurology

Trustee of the paper: Łukasz Milanowski MD, PhD

Corresponding author: Zuzanna Roszkowska (s082681@student.wum.edu.pl)

Background

Paraneoplastic neurological syndromes (PNS) are rare (1-8/100 000 person-year), heterogeneous disorders which can be associated with any cancer, usually on an autoimmune background. Typically, it is not directly connected with the invasion of malignant neoplasm. The one that has an impact on cerebellum is called paraneoplastic cerebellar degeneration (PCD). The aim of this study is to present a case report of a patient with anti-Yo PCD.

Case report

A 68-year-old woman was admitted to the Department of Neurology, Faculty of Health Science, Medical University of Warsaw with a subacute 7-day history of an unsteadiness of gait. Neurological examination revealed dysmetria of lower limbs, scanning speech, bilateral positive Babinski sign. A head CT and MRI were inconclusive. Biochemical tests showed slightly elevated TSH. The general cerebrospinal fluid (CSF) examination was normal, but an auto immunological panel revealed anti-Yo antibodies in both CSF and blood serum, so the PCD was diagnosed. The whole-body CT scan was performed to find the underlying neoplasm and was negative.

The Intravenous Immunoglobulin (IVIg) treatment was implemented to improve patient neurological symptoms.

Patient is currently expecting the PET-CT scan for further examination.

Conclusions

PCD is a challenging condition to diagnose due to its non-specific clinical picture. It should be always considered in subacute, progressive cerebellar symptoms with unspecified cancer signs. Treatment options are limited.

[1991] Progressive multifocal leukoencephalopathy, immune reconstitution inflammatory syndrome – case report

Authors: Anna Motybel

Affiliation: Medical University of Warsaw, Students' Scientific Group, Department of Neurology

Trustee of the paper: Stanislaw Styk

Corresponding author: Anna Motybel (motybelanna@gmail.com)

Background

Progressive multifocal leukoencephalopathy (PML) is a rare demyelinating disease of the central nervous system. It is associated with an infection of the polyomavirus JC. The virus can replicate in glial cells and damage oligodendrocytes. This stage is associated with immunosuppression. At the time of clinical improvement, the properly functioning immune system causes immune reconstitution inflammatory syndrome (IRIS).

Case report

A 73-year-old female patient has been admitted to the neurology department twice – in September 2022 and six weeks later. Initially she presented to the hospital after two episodes of impaired consciousness with amnesia. Head CT on admittance did not show any significant changes. However, on MRI, an affected area was found. It was located in cortex and subcortical white matter of the left hemisphere. The contrast enhancement was heterogeneous and surrounded by oedema. Due to patient's medical history, the finding was considered as a tumor metastasis. The patient had had a mastectomy of her left breast five years before. She was treated with letrozole. In view of her state, dexamethasone was initiated. Before discharge, the patient was examined by neurosurgeon and qualified for the brain operation.

In October 2022, the patient has been admitted to the hospital again, after four episodes of epileptic seizures. During the patient's previous stay in the hospital, epilepsy had been diagnosed and treated with a valproic acid. CT and MRI were performed again. After medical consultation, there was the suspicion of PML-IRIS. Cerebrospinal fluid (CSF) analysis did not reveal any general abnormalities. The results of polymerase chain reaction (PCR) of genetic material of JC-virus in CSF was not prepared at the time of discharge.

Conclusions

In the setting of short duration of survival, there is a high morbidity and mortality. Despite of rare occurrence of PML-IRIS, this disease need to be included in differential diagnosis. Early diagnosis can help to minimize serious effects of the worsening condition.

[1993] Wilson or Hakim? Neurological manifestation of Wilson's disease

Authors: Katarzyna Banasiak

Affiliation: Student Scientific Association of Rare Diseases at the Department of Electrophysiology, medical University of Lodz

Trustee of the paper: Katarzyna Muras - Szwedziak MD, PhD; Krzysztof Kaczmarek MD, PhD

Corresponding author: Katarzyna Anna Banasiak (katarzyna.banasiak@stud.umed.lodz.pl)

Background

Wilson's disease (WD) is a rare hereditary disorder of copper metabolism. The prevalence of WD is estimated as 1 : 30,000. In order to lack of copper-transporting ATPase, an excessive amount of this element is composed in the patient's organs. There is a wide spectrum of clinical manifestations of WD. Usually, the most affected organ is liver. Patient can also present with psychiatric and neurological symptoms. The early diagnosis of WD is crucial, as proper treatment allows the disease to be controlled. Without the therapy or when it is implemented only when serious symptoms occur, the WD leads to premature death.

Case report

A 44 years old patient was admitted to the hospital in 2017 because of slowing down of speech. MRI revealed idiopathic normal pressure hydrocephalus (iNPH) and the area of gliosis. In the following months the patient reported imbalances and memory impairment. In 09.2019, because of failure of conservative treatment, the ventriculoperitoneal valve was implanted. The surgery was complicated by cerebral hematoma. After the implantation of the valve, the patient observed temporary improvement, but in 05.2020 he reported worsening of previous symptoms (tremors, speech disorders, unsteady gait). The drain and valve were replaced, which was complicated by meningitis. In 2021 the valve was removed, and a temporary external ventricular drain was placed. In 03.2022 the patient was admitted to the neurology department in order to extend the diagnosis due to deterioration of symptoms. In numerous blood tests, the serum copper and ceruloplasmin concentrations were determined. The tests revealed copper 550 ug/l and ceruloplasmin 14 mg/dl - both parameters below standard. In the CT the liver was nodular modeled, steatosis. Ophthalmologist determined a high probability of Kayser - Fisher rings. In the biopsy of the liver - steatosis and cirrhosis were confirmed. The result of genetic test confirmed the diagnosis of WD.

Conclusions

In this case neurological manifestation of WD was the main clinical problem. Because MRI findings in WD are non-specific, main disease was overlooked and iNPH was believed to be a causation of symptoms, which led to severe complications. Although there are no previous reports of iNPH associated with WD, other storage diseases (e.g Mucopolysaccharidosis) causes iNPH due to meningeal deposits. Although rare, WD should be taken into consideration in terms of insufficient improvement of symptoms and non-specific changes in brain imaging.

Pediatric Case Report

Date: 22nd April 2023, 15:15 PM

Coordinators:
Maja Kaczan
Julia Petelska

[1568] Mesenteric cavernous lymphangioma in a newborn initially diagnosed as ovarian hyperstimulation syndrome, id est diagnostic difficulties

Authors: Natalia Biedroń, Agnieszka Kwiatkowska

Affiliation: Student Research Group at the Department of Pathology of Newborns and Infants, University Children's Hospital in Lublin

Trustee of the paper: Agata Tarkowska MD, PhD

Corresponding author: Natalia Biedroń (nataliabiedron7@gmail.com)

Background

Hemangiomas and lymphangiomas are common benign tumours in infants and children. In most cases, the lesions are present from birth. They occur mainly on the head and neck but sometimes they can also appear in other parts of the body. The occurrence of mesenteric angiomas in newborns as well as cavernous angiomas in their internal organs are very rarely reported.

Case report

A four-day-old female newborn was admitted to the Department of Neonate Pathology (DNP) due to abnormalities detected by ultrasonography performed after birth. The child was born by caesarean section in the 38th week of the first pregnancy. The child's birth weight, body length and head circumference were normal. The pregnancy was burdened with oligohydramnios and gestational diabetes, hypothyroidism and arterial hypertension in the mother. On admission, the newborn was generally in good condition, circulatory and respiratory systems within normal parameters, with a hypertrophied clitoris.

Based on abnormalities on ultrasonography and elevated parameters of sex hormones, the clinical presentation suggested ovarian hyperstimulation. The patient was consulted several times by an endocrinologist, radiologist, gynaecologist and surgeon. Finally, a decision was made to qualify the child for surgery. In the pelvis, normal ovaries were found during surgery which ruled out the primary diagnosis. A large tumour of the mesentery was removed along with an adjacent fragment of the small intestine. The intestine was anastomosed end to end without complications. The histopathological examination of the excised lesion revealed a mesenteric cavernous lymphangioma.

On account of postoperative respiratory failure, the newborn was transferred to the Intensive Care Unit (ICU). On the fifth day after the surgery, the patient was transferred to the DNP. The child was placed in an incubator and ICU treatment and nutrition were continued. The child's condition gradually improved - the postoperative wound healed and enteral nutrition was started. Thirteen days later the girl was discharged home in good general condition.

Conclusions

Mesenteric angiomas are rare and the lesion has a non-specific appearance on ultrasonography, making a correct diagnosis before surgery difficult. Diagnosis is only possible via histopathological examination. The optimal treatment for mesenteric angioma is surgical resection. However, due to the fact that the tumour is not clearly demarcated and is not encapsulated, its removal can be difficult.

[1574] Nasal Glial Heterotopia in a 5-month-old girl: A Case Report and A Review of Literature

Authors: Jia Jia Teo, Piotr Kwast, Razan Nossier, Lidia Zawadzka-Głós

Affiliation: Pediatric Otolaryngology Department of the Medical University of Warsaw

Trustee of the paper: Dr. hab. n. med. Lidia Zawadzka-Głós

Corresponding author: Jia Jia Teo (angela.teojiajia2508@gmail.com)

Background

Nasal Glial Heterotopia (NGH) is a rare congenital mass commonly mistaken for a nasal polyp. In this case report we focus on the challenges of appropriate imaging techniques as well as the appropriate treatment method.

Case report

A 5-month-old girl presented with a mass in the left nasal cavity originating most likely from the roof of the nose. The mass was noted by the patient's guardian in the first 2 weeks of life. A CT scan with contrast and an MRI were performed in another facility showing, in addition, a possible defect of the floor of the anterior cranial fossa. We performed an endoscopy upon admission to confirm the location, size and possible origin of the mass, followed by a total transnasal endoscopic resection under general anaesthesia. The post-operative site revealed two possible skull base defects which were not able to be confirmed in the imaging studies. The excised mass was sent for histopathological examination which confirmed the diagnosis. There were no complications on the follow-up visits and no CSF leak was noted, the nasal patency was good and a completely healed surgical site was observed in endoscopy.

Conclusions

Differential diagnosis including mainly other congenital lesions of the nose relies strongly on radiological investigation. An appropriate choice of imaging studies is crucial for preparation for surgery, which is the only treatment. Children with NGH will usually be examined initially by paediatricians before being referred to otolaryngologists, therefore awareness about NGH in both specialties is beneficial. Additionally, challenges in radiological imaging in infants should be taken into account so that radiologists, paediatricians and otolaryngologists may work together to establish a proper diagnosis and treatment.

[1622] Steroid resistant nephrotic syndrome due to coeliac disease in 7-year-old girl

Authors: Monika Kondracka, Maja Kaczan

Affiliation: Students Scientific Circle within Warsaw Medical University's Pediatric and Nephrology Clinic, Warsaw Medical University

Trustee of the paper: Agnieszka Szmigielska, MD, PhD

Corresponding author: Monika Kondracka (monika7373@onet.pl)

Background

Nephrotic syndrome (NS) is a kidney disease, caused by damage of the glomerular filtration barrier. NS manifests itself with oedema, proteinuria, hypoalbuminemia and hyperlipidemia. The incidence of NS is 1,15-16,9 per 100 000 children. Corticosteroids are used as the main treatment for idiopathic NS in childhood. Steroid-resistant NS (SRNS) is usually managed with calcineurin inhibitors (cyclosporine and tacrolimus). NS can also be concomitant with neoplastic diseases, autoimmune disorders, reactions to drugs, and infections. There has also been reported a link between NS and coeliac disease (CD). CD is a chronic autoimmune enteropathy that develops as a result of an abnormal immune response to grains containing gluten in genetically predisposed individuals. CD has been described in the literature as one of the most common chronic diseases in the pediatric population, with an estimated prevalence of 1–2%. The clinical presentation ranges from features of malabsorption such as abdominal pain, diarrhea, steatorrhea and weight loss or growth failure to atypical forms of CD with more subtle gastrointestinal. The diagnosis is usually confirmed by immunological tests and a biopsy of the intestine.

Case report

A 7,5-year-old girl was admitted to the Department of Nephrology because of nephrotic syndrome. A year earlier, she had been diagnosed with the first episode of NS. GCs were started, but remission was not achieved after a month. Therapy of GCs was complicated by arterial hypertension, so amlodipine was added to treatment. After 6 weeks SRNS was diagnosed and kidney biopsy was performed. Biopsy revealed mesangial proliferation secondary to minimal change disease. Tacrolimus was added to treatment. However, due to side effects (diabetes) the drug was discontinued and cyclosporine was started. In addition, high TTG IgA (255.7) was found. Gastroscopy revealed no changes. SRNS genetic testing for NS was performed and a potentially pathogenic variant was found in the PLCE1 gene associated with type 3 nephrotic syndrome. A gluten-free diet was started and cyclosporine was discontinued after 6 months. During the 3-year follow-up the girl is healthy.

Conclusions

- 1) SRNS can be secondary to coeliac disease.
- 2) Gluten-free diet may help resolve nephrotic syndrome in a child with coeliac disease.

[1625] Magnet extraction through appendectomy laparoscopically (METAL) in a child 19 days after ingestion of neodymium magnet spheres - a video case report.

Authors: Bartosz Gajek (Presenting), Lidia Babiak-Choroszczak, Kaja Giżewska-Kacprzak

Affiliation: Department of Pediatric and Oncological Surgery, Urology and Hand Surgery, Pomeranian Medical University in Szczecin, Poland.

Trustee of the paper: Kaja Giżewska-Kacprzak

Corresponding author: Bartosz Bronisław Gajek (bartoszgajek02@gmail.com)

Background

Neodymium magnet ingestion in children is a well-known medical problem. Ingestion of a single magnet is usually asymptomatic and not dangerous. The foreign body is naturally excreted and conservative treatment is sufficient. In a case of swallowing multiple neodymium magnets, especially at a different time, could cause dangerous consequences, including obstruction, fistulas and multiple perforations of the digestive tract. Ingestion of multiple magnets correlates with an increased risk of emergent surgical intervention.

Case report

We present an interesting case of a 10-year-old girl who was admitted to a Pediatric Surgery Department after 19 days of observation in a Pediatric Gastroenterology ward after ingestion of two magnetic spheres (5 mm in diameter). The patient was in good general condition. As the length of the conservative treatment was disturbingly long, a decision to perform a low-dose contrast-free abdominal computed tomography was made. Two metal objects in the lumen of the appendix were visualized, but with no signs of perforation. The child was qualified for laparoscopic appendectomy. In our approach presented in the video material, the surgery was adjusted to the presence of the magnets with their initial visualization, the fast closure of the base of the appendix, and the absence of coagulation until the objects were extracted. The presence of two magnetic spheres was confirmed after the dissection of the excised appendix. The histopathological examination confirmed areas of inflammation. The child was discharged, and a long-term follow-up was uneventful.

Conclusions

Our goal is to draw attention to possible dangerous consequences of unjustified prolonged observation in cases of magnet ingestion in children in view of the most up-to-date literature, as well as emphasize the importance of early endoscopy and minimally invasive surgical interventions.

[1631] Kawasaki Disease in a 2-Month-Old Infant

Authors: Agnieszka Poniewiera, Anna Jastrzębska

Affiliation: Medical University of Warsaw

Trustee of the paper: dr Agnieszka Szmigielska

Corresponding author: Anna Maria Jastrzębska (anna.m.f.jastrzebska@gmail.com)

Background

Kawasaki disease (KD) is a self-limited vasculitis that is the most common cause of acquired heart disease among children. The incidence of Kawasaki disease is about 5-8 in Europe per 100,000 children younger than five years of age. It is even more uncommon in young infants. The younger the patient the less likely it is for other clinical criteria to occur. Sometimes the prolonged fever is the only symptom, which lowers the chance for correct treatment to be administered on time in order to minimise the chance of complications.

Case report

A 2-month-old male infant with no significant medical history initially presented with a history of two days of fever, two loose stools and maculopapular rash. The main physical examination findings on admission included fissured lips, coated tongue, cervical and submandibular lymphadenopathy and conjunctival redness. In CSF fluid findings were consistent with aseptic meningitis, CRP was elevated (16.1 mg%). The course of i.v. cefotaxime and vancomycin were started along with fever medication. There were no relevant findings in imaging studies including echocardiogram. After four days without improvement or reduction of fever, Kawasaki disease was diagnosed based on clinical picture. The patient was treated with IVIG and acetylsalicylic acid (ASA). The improvement was achieved based on reduction of fever and resolution of skin rash. In a follow up after one month no changes in coronary arteries were detected in echocardiogram. The ECG was normal. Lab test results still shown a high platelet count > 1 million and moderately elevated CRP. The physical examination had no relevant findings. The patient's parents don't report any symptoms or complaints at home. In a follow up after five years echocardiogram was normal.

Conclusions

This case report highlights the need to remember about Kawasaki disease whenever the cause of prolonged fever cannot be localised. It is a rare possibility for Kawasaki disease to occur in infants younger than 6 months of age and it is important to remain vigilant in order to start treatment as soon as possible.

[1694] Distal hereditary motor neuropathy associated with SIGMAR1 gene mutation.

Authors: Maciej Kalita [1], Anna Potulska-Chromik [2], Karolina Aragon-Gawińska [2], Maria Jędrzejowska [2], Maria Franaszczyk [3], Tomasz Stokłosa [3], Anna Kostera-Pruszczyk [2]

Affiliation: [1] Students' Scientific Association of the Department of Neurology, Medical University of Warsaw; [2] Department of Neurology, Medical University of Warsaw; [3] Department of Medical Genetics, Medical University of Warsaw

Trustee of the paper: Anna Potulska-Chromik, MD, PhD

Corresponding author: Maciej Michał Kalita (kalita.maciej00@gmail.com)

Background

Distal hereditary motor neuropathies (dHMN), also known as distal spinal muscular atrophy, form a clinically and genetically diverse group of neuropathies, characterized by distal weakness and muscle wasting. The onset most commonly occurs in childhood with slow progression of the disease. One of the dHMN types – Jerash type, caused by SIGMAR1 gene mutation, in addition to mentioned clinical features presents with pyramidal signs.

Case report

The patient is an 11-year-old boy presenting with motor dysfunction, progressing since the age of 4. The initial symptoms included: frequent falls, running slower than peers and foot-drop gait. Psychosomatic development abnormalities were not present in the first 24 months of patient's life. Family history of similar symptoms was negative.

Neurological examination revealed quadriparesis, more pronounced in distal than proximal muscle groups, more significant in lower limbs. Deep tendon reflexes were reduced in the upper limbs and absent in the lower limbs with coexisting Babinski sign on the right side. The follow-up examination after 7 months revealed bilateral Babinski sign. Sensory involvement was not present. Laboratory findings were insignificant.

Electrophysiological studies demonstrated axonal motor neuron damage as well as denervation and reduced voluntary action in right anterior tibial muscle.

Genetic testing (Next Generation Sequencing - NGS, neuromuscular panel) revealed presence of c.247T>C (p. Phe83Leu) (ref. NM_005866.4) homozygous variant in SIGMAR1 gene which confirmed dHMN, Jerash type diagnosis. NGS testing was also conducted in proband's mother and sister and in both cases one allele of the mentioned variant was present (heterozygote).

Conclusions

Presented case report demonstrates phenotype-genotype correlation and indicates a diagnosis of juvenile amyotrophic lateral sclerosis-like disease characterized by both upper and lower motor neuron involvement, without concomitant sensory involvement. In addition, due to clinical similarity of neuromuscular diseases, as well as – in some instances - genetic overlap, high throughput genetic testing methods may prove useful for providing correct diagnosis and prognosis.

[1700] **Agenesis of inferior vena cava: an unusual anomaly**

Authors: Magdalena Bukowska (first author), Malwina Wojtas

Affiliation: Medical University of Warsaw

Trustee of the paper: dr n. med. Agnieszka Szmigielska

Corresponding author: Magdalena Bukowska (s080349@student.wum.edu.pl)

Background

The pathologic spectrum of pediatric renal lesions ranges from asymptomatic cysts to malignant tumours comprising nephroblastoma

(the most common type of kidney tumour in children) and clear cell sarcoma.

The diagnostic process of aforesaid masses is based on imaging procedures. The increased use of radiology techniques allows not only to find the cause of patient-reported symptoms, but also to detect incidental lesions .

Case report

A 17-year-old male was admitted to the nephrology clinic in order to deepen diagnostic analysis of the venous anomaly - absence of the hepatic and the suprarenal segment of the IVC.

Since 06.2022 to 07.2022 patient was suffering from colic, stabbing pain in the right hypogastric region. Diarrhoea occurred at the end of the pain duration. USG revealed a cystic lesion in the right kidney. Blood tests results did not show any significant deviations from the norm: WBC 8,5 x 10⁹/L, Hb 16,7 g/dL, PLT 227 x 10⁹/L, CRP 0,12 mg/dL. BP within normal limits. There was no coexisting diseases apart from suspicion of glaucoma in the check-up examination. No kidney diseases in family health history.

During hospitalization in September 2022 urine tests revealed trace proteinuria (132 mg/24h) and border albumin excretion (34 mg/24h). USG of abdomen showed a thin-walled cyst with a mean diameter of 3cm. The lesion was localized in the right renal hilum. The pathologic mass was changing its volume according to the phase of respiration. Its almost complete disappearance was observed during Valsalva maneuver. CT scan revealed that hepatic and suprarenal segment of IVC did not enhance with contrast. There was an outflow of blood through the azygos and hemiazygos vein and well-developed collateral circulation consisting of tributaries of renal veins. The lesion in the right renal hilum in previous USG was identified in CT scan as a venous distention. Kidneys were normal size and had proper structure with no signs of urine retention. There was no premiss for surgical treatment. Follow-up care was recommended.

Conclusions

Agenesis of IVC is extremely rare anomaly with an estimated prevalence of 0.0005-1%. It may be asymptomatic until later in life. Nevertheless, the recognition of this anomaly is crucial to avoid misdiagnoses during imaging examination. Moreover, awareness of absence of IVC allows to be careful enough if it comes to possible consequences of described anomaly such as deep venous thrombosis.

[1708] Difficult management of supraventricular tachycardia in children. A case of 9 years-old patient with hemodynamic complications.

Authors: Filip Baszkowski, Julia Dzierła

Affiliation: Poznan University of Medical Sciences/Department of Pediatric Cardiology

Trustee of the paper: Weronika Pelczar-Płachta

Corresponding author: Filip Baszkowski (baszkowskifilip@gmail.com)

Background

Supraventricular tachycardia (SVT) is the most common clinical arrhythmia in pediatric population. With prevalence of 1:500, it is a popular problem in pediatrician's practice. The clinical presentation depends on the age of the patient and the type of SVT. In general, it is well-tolerated and has extremely low risk of complications (including cardiac arrest). The risk is significantly increased in patients with Wolff-Parkinson-White Syndrome (WPW). Hemodynamically unstable SVT require urgent intervention.

Case report

A 9-years-old patient was admitted to the cardiology department with heart palpitations, chest pain, nausea and increasing fatigue for 5 days. There were recurring, self-limited heart palpitations in his medical history. Electrocardiography revealed SVT with frequency 250 per minute and narrow QRS. The echocardiography showed left ventricle (LV) dysfunction with mild mitral and tricuspid insufficiency. NT-proBNP and troponin-I were elevated. After initial lack of reaction to the pharmacological treatment (low doses of adenosine, metoprolol, amiodarone), aggressive escalation of adenosine dose to 15mg cause termination of SVT and antiarrhythmic agent propafenone was used. During hospitalization gradual improvement of LV function and withdrawal of heart failure features were achieved. Extended capillary refill time and knee pain have paid additional attention to check D-dimers level, which were elevated. Angio-CT revealed thrombosis in internal iliac arteries and left posterior tibial artery. Genetic tests excluded presence of most frequent mutation causing congenital thrombophilia. Treatment with enoxaparin in therapeutic dose, salicylates and pentoxifylline were used and alleviated pain in lower limbs.

Recurrence of SVT was noticed one month later. Electrophysiological study showed concealed WPW with left-sided, retrograde conducted accessory pathway, which was clinically presented clinically as an atrioventricular reentrant tachycardia. Due to radiofrequency ablation accessory pathway were destroyed with the permanent withdrawal of SVT.

Conclusions

Coexisted accessory pathway is a cause and an independent risk factor of complications in SVT. Unusual manifestation should pay practitioner attention to the possibility of concealed WPW. Quick diagnosis, implementation of treatment and qualification to the radiofrequency ablation is crucial to stop further deterioration.

[1738] A rare case of congenital nonscarring alopecia on the scalp

Authors: Akvilė Vélavičiūtė

Affiliation: Vilnius University Faculty of Medicine, Vilnius, Lithuania

Trustee of the paper: Inga Kisielienė, MD

Corresponding author: Akvilė Vélavičiūtė (velakvile@gmail.com)

Background

In this case report, we present a rare case of pediatric congenital nonscarring alopecia on the scalp. The most common differential diagnoses in such cases are congenital alopecia areata, congenital triangular alopecia, aplasia cutis congenita, congenital hypotrichosis, and nevus sebaceous. Congenital alopecia areata is presented with smooth well-circumscribed patchy or total hair loss. Triangular alopecia usually starts at age 2-5 years and is clinically presented as a triangular, oval-shaped area of alopecia in the frontotemporal site. Aplasia cutis congenita is a skin malformation that presents as a localized skin defect. Congenital hypotrichosis usually presents with thin hair and a decreased number of hair follicles. Nevus sebaceous is presented with warty patches of hair loss on the scalp. The majority of these cases have very limited diagnostic and treatment options, which leads to challenges in disease management for the doctor and the patient.

Case report

A 7-year-old girl was brought to an outpatient pediatric clinic with a history of alopecia patch on the scalp since birth, the patient was otherwise healthy. Physical examination revealed a large (11x11 cm) bald patch on the mid-scalp region. The patient's skin on the area was thickened, not infiltrated and painless on palpation. Trichoscopy revealed typical skin structures and vellus hair. An ultrasound of the skin revealed a thickened hypodermis without any structural changes. A 2 mm diameter punch biopsy was taken from the bald patch on the scalp. Histopathological analysis revealed small hypoplastic vellus hair follicles. It was recommended that genetic testing to be performed to identify any significant mutations that could lead to congenital alopecia. Surgical treatment of hair transplantation is expected to be performed in the near future.

Conclusions

A thorough examination and genetic consultation are needed to find out the cause of congenital hypotrichosis. However, even if we cannot find out the exact diagnosis, the patient's psychological health must be taken into consideration, and other treatment options, such as hair transplantation, should be provided to improve the quality of life.

[1794] **Manifestation of anaplastic large cell lymphoma in the form of haemophagocytic lymphohistiocytosis in a 4-year-old girl**

Authors: Julia Białowas

Affiliation: Spherocyte, Medical University of Warsaw

Trustee of the paper: Mariusz Cieślak, MD

Corresponding author: Julia Białowas (juliabialowas25@gmail.com)

Background

Anaplastic large cell lymphoma (ALCL) accounts for 10-15% of childhood non-Hodgkin's lymphomas (NHL). It is characterised by the expression of the CD30 antigen on tumour cells. It is detected as advanced disease with frequent extranodal lesions involving the skin, soft tissues, bones. The first symptoms can manifest in many different ways.

Case report

A 4-year-old girl was admitted to hospital with recurrent fevers of up to 39 degrees, weakness and epigastric pain for 2 weeks, without other signs of infection. In laboratory tests: pancytopenia in morphology, ferritine 20000ng/ml, fibrinogen 0.3 g/l, low CRP. The myelogram showed features of haemophagocytosis, with no blast cells present. The girl fulfilled the criteria for HLH and she started treatment according to the HLH 2004 protocol - dexamethasone, etoposide. Initially she responded well to therapy, drugs were reduced. After a month she returned with symptoms of infection, which was ruled out on the basis of low inflammatory markers and no clinical improvement after antibiotics, so a relapse of HLH was diagnosed. After increasing drugs' doses, the child's condition improved. A month later, fevers began to reappear, there were isolated loose stools, abdominal pain, gradual anaemia, thrombocytopenia and an increase in inflammatory parameters. Further abdominal ultrasound showed enlarged lymph nodes in packs. Increasing abdominal lymphadenopathy with ascites was observed. A laparoscopic abdominal lymph node biopsy was performed. Histopathological examination showed anaplastic large cell lymphoma.

Chemotherapy was started according to the ALCL 99 protocol for the standard risk group. There was no improvement and the girl was reclassified to the high-risk group. Brentuximab vedotin (anti-CD30 monoclonal, cytostatic-conjugated antibody) was added to treatment and to qualify the girl for stem cell transplantation. After chemotherapy, the girl continued to show features of tumour progression as well as active haemophagocytic syndrome. The girl's condition was worsened, with respiratory failure, and she died four months after the cancer diagnosis.

Conclusions

The symptoms of HLH may be the first manifestation of the malignancy, making its diagnosis difficult. During the diagnosis of HLH, it is important to look for proliferative disease. HLH secondary to cancer is associated with a poor prognosis and therefore requires modification of the treatment of the underlying disease.

[1808] Difficulties in ALL therapy resulting from comorbidities on the example of a boy with Marfan syndrome - a case study.

Authors: Kacper Żurek

Affiliation: Student Scientific Club of Pediatric Oncology and Hematology of the Jagiellonian University

Trustee of the paper: Prof. dr hab. Szymon Skoczeń

Corresponding author: Kacper Szczepan Żurek (kapi2612.zurek@student.uj.edu.pl)

Background

The treatment of ALL is a difficult issue, due to the constant balance between effective and toxic doses. Particular attention should be paid to other comorbidities that may impair the patient's tolerance to treatment, consequently hinder therapy and worsen its prognosis.

Case report

A 12-year-old boy with Marfan syndrome, diagnosed with ALL (type common, with CD33 co-expression) intermediate risk group, since 2014 has been treated according to ALL IC-BFM 2009 protocol in Department of Pediatric Oncology and Hematology UCH. In 2016, due to relapse therapy according to the IntReALL-2010 protocol (SR group, arm A) was introduced. The WES analysis revealed numerous gene mutations predisposing to cancer, including CHEK2, while genome abnormalities in Marfan syndrome were detected (e.g.: MYH7 mutation predisposing to myopathy). Treatment was repeatedly interrupted due to severe side effects, e.g.: muscle weakness and progressive polyneuropathy. During treatment, numerous hematological and additional complications were observed like: pancytopenia, coagulation disorders, infections with opportunistic pathogens (fungal pneumonia). During the second-line chemotherapy, intolerance to vincristine and vindesine was found, which forced modifications in subsequent cycles of chemotherapy. Another complication was epilepsy and behavioral disorders that found their origin in changes in CSN. Due to the localization of the disease in the testicles, local radiotherapy was necessary.

Conclusions

In July 2019, the therapy was completed. The boy remains in remission of disease. Due to secondary immunodeficiency, he is under the control of the immunology department. He was followed by a neurologists, currently antiepileptic drugs were discontinued. So far, isolated cases of coexistence of these two disease entities have been described. Congenital disorders associated with Marfan syndrome cause particular diagnostic and therapeutic difficulty if cancer is additionally diagnosed.

[1814] **Lymphocytic colitis: An unexpected cause of chronic diarrhea in paediatric patient**

Authors: Martyna Stobiecka, Anna Olejarz

Affiliation: Department of Paediatrics, Faculty of Medical Sciences in Zabrze, Medical University of Silesia in Katowice

Trustee of the paper: dr Katarzyna Bąk-Drabik

Corresponding author: Martyna Anna Stobiecka (martin.stobiecka@gmail.com)

Background

Lymphocytic colitis, a histologic form of microscopic colitis, was recognized and first described four decades ago. Microscopic colitis typically manifests with chronic watery non-bloody diarrhea, abnormal inflammatory histopathological findings, but normal endoscopy results. As it is mainly a condition of the adults, paediatric data are limited. Very few cases of lymphocytic colitis have been reported in the paediatric population and are available in the medical literature.

Case report

We describe a 5-years old male patient with psychomotor development disorder, vitiligo and nephrotic syndrome admitted to hospital for further diagnostics of chronic diarrhea. Persistent, watery stools (4 to 5 per day) have been presented for one year. During steroid therapy due to nephrotic syndrome gastrointestinal symptoms were masked and diarrhea withdrawal was observed, but reoccurred after discontinuation of the treatment. During the hospitalization, blood tests (including serology of coeliac disease), and fecal calprotectin test remained normal. Carbohydrate intolerance was excluded. The macroscopic picture in gastroscopy and colonoscopy showed no abnormalities. The result of the histopathological examination from colonoscopy finally confirmed the diagnosis of lymphocytic colitis.

Conclusions

Lymphocytic colitis should be considered in differential diagnosis of chronic watery diarrhea in paediatric patients with no macroscopic abnormalities in endoscopic examination.

[1816] A severe case of pediatric SLE with lupus nephritis and serous membrane effusion

Authors: Joanna Pergoł

Affiliation: Medical University of Warsaw

Trustee of the paper: dr hab. n. med. Małgorzata Mizerska-Wasiak

Corresponding author: Joanna Katarzyna Pergoł (joanna.pergol8@gmail.com)

Background

Systemic lupus nephritis (SLE) is a disease, usually involving several systems and organs, including the kidneys. Pediatric patients account for 15-20% of all diagnoses. Lupus nephritis (LN) is a rare illness occurring in 40% of SLE patients and is one of the main determinants of poor prognosis. Its prevalence varies considerably according to ethnicity, gender, and age. Despite anti-inflammatory and immunosuppressive treatment, it leads to end-stage renal failure in up to 10% of cases. In addition, LN is one of the main risk factors for death in patients with SLE, and the risk varies according to the class of lupus glomerulopathy presented. The spectrum of clinical manifestations differs from silent urinary abnormalities to nephrotic syndrome or rapidly progressive renal failure. In the pediatric population, the features of LN are non-specific for acute glomerulonephritis and include haematuria, proteinuria, renal tubules, hypertension, peripheral edema, and acute/chronic kidney damage.

Case report

A 10-year-old girl was admitted to the hospital for left-sided pleuropneumonia presenting with respiratory distress. Initially, she was referred by a pediatrician after being diagnosed with pneumonia with symptoms: fever up to 39 °C, vomiting, slight cough, and shortness of breath. During hospitalization, the patient was diagnosed with SLE with a very severe course and rare complications. The disease presented with renal involvement in the form of class III lupus nephropathy, serous membrane involvement (with threatening cardiac tamponade), hypertension, and venous thrombosis. The patient also had to be admitted to the intensive care unit due to posterior reversible encephalopathy syndrome (PRES). Moreover, she had been diagnosed with juvenile idiopathic arthritis two months earlier. The girl was treated with pulses of glucocorticosteroids, intravenous immunoglobulin, low-molecular-weight heparin, acetylsalicylic acid, antibiotics, numerous hypotensive drugs, plasmapheresis, and cyclophosphamide. After 1.5 months, the patient was discharged home in stable condition, with normal renal function (creatinine 0.33mg%), and proteinuria (238mg%). The girl is currently under the care of the Nephrology Clinic receiving Endoxan pulses as a treatment.

Conclusions

Pediatric SLE is recognized to have a more active disease course and thus rare and difficult-to-maintain complications can occur, like cardiac tamponade. It is important to remember that LN poses a significant risk to the patient's life.

[1825] Pediatric patient with Down syndrome and classical Hodgkin lymphoma.

Authors: Ilona Koziół, Magdalena Leśniewska, Julia Budzyńska

Affiliation: Student Scientific Society of the Department of Pediatric Hematology, Oncology and Transplantology, Medical University of Lublin, Poland

Trustee of the paper: Małgorzata Mitura-Lesiuk, MD PhD

Corresponding author: Ilona Koziół (ilona.koziol9@gmail.com)

Background

Down syndrome (DS) is one of the most common chromosomal abnormalities and its incidence has increased in recent decades, despite a decline in birth rates. DS are more likely to develop both myeloid and lymphoblastic leukemia. It is unknown what causes malignant transformation in children with DS, although solid tumors and Hodgkin's disease are rarely seen in these children. There are few case reports of the co-occurrence of DS and Hodgkin's disease. The mortality rate of these cases was high, with fifty percent dying from disease or treatment-related complications.

Case report

A girl aged 10 with Down's syndrome and a congenital heart defect was admitted to the Department of Pediatric Cardiology due to a fever of up to 39 degrees Celsius with accompanying lymphadenopathy, which did not respond to cefuroxime and clarithromycin therapy. In the examinations performed at that time, abnormal parameters of inflammation were found. In neck USG: numerous, enlarged lymph nodes on both sides of the neck, the largest in the vicinity of the angles of the mandible, measuring up to 28 x 16 mm, with a reactive character. Amikacin was added to the treatment. Initially, the girl's clinical condition improved, then the fever reappeared, increased CRP and ESR. After obtaining negative results of virological tests and in the absence of response despite the modification of treatment for IE and further progression of the size of lymph nodes, a decision was made to harvest the lymph node. The result of the histopathological examination of Classical Hodgkin's lymphoma, nodular sclerosis/NS II, and stage IIB. The patient was qualified for the TG-2 group (2 x OEPA, 2 x COPDAC). The response after 2 blocks of chemotherapy was good (regression of nodal lesions in imaging studies greater than 75% and negative PET-CT result).

Conclusions

Although fever has a number of more common causes in the pediatric population, we should maintain oncological vigilance to prevent the progression of neoplastic processes. Down syndrome patients are uncommonly diagnosed with Hodgkin's lymphoma. In order to optimize therapy for DS patients, it is important to observe how they respond to treatment in terms of disease response and side effect profile.

[1845] **Streptococcus intermedius Acute Meningitis in an Immunocompetent Child**

Authors: Kamil Tkacz (1); Anna Piwowarczyk (2); Edyta Podsiadły (3)

Affiliation: (1) Faculty of Medicine, The Medical University of Warsaw, (2) Department of Pediatrics with Clinical Assessment Unit, The Medical University of Warsaw, (3) Department of Pharmaceutical Microbiology, Faculty of Pharmacy, The Medical University of Warsaw

Trustee of the paper: Ernest Kuchar, MD PhD

Corresponding author: Kamil Tkacz (kamilt2001@gmail.com)

Background

Streptococcus intermedius is a Gram-positive member of the *Streptococcus anginosus* group (SAG) of bacteria. It is a microbiota of the oropharynx, urogenital and gastrointestinal tract. Infections caused by SAG range from minor to more severe infections involving the head and neck regions, lungs, abdomen, and soft tissues. SAG bacteremia is associated with a higher risk of developing abscesses. *S. intermedius* tended to be more frequently detected in older patients. Meningitis is an extremely rare complication of *S. intermedius* infection in children.

Case report

A 6-year-old boy was admitted to the hospital due to fever, headache, and neck pain. Mild respiratory tract infection preceded these symptoms. The boy seemed uncomfortable and had altered mental status. On examination, vital signs were normal, neck stiffness and ambiguous Kernig's sign were noted. There were no focal neurological signs. No vomiting, nausea, irritability, or photophobia was noted. The laboratory testing revealed elevated leukocytosis, C reactive protein and procalcitonin. A lumbar puncture yielded cloudy cerebrospinal fluid (CSF) with high protein, low glucose, increased lactates, high pleocytosis and 88% of neutrophils. Ceftriaxone, vancomycin, and dexamethasone therapy was empirically implemented for suspected bacterial meningitis. A multiplex PCR from CSF for common viral, bacterial, and yeast pathogens was negative. Gram positive cocci were detected in blood culture and CSF and were identified with mass spectrometry as *S. intermedius*. Due to mild consciousness disturbance and facial nerve asymmetry, a head computed tomography scan was performed. The result did not show any bone plates destruction or other pathological changes, particularly a brain abscess. Susceptibility to benzylpenicillin, ceftriaxone and vancomycin was confirmed. Vancomycin was discontinued in a targeted treatment, and the child was cured with ceftriaxone for 14 days. At the end of the treatment, the patient was discharged home without any neurological sequelae. In the 6-months follow-up he did not present any complications.

Conclusions

S. intermedius may be responsible in central nervous system not only for brain abscesses but also for acute bacterial meningitis in immunocompetent pediatric patients. Empirical treatment for bacterial meningitis may be effective also in an infection caused by *S. intermedius*. Early recognition of etiologic agents may be significant for prevention of possible complications.

[1897] Acute cerebellitis with unknown etiology - case series

Authors: Agata Marszałek, Karolina Markusiewicz

Affiliation: Department of Pediatric Neurosurgery and Traumatology, Medical University of Warsaw

Trustee of the paper: Marta Zębala MD, PhD

Corresponding author: Agata Marszałek (agata19x@gmail.com)

Background

Acute cerebellitis (AC) is a rare neurological condition mainly diagnosed in children. Symptoms of AC are fever, headache, cerebellar signs, fatigue and altered mental status. Magnetic Resonance Imaging (MRI) shows the evidence of cerebellar inflammation. AC can be characterized by postinfectious and also postvaccination disorder.

Case report

Five-year old girl was admitted to the hospital with severe headache, stomachache, weakness and walking disturbances manifested by taking small steps. In MRI, dilatation of the ventricular system, abnormalities of cerebellum were observed and AC was suspected. Virological and bacteriological tests have failed to identify the etiological agent of the disease. However, parents reported MMR vaccination a month earlier. Due to the worsening of the neurological condition, a ventricular drainage was performed. Despite resolution of symptoms of the increased intracranial pressure and therapy with antibiotics, acyclovir and steroids, the cerebellar lesions showed progression. To exclude the neoplastic character of the lesions, a stereotactic biopsy was performed, which proved the inflammatory nature of the condition. Soon, regressions of the lesions and improvement in the patient's condition were observed.

In the same month 8-year old girls was admitted to the hospital with headache, vomiting, dizziness and fever. In the tomography widened ventricular system, cerebellar lesions indicating inflammatory processes was observed and consequently AC was diagnosed. The etiology of the disease could not be detected despite laboratory tests. Improvement of patient's condition was observed after antibiotic, steroid and acyclovir therapy.

Conclusions

AC is a serious condition that may require surgical intervention. Diagnosis of AC is challenging, especially when it is impossible to determine the etiologic factor and the MRI result is non-specific. In differential diagnosis we should include neoplastic process. Stereotactic biopsy may be used to confirm the diagnosis.

[1919] It's just a spot- neurofibromatosis type 1- a case report

Authors: Weronika Mielnik

Affiliation: Students' Scientific Society at the Department of Pediatric Radiology, Medical University of Lublin

Trustee of the paper: Magdalena Maria Woźniak

Corresponding author: Weronika Monika Mielnik (weronika.cyranka@gmail.com)

Background

14-month-old girl with type 1 neurofibromatosis diagnosed in a genetic test was admitted to the Department of Pediatric Hematology and Oncology. Physical examination revealed the presence of strabismus, numerous café au lait spots on the skin all over the body. Additionally, the baby had growth disorders and neurological symptoms: musing, myoclonus during sleep and breastfeeding.

Case report

Due to a genetic disease, the girl underwent a scheduled MRI of the head. The examination was performed with the Siemens Magnetom Aera 48 1.5T scanner before and after intravenous administration of a paramagnetic contrast agent. The examination revealed the presence of a 19 x 19 x 22 mm isointense tissue-fluid lesion presenting intense contrast enhancement. The lesion extended into the supraoptic recess of the third ventricle, the frontal lobes and the right hypothalamus. The right optic nerve was affected in intra- and extra- ocular part. The picture most likely corresponded to the optic chiasm glioma. Additionally, a thickening of the right optic nerve (up to 6mm) was observed.

Six months later, a control MRI of the head was performed on the girl using the same scanner and the same protocol. The examination showed a significant progression of the lesion. The tumor invaded the retrobulbar segment of the right optic nerve, the optic chiasm, the area of the right hypothalamus and the optic tract up to the level of the lateral geniculate body. The right optic nerve was thickened to 7.3mm. The described lesion filled the basal cisterns and the sphenoid bone in the area of the sella turcica. The pituitary infundibulum was displaced posteriorly. The lesion put pressure on the lower side of third ventricle.

Due to the infiltration of hypothalamus and optic tract, the neurosurgical team did not qualify the patient for surgery.

Conclusions

Among patients with type 1 neurofibromatosis there is an increased risk of developing tumors of the central nervous system. Surgical treatment remains the most common method of treatment so far. The quality and lifetime of patients depends on the time of diagnosis, therefore the most important is early diagnosis and monitoring of the course of the disease and its complications. Magnetic resonance imaging is the method of choice in the assessment of the central nervous system. Due to the high sensitivity and lack of exposure to X-rays, this test should be performed regularly in patients diagnosed with NF1.

[1924] **A rare case report of an Atypical Choroid Plexus Papilloma in a 3 month old girl**

Authors: Sruthi Arakkal Suresh Babu, Mira Odeessa Pereira

Affiliation: Department of Pediatric Neurosurgery and Traumatology, Medical University of Warsaw, Poland

Trustee of the paper: Dr n. med. Emilia Sołtan

Corresponding author: Sruthi Arakkal Suresh Babu (sruthisuresh1310@gmail.com)

Background

Atypical choroid plexus papilloma is a subtype of the choroid plexus tumors with an occurrence rate of 2-5% in the pediatric population. In the first year of life, although approximately accounting for 13% of all pediatric brain tumors, this type of tumor is considered very rare. Introduced and classified in 2007, as a WHO Grade II according to the WHO Grading of Tumors of the Central Nervous System. These neuroepithelial tumors are considered to have a higher recurrence rate alongside an increase in its mitotic activity as compared to choroid plexus papilloma.

Case report

We report a 3 month old patient who presented to our Emergency Department with hydrocephalus resulting in an enlargement of the head circumference by 7cm, alongside an upward gaze paresis. Imaging diagnostics revealed significant widening of the ventricular system, whereby the third chamber was 35 mm and the fourth chamber was 14 mm. The Evans index was stated as 0.66. As a result, a right frontoparietal craniotomy with rickham pouch placement in the left frontal horn was performed for the hydrocephalus. After stabilization of the condition, a Computer Tomography guided Biopsy was performed which showed a tumor exiting through the choroid fissure, in the anterior corner of right lateral ventricle from ceiling of third ventricle and visible within the opening of the right foramen Monro. Following this a right frontoparietal craniotomy was performed and a highly vascularized tumor was removed. Deterioration of the patient's condition occurred throughout the postoperative period due to hyponatremia with features of cerebral salt wasting syndrome, water intoxication symptoms, diabetes insipidus and seizures. The patient was then discharged two months later. In the follow-up visit 6 months later no recurrence of the tumor was observed, however the patient suffers from epilepsy controlled by anti-seizure medications.

Conclusions

Due to limited cases and data, the outcome is believed to be rather favorable with such tumors. The current mainstay choice of treatment is surgical resection, however, consensus in cases of recurrent tumors have not yet been established.

[1960] Recurrent otitis media as a contributor to the diagnosis of Turner syndrome - the importance of a comprehensive approach to the patient

Authors: Joanna Rapiejko, Anna Rapiejko

Affiliation: Students' Scientific Association, Department of Gynaecological Endocrinology, Medical University of Warsaw, Warsaw, Poland

Trustee of the paper: Monika Grymowicz MD, PhD

Corresponding author: Joanna Katarzyna Rapiejko (asia.rapiejko@gmail.com)

Background

Turner syndrome (TS) is a genetic disorder occurring in female patients, caused by the complete or partial absence of one of the X chromosomes. Patients with TS may present with short stature, gonadal dysgenesis, typical dysmorphic features that include a webbed neck, a low hairline at the back of the neck, widely spaced eyes, low-set ears, a broad chest and widely spaced nipples. These key features may be subtle, so not all affected individuals are diagnosed prenatally, at birth or at a very early age. In addition to the typical symptoms, Turner syndrome is associated with many other health problems.

Case report

A 17-year-old female patient with Turner syndrome is currently under the constant care of the Gynaecological Endocrinology Outpatient Clinic of the Clinical Hospital Anna Mazowiecka in Warsaw, undergoing hormone replacement therapy since the age of 16. She is menstruating regularly and is in good general condition. The typical dysmorphic features are very subtle. No heart or kidney defects have been diagnosed. The patient has been treated with growth hormone from age 6 to 16, current height is 156 cm. Scoliosis under the care of a physical therapist. The diagnosis of the syndrome was not made until the age of 4, when a karyotype, performed on the order of a paediatric endocrinologist in a fairly low-grade girl, confirmed the diagnosis of Turner syndrome (mosaic type). The child was referred for the above consultation by ENT specialists due to recurrent otitis media. The patient, previously considered a healthy child, began suffering from recurrent otitis media with effusion from the age of 2. She underwent numerous ear drains and a tonsillectomy, and required long-term ENT care.

Conclusions

Specialists, aware that girls with recurrent otitis media and relatively short stature may have an underlying diagnosis of Turner syndrome, can contribute to an earlier diagnosis of the condition. A comprehensive approach to the patient provides such opportunities. Early diagnosis of TS is important because affected individuals can suffer from a range of health problems and require early multidisciplinary care.

[1987] A rare case of cardiac thrombosis after chemotherapy

Authors: Aleksandra Kargul, Klaudia Baran, Daniel Balut

Affiliation: Students Scientific Club „Sferocyt” within Medical University of Warsaw’s Department of Oncology, Pediatric Hematology, Clinical Transplantology and Pediatrics

Trustee of the paper: Anna Szmydki-Baran, MD

Corresponding author: Aleksandra Kargul (aleksandra.k96@gmail.com)

Background

Acute lymphoblastic leukemia (ALL) is the most common type of cancer diagnosed among children. Venous thromboembolic complications (VTE) remain one of the most common therapy-associated adverse events in ALL. There is a variety of factors contributing to thrombosis risk in pediatric ALL, especially hyperleukocytosis. It is characterized by an extremely elevated blast cell count and symptoms of severe disseminated intravascular coagulation (DIC).

Case report

10 years old girl was admitted to department of pediatric oncohematology with the suspicion of hematopoietic proliferative disease. Laboratory tests performed on the day of admission showed hyperleukocytosis 547 700 with 97% lymphoblasts, RBC 2.07, PLT 60 000, Hb 5.7. Immunophenotype testing revealed T-cell acute lymphoblastic leukemia. Concomittant abnormality was DIC requiring multiple infusions of platelet concentrates and CPAG (concentrate of cold precipitated antihemophilic globuline). Treatment according to AIEOP BFM 2017 protocole was started with increasing doses of prednison. In 7th day of treatment WBC were below 100 000. Due to the pain in the chest reported by the patient ECHO (echocardiography) was performed and revealed a lesion with echogenicity similar to a heart muscle. Chest radiography and level of troponin were in normal range. With the suspicion of pulmonary embolism angioCT of chest was performed and showed no thrombi in pulmonary vessels. Then angioMRI of heart was performed and revealed 2 thrombi filling whole capacity of the right ventricle. Anticoagulation treatment with fraxiparine was started. Controled ECHO performed after 5 days of treatment showed enlargement of thrombi. In agreement with cardiologist and cardiourgeon thrombolytic treatment as an only option was started. After the uncomplicated infusion of tPA lasting 12 hours controled ECHO showed no thrombi in the right ventricle. Anticoagulation treatment with enoxaparine was continued for 3 months. After 2 weeks another HRCT was performed due to pulmonary infection. It revealed completed pulmonary thromboembolism in distal pulmonary arteries. Remission of T-ALL was confirmed on the 33th day of treatment.

Conclusions

We believe it’s an extremely interesting case due to size and location of thrombi and fact that only one infusion of tPA dissolved it. Leukemia with hyperleukocytosis especially from T-cells is an extremely high risk factor for developing DIC.

Surgical Case Report

Date: 22nd April 2023, 15:15 PM

Coordinators:
Jakub Rachoń
Karolina Zofia Kowalczyk

[1547] A cautionary tale – undetected H-type tracheoesophageal fistula in an adolescent male

Authors: Joanna Łysak

Affiliation: Medical University of Warsaw

Trustee of the paper: Marek Wolski MD

Corresponding author: Joanna Matylda Łysak (s077804@student.wum.edu.pl)

Background

The esophagus and the trachea are two separate hollow organs with varying functions that share a common embryological origin. A tracheoesophageal fistula (TEF), a common congenital abnormality, is a connection between the esophagus and the trachea. Congenital H-type tracheoesophageal fistula is a rare (3,8% of all TEF cases) type of congenital malformation, in which the esophagus is not obstructed. Early diagnosis of H-type TEF may be difficult, resulting in misdiagnosis.

Infants with H-type TEF may present with coughing, choking, salivation, vomiting, and cyanosis induced by the onset of feeding. The severity of these symptoms is variable among affected individuals.

The treatment is surgical, both open and thoracoscopic procedures are employed.

Case report

The patient is a 13-year old male with a history of congenital pneumonia and recurrent bronchitis.

The tracheoesophageal fistula was excluded previously, but the records of diagnostic tests performed were not provided.

The patient was admitted to the hospital with suspected interstitial lung disease. The patient complained of coughing, recurring respiratory infections, exercise-induced dyspnoea and wheezing.

CT scan performed in a different facility showed uneven tracheal silhouette, post-inflammatory nodules in the right lung and ground-glass opacity in the left lung.

Gastroscopy concluded that H-type tracheoesophageal fistula is present.

The patient returned to the hospital 4 months later to undergo surgical closing of the fistula.

Surgery

Thoracoscopic surgery was performed. Two 5 mm trocars and one 10 mm trocar were inserted. Region of the fistula was isolated by exposing the esophagus and trachea near the upper thoracic opening. The location of the fistula was confirmed by bronchoscopy. The fistula was dissected, suspended on a rubber band and closed using three clips. Air was suctioned from the thoracic cavity and the thoracic wall was closed.

The postoperative period was uneventful.

The follow-up visit was performed after 3 months.

Conclusions

This case is an important cautionary tale. Compared to other types of TEF, H-type tracheoesophageal fistula is easy to miss considering its indistinct clinical manifestation. Recurring pneumonia and respiratory tract infections in children, although usually not linked to such condition, should inspire doctors to consider H-type TEF in their diagnostic process.

[1572] Can distal radius fracture cause an immobilization?- A rare case of proximal femoral focal deficiency.

Authors: Edyta Dyngosz, Wojciech Bednarz

Affiliation: Students' Scientific Group of Orthopaedics and Traumatology, Jagiellonian University Medical College

Trustee of the paper: Jarosław Brudnicki, MD PhD

Corresponding author: Edyta Dyngosz (edyta.dyngosz@student.uj.edu.pl)

Background

Proximal femoral focal deficiency (PFFD) is non-hereditary birth defect which affects about 2 in every 100 000 children. Most patients with PFFD, especially with bilateral involvement, have associated anomalies. The most common is fibular hemimelia. PFFD is associated with a defect of primary ossification center, however casues of this condition are uncertain. It may vary in severity from child to child and can range from hipoplastic shortened femur to total absence of proximal two-thirds of femur. Therefore treatment must be individualized and ranges from amputation and prosthetic rehabilitation to limb elongation and hip reconstruction. The limb lengthening should be considered when hip joint is stable and predicted length is more than 50 % of contralateral limb.

Case report

39- year old male patient was admitted in the Orthopaedic Ward in the University Hospital in Cracow in order to reduction of distal radius fracture on the right side. Man suffered from proximal femoral focal deficiency. The deformity was categorized as type 4 according to Amstutz's classification. A right femur was significantly shortened. A connection of the shortened shaft with an acetabulum was deformed and degenerative. The man in the childhood was subjected to a few failed attempts at elongation of right femur. In due to the fact that patient used a wheelchair and crutches since childhood, it was crucial to provide fusion of bone as fast as possible to enable patient's mobilization. The distal radius fracture was clasified as a simple joint and simple methaphysis fracture on AO/OTA classification and qualified to internal fixation by Medartis plate. Surgery and post- surgery period passed without complication. The man was discharged on the day after operation with a recommendation to follow-up in two weeks in the orthopaedic clinic.

Conclusions

Despite the rarity of PFFD, there is still possibility to meet patient suffers from this disease in a medical practis. It is important to remember that their priorities can differ from usual ones. For patients with sever shortening of the femur ability to move is often connected with the function of the upper limbs. The man described in a case was Paralympian, so the chance of fast mobilization and return to training was particularly important. For majority of patients with distal radius fracture conservative treatment is sufficient, however, surgical treatment allows of quick bone fusion and return of function what can be an exellent option for these patients.

[1636] Surgical management of pelvic Ewing's sarcoma: a case report

Authors: Justė Ramonaitė, Tomas Rašinskis, Vėtra Markevičiūtė, Mindaugas Stravinskas

Affiliation: Faculty of Medicine, Lithuanian University of Health Sciences, Kaunas, Lithuania

Trustee of the paper: Vėtra Markevičiūtė

Corresponding author: Justė Ramonaitė

Background

Ewing sarcoma is a rare type of malignancy that occurs in bones or in the soft tissue around the bones. It can also metastasize to other areas of the body, including the bone marrow, lungs, kidneys. While Ewing's sarcoma can occur at any time during childhood, it most commonly develops during puberty. The pelvis is one of the primary sites of Ewing sarcoma and is associated with poorer prognoses than the extremities. Due to the rarity of this disease, the prognostic factors of pelvic Ewing's sarcoma remain controversial.

Case Report

In July 2021, 20 year-old woman was referred to our hospital due to severe left hip pain, which she complained for about half a year. The patient was consulted by an orthopedic oncologist due to a suspicion for a malignant tumor. In August 2021, MRI of lumbar spine and pelvis showed that a mass occupied left side of sacrum and hip bone, was spread to the sacral canal and soft tissues. In September 2021, pulmonary CT showed three solitary masses. Also, whole body PET showed moderately metabolic left pelvis tumor and metabolic inactive neoplastic changes in the lungs. A biopsy was performed, and the patient was diagnosed with Ewing sarcoma, G4. Chemotherapy was initiated by the Euro Ewing 2012 protocol. In March 2022, PET scan was repeated to evaluate the dynamics: a tumor in pelvis area was significantly decreased but metabolic activity was still observed. In May 2022, surgery was performed - a partial resection of the iliac wing and a posterior sacral laminectomy was performed. Resection edges were clear. Operating together with neurosurgeons, osteosynthesis was performed using the SOLAR system. Iliac wing and vertebral bodies were fixed by screws and mutually reinforced with rods. Iliac bone defect was corrected by using two fibular allografts. Histological examination confirmed the pre-operative clinical diagnosis – Ewing sarcoma pT2N0M1 G4 IVB. Necrosis > 99%. Postoperative radiation therapy was started after surgery, followed by a bone marrow transplant. At present, treatment of the patient is complete and there is no evidence to suspect relapse and metastasis. The functional results are great and follow-up and follow-up of the patient is applied every 3 months.

Conclusions

This case report demonstrates that early diagnosis, precise planning of the treatment, timing of the surgery and postoperative management leads to better outcomes of late stages of Ewing sarcoma.

[1658] Intercostal nerve cryoanalgesia in the treatment of pain after the Nuss procedure : a case report.

Authors: Aleksandra Wochna

Affiliation: Studenckie Koło Naukowe przy Oddziale Klinicznym Chirurgii i Urologii Dziecięcej, Wydział Lekarski, Uniwersytet Warmińsko-Mazurski w Olsztynie

Trustee of the paper: dr n. med. Michał Puliński

Corresponding author: Aleksandra Wochna (ola.wochna@gmail.com)

Background

Pectus excavatum is the most common congenital chest wall defect in which the sternum is depressed posteriorly. It occurs in one in a thousand children, usually with male predominance. Patients with the defect may present with complaints of chest wall discomfort, exercise intolerance, and tachycardia. Correction of the defect is currently performed using a very little invasive operation known as a Nuss technique. However, the Nuss surgery is often associated with prolonged hospital stay and severe postoperative pain requiring strong analgesic treatment, including the use of strong opioids or epidural anaesthesia. To reduce pain, the intraoperative cryolysis of the intercostal nerves around the incision can be performed to essentially reduce this postoperative analgesic requirement.

Case report

A 15-year-old boy with pectus excavatum (haller index 3,3) was admitted to the hospital for thoracoplasty of the anterior chest wall using the Nuss procedure. In order to push the chest into a normal position, two curved metal bars were inserted behind the sternum. After the elevation of the sternum, cryolysis of the intercostal nerves was performed. Postoperative pain management included paracetamol, metamizole, and a single dose of nalbuphine, without the use of an epidural. On the Numerical Rating Scale, the patient rated postoperative pain at 3,3 on average. On the third day after the operation, the patient was discharged home with the recommendation to use paracetamol or tramadol in case of pain.

Conclusions

Intraoperative intercostal nerves cryolysis performed during the minimally invasive Nuss correction of funnel deformation is more effective in terms of acute pain management in relation to the routinely used multimodal analgesia, allowing for the shortening of the time of opioid use and hospitalisation time.

[1680] “Primary pulmonary invasive mucinous adenocarcinoma presenting as a giant mediastinal tumor with cardiac compression”

Authors: Alicja Kamińska, Natalia Kwiatkowska

Affiliation: Department of Thoracic Surgery, Poznan University of Medical Sciences, Poznan, Poland

Trustee of the paper: Magdalena Sielewicz, MD; Mariusz Kasprzyk, MD PhD

Corresponding author: Alicja Kamińska (alicjaaleksandrakaminska@gmail.com)

Background

Background

Invasive mucinous adenocarcinoma (IMA) represents only 2-5% of lung adenocarcinomas [1]. IMA typically presents in the sixth decade of life with equal representation in both sexes. It bears distinct clinicopathological, molecular, and radiological characteristics and an unclear prognosis [2]. Here we present a patient with giant invasive mucinous adenocarcinoma of the lung compressing the heart and great vessels.

Case report

Case Report

A 64-year-old male was referred to the Department of Thoracic Surgery to treat a large tumor filling the posterior mediastinum. His medical history revealed arterial hypertension, atrial fibrillation, transient ischaemic attack, and previous chemotherapy treatment due to lymphoma. The patient presented with dyspnea requiring oxygen therapy, cough, vomiting, and chest pain. Chest Computed tomography (CT) showed a posterior mediastinal mass compressing heart, aorta, pulmonary trunk, and both lungs. Due to the severe manifestation and the lack of other treatment options, the patient was qualified for urgent surgery. A tumor with 17,5 x 16,0 x 18,0 cm dimensions was resected via a right posterolateral thoracotomy. Additionally, a right lower lobectomy was performed due to extended compression resulting in cirrhosis of lung tissue. The final histopathological examination reported the invasive mucinous adenocarcinoma.

Conclusions

Summary

IMAs are usually asymptomatic in the early stage. However, large tumors can cause symptoms like cough, chest pain, chest tightness, and dyspnea due to the compression of surrounding tissues [3]. Since the nonspecific presentation, it is crucial to consider them in the differential diagnosis. Surgical resection and postoperative chemotherapy remain the preferred treatment option for IMA patients [4].

[1720] Breast implant protrusion and prosthesis salvage after primary breast augmentation

Authors: Emilija Dedelytė

Affiliation: Lithuanian University of Health Sciences

Trustee of the paper: Dr. Domantas Rainys

Corresponding author: Emilija Dedelytė (dedelyte.emilija@gmail.com)

Background

Breast implants are one of the most popular types of plastic surgery prostheses. Periprosthetic infection is one of the major complications that often results in implant loss. It is much more common in patients after breast reconstruction compared to patients after primary breast augmentation with implants. There is still a debate regarding the clinical management of periprosthetic breast infection. This case report presents successful salvage of breast prosthesis.

Case report

A 29-year old woman presented with 3x2mm size lesion of postoperative scar. Further inspection revealed that the wound was deep, went through all the layers of the breast and prosthetic implant was visible in the wound bed. There were no other clinical signs of infection except for wound dehiscence, granulation tissue in the subcutaneous layer and swelling. Medical history revealed that patient had undergone breast augmentation with silicone gel prosthesis 6 weeks ago, postoperative period was uneventful until the incidence. The patient informed that the previous week she was on holiday, was using sauna and swimming in a lake, subsequently she noticed a wound on the left breast and copious yellow exudate. An infection of the implant was suspected, and revision surgery was advised. The revision surgery under general anaesthesia was done the following day after examining the patient. A prophylactic dose of cefuroxime was given. The postoperative scar with inflamed surrounding tissue was excised and the implant was removed. Prosthesis was mechanically cleaned and immersed in 0.9 percent NaCl solution, 1g of cefazolin, 80mg of gentamicin, 1g of clindamycin and 50% Betadine solution, the exposure time was 30 minutes. The implant socket was revised, there was no purulent exudate, thus the decision to save the implant was made. The pocket was irrigated with the same solution as the implant, a vacuum drain was inserted. The prosthesis was reimplanted, and the wound was closed. After the surgery patient was treated with 7-day antibiotic therapy of cefuroxime and metronidazole. The wound bacterial culture came back negative. Postoperative recovery was uneventful.

Conclusions

The described case report showcases 1-stage periprosthetic infection management and implant salvage using rigorous implant and breast pocket cleaning along with antibiotic therapy. The method used in this case can yield positive results and allow salvage of the implant when non-severe implant infection occurs early after breast augmentation.

[1728] EndoVAC dressings for a scro-rectal fistula resulting from Fournier's gangrene - case report

Authors: Adrianna Pielech, Marta Domagalska, Jakub Migoń, Michał Bąk

Affiliation: University of Zielona Góra; General and Oncological Surgery Department, Clinical Hospital in the name of Karol Marcinkowski, Zielona Góra

Trustee of the paper: Michał Bąk

Corresponding author: Adrianna Pielech (adrianna.pielech@gmail.com)

Background

Extensive crush trauma create treatment difficulties due to injuries to many organs, their complications and therapeutic possibilities. The presented clinical case is an example of endoVAC dressings for a scro-rectal fistula resulting from Fournier's gangrene.

Case report

A 45-year-old patient, after an accident at work, with multiple fractures of the pelvis, urethral trauma and pneumothorax. Initially hospitalized in the orthopedic ward in order to supply the pelvic fractures, caused by crushing, with an external fixator. Due to post-traumatic urethral tear, cystofix was placed. In the following days of hospitalization, an extensive scrotal hematoma developed, which led to infection and Fournier's gangrene - the patient required urgent urological intervention. A surgical consultation was requested and a rectoscrotal fistula was found. A double-barrel colostomy was performed to avoid fecal infiltration into the fistula. Postoperatively, the symptoms of septic shock occurred in the ICU, and the following strains were obtained from wound cultures: GRE, ESBL and HLGR. Due to the patient's serious condition and high risk of pneumothorax recurrence, he was not qualified for treatment in the hyperbaric chamber. It was decided to use broad-spectrum antibiotic therapy and use an EndoVAC dressing. During the therapy, another fistula opening was noticed on the medial side of the right thigh, which was also treated with EndoVAC. Later on, the fistula was gradually closed, confirmed by endoscopy, and the wounds in the abdominal cavity and thigh healed. During stay in the ICU, a bedsore appeared on the sacrum, which was treated with a VAC dressing after demarcation. In the following days, the patient was admitted to the surgery department, where he was treated further. Patient initially uncooperative, with symptoms of depression, consulted psychiatrically during hospitalization. Further improvements in wound healing were obtained. Rehabilitation was started in terms of the possibilities of the stabilizer. On the 96th day of stay, he was discharged home with a healed fistula on the thigh, with a closed rectoscrotal fistula and a bedsore on the sacrum supplied with specialist dressings. He is currently undergoing rehabilitation in the day ward.

Conclusions

EndoVAC dressings can be used in the treatment of extensive, complicated wounds, including fistulas. They are a good method in cases of patients who cannot be qualified for treatment in a hyperbaric chamber.

[1762] Septic loosening of endoprosthesis with rare fungal etiology: A Case Report

Authors: Flynn Ott

Affiliation: Chair and Department of Medical Microbiology

Trustee of the paper: Robert Kuthan PhD

Corresponding author: Flynn Ott (s087100@student.wum.edu.pl)

Background

Aspergillus clavatus is a species of the genus *Aspergillus* commonly found in soil and animal feces. It is classified as an opportunistic pathogen, capable of causing infections in individuals with compromised immune systems. While infections caused by *A. clavatus* are rare, compared to the more prevalent *Aspergillus fumigatus* or *Aspergillus flavus*, the incidence of *Aspergillus* infection in endoprosthetic infections is less than 1%. This case report documents a rare pathogenic presentation of *Aspergillus* infection involving an endoprosthesis, caused by *A. clavatus*, which typically carries a poor prognosis and poses significant challenges in clinical management.

Case report

A 74-year-old female patient presented to an orthopedic hospital with left knee pain. During the patient interview, she reported experiencing pain in the left knee for the past two months. The patient's medical history revealed a previous left knee alloplasty with an endoprosthesis, and bilateral gonarthrosis. A septic loosening of the left knee joint endoprosthesis was diagnosed, leading to a surgical revision of the left knee joint, including removal of the loose endoprosthesis, joint debridement, pulse lavage, and implantation of an antibiotic spacer. Bacteriological tests were performed on samples taken from five different locations, all of which returned positive for *Staphylococcus lugdunensis*. The patient was administered conservative treatment, which included thromboprophylaxis, intravenous antibiotic therapy, and painkillers. Additionally, mycological tests were performed, which revealed positive results for both *A. fumigatus* and *A. clavatus*. The positive *A. fumigatus* result was likely due to site contamination, while *A. clavatus* was identified as a causative agent of septic loosening of the endoprosthesis. The patient made a complete postoperative recovery without any complications.

Conclusions

A. clavatus infections are frequently misdiagnosed and misclassified as *A. flavus* or *A. fumigatus* due to the lower frequency of environmental isolation compared to other *Aspergillus* species. The relative rarity of *A. clavatus* infection may be explained by its lower virulence compared to other members of the genus. Consequently, prompt and accurate diagnosis, along with appropriate treatment, are critical to achieving optimal clinical outcomes, despite the infrequent occurrence of *A. clavatus* infections.

[1768] Osteoarthritis of the CMC I joint - treatment with a novel endoprosthesis, a case report

Authors: Mikołaj Lewandowski, Jędrzej Jabłoński

Affiliation: Student Research Group of Hand Surgery, Poznań University of Medical Sciences

Trustee of the paper: Michał Górecki MD

Corresponding author: Mikołaj Lewandowski (lewymikus99@gmail.com)

Background

The carpometacarpal joint of the thumb is a saddle joint with a unique anatomical architecture that allows a wide range of movement. Osteoarthritis in this joint is the second most common location in the hand, affecting more often women. Symptoms of this condition include resting pain, increasing with thumb movement and global and pinpoint grasping, weakness in hand strength and palpation soreness at the CMC I joint projection. The primary additional examination is X-ray and, to a lesser extent, ultrasound. The radiological picture is characterized by joint stenosis, subchondral sclerotisation, osteophytes and subluxation of the joint. Depending on the degree of destruction of the joint, a decision is made on non-operative treatment consisting of improvement and physical therapy, temporary use of NSAIDs, delivery steroid injections, fitting of orthosis, or surgical treatment using one of the techniques: trapeziectomy, arthrodesis or endoprosthesis.

Case report

48-year-old female patient was admitted to the Department of Hand Surgery on an elective basis due to pain and limitation of thumb movement in the course of advanced degenerative changes. The symptoms have persisted for 5 years. The patient reports partial improvement after conservative treatment - improvement with physiotherapy, steroid injections 2x/year. The gradual exacerbation of symptoms makes it difficult to grasp objects and also prevents the performance of basic activities of daily life.

X-rays confirmed advanced degenerative changes with bone destruction, as well as subluxation in the CMC I joint. After clinical and functional analysis, an endoprosthesis was proposed. The technique was applied through dorsal-radial access. After the operation, the patient immobilized in an orthosis for a period of 3 weeks. Improvement of motor functions was recommended. Currently, the patient performs full range of motion - opposition to the base of the little finger, reports periodic meteosomatic pain, sensation on the finger is normal.

Conclusions

Endoprosthesis when degenerative changes are advanced in the CMC I joint is a technically demanding procedure. It is believed that appropriate patient selection and surgical experience are fundamental to achieving optimal results and reducing complications. Trapeziectomy is still the gold standard of treatment. However, endoprosthesis is being used more and more often due to patient's faster return to daily activities, significant improvement in function and grip strength.

[1785] Septic Bursitis Caused by *Exophiala dermatitidis*: A Rare Invasive Fungal Infection Requiring Surgical Intervention

Authors: Abdulla Hourani, Natalia Ekielska

Affiliation: Chair and Department of Microbiology, Medical University of Warsaw, Poland

Trustee of the paper: Robert Kuthan, Gabriel Zaremba

Corresponding author: Abdulla Hourani (hourani03@gmail.com)

Background

Exophiala dermatitidis, a dimorphic melanized opportunistic yeast belonging to the phylum Ascomycotina, is a rare cause of invasive fungal infections. However, infections tend to be long-lasting and often require aggressive treatment. This report describes a case of septic bursitis in the elbow joint caused by *E. dermatitidis*.

Case report

A 70-year-old male patient with a history of Diabetes Mellitus 1 and a previous kidney transplant in 2010 was admitted to the Immunology and Transplantology Clinic in the context of painful swelling of the right elbow.

A mobile nodular lesion was detected during physical examination, and ultrasound imaging revealed a well-defined, solitary nodule adhering to the bursa, along with signs of chronic olecranon bursal inflammation. No malignant signs were found on the biopsy, and *E. dermatitidis* was isolated from a subsequent culture, with a determined susceptibility to Fluconazole, Voriconazole, and Itraconazole. To rule out contamination, another culture was obtained, which also yielded *E. dermatitidis* growth.

Treatment with Voriconazole was initiated, and a day later, the bursal nodule was surgically excised without any complications. Three days after the surgery, there were no signs of inflammation in the elbow, and the patient was then discharged from the hospital with a recommendation to continue using Voriconazole at home for two more weeks.

Conclusions

This case report emphasizes the significance of early detection and prompt management of invasive fungal infections caused by rare organisms like *E. dermatitidis*, as the incidence of such cases is increasing in both immunocompromised and immunocompetent patients.

[1828] **An anterior diaphragmatic hernia incidentally found during the coronary artery bypass graft surgery.**

Authors: Kamil Krauz

Affiliation: Department of Cardiac Surgery, Medical University of Warsaw

Trustee of the paper: Radosław Wilimski

Corresponding author: Kamil Krauz (kamilkrauz007@gmail.com)

Background

Diaphragmatic hernias can be described as translocations of abdominal organs or omental fat to the thoracic cavity through a diaphragm defect. Depending on the cause, they can be divided into congenital and acquired. Congenital hernias are typically found in neonates and infants. They approximately occur with the frequency of 2,5 cases per 10 000 births. Anterior diaphragmatic hernias (Morgagni hernias) account for only 2-4% of them. The presence of such abnormalities might produce pulmonary, gastrointestinal and cardiac symptoms but it can also be asymptomatic.

Case report

A 64-year-old male presenting with ventricular tachycardia was admitted to the hospital and successfully treated with electrical cardioversion. He underwent emergency coronary angiography that revealed chronic occlusion of the right coronary artery and circumflex branch of the left coronary artery, subtotal occlusion of the left anterior descending (LAD) artery and significant stenosis of the intermediate (IM) branch of the left coronary artery. The echocardiogram showed moderate impairment of left ventricle contractility with ejection fraction 39%. His cardiovascular and operative risk factors were type 2 diabetes, atherosclerotic peripheral arterial disease of lower extremities, pulmonary emphysema (a long-time smoker) and arterial hypertension. The patient underwent emergency, off-pump, beating heart bypass surgery through a median sternotomy. The right internal thoracic artery (RIMA) was anastomosed to the LAD and the left internal thoracic artery to the IM. The RIMA harvesting technique and the beating heart off-pump coronary grafting performed on the lateral wall of the heart required opening of the right pleural cavity. A right anterior diaphragmatic hernia was incidentally found during the operation. Before surgery, the patient didn't report any complaints which could suggest the presence of the hernia and only the chest X-ray showed a shadowing in the right cardiophrenic angle. The hernia neck was incised, adhesions within the sac were divided to allow the contents (transverse colon with omentum) to be reduced and the sac was excised. The diaphragmatic defect was closed with interrupted 2-0 nylon sutures. The patient recovered uneventfully and was discharged home from the hospital.

Conclusions

Morgagni hernias are rarely found in adult patients undergoing cardiac surgery, but the presence of such a condition usually requires repair of the diaphragmatic defect simultaneous to the heart operation.

[1831] From Palliation to cure. Pressed IntraPeritoneal Aerosol Chemotherapy as a method for peritoneal carcinomatosis in colorectal cancer.

Authors: Dominika Hanusek

Affiliation: Collegium Medicum University of Warmia and Masuria

Trustee of the paper: Centre Hospitalier Lyon Sud

Corresponding author: Dominika Aleksandra Hanusek (hanusekdominika@gmail.com)

Background

PIPAC (Pressured IntraPeritoneal Aerosol Chemotherapy) is a recent approach for delivering intraperitoneal chemotherapy in the treatment of unresectable peritoneal metastasis (PM) of digestive cancers. This treatment is advocated for patients who aren't candidates for curative cytoreductive surgery (CRS), without clinical or morphological responses or who present intolerance for systematic treatment. This procedure is considered as a palliative intent and aims to prevent diffusion of PM.

Case report

A 52-year-old woman presented abdominal pain and a positive faecal occult blood test with a CT scan which detected a lesion of the caecum. Colonoscopy with biopsies confirmed the diagnosis of a slightly differentiated adenocarcinoma with mucus-secreting cells. Carcinoembryonic antigen (CEA) was 9,4 ng/ml. A right hemicolectomy was performed. PM was observed in the pelvis. Histopathological specimen was classed as pT4 N1 M1 without mutation in K-Ras and BRAF genes and with microsatellite stability phenotype. A postoperative chemotherapy composed of 5FU, irinotecan, oxaliplatin and bevacizumab was introduced. Because of side effects, bevacizumab was replaced by cetuximab after 4 courses. A exploratory laparoscopy revealed PM with a Peritoneal Cancer Index (PCI) of 13/39. PM was assessed to be unresectable because of extensive lesions of small intestine. After discussion, a treatment with PIPAC was adopted. This patient underwent 3 PIPAC procedures with oxaliplatin 92mg/m² in 150 ml NaCl 0.9% during laparoscopy every 6 weeks. Follow-up biopsies objectives fibrosis of tumour cells. After 3rd PIPAC, PCI decreased to 9/39 with disappearance of small bowel lesions. Complete cytoreduction with HIPEC (Hyperthermic Intraperitoneal Chemotherapy) was performed and limited resections as pelvic peritonectomy, total hysterectomy, omentectomy, peritonectomy, cholecystectomy, parietal resections and omphalectomy.

Conclusions

In Literature, 14% of patients with initial unresectable PM who underwent consecutive PIPAC procedures become eligible to curative CRS+HIPEC, with gastric cancers, colorectal, ovarian PM and peritoneal mesothelioma. Systemic chemotherapy must be associated. PIPAC is a safe procedure when performed in expert centres. Some authors described an increased overall survival with adjunction of PIPAC procedures compared to systemic chemotherapy alone. This case demonstrates that PIPAC may have a role in secondary curative treatment in PM of digestive cancers

[1832] First laparoscopic Whipple surgery In Latvia

Authors: Valērija Garaščenko Daniela Vāvere Sergejs Šapovalovs Sintija Lapsa

Affiliation: University of Latvia Faculty of Medicine

Trustee of the paper: Dr. Med Sergejs Šapovalovs

Corresponding author: Valērija Garaščenko (valeerijag@gmail.com)

Background

Pancreatic cancer is the fourth leading cause of cancer deaths globally, with a 5-year survival rate of only 12%. The standard treatment for removing pancreatic lesions from the pancreatic head is the Whipple procedure - pancreaticoduodenectomy. This complex and high-risk procedure has nowadays gained popularity over by laparoscopic pancreatic resection in recent years due to its benefits such as lower surgical complications, shorter hospital stays, improved appearance, and cost-effectiveness.

Case report

A 71-year-old female was first seen at the outpatient department with progressive mechanical jaundice and elevated tumour markers CA 19-9. At first, the patient underwent endoscopic retrograde cholangiopancreatography with stent placement, where narrowing of the common bile duct was diagnosed. As the patient is still experiencing symptoms of mechanical jaundice caused by a tumour of the pancreatic head and elevated tumour markers, an elective surgical procedure is scheduled two weeks later. The patient's ECOG score was 1 and the surgery was performed under general anaesthesia and took 10 hours. The postoperative period was uneventful. Blood sugar levels were monitored in case of the development of pancreatogenic diabetes. Altogether, the patient was stationed for seven days, of whom five were post-surgery, and the patient did not experience any complications. Following the surgery, the patient continues her treatment with adjuvant chemotherapy.

Conclusions

In the included studies that based their learning curve analysis on a statistical calculation, the number of procedures to surpass the first phase of the surgeon's learning curve was 30 for open pancreaticoduodenectomy and 39 for laparoscopic procedure. This case report suggests that although performed for the first time, the laparoscopic Whipple procedure shows good results with satisfactory patient recovery. To conclude, we would like to accentuate that this patient was carefully chosen as the first patient to undergo this procedure as the width of the common bile duct and the duct of Wirsung was wide enough, and the pancreatic structure was appropriate for a technically easier biliodigestive and pancreaticojejunal anastomosis. It is also important to emphasize that the risks and benefits of this procedure should be weighed out for each patient individually.

[1876] Rare tumor of the extrahepatic biliary tract

Authors: Kamila Kamińska¹, Krzysztof Dudek², Mateusz Bartkowiak²

Affiliation: Department of General, Transplant, and Liver Surgery, Medical University of Warsaw, 02-097 Warsaw, Poland

Trustee of the paper: dr hab. n. med. Krzysztof Dudek

Corresponding author: Kamila Joanna Kamińska (klamcia2@gmail.com)

Background

Carcinoma of the extrahepatic biliary tract occurs in less than 5% of all cancers of all primary neuroendocrine tumors. Primary neuroendocrine tumors of the extrahepatic bile duct (EBNET) are extremely rare and account for only up to 2% of all primary neuroendocrine tumors. In the literature only less than 200 cases of EBNET have been reported since 1959. The definite diagnosis relies on postoperative histopathological examination which utilizes immunohistochemical biomarker assessment including chromogranin A and synaptophysin. A surgical resection of the lesion in a case without presence of the metastasis, is the main treatment. Further therapy such as chemotherapy depends not only on the presence of metastases, but also on the degree of malignancy.

Case report

A 56-year-old man had been admitted to the Department of General Transplant and Liver Surgery of the Medical University of Warsaw, due to a not specified tumor of the extrahepatic bile duct diagnosed in radiological examination. The resection of the extrahepatic bile ducts, cholecystectomy and lymphadenectomy of the hepatoduodenal ligament with Roux-en-Y choledochojejunostomy was performed. Histopathological examination resulted in diagnosis of neuroendocrine tumor of common bile duct with specific immunohistochemical pattern (Caudal Type Homeobox 2 CDX2, Chromogranin, Synaptophysin). The postoperative period had been without any complications, the patient was discharged from the hospital on postoperative day 6. Three months after the primary operation, a positron emission tomography/ computed tomography scan (PET/CT) with 18FDG and whole body scintigraphy with somatostatin analogues was performed. No metastatic lesions were observed. On six-month follow-up patient was in good clinical condition, with no recurrence of the disease.

Conclusions

The case presents an atypical localisation for a neuroendocrine tumor. Due to its rarity, a diagnosis of EBNET in preoperative radiological examination is truly difficult. A complete surgical resection of the lesion is a standard of care in management of EBNET. Diagnosis of tumor can be obtained only by extended histopathological and immunohistochemical examination.

[1893] A case report of a rare abdominal wall desmoid tumor

Authors: Giedrius Šulskus

Affiliation: Lithuanian University of Health Sciences, Academy of Medicine, Faculty of Medicine

Trustee of the paper: Linas Martinaitis, MD

Corresponding author: Giedrius Šulskus (Giedrius.sulskus@gmail.com)

Background

Desmoid tumors also called aggressive fibromatosis are locally aggressive mesenchymal tumors with no known potential for metastasis or dedifferentiation. Desmoid tumors are rare and account for approximately 0.03 percent of all neoplasms and fewer than 3 percent of all soft tissue tumors. The estimated incidence in the general population is two to four per million population per year. Despite being histologically benign, they are locally infiltrative and, uncommonly, can cause death through the destruction of adjacent vital structures and organs. The standard treatment of aggressive fibromatosis is surgery.

Case report

A 74-year-old woman was admitted to a regional hospital with an enlarging painful abdominal mass above the navel. The patient presented with a history of a painful and red abdominal mass for 4 months. There was no reporting of any associated gastrointestinal symptoms during the medical examination. Abdominal computed tomography showed 4.2 x 7.4 cm oval, well-defined solid soft tissue mass between rectus abdominis muscle and preperitoneal layer. The abdominal mass was neither fixed to other organs nor showed signs of malignancy. After thorough evaluation of CT scan, laparoscopic surgery was chosen. During the operation, the tumor was excised with clean margins, along with the part of rectus abdominis muscle and posterior fascia layer. The patient was discharged on the third day after surgery; the postoperative period was uneventful. Histopathological analysis of the excised mass revealed the diagnosis of a desmoid tumor. Two years after surgery, there is no evidence of a recurrence in an abdominal MRT scan.

Conclusions

Desmoid tumor is a very rare and benign entity, however it can still be debilitating and make a huge influence on a person's quality of life due to pain, disfiguration, and a decrease of motion. Moreover, desmoid tumors often recur at or near the original tumor site after surgery. This clinical case underlines the importance of thorough diagnostics, careful planning and execution of the most appropriate surgical approach for the removal of a desmoid tumor. Consistent follow-up is essential to ensure that the tumor does not recur.

[1900] The case report of a cutaneous squamous cell carcinoma inside a chronically non-healing wound

Authors: Maria Kleczkowska

Affiliation: Students' Scientific Group of Multidisciplinary Oncology 'Onkosfera', Department of Soft Tissue/Bone Sarcoma and Melanoma, Maria Skłodowska-Curie National Research Institute of Oncology in Warsaw

Trustee of the paper: Professor Anna Czarnecka

Corresponding author: Maria Magdalena Kleczkowska (marysia.kleczkowska1@wp.pl)

Background

Cutaneous squamous cell carcinoma (SCC) is a neoplasm arising from the keratinising cells of the spinous layer of the epidermis, classified as non-melanocytic skin cancers. They account for about 15-20% of all skin cancers. SCC is caused by abnormal multiplication of keratinocytes, mainly under the influence of UV radiation, but there are also other causes, such as chronic skin irritation and long-lasting wounds. Wound healing is particularly difficult in diabetes, which damages vessels and impairs tissue perfusion.

Case report

A 61 years old man reported after a traffic accident 25 years ago with an ulcerated wound, chronically non-healing, on the lower part of the left crus, measuring 12cm by 12 cm. On admission, the wound had signs of necrosis, infection, and inflammatory infiltration. The patient's comorbidities include COPD, DM II, and hypertension. Histopathological examination showed it to be a SCC in the wound. Computed tomography revealed carcinogenic infiltration of the fascia and muscles as well as destruction of the tibia. Due to the stage of the disease, radiotherapy was rejected and the patient was offered an amputation of the limb, but he did not consent to the given decision. Finally, it was decided to treat him with anti-PD-1 drug - cemiplimab. The patient received 10 infusions of 350 mg of cemiplimab immunotherapy. Due to the significant risk of sepsis, a decision was made to amputate the leg in the thigh, but the patient did not consent to it and also did not contact for further infusions of immunotherapy.

Conclusions

While establishing the treatment for the patient, it is important to consider the present concomitant diseases as well as to predict the future possible development of the condition. Despite the establishment of the best possible treatment, sometimes therapy must be limited to the administration of systemic medication due to the patient's lack of consent to the other offered method of treatment. It also must be taken into account, that the final decision on whether to continue the given therapy rests with the patient.

[1933] A case of recurrent anemia of unknown origin - diagnostic and treatment difficulties

Authors: Jerzy Krzeszowiak, Wiktoria Szykiewicz

Affiliation: SSG at the 1st Chair of General, Oncological, Gastrointestinal Surgery and Transplantology of Jagiellonian University Medical College

Trustee of the paper: dr hab. Jakub Kenig, Prof UJ

Corresponding author: Jerzy Krzeszowiak (jerzykrzeszowiak@docs.name)

Background

There are various causes of anemia such as defects of erythropoiesis or blood loss, caused by bleeding or hemolysis. Anemia may often be asymptomatic or compensated by the patient's organism. However, anemia might also be life-threatening condition. Persistent blood loss leads to the development of iron deficiency anemia. It is estimated to occur in 10% of western population. Bleeding from the gastrointestinal tract is the second leading cause of that condition.

Case report

This is a case of a 32-years old women admitted to ER due to severe weakness, with emesis and tarry stools. In physical examination pain in the right part of the abdomen at palpation and tachycardia were found. No other abnormalities were examined. Patient is treated due to anemia and paranoid schizophrenia. In 2016 patient was operated because of the suspicion of the bleeding from Meckel's Diverticulum. Diverticulum was resected. Despite resection, anemia was still reoccurring. During last 6 months, the patient was hospitalized four times because of life-threatening anemia. The enhanced endoscopic and radiological examinations was conducted. Serology tests for coeliac disease and Crohn's disease were negative. In 2021 the patient was hospitalized due to anemia. Endoscopic and histopathological tests were provided, but they did not confirm the suspicion of Crohn's disease and they did not identify source of bleeding. For months ago in capsule endoscopy, multiple angiodysplasia of the small intestine was revealed. The patient was qualified for elective surgical treatment, but, due to intensive overall deterioration she was admitted to ER immediately. Laboratory results indicated: HBG 4,9g/dl, RBC $2,42 \times 10^6/\mu\text{L}$, HCT 16,7%. Laparotomy with intraoperative enteroscopy was performed. Based on the enteroscopy, 30 cm of the small intestine, distally to the Treitz ligament was resected. Patient's condition has improved postoperatively. Laboratory results have increased, reaching: HBG 10,0g/dl, RBC $4,04 \times 10^6/\mu\text{L}$, HCT 31,7% on the 4th day postoperatively. The patient awaits for the histopathological examination results.

Conclusions

This case shows that many times even extended and profound diagnostics may not reveal the source of bleeding and the cause of anemia. Further extended diagnostics and surgical intervention was required. Due to the localization and difficult endoscopic access, despite implemented treatment and initial postoperative improvement, there is no certainty that the anemia will not reoccur.

[1954] **An unusual combined liver-pancreas transplantation as a treatment for young woman with cystic fibrosis**

Authors: Paulina Kalman, Damian Zienkiewicz

Affiliation: Student's Scientific Organisation of General and Transplant Surgery „Kindley”, Department of General and Transplant Surgery, Medical University of Warsaw

Trustee of the paper: Prof. Wojciech Lisik MD, PhD

Corresponding author: Paulina Kalman (paulina.kalman@wp.pl)

Background

Cystic fibrosis (CF) is an inherited disease with a defect in epithelial chloride transport that results in multi-system disease. Most patients develop pulmonary insufficiency. However, improved survival in patients with CF has led to an increased incidence of extrapulmonary complications of this disease, including liver cirrhosis and pancreatic insufficiency. Combined liver-pancreas transplantation has become a promising therapy for CF patients with end-stage organ failure.

Case report

21-year-old woman diagnosed with CF developed cirrhosis, exocrine pancreatic insufficiency and insulin-dependent diabetes mellitus. The respiratory symptoms were moderate and well-treated. The patient was endangered mainly by liver insufficiency and recurrent hypoglycemia, which was due to the treatment of diabetes with high doses of insulin. Gastrointestinal complications were dominant, and sufficient for the patient to be qualified to combined liver-pancreas transplantation. First, hepatectomy was performed. The liver was transplanted orthotopically. Next, the team transplanted the pancreas in a standard manner. After the reperfusion, the donor's duodenum was anastomosed to the recipient's jejunum, close to the ligament of Treitz. Surgeons did not encounter any major problems during the transplantation. No serious complications followed the surgery. The grafts started functioning immediately. The patient became independent from external insulin and pancreatin, with good C-peptide levels and no steatorrhea. Standard immunosuppressive triple therapy with additional antithymocyte globulin was administered. She was discharged after six weeks in general good condition. Sixteen months later the patient felt well, and the grafts kept functioning properly.

Conclusions

In conclusion, combined liver–pancreas transplantation in patients with CF restores exocrine and endocrine pancreatic function and minimizes the risk of life-threatening complications associated with liver insufficiency. Improvement of life quality coincides with the possibility of discontinuing insulin and pancreatic enzyme supplementation. The combination of liver and pancreas transplantation may even prevent advanced pulmonary complications and extend the prognosis of survival.

[1962] Acute adrenal bleeding requiring an immediate surgery - a case report

Authors: Krzysztof Bratek, Joanna Kaszczewska

Affiliation: Department of General, Vascular, Endocrine and Transplant Surgery, Medical University of Warsaw

Trustee of the paper: dr n. med. Wawrzyniec Jakuczun, prof. dr hab. n. med. Zbigniew Gałązka

Corresponding author: Krzysztof Karol Bratek (krzyszbr@wp.pl)

Background

Adrenal bleeding is rare and potentially life-threatening condition, resulting from trauma or non-traumatic causes: stress, infectious diseases, coagulopathy, neoplastic diseases, adrenal tumors, and idiopathic. Adrenal bleeding symptoms are non-specific and depend on severity and intensity of bleeding, and the degree of adrenal tissue destruction.

The treatment should be individually adjusted, based on the hemodynamic stability, presence and intensity of active bleeding, and the overall patient's condition.

Case report

A 61-year-old male with past medical history: tachycardia-bradycardia syndrome, permanent atrial fibrillation (the patient admits rivaroxaban on a regular base), hypertension, chronic obstructive pulmonary disease, obstructive sleep apnea, obesity II/III after appendectomy - was hospitalized and treated conservatively in a city hospital due to 3,8x3,6 cm hematoma of left adrenal gland (Ag). 3 days after resuming the admission of anticoagulants, the patient presented to the Emergency Room with pain located in the left lumbar region. A computed tomography (CT) scan without contrast, revealed a 8x8x11 cm lesion. It progressed to 14x8x8 cm in the control contrast-enhanced CT. The laboratory tests revealed anemia - haemoglobin decreased from 13,9 g/dl to 12,6 g/dl. Due to the increase of the size of the lesion and haemoglobin decrease the acute bleeding to left Ag was diagnosed, and the patient was qualified for emergency surgery. The patient underwent classical adrenalectomy, during which a 14 cm haematoma was removed. The removed tissues were sent for histopathological examination, in which a nodular hyperplasia of adrenal cortex with ischemic necrosis and fields of partially organizing hematoma on the outskirts of the lesion were diagnosed.

Conclusions

A proper management of this non-specific disorder must be based on imaging examinations, carefully performed diagnosis, and adequate treatment, to allow for the best clinical outcome.

[1967] Recurrent intramedullary mature teratoma in the cervical spine - a case report.

Authors: Zuzanna Nogaj, Nikola Velkov

Affiliation: Poznan University of Medical Sciences, Poland and Plovdiv Medical University, Bulgaria

Trustee of the paper: Jeremi Kościński, M.D., Ph.D.

Corresponding author: Zuzanna Katarzyna Nogaj (zuzannanogaj@gmail.com)

Background

Intramedullary tumours are relatively rare spinal anomalies, especially when located in the cervical region. Scarce literature due to low frequency has made classifying these anomalies difficult. We present a case study of an adult cystic teratoma/ enterogenous cyst with recurrence after resection and discuss the confusion in the available literature regarding said classification.

Case report

A 31-year-old female presented to the neurosurgery department with a 5-year history of escalating interscapular pain, heightened whole-body sensitivity to pain and weakness in the extremities. Medical history is significant for craniospinal mass extending from the cerebellum to C4 with intramedullary involvement and dysraphic features from 21 years prior. Said mass was classified as an enterogenous cyst. Suboccipital craniotomy, C1-C3 laminectomy, foramen magnum decompression and gross total resection of mass were successfully performed. The recovery was complicated by chronic meningitis, which resulted in a second surgery - relaminotomy with wound inspection. Following physical rehabilitation, the condition gradually improved to baseline. On present examination, MRI displayed an intramedullary mass, located between C2 and C3 vertebrae, with the typical appearance of a cystic tumour. Utilizing the same access and posterior approach as the first resection surgery, but on this occasion also incorporating intraoperative neuromonitoring, gross total resection was again achieved. Two weeks into the recovery period, CSF leak from the wound was noted, necessitating its revision. From then on, recovery was uneventful, and no neurological deficits were observed. It should be noted that pathomorphological examination of the first lesion came out with a Wilkins 3 or C class, which the literature reports as being more prone to recurrence after resection. There has been a lack of consensus regarding terminology surrounding this type of lesion. It has been suggested in the literature that an isolated lesion with no associated dysraphic abnormalities be referred to as "Mature Teratoma," while the term "Enterogenous cyst" be reserved for when such changes are present.

Conclusions

We would like to use this case report as a positive example promoting the usage of pathomorphological subtyping as a predictor for the course and potential recurrence of these rare pathologies. Furthermore, we believe that the neuromonitoring during this last intervention had a substantial impact on its excellent outcome.

[1981] Perivascular epithelioid cell tumor in kidney transplant recipient with tuberous sclerosis complex

Authors: Marcin Dymkowski, Piotr Niecikowski

Affiliation: Katedra i Klinika Chirurgii Ogólnej i Transplantacyjnej UCK WUM

Trustee of the paper: prof. dr hab. n. med. Maciej Kosieradzki

Corresponding author: Marcin Rafał Dymkowski (mrcn.dymkowski@gmail.com)

Background

Perivascular epithelioid cell tumor (PEComa) is a rare tumor of mesenchymal origin, composed mostly of perivascular epithelioid cells. One of its most common localizations is uterus, whereas only few studies reported PEComa localization as liver. There is a correlation between the presence of PEComa and tuberous sclerosis complex (TSC). TSC is a rare disease which leads to development of many non-cancerous tumors in various organs. We would like to present a case of a kidney transplant recipient with a PEComa detected post-transplant in the liver.

Case report

A 24-year old patient with chronic renal failure in the course of autosomal dominant polycystic kidney disease and concomitant tuberous sclerosis complex (TSC) was admitted to the Clinic and Department of General and Transplant Surgery for preemptive kidney transplantation from a deceased donor and qualified for the operation. Transplantation was successfully performed and the graft began to function with increasing diuresis from 600ml on the first day after surgery to 2600ml on the third day. During graft preparation a cystic lesion, 6mm in diameter, was excised and sent for histopathological examination, which revealed a type 1 papillary renal cell carcinoma (PRCC). Therefore the patient was put in oncological supervision in the post-transplant period. Three years after KTx the control computed tomography scan of the abdomen revealed two tumors in the liver, one 27mm in diameter in segment VII/VIII and the other 8mm in diameter in segment II/III. Because of typical radiological signs hepatocellular carcinoma was suspected, but the serum level of alpha fetoprotein was within normal limits and liver function was preserved. The biopsy and the thermoablation of the tumor were performed three months later. In the histopathological examination benign PEComa (HMB45 +, Melan A +) was detected.

Conclusions

In a 7-year follow-up no sign of PRCC was found and the oncological supervision made it possible to detect tumors in the liver in presymptomatic phase.

[3004] Nocardiosis – A Surgical Case Report

Authors: Viktoriia Kulyk, Yevhenii Prykhodko

Affiliation: Bogomolets National Medical University

Trustee of the paper: Oleksandr Stetsenko, Candidate of Medical Sciences, Associate Professor;
Stepan Kindzer, Candidate of Medical Sciences

Corresponding author: Viktoriia Kulyk ()

Background

Nocardiosis is a tropical opportunistic disease caused by the gram-positive bacterium *Nocardia* spp. It affects people with HIV/AIDS immunodeficiency, systemic connective tissue diseases, diabetes, immunosuppression due to long-term use of corticosteroids, certain congenital immunity pathologies. Primary nocardiosis has three clinical forms: pulmonary, generalized and cutaneous (mycetoma). Secondary nocardiosis occurs in two forms: pulmonary and septic. 33% of immunocompromised patients have cutaneous form of nocardiosis. A total of 699 cutaneous nocardiosis cases were detected from 2000 to 2020. The MALDI-TOF MS (Matrix Assisted Laser Desorption/Ionization - Time of Flight) is one of the modern methods of laboratory diagnostics.

Case report

A 65 years old female, presented with multiple small infiltrates, swelling and redness on her right shin. She had been sick for 3 months. Condition gradually had been worsening and came with an intensive increasing pain in her right shin and the movement disability. She had suffered rheumatoid arthritis, seropositive (RF+) polyarthritis for 8 years. Blood and urine laboratory tests determined the signs of multiple organ failure. On the first day, surgical intervention was performed by curing the abscess under intravenous anaesthesia. Attention was drawn to the purulent exudate, which had a mucous and thick consistency and was odourless and yellowish. *Nocardia Africana* was detected by the means of MALDI-TOF MS analysis. Every day, the patient received antipyretic (to cease T above 38.5 C), antibacterial therapy (trimethoprim-sulfamethoxazole 480 mg IV twice a day, ceftriaxone), analgesics, and wound dressings with Octenisept. Wounds were healed by secondary intension.

Conclusions

The implementation of the latest bacteriological research technologies helps to identify pathogens easier and better. Rapid detection of pathogens allows us to prescribe etiotropic therapy instead of empiric one. The prescription of etiotropic therapy significantly reduces the risk of developing antibiotic resistance.